SPANDIDOS PUBLICATIONS

MOLECULAR AND CLINICAL ONCOLOGY 16: 24, 2022

Pathological examination of a placenta leading to the diagnosis of endometrial carcinoma: A case report

TAKAAKI MAEDA, MASATO NISHIMURA, EISHI SOGAWA, TAKASHI KAJI, MINORU IRAHARA and TAKESHI IWASA

Department of Obstetrics and Gynecology, Tokushima University Hospital, Tokushima 770-8503, Japan

Received May 12, 2021; Accepted August 4, 2021

DOI: 10.3892/mco.2021.2457

Abstract. Although endometrial cancer is extremely rare during pregnancy, the placental metastasis of endometrial cancer is even rarer. The current study presents a case of endometrial carcinoma that was diagnosed through the pathological examination of the placenta. A 35-year-old primipara woman who underwent frozen-thawed embryo transfer at the Keiai Ladies Clinic in Tokushima prefecture (Japan) received regular prenatal check-ups. She was transferred to Tokushima University Hospital for perinatal management due to the preterm premature rupture of membranes at 21 weeks and 6 days gestation. The administration of antibiotics and tocolytic agents was continued; however, labor pain occurred at 23 weeks and 3 days gestation, and a female fetus weighing 524 g was delivered vaginally. The placenta weighed 262 g and had no macroscopic abnormalities. It was submitted for pathological examination, which revealed metastatic adenocarcinoma (clear cell carcinoma suspected). The patient was subsequently diagnosed with endometrial cancer (stage I suspected), and underwent abdominal total hysterectomy, bilateral salpingo-oophorectomy, partial omentectomy and pelvic lymph node dissection. The final diagnosis was stage IA endometrial cancer (endometrioid carcinoma, G2). At 1 year after surgery, there was no evidence of disease. The present case highlights the importance of considering the emergence of endometrial cancer during pregnancy.

Introduction

When an abnormality occurs during the course of pregnancy, such as premature birth, the placenta is submitted for a pathological examination to identify the underlying cause. In some cases, malignant tumors are detected in the placenta. The placental metastasis of maternal malignancy is very rare. Previous case reports of metastatic tumors in the placenta included malignant melanoma, breast cancer, lung cancer, hematological malignancies, gastric cancer, and ovarian cancer (1,2). Most gynecological malignancies diagnosed during pregnancy are cervical and ovarian cancer (1). Endometrial cancer is often associated with estrogen, and so mostly occur in peri- or postmenopausal woman. However, endometrial cancer occurs in 5% of women <40 years of age. Smoking, family history, obesity and unstable menstruation are strong risk factors for endometrial cancer in individuals that are <40 years old. It is rare to observe endometrial cancer during or before pregnancy. Most patients diagnosed with endometrial cancer during pregnancy are first-trimester, which is attributable to spontaneous abortions by dilatation and curettage (3,4). A previous report has indicated that the symptoms of spontaneous abortion are often genital bleeding, which may be caused by damage of chorionic villi due to the the presence of endometrial cancer (3). Endometrial cancer before pregnancy adversely affects the intrauterine environment and implantation. Therefore, it is very rare to be able to deliver a surviving baby in a pregnancy where the mother is diagnosed with endometrial cancer. In some cases, endometrial cancer can be diagnosed postpartum. As a histopathological type, the proportion of grade 1 to 2 endometrioid adenocarcinoma is high (5). To the best of our knowledge, the placental metastasis of endometrial cancer has not yet been reported. In pregnancies where the individual has cancer and in nonpregnant patients, the former has a worse prognosis and worse response to therapy (6). Additionally, the diagnosis of cancer during pregnancy is often delayed due to pregnancy-specific changes. For example, the breast is well developed following hormonal changes during pregnancy, such that the sensitivity of mammography decreases (6). Certain reports indicate that pregnancy does not affect the prognosis of patients with endometrial cancer; however, it is unclear how endometrial cancer affects pregnancy or how pregnancy affects endometrial cancer (5). We herein describe a case in which a pathological examination of the placenta led to a diagnosis of endometrial carcinoma.

Case presentation

Placental pathology of endometrial carcinoma. A 34-year-old Japanese woman presented to a local clinic with infertility. An examination at the clinic revealed no thickening of the

Correspondence to: Dr Takaaki Maeda, Department of Obstetrics and Gynecology, Tokushima University Hospital, 2-50-1 Kuramoto-cho, Tokushima 770-8503, Japan
E-mail: sikakajyositakaaki@yahoo.co.jp

Key words: placental metastasis, endometrial cancer, placenta pathological examination

endometrium; therefore, the patient was treated with clomiphene citrate, received gonadotropin therapy, and underwent artificial insemination. However, she did not become pregnant. One year later, she underwent frozen-thawed embryo transfer with a hormone replacement therapy cycle regimen (estradiol patch, vaginal progesterone 300 mg/day) and became pregnant. The patient was referred to another hospital for an epidural birth. Although the progression of the pregnancy was uneventful, the patient presented to the hospital with scant bleeding in the 21st (21+2) week of gestation. A shortened cervical length and uterine contractions were detected. Therefore, the patient was admitted to the hospital with a diagnosis of threatened premature delivery and was administered ritodrine. The patient was diagnosed with the premature rupture of membranes and transferred to our hospital at 21 weeks and 6 days gestation. No obvious abnormalities were observed in the fetus, placenta (attached to the posterior wall of the uterus), or umbilical cord. Tocolytic agents (ritodrine and magnesium sulfate) and prophylactic antibiotics were administered. Labor pain occurred on the 23rd (23+3) week of gestation, and a female fetus weighing 524 g was delivered vaginally. Apgar scores at one and five minutes were two and seven, and umbilical artery pH was 7.2. The placenta was 262 g with no major macroscopic abnormalities. Since this was a preterm birth, the placenta was submitted for a pathological examination, which revealed metastatic adenocarcinoma (Expression of estrogen receptor was observed, but clear cell carcinoma was suspected because immunohistochemistry analysis showed positive for PAX8 and HNF1B; the tumor was also negative for CD10, Glypican, AMACR and p53). No significant inflammatory cell infiltration was noted in the placenta or umbilical cord. (Fig. 1A-E).

Diagnosis of endometrial carcinoma. One month postpartum, a high echoic mass of 1.5 cm was detected in the endometrial cavity by transvaginal ultrasonography, and endometrial cancer was suspected. (Fig. 2A). Cytological findings of the uterine cervix were negative for intraepithelial lesions and malignancy, and endometrial cytology was also negative. Biopsy of the lesion revealed adenocarcinoma, and the final diagnosis was endometrial cancer. A 4-cm mass was detected in the endometrial cavity by contrast-enhanced magnetic resonance imaging. (Fig. 2B and C) Contrast-enhanced computed tomography did not show any distant metastasis, and tumor markers (CEA, CA125, and CA19-9) were negative.

The patient was diagnosed with endometrial cancer (stage I suspected), and underwent abdominal total hysterectomy, bilateral salpingo-oophorectomy, partial omentectomy, and pelvic lymph node dissection based on suspected clear cell carcinoma in the preoperative diagnosis (intraoperative consultation, endometrioid carcinoma, grade 2, invasion involving less than one-half of the myometrium) (Fig. 3).

The postoperative diagnosis was endometrial cancer stage 1A (pT1aN0M0, endometrioid carcinoma, grade 2, negative peritoneal lavage cytology, positive lymphatic vessel invasion, negative blood vessel invasion, and myometrium invasion of 3 mm with endometrial thickness of 20 mm). There has been no evidence of disease one year after surgery and the patient is being followed up.

Discussion

The incidence of malignancy during pregnancy ranges between 0.05 and 0.1% (1). Common malignancies during pregnancy include melanoma, ovarian cancer, cervical cancer, leukemia, and breast cancer, whereas endometrial cancer is rare (2). In recent years, the number of cases of endometrial cancer in patients younger than 40 years and those with an advanced maternal age due to assisted reproductive technology has been increasing. Therefore, the rate of malignancy during pregnancy has also increased. A risk factor for endometrial cancer is the excessive and unopposed exposure of the endometrium to estrogen, such as obesity and nulliparity; therefore, pregnancy is a protective factor. The patient is overweight (Body Mass Index is 27.9 kg/m^2) and has had menstrual disorders since junior high school student.

In the present case, endometrial cancer may have been present before or during pregnancy. We identified dozen of cases of endometrial carcinoma during pregnancy; however, more than 50% were detected at the time of dilatation and curettage for first-trimester spontaneous abortions (3-5). Other cases were diagnosed after childbirth. Although the reason why endometrial cancer coexists with pregnancy currently remains unknown, the partial resistance of the endometrium to progesterone has been proposed (3,6). In most cases, the histopathology of endometrial cancer during pregnancy is endometrioid carcinoma (4,5). The present case became pregnant by frozen-thawed embryo transfer with a hormone replacement therapy cycle regimen; therefore, the intra-uterine concentration of progesterone was high. A high progesterone status during pregnancy may have suppressed the growth of endometrioid carcinoma. Since the placenta was attached to the posterior wall of the uterine and located at a different position to the site of cancer, the pregnancy continued.

The underlying reason for the premature rupture of membranes was inhibited uterine growth and increased intrauterine pressure caused by cancer in the uterus. Previous cases of maternal to placental metastasis included malignant melanoma, gastric cancer, leukemia, breast cancer, lung cancer, and ovarian cancer (7-9). Furthermore, many cases of placental metastasis were advanced cancers. To the best of our knowledge, the placental metastasis of endometrial cancer has not yet been reported. A previous study showed that placental metastasis occurred via blood vessels (9). In the present case, the placenta was closely located to the site of cancer in the peripheral tissues, which allowed for its migration or attachment to the placenta.

Metastasis to not only the placenta, but also to the fetus may occur, and this may be attributed to the immature fetal immune system (8). Therefore, metastasis to the fetus also needs to be considered. At this time, it does not recognize obvious abnormalities in the pelvis by ultrasonography, but we will continue to follow up.

Lynch syndrome accounts for 2% of all endometrial cancer cases (10). Since our patient was young and has a family history of rectal cancer (father), it is important to consider the possible diagnosis of Lynch syndrome. Follow-up assessments are needed for both the patient and

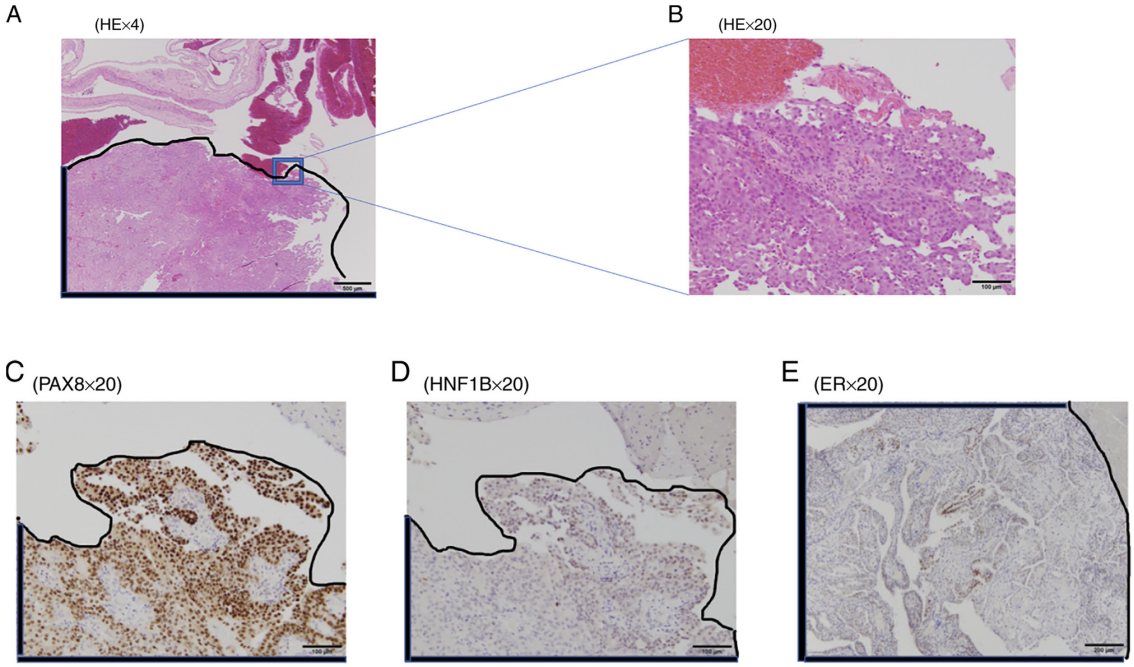

Figure 1. Histopathological findings of a resected placenta specimen. The tumor site is indicated by a black line. Microscopically, at (A) x4 and (B) x20 magnifications, a 10-mm neoplastic lesion in a section of the placenta exhibited metastatic adenocarcinoma. The tumor grew with a solid and luminal structure, and metastatic adenocarcinoma was suspected. Clear cell carcinoma was additionally suspected as immunohistochemistry analysis demonstrated that samples were positive for (C) PAX8 and (D) HNF1B (magnification, x20). PAX8 demonstrated strong positive staining in ~50% of the tumor. HNF1B was weakly positive in ~5% of the tumor. The tumor was however negative for CD10, Glypican, AMACR and p53. (E) ER demonstrated strong positive staining in ~10% of the tumor (magnification, x20). HE, hematoxylin and eosin; PAX8, paired box 8; HNF1B, hepatocyte nuclear factor 1β; ER, estrogen receptor.

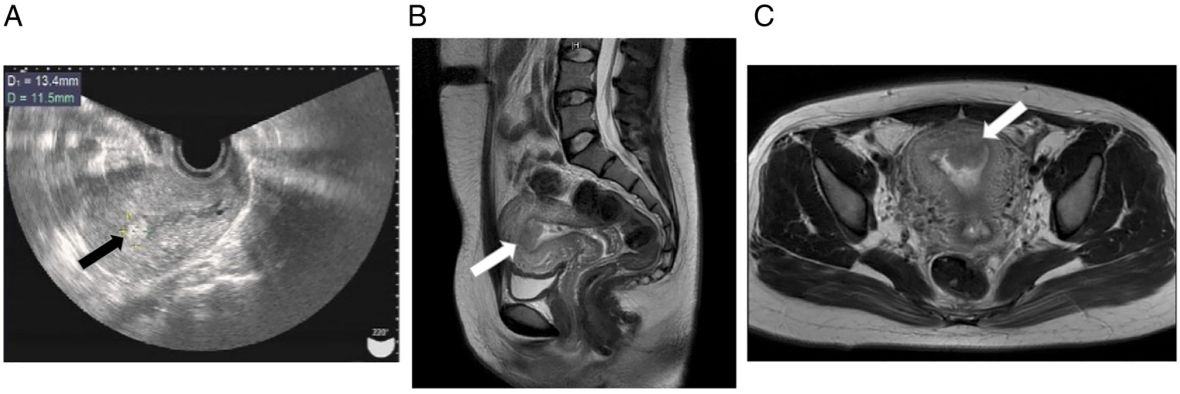

Figure 2. Transvaginal ultrasonographic and MRI findings after 1 month postpartum. (A) Transvaginal ultrasonography demonstrated a high echoic mass of 1.5 cm in the endometrial cavity 1 month postpartum. (B) Sagittal and (C) axial contrast-enhanced T2-weighted MRI revealed endometrial carcinoma measuring 4 cm in diameter with a low signal. The location of the tumor is indicated by an arrow.

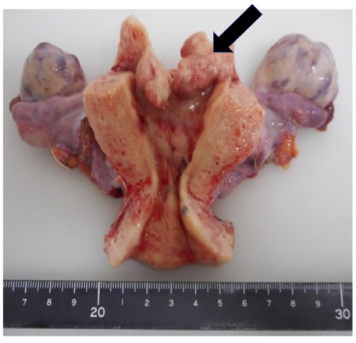

Figure 3. Macroscopic findings in the surgical specimen of the uterus and bilateral adnexa. The uterus was spilt at the front. Endometrial carcinoma is present in the uterine fundus. The location of the tumor is indicated by an arrow.

the child. However, NGS method was not performed due to lack of her consent; Therefore, we plan to begin colorectal surveillance with the possibility of Lynch syndrome in mind.

In previous cases of placental metastasis, metastatic lesions were not observed macroscopically, similar to the present case.

In conclusion, the study confirms the need to perform a histopathological examination of the placenta in the abnormal course of pregnancy, especially in all cancers coexisting with pregnancy and shows that careful observation of the potential development of hormone-dependent tumors during assisted reproductive procedures is needed.

Acknowledgements

The authors would like to thank Dr Takumi Kakimoto (Department of Pathology, Tokushima University Hospital) for conducting pathological evaluations.

Funding

No funding was received.

Availability of data and materials

The datasets used and/or analyzed during the current study are available from the corresponding author on reasonable requests.

Authors' contributions

MN, ES, TK, MI, TI and TM were involved in the conception and design of the current study. TM wrote the manuscript. MN, MI and TI supervised the study. TM and MN confirm the authenticity of all the raw data. All authors have read and approved the final version of the manuscript.

Ethics approval and consent to participate

The present study was approved by the Institutional Review Board of The University of Tokushima Hospital. Written informed consent was obtained from the patient.

Patient consent for publication

Consent for publication was obtained from the patient.

Competing interests

The authors declare that they have no competing interests.

References

1. Skrzypczyk-Ostaszewicz A and Rubach M: Gynaecological cancers coexisting with pregnancy-a literature review. Contemp Oncol (Pozn) 20: 193-198, 2016.
2. Pavlidis N, Peccatori F, Lofts F and Greco AF: Cancer of unknown primary during pregnancy: An exceptionally rare coexistence. Anticancer Res 35: 575-579, 2015.
3. Zhou F, Qian Z, Li Y, Qin J and Huang L: Endometrial adenocarcinoma in spontaneous abortion: Two cases and review of the literature. Int J Clin Exp Med 8: 8230-8233, 2015.
4. Saciragic L, Ball CG, Islam S and Fung-Kee-Fung M: Incidental endometrial carcinoma diagnosed at first trimester pregnancy loss: A case report. J Obstet Gynaecol Can 36: 1010-1013, 2014.
5. Shiomi M, Matsuzaki S, Kobayashi E, Hara T, Nakagawa S, Takiguchi T, Mimura K, Ueda Y, Tomimatsu T and Kimura T: Endometrial carcinoma in a gravid uterus: A case report and literature review. BMC Pregnancy Childbirth 19: 425, 2019.
6. Hoellen F, Reibke R, Hornemann K, Thill M, Luedders DW, Kelling K, Hornemann A and Bohlmann MK: Cancer in pregnancy. Part I: Basic diagnostic and therapeutic principles and treatment of gynecological malignancies. Arch Gynecol Obset 285: 195-205, 2012.
7. Altman JF, Lowe L, Redman B, Esper P, Schwartz JL, Johnson TM and Haefner KH: Placental metastasis of maternal melanoma. J Am Acad Dermatol 49: 1150-1154, 2003.
8. Oga S, Hachisuga M, Hidaka N, Fujita Y, Tomonobe H, Yamamoto HY and Kato K: Gastric cancer during pregnancy with placental involvement: Case report and review of published works. Obstet Gynecol Sci 62: 357-361, 2019.
9. Honda M, Yamada M, Kumasawa T, Samejima T, Satoh H and Sugimoto M: Recurrence of ovarian cancer with placental metastasis: A case report. Case Rep Oncol 10: 824-831, 2017.
10. Pellat A, Netter J, Perkins G, Cohen R, Coulet F, Parc Y, Svrcek M, Duval A and André T: Lynch syndrome: What is new? Bull Cancer 106: 647-655, 2019 (In French).