# Primary urethral carcinoma with variant histology: A case report and literature review

MIAO LIU[1*], SHENGHAN XU[1*], JUN HE[1], YI MU[1], KEHANG CHEN[1], WENJUN ZHANG[1], BANGWEI CHE[1] and KAIFA TANG[1,2]

[1]Department of Urology, Affiliated Hospital of Guizhou Medical University; [2]Institute of Medical Science of Guizhou Medical University, Guiyang, Guizhou 550004, P.R. China

Received April 29, 2022; Accepted July 25, 2022

DOI: 10.3892/mco.2022.2575

**Abstract.** Primary urethral carcinoma (PUC) has rarely been reported, notably with variant histology. The present case reports a 68-year-old male patient with a 3-month history of difficulty voiding urine accompanied by a burning sensation in the urinary tract and hematuria. Urethrography and computed tomography (CT) indicated a mass localized in the urethral bulb. A fine needle biopsy revealed the mass to be a malignant tumor of the urethra. Partial penectomy was eventually performed and postoperative histopathological examination confirmed that the lesion was PUC, with mixed characteristics of urothelial and squamous differentiation. The patient was postoperatively followed up and at 9 months, a repeat CT scan revealed local recurrence and metastases. The patient rejected further treatment and eventually succumbed to the disease three months later. The present case report demonstrates an example in which urothelial and squamous differentiation simultaneously exist in the pathological report. The clinical features, diagnosis and treatment status of PUC were also summarized and analyzed to improve the clinical understanding of this unique disease.

## Introduction

Primary urethral carcinoma (PUC) is an aggressive and infrequent carcinoma, accounting for ≤1% of malignant tumors of the genitourinary system (1). The incidence of this cancer in male subjects is three times higher than that of female subjects and an increased incidence has been noted for the elderly (2). Recurrent urinary tract infections, sexually transmitted diseases and chronic irritation through catheterization, are important risk factors for the development of PUC (3). According to the current World Health Organization-based program, three main histological types have been reported for PUC, including urothelial carcinoma (UCSD; 55%), squamous cell carcinoma (21.5%) and adenocarcinoma (16.4%) (4). The remaining cases are extremely rare and involve clear cell and adenoid cystic carcinomas (5).

The presence of tissue variations in the pathological reports is very important due to their prognostic and therapeutic significance (6). Squamous differentiation of UCSD refers to the presence of both urothelial and squamous differentiation in the same tumor, although the ratio of the two is not clearly defined. Squamous differentiation requires the presence of intercellular bridges and/or keratinization (7). UCSD accounts for 10-20% of bladder cancer cases and is the most common variant of bladder cancer (8). Muscle invasion is present in 60-70% of UCSD cases. The latter is considered a more invasive cancer type that progresses more rapidly than pure UCSD and is associated with a poor prognosis (7). However, in contrast to UCSD, PUC with squamous differentiation is rarely reported. In the present study, a rare case of a male patient is presented whose pathological result was UCSD in PUC. The clinical challenges and management of this condition were discussed.

## Case report

A 68-year-old man who presented with the major complaint of an extra-urethral mass and difficulty voiding urine was treated at the Affiliated Hospital of Guizhou Medical University (Guiyang, China). A hard mass with poor mobility and an approximate size of 3x2 cm could be palpated in the overhanging part of the penis approximately 1.5 cm from the distal end of the penile bulb. The prostatic findings were normal and no enlarged lymph nodes were found by bilateral inguinal palpation. No abnormalities were found in the remaining laboratory tests except for hematuria, which was indicated by urine analysis.

The patient had undergone several imaging examinations. Urethrography indicated an apparent urethral stricture (Fig. 1A). Abdominal computed tomography (CT; Fig. 1B)

*Correspondence to:* Professor Kaifa Tang, Department of Urology, Affiliated Hospital of Guizhou Medical University, 9 Beijing Road, Guiyang, Guizhou 550004, P.R. China
E-mail: tangkaifa@gmc.edu.cn

[*]Contributed equally

*Key words:* primary urethral carcinoma, variant histology, squamous differentiation of urothelial carcinoma, surgical therapy, case report

demonstrated the presence of a neoplastic lesion in the overhanging part of the penis, with approximate dimensions of 4.0x2.0x2.0 cm. Concomitantly, abdominal CT indicated that the inner wall of the bladder was smooth in the absence of an apparent space-occupying sign. The bladder was devoid of inguinal nodules, and organ or other nodal metastases (cT3 cN0 cM0). Preoperative urethral cystoscopy confirmed the presence of urethral stricture and the space-occupying site was located approximately at a site 7.0 cm from the external orifice of the urethra. After the replacement of a thinner pediatric ureteroscope, it was still unable to pass through the narrow segment. Therefore, a fine needle biopsy had to be performed on the mass site of the patient. The results suggested that the tumor was malignant. Subsequently, a partial penectomy was performed. Notably, during the surgery, it was found that the mass had invaded the corpus cavernosum (Fig. 1C and D).

Microscopic findings (Fig. 2A) and immunohistochemical results combined with clinical data indicated the presence of high-grade UCSD with focal areas of squamous differentiation. Fortunately, no neoplastic involvement was present in the surgical resection margins. Immunohistochemical analysis provides a semi-quantitative assessment of the expression levels of specific markers in tumor cells. These cells are considered to be positive or negative with regard to the expression of these markers. The immunohistochemical results in the present study were the following: Cytokeratin (CK) 5/6 (+) (Fig. 2B), P40 (nuclear and cytoplasmic +) (Fig. 2C), CK7 (+), p63 (+), GATA binding protein 3 (nuclear focally and weakly +) (Fig. 2D), CK20 (-), uroplakin III (-), and prostate-specific antigen (-).

Therefore, the patient was discharged. During the 3-month postoperative follow-up, no apparent abnormality was noted according to the laboratory or imaging examination. However, 9 months later, the patient returned to the hospital due to recurrent dysuria with hematuria and a re-examination of abdominal enhancement CT indicated that the enhancement of the anterior part of the cavernous body was decreased (Fig. 1E), the enhancement of the prostate was uneven, and the bilateral inguinal lymph nodes were enlarged with apparent enhancement (Fig. 1F). The final clinical diagnosis was tumor recurrence with prostate invasion and bilateral inguinal lymph node metastasis. Due to the poor medical condition of the patient, multimodal treatment was declined, including salvage surgery and/or chemoradiotherapy, and cystostomy was accepted to merely relieve urinary retention. As a consequence of his progressive disease, the condition of the patient significantly deteriorated. The patient succumbed to his illness, 3 months after the recurrent presentation.

## Discussion

PUC is defined by the European Association of Urology as a tumor with its very first lesion located in the urethra (9). Early diagnosis of urethral cancer is difficult due to the absence of apparent symptoms in the early stages and a lack of specific screening indicators. The major role of the imaging examination of primary urethral cancer is to detect the extent of the local lesions and to evaluate the presence of metastatic diseases. Due to its improved spatial resolution, superior soft tissue contrast, and lack of ionizing radiation, magnetic resonance imaging (MRI) has emerged as the most sensitive imaging modality for assessing the local staging of urethral cancer (10). Although MRI performs well in the local staging of the disease due to its excellent representation of the soft tissue, CT imaging can accurately depict adenopathy and distant metastatic disease in the abdomen and pelvis (11). The CT imaging of this patient indicated that the tumor invaded the corpus cavernosum; however, no enlarged pelvic or celiac lymph nodes were found. The disease was staged as T3N0M0 according to the tumor, nodes, and metastases classification of the newly updated European Association of Urology Guidelines for primary urethral carcinoma (12).

As an invasive examination, diagnostic urinary cystoscopy and biopsy can initially evaluate urinary tract tumors based on the extent, location, and potential histology of the tumor (13). Multiple methods, such as cystoscopy with cold-cup biopsy forceps or a transurethral/percutaneous approach using a 14-gauge Temno biopsy needle, can aid the diagnosis of the proximal tumors (14). Although the present case report was prepared to be examined by diagnostic urethrocystoscopy, a successful diagnosis was not possible due to urinary tract stricture, which was confirmed by urethrography.

Given the rarity and lack of level I evidence of primary urethral cancer, a limited number of prospective multi-agency studies have determined the optimal treatment for PUC. For several years, partial or radical penectomy for distal tumors and total penectomy with cystoprostatectomy for proximal tumors were the standard treatments for urethral cancer. A retrospective cohort study of 1,544 non-metastatic patients with PUC indicated that the overall 5-year survival rate of patients who received local treatment or radical surgery was considerably higher than that noted in patients who did not undergo surgery at the primary site (1). Penis preservation surgery is recommended by the current guidelines for the treatment of localized PUC. This method has become the preferred treatment option while maintaining optimal local cancer control (12,15). A retrospective series demonstrated that for patients with pT1-3NO-2 anterior urethral cancer and clinically suspected nodular diseases, penis-preserving surgery with <5 mm resection margins combined with iliac/inguinal lymphadenectomy did not lead to local recurrence of the disease (16). In the present case report, for the patient in stage cT3N0M0, according to the disease management of the European Association of Urology Guidelines on Primary Urethral Carcinoma in Males with Localised PUC (12), and combined with the willingness of the patient and his family to retain the penis, partial penectomy without inguinal lymphadenectomy was finally performed.

Radiation therapy (RT) or chemotherapy are the two standard treatment options for the treatment of patients with PUC in addition to surgery. In localized PUC, the survival rate and recurrence rate of RT are worse than those of surgery. In addition, the patients experience a higher number of side effects, which limit the application of RT in genital protection therapy (2). However, in locally advanced UC, multimodal therapy is highly respected in both sexes due to the monotherapies leading to lower disease recurrence and patient survival rates. Multimodal therapy in PUC includes definite surgery plus chemotherapy and additional RT can be selected (14). According to the National Cancer Database, the overall survival rate of patients with locally advanced PUC

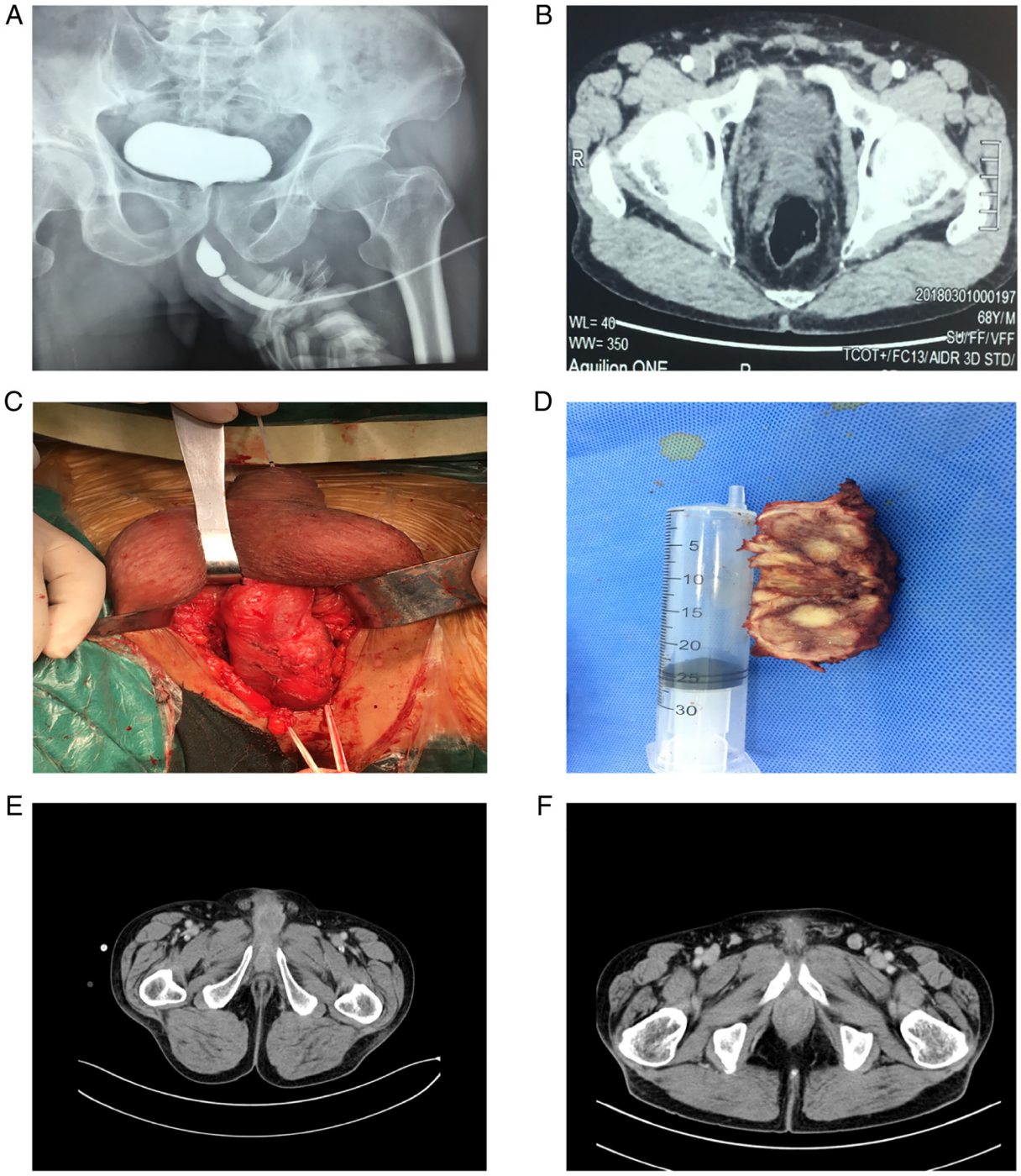


Figure 1. Imaging examination and gross specimens of urethral tumors. (A) Retrograde urethrogram demonstrated urethral strictures of the bulbar urethra and the uneven wall of the urethra. (B) A lower abdominal CT examination indicated that the tumor was located in the urinary bulb and its dimensions were approximately 4.0x2.0x2.0 cm. The tumor indicated apparent inhomogeneous enhancement. (C) Partial penectomy of the urethral tumor. (D) The mass following partial penectomy. (E) Re-examination of abdominal enhancement CT demonstrated uneven enhancement of the anterior part of the corpus cavernosum of the penis. (F) Enlarged left inguinal lymph nodes with apparent enhancement. CT, computed tomography.

receiving well-defined multimodal treatment has improved. A large multicentre cohort study demonstrated increased overall survival rates in patients who received perioperative chemotherapy plus surgery for advanced PUC (17). The patient reported in the present study exhibited a postoperative recurrence. Due to this fact, neoadjuvant chemotherapy with 5-fluorouracil and cisplatin combined with salvage surgery was recommended. Unfortunately, due to his poor performance status and expensive treatment, as well as the fact that the tumor may have metastasized to the prostate and inguinal lymph nodes, the patient refused the treatment.

In recent years, with the deepening of our understanding of tumor immunology, systemic immunotherapy targeting immune checkpoint inhibition has been explored and applied in the field of urothelial cancer (18). Despite the fact that a limited number of systematic reports or no reports have been published on the use of immunotherapy for urethral cancer, the latest literature has suggested that programmed death-ligand

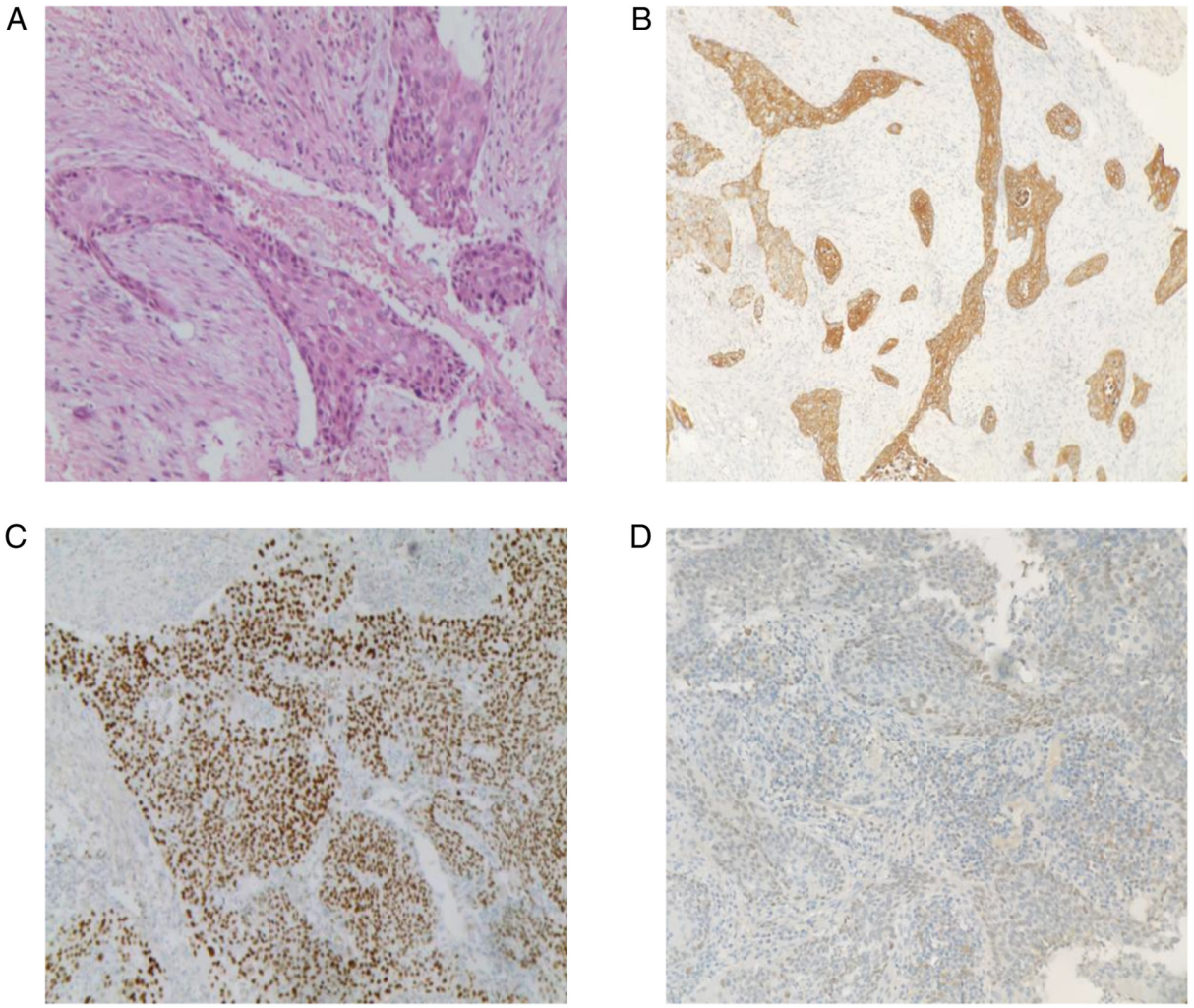


Figure 2. Histopathological examination of the resected specimen. (A) H&E staining of tumor sections indicated infiltrative growth of cancer nests in the stroma. Certain cells had rich cytoplasm and were slightly eosinophilic with large and deep stained nuclei and paving stone-like changes. The differentiation of the squamous epithelium and the proliferation of the surrounding fibrous tissue was also noted (original magnification, x200). Immunohistochemical staining of the tumor cells revealed positive expression for (B) CK5/6 (original magnification, x40), (C) P40, (original magnification, x100), and nuclear focal and weak positivity for (D) GATA-3 (original magnification, x40). H&E, hematoxylin and eosin; CK5/6, cytokeratin 5/6; GATA-3, GATA-3, GATA binding protein 3.

1 May be strongly expressed in certain urethral adenocarcinomas. Therefore, it is possible to apply immunotherapy in specific cases of advanced or recurrent adenocarcinoma. Miyama *et al* (19) reported for the first time that squamous differentiation is a potential and novel marker used for the prediction of the treatment of progressive UCSD with pembrolizumab therapy. The study further demonstrated that squamous differentiation was significantly associated with tumor progression and shorter overall survival.

In general terms, different histological results are closely related to the presence of high-level and high-stage diseases (8). Accurate classification is important as the clinical behaviors, prognosis, and therapeutic strategies differ between pure urothelial carcinoma, UCSD, and pure squamous cell carcinoma (20). Liu *et al* (21) reported that UCSD was frequently detected in patients with advanced tumor stage (pT3-4: 72.3%) and nodal metastasis. A retrospective study proposed that compared with pure UCSD, UCSD indicated a considerably higher pathological stage. Moreover, it was reported that UCSD of the bladder may be associated with a poor oncological outcome following radical cystectomy and it could be used to predict lowered rates of overall survival and recurrence-free survival (22). Although a limited number of studies have been reported, it is generally accepted that squamous differentiation is not confined to UCSD of the bladder as this morphology has also been reported in UCSD of the PUC. Zhang *et al* (23) focused on 130 cases of primary urethral tumors, of which 106 were classified as 'PUCs'. The latter is a new entity proposed by the authors of that study and refers to poorly differentiated tumors with mixed features of urothelial and squamous differentiation. It is considered that this type of cancer is different from the typical UCSD in the bladder and from the squamous cell carcinoma in the male distal urethral orifice, or balanus. It develops from the intraepithelial precursor state of the urethral mucosa to the sequence of dysplasia/carcinoma *in situ*. Clinically, it is highly invasive, with frequent regional lymphatic metastasis and distant organ metastasis. In the present case report, the microscopic findings indicated that the papillary structures of urethral carcinomas were short and irregular with an extensive fibrovascular core and cancer nest formation; in addition, the intercellular bridge could be observed in the squamous differentiation components. These

morphological characteristics are the basis for supporting the diagnosis of UCSD.

Pathological diagnosis is primarily based on morphology and immunohistochemistry, but when there are boundary features and tissue artifacts or morphological overlap, it will hinder the best evaluation of morphology, so the presence of immunohistochemical biomarkers may help differentiate between UCSD and traditional urothelial carcinoma. According to Gaisa *et al* (24), primary bladder squamous cell carcinomas were all positive for high molecular weight keratin CK5/6, whereas pure urothelial carcinomas were positive for 33%. In comparison with adenocarcinoma, a specific subtype of p63 called delta-np63 (P40) is not only expressed in 95% of urothelial cell carcinomas but also highly specific for squamous cell carcinomas (8). GATA3, a transcription factor located on chromosome 10p14, is a *trans*-acting T-cell-specific transcription factor (25). Based on the morphology of hematoxylin and eosin, GATA3 has a sensitivity of 88% and a specificity of 100% for distinguishing urothelial carcinoma from squamous cell carcinoma (26). Although there is no one-to-one correspondence between these biomarkers and a specific subtype of PUC, the immunohistochemical results of the above three coexisting biomarkers coupled with the morphological characteristics were highly consistent with those reported by Zhang *et al* (23).

Squamous differentiation has important diagnostic, prognostic, and therapeutic implications. This includes UCSDs or the new entities termed 'PUCs'. Ignoring this particular subtype may lead to an increased risk of clinical understaging and occult metastatic disease. However, the present case report has inherent limitations, such as the inability to generalize the findings reported, the inability to determine causality, and the risk of overinterpretation. In addition, since the Department of Pathology of our hospital did not report the lymphatic vessel, vein, or perineural invasion of the tumor, unfortunately, the specific mode of tumor invasion could not be elucidated. Despite these drawbacks, in future studies, individualized, risk-based, sex-specific treatment strategies for PUC are anticipated to be developed, based on the following important risk factors: Tumor location, clinical and pathological tumor stage, and histological classification. Furthermore, additional similar cases and potential molecular determinants will be of great significance for subsequent investigations since UCSD in PUC appears to be generally underrecognized and underreported.

In conclusion, the present study recommends that additional caution should be paid in patients with pathological findings suggestive of UCSD in PUC.

## Acknowledgments

Not applicable.

## Funding

No funding was received.

## Availability of data and materials

The datasets used and/or analyzed during the current study are available from the corresponding author on reasonable request.

## Authors' contributions

KT contributed to the concept and design of the case report. KT, ML, and SX participated in the surgery. ML produced the first draft of the article. SX and JH obtained the raw data of the patient, such as laboratory and imaging examinations and preliminary examination results, and participated in the diagnosis and treatment of the patient. YM and KC collected the postoperative pathological results and advised on patient treatment. KT, BC, and WZ critically revised the manuscript with regard to the content. All authors confirm the authenticity of the data and have read and approved the final manuscript.

## Ethics approval and consent to participate

Not applicable.

## Patient consent for publication

Written informed consent was obtained from the daughter of the patient for publication of this case report and of the accompanying images.

## Competing interests

The authors declare that they have no competing interests.

## References

1. Wu J, Wang YC, Luo WJ, Bo D, Ye DW and Zhu YP: Primary tumor surgery improves survival in non-metastatic primary urethral carcinoma patients: A large population-based investigation. BMC Cancer 21: 857, 2021.
2. Janisch F, Abufaraj M, Fajkovic H, Kimura S, Iwata T, Nyirady P, Rink M and Shariat SF: Current disease management of primary urethral carcinoma. Eur Urol Focus 5: 722-734, 2019.
3. Wenzel M, Nocera L, Colla Ruvolo C, Würnschimmel C, Tian Z, Shariat SF, Saad F, Briganti A, Tilki D, Mandel P, *et al*: Incidence rates and contemporary trends in primary urethral cancer. Cancer Causes Control 32: 627-634, 2021.
4. Williams C, Lamar M and Delgado P: Urethral carcinoma: A compilation of case studies and research findings. Urol Case Rep 31: 101169, 2020.
5. Moch H, Cubilla AL, Humphrey PA, Reuter VE and Ulbright TM: The 2016 WHO classification of tumours of the urinary system and male genital Organs-Part A: Renal, penile, and testicular tumours. Eur Urol 70: 93-105, 2016.
6. Shah RB, Montgomery JS, Montie JE and Kunju LP: Variant (divergent) histologic differentiation in urothelial carcinoma is under-recognized in community practice: Impact of mandatory central pathology review at a large referral hospital. Urol Oncol 31: 1650-1655, 2013.
7. Minato A, Fujimoto N and Kubo T: Squamous differentiation predicts poor response to cisplatin-based chemotherapy and unfavorable prognosis in urothelial carcinoma of the urinary bladder. Clin Genitourin Cancer 15: e1063-e1067, 2017.
8. Gellert LL, Warrick J and Al-Ahmadie HA: Urothelial carcinoma with squamous differentiation-the pathologists perspective. Urol Oncol 33: 437-443, 2015.
9. Gakis G, Witjes JA, Compérat E, Cowan NC, De Santis M, Lebret T, Ribal MJ and Sherif AM; European Association of Urology: EAU guidelines on primary urethral carcinoma. Eur Urol 64: 823-830, 2013.
10. Stewart SB, Leder RA and Inman BA: Imaging tumors of the penis and urethra. Urol Clin North Am 37: 353-367, 2010.
11. Galgano SJ, Sivils C, Selph JP, Sanyal R, Lockhart ME and Zarzour JG: The male urethra: Imaging and surgical approach for common pathologies. Curr Probl Diagn Radiol 50: 410-418, 2021.

12. Gakis G, Bruins HM, Cathomas R, Compérat EM, Cowan NC, van der Heijden AG, Hernández V, Linares Espinós EE, Lorch A, Neuzillet Y, *et al*: European association of urology guidelines on primary urethral carcinoma-2020 update. Eur Urol Oncol 3: 424-432, 2020.
13. Karnes RJ, Breau RH and Lightner DJ: Surgery for urethral cancer. Urol Clin North Am 37: 445-457, 2010.
14. Zinman LN and Vanni AJ: Management of proximal primary urethral cancer: Should multidisciplinary therapy be the gold standard? Urol Clin North Am 43: 505-513, 2016.
15. Spiess PE, Agarwal N, Bangs R, Boorjian SA, Buyyounouski MK, Clark PE, Downs TM, Efstathiou JA, Flaig TW, Friedlander T, *et al*: Bladder cancer, version 5.2017, NCCN clinical practice guidelines in oncology. J Natl Compr Canc Netw 15: 1240-1267, 2017.
16. Smith Y, Hadway P, Ahmed S, Perry MJ, Corbishley CM and Watkin NA: Penile-preserving surgery for male distal urethral carcinoma. BJU Int 100: 82-87, 2007.
17. Gakis G, Morgan TM, Daneshmand S, Keegan KA, Todenhöfer T, Mischinger J, Schubert T, Zaid HB, Hrbacek J, Ali-El-Dein B, *et al*: Impact of perioperative chemotherapy on survival in patients with advanced primary urethral cancer: Results of the international collaboration on primary urethral carcinoma. Ann Oncol 26: 1754-1759, 2015.
18. Kim HS and Seo HK: Immune checkpoint inhibitors for urothelial carcinoma. Investig Clin Urol 59: 285-296, 2018.
19. Miyama Y, Morikawa T, Miyakawa J, Koyama Y, Kawai T, Kume H and Ushiku T: Squamous differentiation is a potential biomarker predicting tumor progression in patients treated with pembrolizumab for urothelial carcinoma. Pathol Res Pract 219: 153364, 2021.
20. Gulmann C, Paner GP, Parakh RS, Hansel DE, Shen SS, Ro JY, Annaiah C, Lopez-Beltran A, Rao P, Arora K, *et al*: Immunohistochemical profile to distinguish urothelial from squamous differentiation in carcinomas of urothelial tract. Hum Pathol 44: 164-172, 2013.
21. Liu Y, Bui MM and Xu B: Urothelial carcinoma with squamous differentiation is associated with high tumor stage and pelvic lymph-node metastasis. Cancer Control 24: 78-82, 2017.
22. Minato A, Noguchi H, Tomisaki I, Fukuda A, Kubo T, Nakayama T and Fujimoto N: Clinical significance of squamous differentiation in urothelial carcinoma of the bladder. Cancer Control 25: 1073274818800269, 2018.
23. Zhang M, Adeniran AJ, Vikram R, Tamboli P, Pettaway C, Bondaruk J, Liu J, Baggerly K and Czerniak B: Carcinoma of the urethra. Hum Pathol 72: 35-44, 2018.
24. Gaisa NT, Braunschweig T, Reimer N, Bornemann J, Eltze E, Siegert S, Toma M, Villa L, Hartmann A and Knuechel R: Different immunohistochemical and ultrastructural phenotypes of squamous differentiation in bladder cancer. Virchows Arch 458: 301-312, 2011.
25. Ko LJ, Yamamoto M, Leonard MW, George KM, Ting P and Engel JD: Murine and human T-lymphocyte GATA-3 factors mediate transcription through a cis-regulatory element within the human T-cell receptor delta gene enhancer. Mol Cell Biol 11: 2778-2784, 1991.
26. Chaux A, Han JS, Lee S, Gonzalez-Roibon N, Sharma R, Burnett AL, Cubilla AL and Netto GJ: Immunohistochemical profile of the penile urethra and differential expression of GATA3 in urothelial versus squamous cell carcinomas of the penile urethra. Hum Pathol 44: 2760-2767, 2013.