Metastatic patterns and treatment options for head and neck cutaneous squamous cell carcinoma (Review)

DORIANA IANCU[1,2], ANA FULGA[1,2], DOINA VESA[1,2], ANDREI ZENOVIA[3], IULIU FULGA[2,4], MIHAELA IONELA SARBU[2] and ALIN LAURENTIU TATU[2,5,6]

[1]Department of Otorhinolaryngology, 'Sfantul Andrei' Emergency Clinical Hospital of Galati, 800578 Galati, Romania; [2]Clinical Department, Faculty of Medicine and Pharmacy, 'Dunarea de Jos' University of Galati, 800010 Galati, Romania; [3]Department of Otorhinolaryngology, 'Cai Ferate' General Hospital, 800223 Galati, Romania; [4]Department of Forensic Medicine, 'Sfantul Andrei' Emergency Clinical Hospital of Galati, 800578 Galati, Romania; [5]Department of Dermatology, 'Sfanta Cuvioasa Parascheva' Clinical Hospital of Infectious Diseases, 800179 Galati, Romania; [6]Multidisciplinary Integrative Center for Dermatologic Interface Research, 800179 Galati, Romania

Received January 19, 2024; Accepted March 14, 2024

DOI: 10.3892/mco.2024.2739

Abstract. According to current predictions, one-fifth of all Americans will develop skin cancer during their lifetime. Cutaneous squamous cell carcinoma (cSCC) most commonly occurs in the head and neck region, which is the area of the body with the highest level of sun exposure. High-risk head and neck cSCC (HNcSCC) is a broad category with numerous high-risk factors that are associated with unfavorable results. In cSCC staging systems, clinical and tumor traits that are likely to result in poor outcomes are identified. Metastasis occurs in ~2.5% of patients with cSCC, most often in the local lymph nodes, and there is some indication that lymph node metastasis has a distinct pattern based on the tumor site. Current findings on tumor molecular targets have suggested the use of systemic treatments, particularly immunotherapy (such as cemiplimab, pembrolizumab and nivolumab), over radiotherapy or chemotherapy for this type of metastasis. However, when used simultaneously with immunotherapy, radiotherapy may be beneficial in the treatment of metastatic HNcSCC by improving the efficacy of immunotherapy. The present review aims to assess the existing literature on metastatic HNcSCC pathways and treatment options, in order to define current and future directions. Notably, there is an urgent need to identify patients who may benefit from local or systemic cancer treatments. The treatment of lymph node metastasis presents a therapeutic challenge and requires comprehensive management.

Correspondence to: Dr Ana Fulga or Dr Iuliu Fulga, Clinical Department, Faculty of Medicine and Pharmacy, 'Dunarea de Jos' University of Galati, 35 Alexandru Ioan Cuza Street, 800010 Galati, Romania
E-mail: ana.fulgaa@gmail.com
E-mail: fulgaiuliu@yahoo.com

Abbreviations: cSCC, cutaneous squamous cell carcinoma; BCC, basal cell carcinoma; SLNB, sentinel lymph node biopsy; HNcSCC, head and neck cSCC; PNI, perineural invasion; MRI, magnetic resonance imaging; CT, computed tomography; CTCs, circulating tumor cells; EGFR, epidermal growth factor receptor; EBRT, external beam radiation therapy; SBRT, stereotactic body radiation therapy; DOI, depth of invasion

Key words: cSCC, HNcSCC, metastasis

Contents

1. Introduction

The two subtypes of cutaneous neoplasms are melanoma and nonmelanoma skin malignancies. Skin malignancies other than melanoma include sarcoma, adnexal tumors, cutaneous squamous cell carcinoma (cSCC), basal cell carcinoma (BCC) and Merkel cell carcinoma (1). cSCC, melanoma and other types of cancer often spread to regional and distant sites, which can markedly affect the clinical course of the disease and patient prognosis (2). BCC normally exhibits localized, slow growth, but rarely metastasizes. The head and neck region, where >50% of newly diagnosed cSCC lesions are located, presents unique challenges in surgical treatment (3). In addition, the chances of survival of patients with cSCC are reduced by localized and/or distant metastases, and the disease is responsible for the death of 2% of patients annually

worldwide. While most nonmelanoma malignancies are BCC (70-80%), cSCC accounts for ~20% of all reported cases (4). As sun exposure is a significant risk factor for cSCC, the ear, cheek, lip and scalp are common sites of occurrence. cSCC is classified into low-risk and high-risk tumors based on prognostic variables, including human papillomavirus infection, smoking and location (specifically the scalp), and patients with high-risk cSCC require more intensive treatment and follow-up. However, these recommendations do not consider the age of the patient at diagnosis, and assume that the tumor features are identical in both adult and elderly individuals (5).

2. Clinicopathological features

Uncontrolled proliferation of atypical keratinocytes, a primary cell type found in the epidermis, is responsible for the development of cSCC (6). A substantial increase in the incidence of cSCC has been reported in the literature. Longitudinal studies conducted in Canada and Australia over the past 30 years have revealed a 50-300% increase in the prevalence of primary cSCC (7). BCC generally experiences gradual confined growth and hardly metastasizes; by contrast, cSCC, melanoma and other types of cancer often spread to both nearby and distant locations, which can have an impact on the clinical course of the disease and the well-being of the patients (8). The early detection of individuals who are more likely to develop metastatic disease would justify the need for surveillance (9). Currently, to the best of our knowledge, there are no indicators of metastasis in cSCC other than conventional histopathological examination. High-risk clinicopathological characteristics of cSCC metastasis include immunosuppression, poor histological differentiation, perineural invasion (PNI), lymphovascular invasion, tumor size >2 cm, depth of invasion >6 mm, and the main location being the scalp, ear or lip (10). Consensus is currently lacking on the definition for high-risk conditions or the ideal cSCC therapy. A previous study reported that 20-40% of head and neck cutaneous neoplasms disseminate to lymph nodes outside of clinically expected levels (11). In locating interval nodes, preoperative lymphoscintigraphy or single photon emission computed tomography is recommended to aid sentinel lymph node biopsy (SLNB) in the head and neck or trunk areas (12). In clinical practice, nodal metastasis of head and neck cSCC (HNcSCC) most often occurs in the parotid glands. The anterior and posterior skin zones are generally categorized according to the drainage pattern in the head and neck area, with a hypothesized lymphatic watershed area between them (13). The occipital, postauricular, cervical level V and supraclavicular fossa are the drainage sites for the posterior part of the head and neck (14), and the parotid and preauricular nodes, as well as the anterior cervical nodes, are the drainage sites of the anterior head and neck areas (15).

3. Metastasis

Nodal metastasis. Tumor staging systems have been devised to predict the risk of nodal metastasis and death. Significant research has been performed to characterize the clinical and histopathological characteristics of the subset of cSCC at a high risk for nodal metastasis (16). In nodal metastasis, both the size and number of lymph nodes involved influence the probability of disease-specific death (17). The identification of a low-risk population and the high cure rates for early nodal disease imply that earlier detection of nodal metastases may simplify the treatment and enhance the outcomes. Furthermore, a state of immunosuppression has been hypothesized to lower the overall survival rate and increase the likelihood of metastasis (18). The value of radiological imaging resides in its ability to detect abnormally sized lymph nodes, most likely as a result of tumor infiltration, in individuals with no clinical evidence of lymphadenopathy (19). Clinically palpable nodes necessitate fine needle aspiration or biopsy to confirm the diagnosis, CT or ultrasound for preoperative staging, and subsequently, regional lymph node dissection. There is increasing evidence that SLNB for cSCC is a promising method to identify microscopic metastases (20). When used for diagnosing head and neck tumors, SLNB is usually safe, with a 5.1% combined risk of hematoma, seroma and infection. Patients with a positive SLN have a significantly higher disease-specific death rate than those with a negative SLN, which suggests that SLNB could be used as a prognostic indicator (21). False positives, which could lead to further excessive procedures, and false negatives, which result from failed attempts to detect micrometastases, are two examples of the limitations of SLNB (22).

In-transit metastases. SCC in-transit metastases are described as tumor foci that have spread from the main tumor to the next local lymph node basin, and typically manifest as subcutaneous or dermal nodules (23). In immunocompromised patients, such as organ transplant recipients, these metastases develop from aggressive original tumors (SCC stage ≥T2). The initial tumor location is often in high-risk areas, such as the scalp, ears or lips, or in areas that are commonly exposed to the sun (24). Diagnostic criteria for in-transit SCC have been proposed, owing to the difficulty in differentiating between diagnoses (25). Metastatic lesions that are distinct from prior surgical scars and situated between the main tumor and draining lymph nodes are included in the clinical criteria (26). Furthermore, the differential diagnosis encompasses local recurrence, perineural dissemination and other metastatic diseases. The following histological requirements should be fulfilled: The primary tumor must not have an epidermal origin, the primary tumor must not have a metastatic component and the metastatic tumor must be distinct from any prior surgical scars (27). A rare occurrence in cSCC is lymphovascular invasion, which refers to a tumor that involves or invades the lymphatics or arteries. Lymphovascular invasion is not considered in staging, despite the fact that it is a predictor of lymph node metastases, and, to the best of our knowledge, no research has thus far shown that it has independent prognostic value (28). Although immunosuppression, such as that seen after organ transplantation, is known to contribute to the development of aggressive SCC, immunocompetent individuals can also acquire in-transit SCC. The prognosis for these patients has been recorded in various ways, and the global disease-specific survival of combined organ transplant recipients and non-organ transplant recipients at 3 years has been reported to be 27-56% and the 5-year overall survival to be 13% (29).

PNI. PNI is the process of malignant invasion of nerves, and is an overlooked path of metastatic dissemination (30). Skin cancers of the head and neck region may penetrate the subarachnoid space of the cerebral cavity via this gap. PNI can be categorized into that discovered by chance during a medical investigation, also known as pathological PNI (pPNI); and that involving a specific nerve, also known as clinical PNI (cPNI) (31). A prior history of pPNI is not always present in patients with cPNI. The trigeminal (V) and facial (VII) cranial nerves are often affected by cPNI, typically proceeding from the skin to the brain in a retrograde manner. Aggressive disease behavior is linked to extratumoral disease, excessive nerve diameter and multifocal PNI. In contrast to BCC, cPNI is more aggressive when it occurs in cSCC (32). According to Jackson *et al*, in a study of 118 patients, 5-year local control rates for pPNI were reported to be 90%, whereas those for cPNI were only 57% (33). Risk factors for PNI in SCC are male sex, tumor size >2 cm, midfacial tumor site, recurring tumor, poorly defined histological subtypes and considerable subclinical expansion. These patients should be queried about any symptoms they may be experiencing, such as tingling, numbness, discomfort, paralysis or formication (34). Any tumor mass close to the main nerve trunk should be detected during the physical examination. Deficits in the trigeminal nerve distribution should be assessed via sensory testing (35). The Schirmer test, taste test and impedance audiometry can be used to determine whether the facial nerve is paralyzed. Notably, ptosis, ophthalmoplegia or visual abnormalities could indicate the involvement of cranial nerves II, III, IV or VI (36). Preoperative imaging investigations are crucial adjunctive tools in the initial assessment of high-risk patients with SCC, in addition to the evaluation of the signs and symptoms of PNI (37). Magnetic resonance imaging (MRI) or CT are the most commonly used methods for radiographic imaging of PNI (38). Based on the presence of nerve enhancement or enlargement, or the absence of the typical fat plane surrounding a nerve, MRI can detect the extent of macroscopic disease (39). Bone erosion caused by tumor invasion of the foramina connected to the cranial nerves can be visualized via CT scanning. Notably, a patient may have positive imaging scans without neurological signs of the illness. The importance of early diagnosis of PNI in SCC cannot be underestimated as appropriate and aggressive therapy must be initiated (40). In general, recommendations for postoperative radiotherapy are based on the mortality linked to PNI (41), as well as concerns about the accuracy of surgical margins (42). Owing to insufficient tumor removal, conventional excision alone may put patients with SCC and PNI at a significant risk for local recurrence (43); therefore, following surgery, radiotherapy is often advised as adjuvant therapy. Notably, to the best of our knowledge, no previous study has separated data into groups based on radiotherapy alone and radiotherapy combined with surgical resection.

Circulating tumor cells (CTCs). CTCs, which are derived from the initial tumor (44), are shed during the lymphatic and/or vascular infiltration process into the bloodstream, causing the spread of cancer (45). These CTCs can be easily detected in peripheral blood, and are often used for the surveillance of breast, lung, colorectal and prostate cancer (46). These cells may exist alone or as microemboli (47). Tumor cells can spread to distant locations after entering the circulatory space, and CTCs make it possible to conduct 'liquid biopsies' and offer 'real-time' monitoring (48). CTC determination can aid in tracking the development or recurrence of the disease in real time, and identify patients for which treatment should be initiated or modified (49). Given that cSCC is the most prevalent type of nonmelanoma skin malignancy with a high risk of metastasis, being able to identify the few patients who develop metastases would have a significant impact on public health, especially in areas with notable sun exposure (50). The identification of CTCs as indicators of metastatic disease can also directly influence therapeutic practice via the early detection of recurrence and the development of specialized treatment procedures for high-risk patients (51). It could be hypothesized that using mesenchymal and novel biomarkers to broaden CTC markers in a positive selection model may enable higher levels of detection and enhance understanding of the metastatic process in cSCC.

4. Immunotherapy

Tumor characteristics and patient considerations influence treatment selection and prognosis (52). Prior to the development of immunotherapy, cytotoxic platinum-based chemotherapy and targeted therapy, which inhibits the epidermal growth factor receptor (EGFR), were the only systemic treatments available for HNcSCC (53). With a 50% response rate, good tolerability and long-lasting disease control, immunotherapy has radically transformed the management of advanced and metastatic cSCC (54). A high level of complete response, as well as lasting, meaningful clinical response, has been seen in patients with advanced cSCC. Numerous clinical trials (such as NCT04154943, NCT03916627, NCT03969004 and NCT03833167) (Table I) examining the use of these novel therapies in clinical settings highlight the need to thoroughly define the epidemiology and morbidity of cSCC to understand how such treatments revolutionize patient outcomes (55). The United States Food and Drug Administration approved cemiplimab in 2018 as the first immunotherapy drug for the treatment of metastatic or locally advanced cSCC unresponsive to curative therapy (56). The reaction of the immune system to cancer cells is considerably regulated by immune checkpoint proteins (57). Two steps are essential for T-cell activation: i) Peptides must be recognized by the T-cell receptor; ii) partner proteins on tumor cells must interact with coregulatory proteins (immune checkpoints) on T cells (58). When activated, immune checkpoints can have either stimulatory or inhibitory effects on the immune system (59). Immune checkpoints facilitate an appropriate immune response while preventing the death of healthy tissues and immune hyperactivation, as seen in autoimmune disorders (60). A compromised immune system promotes mutations; therefore, subsets of cancer cells are able to evade immune detection owing to the compromised antitumor response of the immune system (61). This evasion is referred to as the escape mode, which permits unregulated tumor growth and progression (62). Cemiplimab is a monoclonal antibody that targets PD-1. With a discontinuation rate of just 7% and an adverse event rate comparable to that of other anti-PD-1 medications, cemiplimab is considered

Table I. Trials considering novel therapies for head and neck cSCC.

Trial registration number	Malignancy	Intervention	Primary outcome	(Refs.)
NCT04154943	Stage II-IV cSCC	Intravenous cemiplimab every 21 days	Pathological complete response rate assessed by independent central pathology review	(124)
NCT03916627	Non-small cell lung cancer; hepato-cellular carcinoma; HNSCC	Cemiplimab; platinum doublet; fianlimab	Major treatment effect at time of surgery was the primary endpoint for the HNSCC cohort	(125)
NCT03969004	cSCC	Cemiplimab; placebo	To compare disease-free survival of patients with high-risk cSCC treated with adjuvant cemiplimab vs. those treated with placebo, after surgery and radiation therapy	(126)
NCT03833167	cSCC as the primary site of malignancy	Pembrolizumab (400 mg); placebo	Recurrence-free survival as assessed by the investigator and confirmed by biopsy (time frame: up to ~60 months)	(127)

HNSCC, head and neck squamous cell carcinoma; cSCC, cutaneous squamous cell carcinoma.

to have an acceptable safety profile (63). Pembrolizumab is another immunotherapy agent, which is permitted for use in individuals with locally advanced, metastatic or recurrent HNcSCC who are not candidates for radiation therapy or surgery. This drug is well tolerated and has yielded good results (64). Cutaneous immune-related adverse symptoms, including the rare Stevens-Johnson syndrome/toxic epidermal necrolysis (65), are primarily managed with glucocorticoids; however, the prolonged use of glucocorticoids can lead to various side effects and reduce antitumor activity. Therefore, identifying a safe and efficient approach to manage cutaneous immune-related adverse reactions is critical, including conventional and alternative therapies (66). For example, Feiji Recipe, a Chinese herbal compound, is known to exert anticancer effects by stabilizing the lesions through the modulation of T-cell immunity in patients with lung cancer. The molecular action of this herb is to restore T-cell activity by interfering with indoleamine-2,3-dioxygenase (67).

5. Chemotherapy

Platinum drugs (cisplatin or carboplatin), 5-fluorouracil, bleomycin, doxorubicin, methotrexate and taxanes are examples of the chemotherapeutics explored so far in treating cSCC (49). Platinum agents, either in isolation or in combination, have been the most commonly employed therapeutic approaches. Data on the effectiveness of chemotherapy have generally been obtained only from small observational studies with a confined range of results (68). Poor efficacy, brief duration of the response (non-curative) and increased toxicity are the limitations of chemotherapy, which is a significant treatment challenge for elderly patients or those with several comorbidities (69). Numerous medications, such as cisplatin, target cancer cells by attaching to their DNA; however, once the DNA is broken, cells can use various methods to repair the lesions and stimulate resistance mechanisms (70). Table II summarizes the most frequent chemotherapeutic drugs used to treat cSCC, including their mechanisms, results and potential adverse events. The unique binding site of the drug on the target molecule must be precisely identified to facilitate drug-target interaction. Intrinsic resistance can be caused by the presence of a mutation, low expression or the absence of the drug-metabolizing enzyme-binding site before treatment (71). Moreover, cells may try to repair the harm or reverse the loss by upregulating the production of repair enzymes, reducing cell death, which results in the development of induced resistance with changes in the cell microenvironment (72). In response, there are higher drug release rates and increased capacity for DNA repair of the cells. Hence, with promising results and perspectives, we accept the recommendation that patients who are considered ineligible or exhibit disease progression following immunotherapy should undergo cytotoxic chemotherapy. Fig. 1 illustrates the ongoing cycle of drug resistance within the tumor microenvironment.

6. Radiotherapy

The radiotherapy planning and treatment process is extensive and involves several procedures (73), such as patient consultation and the interpretation of diagnostic imaging (74). Currently, there is no consensus regarding the methods used to treat locally advanced HNcSCC. Based on the limited retrospective studies (75,76) that have thus far been reported, surgical resection is often followed by adjuvant therapy in patients

Table II. Chemotherapy drugs used in cutaneous squamous cell carcinoma.

First author, year	Drug agent	Category	Method	Outcomes	Adverse symptoms	(Refs.)
Rades *et al*, 2023	Cisplatin	Platinum based	DNA crosslink	88.5% response rate	Bone marrow suppression;kidney failure	(128)
Rades *et al*, 2023	Carboplatin	Platinum based	Non-specific cell cycle	83% overall survival rate	Hypoxia and bronchospasm, and anaphylaxis	(128)
Kurosaki *et al*, 2021	Cetuximab	Antibody drug	EGFR inhibitor	49 months overall survival	Interstitial pneumonia; hypomagnesemia	(129)
Chen *et al*, 2023	Pembrolizumab and nivolumab	Anti-PD-1 antibody	PD-1 receptor inhibitor	7.7 months overall survival	Diabetes mellitus; colitis; interstitial pneumonia	(130)

EGFR, epidermal growth factor receptor.

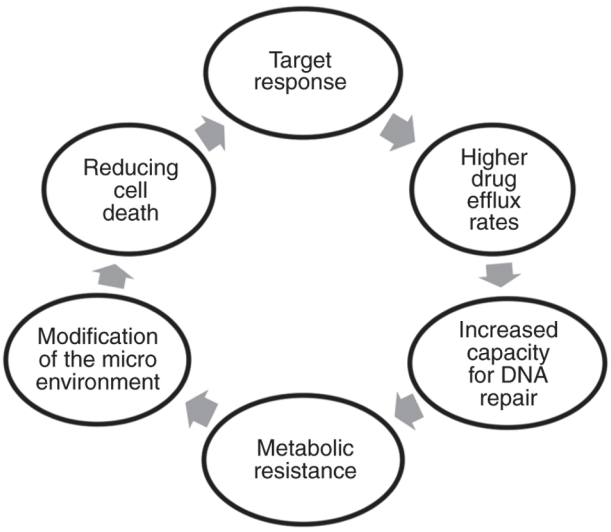

Figure 1. Mechanism underlying induced drug resistance cycle in cancer cells.

with HNcSCC (77). The highest risk of recurrence has been identified in patients with positive margins, substantial PNI or significant nerve involvement (78). To maximize locoregional control, postoperative radiation treatment has long been utilized to treat patients with locally advanced cancer (e.g., T3/T4, lymph node-positive and PNI) (79) and has demonstrated high control rates in various retrospective studies (80-82). With the aid of intensity-modulated radiotherapy, steep dose gradients can be produced even in target volumes with a concave shape by combining irradiation beams with nonuniform fluence intensities. To increase the therapeutic index, the ultimate goal is to precisely administer the radiation dose to the target site, maximizing the tumor dose and limiting the damage to vulnerable nearby organs (83). According to a recent study, the 2-year progression-free survival rates for intermediate-risk patients randomly assigned to receive 50 and 60 Gy adjuvant radiotherapy were 95.0 and 95.9%, respectively (84). This finding supports the use of de-escalated adjuvant therapy for patients who have undergone surgery (85). In general, radiotherapy is reasonably well tolerated. Acute and delayed potential radiotherapy-related toxicities are those that occur within the first 6 months post-treatment and beyond (86). Skin reactions, from redness to ulceration, can be the first sign of acute toxicity (87). Delayed toxicities are more commonly encountered at higher doses and can appear months to years after radiotherapy. Alterations in skin pigmentation, necrosis, atrophy, fibrosis and secondary malignancies are examples of delayed toxicities (Table III) (88).

7. Future therapies

Depth of invasion (DOI) of a tumor, assessed in Breslow thickness or histological depth, has been linked to metastasis (89). Patients with malignancies with a DOI of >2 mm experience a greater relative risk, whereas no metastases have been identified for superficial tumors with DOIs <2 mm (90). In addition, tumor invasion beyond the subcutaneous fat layer has been linked to nodal metastasis (subhazard ratio 7.2) (91). Wermker *et al* established an indicator model based on tumor depth, cartilage invasion, recurrence number and grade, which identified patients with cSCC of the ear who may benefit from neck lymph node dissection. Large tumors are associated with lymph node metastasis and low survival rates. Lymph node metastasis, whether diagnosed at the onset or after therapy, appears to be related to 5-year death rates; lymph node involvement raises the risk of recurrence by 51% and reduces the 3-year overall survival rate to 52% despite second-line therapy (92). Considering all risk factors for metastasis in cSCC is crucial for the earliest detection of patients who require aggressive, multiple forms of therapy.

The use of photoimmunotherapy to treat patients with cSCC is currently being investigated in two trials, NCT05220748 (93) and NCT04305795 (94). An antibody-dye conjugate is injected, which is subsequently activated using a certain wavelength of light. RM-1995 is an antibody that specifically targets CD25, a receptor more often expressed by regulatory T cells than other cell types (95). This treatment method targets regulatory T cells within tumors (96) and becomes activated when exposed to

Table III. Adverse symptoms and overall survival rate from studies of patients with head and neck cutaneous squamous cell carcinoma undergoing fractionated radiotherapy.

First author, year	No. of patients	Radiation dose	Adjuvant therapy	Adverse symptoms	Outcomes	(Refs.)
Nottage *et al*, 2017	21	EBRT, 70 Gy	Yes	Thrombocytopenia, anemia, hearing loss, fibrosis, leukopenia	1-year overall survival rate, 80.2%	(131)
Cowey *et al*, 2019	82	EBRT	Yes	No	Overall survival rates: 1-year, 56.1%; 2-year, 30.2%; 3-year, 15.6%	(132)
Lavaud *et al*, 2019	4	Hypofractionated EBRT, 26 Gy	Yes	No	Disease-free survival, 14.4 months; overall survival, 15.6 months	(133)
Fan *et al*, 2020	166	Hypofractionated EBRT	Yes	Dysphagia, trismus, dermatitis, mucositis	Recurrence rate, 66%; 1-year overall survival rate, 25.3%	(134)
Ogata *et al*, 2020	130	EBRT	Yes	Skin ulcer, anemia, duodenal ulcer, heart failure, febrile neutropenia, erythema multiforme	5-year overall survival rate, 29%	(135)
De Felice *et al*, 2021	18	Ultra-hypofractionated EBRT	No	No	Overall survival rates: 1-year, 66%; 2-year, 26.4%	(136)
Voruganti *et al*, 2021	77	SBRT	No	Dermatitis, mucositis, skin ulceration, fibrosis	Overall survival rates: 1-year, 44%; 2-year, 26%	(137)

EBRT, external beam radiation therapy; SBRT, stereotactic body radiation therapy.

red light, resulting in increased anticancer immune response. RM-1995 is administered both alone and in combination with pembrolizumab. Notably, ASP-1929 is an EGFR antibody that can be triggered by red light, and cemiplimab and ASP-1929 can be administered simultaneously (97). Another trial, NCT04160065, is examining the injection of an intratumoral vaccine that expresses the plasmid DNA IFX-Hu2.0 (98). As a result, a streptococcal membrane protein is expressed within the lesion, which stimulates the immune system and creates an ideal environment for immune checkpoint inhibitor therapy. A total of 20 patients with advanced nonmelanoma skin malignancies are to be enrolled in phase I research (which is currently underway) (99).

Upon being injected into tumors, oncolytic viruses stimulate the human body to evoke both local and systemic anticancer responses (100). Locally, the injected tumor is infected by oncolytic viruses that cause tumor lysis and cell death (101). In addition, oncolytic viruses can exert crucial antineoplastic effects and support the migration of tumor-specific T lymphocytes to uninjected tumor cells (102). Finally, increased interferon-γ signaling results in the overexpression of PD-1 on host T cells and PD-L1 on tumor cells (103), which, when targeted by PD-1 inhibitors exerts a strong antitumor impact (104). RP1 is a genetically altered herpes simplex oncolytic virus (105). According to Liu *et al* (106), patients with HNcSCC and other tumor types experienced a complete remission rate that approached 50% in the phase I/II IGNYTE trial upon the administration of RP1 monotherapy or in combination with nivolumab. The use of RP1 both alone and in combination with cemiplimab in patients with advanced cSCC is currently being studied in a phase II trial, NCT04050436 (107). In addition, RP1 is being assessed in a phase IB/II trial involving solid organ transplant recipients with advanced cutaneous malignancies, including cSCC (108).

8. Discussion

According to previous research, a number of patients with HNcSCC tend to be frail, and such patients are highly likely to experience postoperative challenges (109). Reducing the length and scope of the procedure could decrease the complication rate and adverse long-term effects, as general anesthesia and therapeutic intensity have been shown to be predictors of postoperative complications (110). Although SLNB has been demonstrated to be viable, it has minimal predictive use for this condition (111). The SLN status in relation to the outcomes of HNcSCC has a low predictive value due to various reasons. First, the anatomy of the lymphatic network is complex, and involves bilateral or contralateral drainage in up to 10% of patients (112); therefore, the surgeon must detect SLNs with a high precision (113). Fibrosis from prior tumor surgery and trauma itself can both alter and obstruct the natural lymphatic pathways (114). Several studies have reported that cSCC can perineurally invade the surrounding soft tissues (115,116); this finding suggests that in contrast to, for example, melanoma, the processes of cancer spread depend less on the lymphatic system and have multiple patterns of invasion (117). Often, during surgery for cSCC, a tumor that travels via a cranial nerve to the base of the skull is identified (118), which may be treated via radiotherapy (119). On pretreatment radiographs, a tumor that has spread to the brain via the cranial foramen may often be visible; nevertheless, it is important to highlight that individuals with such tumors are unlikely to be cured and that such tumors are no longer amenable to surgery (120). Aggressive surgery, with or without adjuvant radiotherapy, has been shown to be successful in limiting the degree of tumor involvement (121) and in maximizing disease-free survival in patients with highly advanced cSCC with PNI (122). A pooled average local recurrence rate of 6.4% after radiotherapy was reported in a 2012 meta-analysis of 14 retrospective studies, which amounted to 1,018 primary cSCC cases (123). It may be hypothesized that understanding of the fundamental biology of SCC and BCC represents the future of head and neck cancer treatment standards, with the potential to increase survival rates while limiting local adverse events. Using current options with newer, experimental treatments may not only increase the quality of life for these patients, but also increase their life expectancy. Although immunotherapy has a significant potential in cancer treatment as a single medication, multimodal approaches with more than one focus seem to be more effective.

In conclusion, patients with localized metastatic disease exhibit treatment-elevated morbidity and decreased survival rates. The present study indicated that identifying patients with high-risk disease is vital for providing the best possible care, including access to drug trials. As molecular and genetic biomarkers become more reliable and standardized, it is suggested that they should also be included in patient risk stratification, so that physicians can provide personalized therapies and precision surgery to improve patient outcomes.

Acknowledgements

Not applicable.

Funding

No funding was received.

Availability of data and materials

Not applicable.

Authors' contributions

DI wrote the original draft, and contributed to study conception and analysis of the literature. ALT and IF contributed to supervision, writing, conception, design, analysis of the literature, and reviewed and edited the manuscript. DV, AZ and MIS contributed to collection of the literature, study conception and manuscript editing. Data authentication is not applicable. All authors read and approved the final version of the manuscript.

Ethics approval and consent to participate

Not applicable.

Patient consent for publication

Not applicable.

Competing interests

The authors declare that they have no competing interests.

References

1. Torre LA, Bray F, Siegel RL, Ferlay J, Lortet-Tieulent J and Jemal A: Global cancer statistics, 2012. CA Cancer J Clin 65: 87-108, 2015.
2. Leus AJG, Haisma MS, Terra JB, Diercks GFH, Van Kester MS, Halmos GB, Rácz E, Van Dijk BAC and Plaat BEC: Age-related differences in tumour characteristics and prognostic factors for disease progression in cutaneous squamous cell carcinoma of the head and neck. Acta Derm Venereol 102: adv00652, 2022.
3. Grover P, Flukes S, Jacques A, Leedman S, Lindsay A, White R, Friedland P, Gurfinkel R and Lim AM: Clinicopathological characteristics and clinical morbidity in high-risk head and neck cutaneous squamous cell carcinoma patients in Western Australia. Intern Med J 52: 944-951, 2022.
4. Han AY and John MAS: Predictors of nodal metastasis in cutaneous head and neck cancers. Curr Oncol Rep 24: 1145-1152, 2022.
5. Grammatica A, Tomasoni M, Fior M, Ulaj E, Gualtieri T, Bossi P, Battocchio S, Lombardi D, Deganello A, Mattavelli D, *et al*: Regional disease in head and neck cutaneous squamous cell carcinoma: The role of primary tumor characteristics and number of nodal metastases. Eur Arch Otorhinolaryngol 279: 1573-1584, 2022.
6. Lubov J, Labbé M, Sioufi K, Morand GB, Hier MP, Khanna M, Sultanem K and Mlynarek AM: Prognostic factors of head and neck cutaneous squamous cell carcinoma: A systematic review. J Otolaryngol Head Neck Surg 50: 54, 2021.
7. Fox M, Brown M, Golda N, Goldberg D, Miller C, Pugliano-Mauro M, Schmults C, Shin T, Stasko T, Xu YG, *et al*: Nodal staging of high-risk cutaneous squamous cell carcinoma. J Am Acad Dermatol 81: 548-557, 2019.
8. Arron ST, Wysong A, Hall MA, Bailey CN, Covington KR, Kurley SJ, Goldberg MS, Kasprzak JM, Somani AK, Ibrahim SF, *et al*: Gene expression profiling for metastatic risk in head and neck cutaneous squamous cell carcinoma. Laryngoscope Investig Otolaryngol 7: 135-144, 2022.

9. Hurell MJL, Low TH, Ebranhimi A, Veness M, Ashford B, Porceddu S and Clark JR: Evolution of head and neck cutaneous squamous cell carcinoma nodal staging-an Australian perspective. Cancers (Basel) 14: 5101, 2022.
10. Stewart JR, Ahn JW and Brewer JD: In-transit metastasis of cutaneous squamous cell carcinoma with lymphovascular invasion in an immunocompetent patient. Cureus 14: e21204, 2022.
11. Morosin T, Ashford B, Ranson M, Gupta R, Clark J, Iyer NG and Spring K: Circulating tumour cells in regionally metastatic cutaneous squamous cell carcinoma: A pilot study. Oncotarget 7: 47111-47115, 2016.
12. Nwabudike LC and Tatu AL: Reply to Gambichler T *et al*: Altered epigenetic pathways and cell cycle dysregulation in healthy appearing skin of patients with koebnerized squamous cell carcinomas following skin surgery. J Eur Acad Dermatol Venereol 33: e3-e4, 2019.
13. Janković I, Kovačević P, Janković D, Stevanović G and Momčilović S: Lymphatic drainage map of the head and neck skin squamous cell carcinoma detected by sentinel lymph node biopsy. Eur Rev Med Pharmacol Sci 25: 5228-5234, 2021.
14. Waldman A and Schmults C: Cutaneous squamous cell carcinoma. Hematol Oncol Clin North Am 33: 1-12, 2019.
15. Thiem DGE, Scharr K, Pabst AM, Saka B and Kämmerer PW: Facial cutaneous squamous cell carcinoma-microscopic safety margins and their impact on developing local recurrences. J Craniomaxillofac Surg 48: 49-55, 2020.
16. Hori R, Shinohara S, Kojima T, Kogoshima H, Kitamura M, Tateya I, Tamaki H, Kumabe Y, Asato R, Harada H, *et al*: Real world outcomes and prognostic factors in patients receiving Nivolumab therapy for reccurent or metastatic head and neck carcinoma. Cancers (Basel) 11: 1317, 2019.
17. Wu MP, Sethi RKV and Emerick KS: Sentinel lymph node biopsy for high-risk cutaneous squamous cell carcinoma of the head and neck. Laryngoscope 130: 108-114, 2020.
18. Hughes BGM, Munoz-Couselo E, Mortier L, Bratland Å, Gutzmer R, Roshdy O, González Mendoza R, Schachter J, Arance A, Grange F, *et al*: Pembrolizumab for locally advanced and recurrent/metastatic cutaneous squamous cell carcinoma (KEYNOTE-629 study): An open-label, nonrandomized, multicenter, phase II trial. Ann Oncol 32: 1276-1285, 2021.
19. Baggi A, Quaglino P, Rubatto M, Depenni R, Guida M, Ascierto PA, Trojaniello C, Queirolo P, Saponara M, Peris K, *et al*: Real world data of cemiplimab in locally advanced and metastatic cutaneous squamous cell carcinoma. Eur J Cancer 157: 250-258, 2021.
20. Mei Z, Huang J, Qiao B and Lam AK: Immune checkpoint pathways in immunotherapy for head and neck squamous cell carcinoma. Int J Oral Sci 12: 16, 2020.
21. Constantino A, Canali L, Festa BM, Spriano G, Mercante G and De Virgilio A: Sentinel lymph node biopsy in high-risk cutaneous squamous cell carcinoma of the head and neck: Systematic review and meta-analysis. Head Neck 44: 2288-2300, 2022.
22. Labani-Motlagh A, Ashja-Mahdavi M and Loskog A: The tumor microenvironment: A milieu hindering and obstructing antitumor immune responses. Front Immunol 11: 940, 2020.
23. Chen A, Ali N, Boasberg P and Ho AS: Clinical remission of cutaneous squamous cell carcinoma of the auricle with cetuximab and nivolumab. J Clin Med 7: 10, 2018.
24. Thornton AM, Piccirillo CA and Shevach EM: Activation requirements for the induction of CD4+CD25+ T cell suppressor function. Eur J Immunol 34: 366-76, 2004.
25. Harrell CR, Simovic Markovic B, Fellabaum C, Arsenijevic A, Djonov V and Volarevic V: Molecular mechanisms underlying therapeutic potential of pericytes. J Biomed Sci 25: 21, 2018.
26. Siegel RL, Miller KD and Jemal A: Cancer statistics, 2019. CA Cancer J Clin 69: 7-34, 2019.
27. Coughlin SS and Dean LT: Cancer survivorship care plans, financial toxicity, and financial planning alleviating financial distress among cancer survivors. Support Care Cancer 27: 1969-1971, 2019.
28. Ezzedine K, Painchault C and Brignone M: Use of complete clearance for assessing treatment efficacy for 5-fluorouracil interventions in actinic keratoses: How baseline lesion count can impact this outcome. J Mark Access Health Policy 8: 1829884, 2020.
29. Bortoluzzi P, Brambilla R, Berti E, Marzano AV and Piccinno R: The role of radiotherapy in the management of cutaneous squamous cell carcinoma: A retrospective study on 92 cases. Ital Dermatol Venereol 157: 363-367, 2022.
30. McDowell L and Yom S: Locally advanced non-melanomatous skin cancer: Contemporary radiotherapeutic management. Oral Oncol 99: 104443, 2019.
31. Hazim AZ, Reed CT, Price KA, Foote RL, Ma DJ, Neben-Wittich M, DeLone DR, Jenkins SM, Smith CY and Chintakuntlawar AV: Survival outcomes in locally advanced cutaneous squamous cell carcinoma presenting with clinical perineural invasion alone. Head Neck 43: 1995-2001, 2021.
32. Schachtel MJC, Gandhi M, Bowman JJ, Porceddu SV and Panizza BJ: Facial nerve perineural spread from cutaneous squamous cell carcinoma of the head and neck: A single institution analysis of epidemiology, treatment, survival outcomes, and prognostic factors. Head Neck 44: 1223-1236, 2022.
33. Jackson JE, Dickie GJ, Wiltshire KL, Keller J, Tripcony L, Poulsen MG, Hughes M, Allison RW and Martin JM: Radiotherapy for perineural invasion in cutaneous head and neck carcinomas: Toward a risk-adapted treatment approach. Head Neck 31: 604-610, 2009.
34. Amit M, Liu C, Mansour J, Gleber-Netto FO, Tam S, Baruch EN, Aashiq M, El-Naggar AK, Moreno AC, Rosenthal DI, *et al*: Elective neck dissection versus observation in patients with head and neck cutaneous squamous cell carcinoma. Cancer 127: 4413-4420, 2021.
35. Lin C, Ballah T, Nottage M, Hay K, Chua B, Kenny L, Thomas P, Teng M, Keller J, Le T, *et al*: A prospective study investigating the efficacy and toxicity of definitive ChemoRadiation and ImmunOtherapy (CRIO) in locally and/or regionally advanced unresectable cutaneous squamous cell carcinoma. Radiat Oncol 16: 69, 2021.
36. Dikova V, Jantus-Lewintre E and Bagan J: Potential non-invasive biomarkers for early diagnosis of oral squamous cell carcinoma. J Clin Med 10: 1658, 2021.
37. Villa A, Celentano A, Glurich I, Borgnakke WS, Jensen SB, Peterson DE, Delli K, Ojeda D, Vissink A and Farah CS: World workshop on oral medicine VII: Prognostic biomarkers in oral leukoplakia: A systematic review of longitudinal studies. Oral Dis 25 (Suppl 1): S64-S78, 2019.
38. Assao A, Domingues MAC, Minicucci EM, Marchi FA, Coutinho-Camillo CM and Oliveira DT: The relevance of miRNAs as promising biomarkers in lip cancer. Clin Oral Investig 25: 4591-4598, 2021.
39. Panarese I, Aquino G, Ronchi A, Longo F, Montella M, Cozzolino I, Roccuzzo G, Colella G, Caraglia M and Franco R: Oral and Oropharyngeal squamous cell carcinoma: Prognostic and predictive parameters in the etiopathogenetic route. Expert Rev Anticancer Ther 19: 105-119, 2019.
40. Wilkat M, Bast H, Drees R, Dünser J, Mahr A, Azoitei N, Marienfeld R, Frank F, Brhel M, Ushmorov A, *et al*: Adenosine receptor 2B activity promotes autonomous growth, migration as well as vascularization of head and neck squamous cell carcinoma cells. Int J Cancer 147: 202-217, 2020.
41. Liu SC, Wu YC, Huang CM, Hsieh MS, Huang TY, Huang CS, Hsu TN, Huang MS, Lee WH, Yeh CT and Lin CS: Inhibition of Bruton's tyrosine kinase as a therapeutic strategy for chemoresistant oral squamous cell carcinoma and potential suppression of cancer stemness. Oncogenesis 10: 20, 2021.
42. Alsahafi E, Begg K, Amelio I, Raulf N, Lucarelli P, Sauter T and Tavassoli M: Clinical update on head and neck cancer: Molecular biology and ongoing challenges. Cell Death Dis 10: 540, 2019.
43. Grassilli E, Cerrito MG, Bonomo S, Giovannoni R, Conconi D and Lavitrano M: p65BTK is a novel biomarker and therapeutic target in solid tumors. Front Cell Dev Biol 9: 690365, 2021.
44. Johnson DE, Burtness B, Leemans CR, Lui VWY, Bauman JE and Grandis JR: Head and neck squamous cell carcinoma. Nat Rev Dis Primers 6: 92, 2020.
45. Ngan HL, Liu Y, Fong AY, Poon PHY, Yeung CK, Chan SSM, Lau A, Piao W, Li H, Tse JSW, *et al*: MAPK pathway mutations in head and neck cancer affect immune microenvironments and ErbB3 signaling. Life Sci Alliance 3: e201900545, 2020.
46. Wilbur J: Surveillance of the adult cancer survivor. Am Fam Physician 91: 29-36, 2015.
47. Kriegs M, Clauditz TS, Hoffer K, Bartels J, Buhs S, Gerull H, Zech HB, Bußmann L, Struve N, Rieckmann T, *et al*: Analyzing expression and phosphorylation of the EGF receptor in HNSCC. Sci Rep 9: 13564, 2019.
48. Lee A, Duggan S and Deeks ED: Cemiplimab: A review in advanced cutaneous squamous cell carcinoma. Drugs 80: 813-819, 2020.

49. Ilmonen S, Sollamo E, Juteau S and Koljonen V: Sentinel lymph node biopsy in high-risk cutaneous squamous cell carcinoma of the head and neck. J Plast Reconstr Aesthet Surg 75: 210-216, 2022.
50. Maubec E, Boubaya M, Petrow P, Beylot-Barry M, Basset-Seguin N, Deschamps L, Grob JJ, Dréno B, Scheer-Senyarich I, Bloch-Queyrat C, *et al*: Phase II study of pembrolizumab as first-line, single-drug therapy for patients with unresectable cutaneous squamous cell carcinomas. J Clin Oncol 38: 3051-3061, 2020.
51. Luk PP, Ebrahimi A, Veness MJ, McDowell L, Magarey M, Gao K, Palme CE, Clark JR and Gupta R: Prognostic value of the 8th edition American joint commission cancer nodal staging system for patients with head and neck cutaneous squamous cell carcinoma: A multi-institutional study. Head Neck 43: 558-567, 2021.
52. Schmidt C, Martin JM, Khoo E, Plank A and Grigg R: Outcomes of nodal metastatic cutaneous squamous cell carcinoma of the head and neck treated in a regional center. Head Neck 37: 1808-1815, 2015.
53. Hahlweg P, Hoffmann J, Härter M, Frosch DL, Elwyn G and Scholl I: In absentia: An exploratory study of how patients are considered in multidisciplinary cancer team meetings. PLoS One 10: e0139921, 2015.
54. Robinson TE, Janssen A, Harnett P, Museth KE, Provan PJ, Hills DJ and Shaw T: Embedding continuous quality improvement processes in multidisciplinary teams in cancer care: Exploring the boundaries between quality and implementation science. Aust Health Rev 41: 291-296, 2017.
55. Hoesseini A, Dronkers EAC, Sewnaik A, Hardillo JAU, Baatenburg de Jong RJ and Offerman MPJ: Head and neck cancer patients' preferences for individualized prognostic information: A focus group study. BMC Cancer 20: 399, 2020.
56. Szturz P and Vermorken JB: Management of recurrent and metastatic oral cavity cancer: Raising the bar a step higher. Oral Oncol 101: 104492, 2020.
57. Bruni D, Angell HK and Galon J: The immune contexture and Immunoscore in cancer prognosis and therapeutic efficacy. Nat Rev Cancer 20: 662-680, 2020.
58. Ziemann F, Arenz A, Preising S, Wittekindt C, Klussmann JP, Engenhart-Cabillic R and Wittig A: Increased sensitivity of HPV-positive head and neck cancer cell lines to x-irradiation ± cisplatin due to decreased expression of E6 and E7 oncoproteins and enhanced apoptosis. Am J Cancer Res 5: 1017-1031, 2015.
59. Chen YP, Wang YQ, Lv JW, Li YQ, Chua MLK, Le QT, Lee N, Colevas AD, Seiwert T, Hayes DN, *et al*: Identification and validation of novel microenvironment-based immune molecular subgroups of head and neck squamous cell carcinoma: Implications for immunotherapy. Ann Oncol 31: 316-318, 2018.
60. Ji H and Zhou Z: A 'Hybrid' radiotherapy regimen designed for immunomodulation: Combining high-dose radiotherapy with low-dose radiotherapy. Cancers (Basel) 14: 3505, 2022.
61. Patil VM, Singh GK, Noronha V, Joshi A, Menon N, Lashkar SG, Mathrudev V, Satam KN, Mukadam SA and Prabhash K: Lymphopenia during chemoradiation-Foe or friend. Ecancermedicalscience 14: 1109, 2020.
62. Köcher S, Zech HB, Krug L, Gatzemeier F, Christiansen S, Meyer F, Rietow R, Struve N, Mansour WY, Kriegs M, *et al*: A lack of effectiveness in the ATM-orchestrated DNA damage response contributes to the DNA repair defect of hpv-positive head and neck cancer cells. Front Oncol 12: 765968, 2022.
63. Brancaccio G, Briatico G, Pellegrini C, Rocco T, Moscarella E and Fargnoli MC: Risk factors and diagnosis of advanced cutaneous squamous cell carcinoma. Dermatol Pract Concept 11 (Suppl 2): e2021166S, 2021.
64. Skulsky SL, O'Sullivan B, McArdle O, Leader M, Roche M, Conlon PJ and O'Neill JP: Review of high-risk features of cutaneous squamous cell carcinoma and discrepancies between the American joint committee on cancer and NCCN clinical practice guidelines in oncology. Head Neck 39: 578-594, 2017.
65. Chen SY, Chen QW, Shou LM, Pan H, Ruan SM, Liang ZH and Shu QJ: Stevens-Johnson syndrome/toxic epidermal necrolysis successfully treated with Chinese herbal medicine Pi-Yan-Ning: A case report. J Integr Med 19: 555-560, 2021.
66. Liu Y, Tang J, Yu LY and Jiang Q: Successful treatment of immune-related lichenoid dermatitis by Weiling decoction in a patient with non-small cell lung cancer: A case report and review of literature. Explore (NY) 19: 730-735, 2023.
67. Luo B, Que ZJ, Zhou ZY, Wang Q, Dong CS, Jiang Y, Hu B, Shi H, Jin Y, Liu JW, *et al*: Feiji Recipe inhibits the growth of lung cancer by modulating T-cell immunity through indoleamine-2,3-dioxygenase pathway in an orthotopic implantation model. J Integr Med 16: 283-289, 2018.
68. Flezar MS, Prevodnik VK, Kirbis IS and Strojan P: Cutaneous squamous cell carcinoma metastatic to chronic lymphocytic leukaemia: Diagnostic potential of fine needle aspiration cytology. Cytopathology 17: 288-294, 2006.
69. Künzel J, Brandenstein M, Zeman F, Symeou L, Platz Batista da Silva N and Jung EM: Multiparametric ultrasound of cervical lymph node metastases in head and neck cancer for planning non-surgical therapy. Diagnostics (Basel) 12: 1842, 2022.
70. Rossi SH, Prezzi D, Kelly-Morland C and Goh V: Imaging for the diagnosis and response assessment of renal tumours. World J Urol 36: 1927-1942, 2018.
71. Machiels JP, Rene Leemans C, Golusinski W, Grau C, Licitra L and Gregoire V; EHNS Executive Board. Electronic address: secretariat@ehns.org, ESMO Guidelines Committee. Electronic address: clinicalguidelines@esmo.org, ESTRO Executive Board. Electronic address: info@estro.org: Squamous cell carcinoma of the oral cavity, larynx, oropharynx and hypopharynx: EHNS-ESMO-ESTRO clinical practice guidelines for diagnosis, treatment and follow-up. Ann Oncol 31: 1462-1475, 2020.
72. Vos JL, Elbers JBW, Krijgsman O, Traets JJH, Qiao X, van der Leun AM, Lubeck Y, Seignette IM, Smit LA, Willems SM, *et al*: Neoadjuvant immunotherapy with nivolumab and ipilimumab induces major pathological responses in patients with head and neck squamous cell carcinoma. Nat Commun 12: 7348, 2021.
73. Khadela A, Shah Y, Mistry P, Bodiwala K and Cb A: Immunomodulatory therapy in head and neck squamous cell carcinoma: Recent advances and clinical prospects. Technol Cancer Res Treat 22: 15330338221150559, 2023.
74. Petit C, Lacas B, Pignon JP, Le QT, Grégoiere V, Grau C, Hackshaw A, Zackrisson B, Parmar MKB, Lee JW, *et al*: Chemotherapy and radiotherapy in locally advanced head and neck cancer: An individual patient data network meta-analysis. Lancet Oncol 22: 727-736, 2021.
75. Newman JG, Hall MA, Kurley SJ, Cook RW, Farberg AS, Geiger JL and Koyfman SA: Adjuvant therapy for high-risk cutaneous squamous cell carcinoma: 10-Year review. Head Neck 43: 2822-2843, 2021.
76. Svajdova M, Dubinsky P and Kazda T: Radical external beam re-irradiation in the treatment of recurrent head and neck cancer: Critical review. Head Neck 43: 354-366, 2021.
77. Uppaluri R, Campbell KM, Egloff AM, Zolkind P, Skidmore ZL, Nussenbaum B, Paniello RC, Rich JT, Jackson R, Pipkorn P, *et al*: Neoadjuvant and adjuvant pembrolizumab in resectable locally advanced, human papillomavirus-unrelated head and neck cancer: A multicenter, phase II trial. Clin Cancer Res 26: 5140-5152, 2020.
78. Ng SP, Pollard C III, Kamal M, Ayoub Z, Garden AS, Bahig H, Gunn GB, Frank SJ, Skinner HD, Phan J, *et al*: Risk of second primary malignancies in head and neck cancer patients treated with definitive radiotherapy. NPJ Precis Oncol 3: 22, 2019.
79. Lideståhl A, Johansson G, Siegbahn A and Lind PA: Estimated risk of radiation-induced cancer after thymoma treatments with proton- or X-ray beams. Cancers (Basel) 13: 5153, 2021.
80. Ordoñez R, Otero A, Jerez I, Medina JA, Lupiañez-Pérez Y and Gomez-Millan J: Role of radiotherapy in the treatment of metastatic head and neck cancer. Onco Targets Ther 12: 677-683, 2019.
81. Zhang S, Zeng N, Yang J, He J, Zhu F, Liao W, Xiong M and Li Y: Advancements of radiotherapy for recurrent head and neck cancer in modern era. Radiat Oncol 18: 166, 2023.
82. Runnels J, Bloom JR, Hsieh K, Dickstein DR, Shi Y, Jones BM, Lehrer EJ and Bakst RL: Combining radiotherapy and immunotherapy in head and neck cancer. Biomedicines 11: 2097, 2023.
83. Fang LC, Lemos B, Douglas J, Iyer J and Nghiem P: Radiation monotherapy as regional treatment for lymph node-positive Merkel cell carcinoma. Cancer 116: 1783-1790, 2010.
84. Wahlberg P, Anderson H, Biörklund A, Möller T and Perfekt R: Carcinoma of the parotid and submandibular glands-a study of survival in 2465 patients. Oral Oncol 38: 706-713, 2002.
85. Reichelmann H, Dejaco D, Steinbichler TB, Lettenbich-Haug A, Anegg M, Ganswindt U, Gamerith G and Riedl D: Functional outcomes in head and neck cancer patients. Cancers (Basel) 14: 2135, 2022.

86. Henry M, Harvey R, Chen LM, Meaney M, Nguyen TTT, Kao HT, Rosberger Z, Frenkiel S, Hier M, Zeitouni A, *et al*: Genetic predisposition to depression and inflammation impacts symptom burden and survival in patients with head and neck cancer: A longitudinal study. J Affect Disord 331: 149-157, 2023.
87. Ch'ng S, Low I, Ng D, Brasch H, Sullivan M, Davis P and Tan ST: Epidermal growth factor receptor: A novel biomarker for aggressive head and neck cutaneous squamous cell carcinoma. Hum Pathol 39: 344-349, 2008.
88. Bachar G, Mizrachi A, Rabinovics N, Guttman D, Shpitzer T, Ad-El D and Hadar T: Prognostic factors in metastatic cutaneous squamous cell carcinoma of the head and neck. Ear Nose Throat J 95: E32-E36, 2016.
89. Sood A, Wykes J, Roshan D, Wang LY, McGuinness J, Fowler A and Ebrahimi A: A critical analysis of the prognostic performance of the 8th edition American joint committee on cancer staging for metastatic cutaneous squamous cell carcinoma of the head and neck. Head Neck 41: 1591-1596, 2019.
90. Bossi P, Alfieri S, Strojan P, Takes RP, López F, Mäkitie A, Saba NF, Rodrigo JP, Bradford C, Suarez C, *et al*: Prognostic and predictive factors in recurrent and/or metastatic head and neck squamous cell carcinoma: A review of the literature. Crit Rev Oncol Hematol 137: 84-91, 2019.
91. Thomson AK, Kelley BF, Prokop LJ, Murad MH and Baum CL: Risk factors for cutaneous squamous cell carcinoma recurrence, metastasis, and disease-specific death: A systematic review and meta-analysis. JAMA Dermatol 152: 419-428, 2016.
92. Wermker K, Kluwig J, Schipmann S, Klein M, Schulze HJ and Hallermann C: Prediction score for lymph node metastasis from cutaneous squamous cell carcinoma of the external ear. Eur J Surg Oncol 41: 128-135, 2015.
93. National Library of Medicine: RM-1995 Photoimmunotherapy, as monotherapy or combined with pembrolizumab, in patients with advanced CuSCC and HNSCC. ClinicalTrials.gov ID: NCT05220748. https://clinicaltrials.gov/study/NCT05220748. Accessed April 19, 2023.
94. An open-label study using ASP-1929 photoimmunotherapy in combination with anti-PD1 therapy in EGRF expressing advanced solid tumors, 2024. https://www.clinicaltrials.gov/study/NCT04305795.
95. Volovat SR, Ursulescu CL, Moisii LG, Volovat C, Boboc D, Scripcariu D, Amurariti F, Stefanescu C, Stolniceanu CR, Agop M, *et al*: The landscape of nanovectors for modulation in cancer immunotherapy. Pharmaceutics 14: 397, 2022.
96. Economopoulou P, de Bree R, Kotsantis I and Psyrri A: Diagnostic tumor markers in head and neck squamous cell carcinoma (HNSCC) in the clinical setting. Front Oncol 9: 827, 2019.
97. Rolih V, Barutello G, Iussich S, De Maria R, Quaglino E, Buracco P, Cavallo F and Riccardo F: CSPG4: A prototype oncoantigen for translational immunotherapy studies. J Transl Med 15: 151, 2017.
98. Green A and Olsen C: Cutaneous squamous cell carcinoma. An epidemiological review. Br J Dermatol 177: 373-381, 2017.
99. Warta R, Herold-Mende C, Chaisaingmongkol J, Popanda O, Mock A, Mogler C, Osswald F, Herpel E, Küstner S, Eckstein V, *et al*: Reduced promoter methylation and increased expression of CSPG4 negatively influences survival of HNSCC patients. Int J Cancer 135: 2727-2734, 2014.
100. Goldie SJ, Cottle DL, Tan FH, Roslan S, Srivastava S, Brady R, Partridge DD, Auden A, Smyth IM, Jane SM, *et al*: Loss of GRHL3 leads to TARC/CCL17-mediated keratinocyte proliferation in the epidermis. Cell Death Dis 9: 1072, 2018.
101. Chahal HS, Lin Y, Ransohoff KJ, Hinds DA, Wu W, Dai HJ, Qureshi AA, Li WQ, Kraft P, Tang JY, *et al*: Genome-wide association study identifies novel susceptibility loci for cutaneous squamous cell carcinoma. Nat Commun 7: 12048, 2016.
102. Sánchez-Danés A, Hannezo E, Larsimont JC, Liagre M, Youssef KK, Simons BD and Blanpain C: Defining the clonal dynamics leading to mouse skin tumour initiation. Nature 536: 298-303, 2016.
103. Darido C, Georgy SR, Cullinane C, Patridge DD, Walker R, Srivastava S, Roslan S, Carpinelli MR, Dworkin S, Pearson RB and Jane SM: Stage-dependent therapeutic efficacy in PI3K/mTOR-driven squamous cell carcinoma of the skin. Cell Death Differ 25: 1146-1159, 2018.
104. Majumdar M, Vouri K and Stallcup WB: Engagement of the NG2 proteoglycan triggers cell spreading via rac and p130cas. Cell Signal 15: 79-84, 2003.
105. Sardone F, Santi S, Tagliavini F, Traina F, Merlini L, Squarzoni S, Cescon M, Wagener R, Maraldi NM, Bonaldo P, *et al*: Collagen VI-NG2 axis in human tendon fibroblasts under conditions mimicking injury response. Matrix Biol 55: 90-105, 2016.
106. Liu N, Matsumura H, Kato T, Ichinose S, Takada A, Namiki T, Asakawa K, Morinaga H, Mohri Y, De Arcangelis A, *et al*: Stem cell competition orchestrates skin homeostasis and ageing. Nature 568: 344-350, 2019.
107. Nishihara T, Remacle AG, Angert M, Shubayev I, Shyryaev SA, Liu H, Dolkas J, Chernov AV, Strongin AY and Shubayev VI: Matrix metalloproteinase-14 both sheds cell surface neuronal glial antigen 2 (NG2) proteoglycan on macrophages and governs the response to peripheral nerve injury. J Biol Chem 290: 3693-3707, 2015.
108. Beckham TH, Leeman JE, Xie P, Li X, Goldman DA, Zhang Z, Sherman E, McBride S, Riaz N, Lee N and Tsai CJ: Long-term survival in patients with metastatic head and neck squamous cell carcinoma treated with metastasis-directed therapy. Br J Cancer 121: 897-903, 2019.
109. Lenouvel D, González-Moles MÁ, Talbaoui A, Ramos-García P, González-Ruiz L, Ruiz-Ávila I and Gil-Montoya JA: An update of knowledge on PD-L1 in head and neck cancers: Physiologic, prognostic and therapeutic perspectives. Oral Dis 26: 511-526, 2020.
110. Chen HM, Wang L and Zhou SB: Recent progress in shape memory polymers for biomedical applications. Chin J Polym Sci 36: 905-917, 2018.
111. Bakst RL, Glastonbury CM, Parvathaneni U, Katabi N, Hu KS and Yom SS: Perineural invasion and perineural tumor spread in head and neck cancer. Int J Radiat Oncol Biol Phys 103: 1109-1124, 2019.
112. Das R, Langou S, Le TT, Prasad P, Lin F and Nguyen TD: Electrical stimulation for immune modulation in cancer treatments. Front Bioeng Biotechnol 9: 795300, 2022.
113. Campana LG, Miklavčič D, Bertino G, Marconato R, Valpione S, Imarisio I, Dieci MV, Granziera E, Cemazar M, Alaibac M and Sersa G: Electrochemotherapy of superficial tumors-current status: Basic principles, operating procedures, shared indicators, and emerging applications. Semin Oncol 46: 173-191, 2019.
114. Plaschke CC, Gehl L, Johannesen HH, Fishcher BM, Kjaer A, Lomholt AF and Wessel I: Calcium electroporation for recurrent head and neck cancer: A clinical phase I study. Laryngoscope Investig Otolaryngol 4: 49-56, 2019.
115. Caracciolo G: Clinically approved liposomal nanomedicines: Lessons learned from the biomolecular corona. Nanoscale 10: 4167-4172, 2018.
116. Ahmad S, Idris RAM, Hanaffi WNW, Perumal K, Boer JC, Plebanski M, Jaafar J, Lim JK and Mohamud R: Cancer nanomedicine and immune system-interactions and challenges. Front Nanotechnol 3: 681305, 2021.
117. Ochoa MC, Minute L, Rodriguez I, Garasa S, Perez-Ruiz E, Inogés S, Melero I and Berraondo P: Antibody-dependent cell cytotoxicity: Immunotherapy strategies enhancing effector NK cells. Immunol Cell Biol 95: 347-355, 2017.
118. Niculet E, Bobeica C, Onisor C, Gurau G, Nechita A, Radaschin DS, Tutunaru D, Bujoreanu-Bezman L and Tatu AL: Basal cell carcinoma perineural invasion and suggestive signs of perineural invasion-findings and perspectives. Life (Basel) 13: 1406, 2023.
119. Rehmani HS and Issaeva N: EGFR in head and neck squamous cell carcinoma: Exploring possibilities of novel drug combinations. Ann Transl Med 8: 813, 2020.
120. Wise-draper TM, Bahig H, Tonneau M, Karived V and Burtness B: Current therapy for metastatic head and neck cancer: Evidence, opportunities, and challenges. Am Soc Clin Oncol Educ Book 42: 1-14, 2022.
121. Hepp MV, Eigentler TK, Kähler KC, Herbst RA, Göppner D, Gambichler T, Ulrich J, Dippel E, Loquai C, Schell B, *et al*: Immune checkpoint blockade with concurrent electrochemotherapy in advanced melanoma: A retrospective multicenter analysis. Cancer Immunol Immunother 65: 951-959, 2016.
122. Caramazza L, Nardoni M, De Angelis A, Paolicelli P, Liberti M, Apollonio F and Petralito S: Proof-of-concept of electrical activation of liposome nanocarries: From dry to wet experiments. Front Bioeng Biotechnol 8: 819, 2020.
123. Parmar K, Mohamed A, Vaish E, Thawani R, Cetnar J and Thein KZ: Immunotherapy in head and neck squamous cell carcinoma: An updated review. Cancer Treat Res Commun 33: 100649, 2022.
124. Study of Cemiplimab in patients with type of skin cancer stage II to IV cutaneous squamous cell carcinoma, 2023. https://www.clinicaltrials.gov./study/NCT04154943.

125. National Library of Medicine: Neoadjuvant Cemiplimab for the treatment of resectable NSCLC, HCC, and HNSCC in adult patients. ClinicalTrials.gov ID: NCT03916627. https://clinicaltrials.gov/study/NCT03916627. Accessed May 31, 2023.
126. National Library of Medicine: Study of adjuvant Cemiplimab versus placebo after surgery and radiation therapy in patients with high risk cutaneous squamous cell carcinoma. ClinicalTrials.gov ID: NCT03969004. https://clinicaltrials.gov/study/NCT03969004. Accessed May 31, 2019.
127. National Library of Medicine: Pembrolizumab (MK3475) versus placebo following surgery and radiation in participants with locally advanced cutaneous squamous cell carcinoma (MK-3475-630/KEYNOTE-630). ClinicalTrials.gov ID: NCT03833167. https://clinicaltrials.gov/study/NCT03833167. Accessed Febryary 6, 2019
128. Rades D, Zwaan I, Soror T, Idel C, Pries R, Bruchhage KL, Hakim SG and Yu NY: Chemoradiation with cisplatin vs carboplatin for squamous cell carcinoma of the head and neck (SCCHN). Cancers (Basel) 15: 3278, 2023.
129. Kurosaki T, Mitani S, Tanaka K, Suzuki S, Kanemura H, Haratani K, Fumita S, Iwasa T, Hayashi H, Yoshida T, *et al*: Safety and efficacy of cetuximab-containing chemotherapy after immune checkpoint inhibitors for patients with squamous cell carcinoma of the head and neck: # single-center retrospective study. Anticancer Drugs 32: 95-101, 2021.
130. Chen YH, Tsai CH, Chen YY, Wang JH, Hung CH and Kuo YH: Real-world comparison of pembrolizumab and nivolumab in advanced hepatocellular carcinoma. BMC Cancer 23: 810, 2023.
131. Nottage MK, Lin C, Hughes BGM, Kenny L, Smith DD, Houston K and Francesconi A: Prospective study of definitive chemoradiation in locally or regionally advanced squamous cell carcinoma of the skin. Head Neck 39: 679-683, 2017.
132. Cowey CL, Robert NJ, Espirito JL, Davis K, Frytak J, Lowy I and Fury MG: Clinical outcomes among unresectable, locally advanced, and metastatic cutaneous squamous cell carcinoma patients treated with systemic therapy. Cancer Med 9: 7381-7387, 2020.
133. Lavaud J, Blom A, Longvert C, Magali F, Funck-Brentano E and Saiag P: Pembrolizumab and concurrent hypo-fractionated radiotherapy for advanced non-resectable cutaneous squamous cell carcinoma. Eur J Dermatol 29: 636-640, 2019.
134. Fan M, Kang JJ, Lee A, Fan D, Wang H, Kitpanit S, Fox P, Sine K, Mah D, McBride S, *et al*: Outcomes and toxicities of definitive radiotherapy and reirradiation using 3-dimensional conformal or intensity-modulated (pencil beam) proton therapy for patients with nasal cavity and paranasal sinus malignancies. Cancer 126: 1905-1916, 2020.
135. Ogata D, Namikawa K, Otsuka M, Asai J, Kato H, Yasuda M, Maekawa T, Fujimura T, Kato J, Takenouchi T, *et al*: Systemic treatment of patients with advanced cutaneous squamous cell carcinoma: Response rates and outcomes of the regimes used. Eur J Cancer 127: 108-117, 2020.
136. De Felice F, Musio D, De Falco D, Grapulin L, Magnante AL, Caiazzo R, Bulzonetti N, and Tombolini V: Definitive weekly hypofractionated radiotherapy in cutaneous squamous cell carcinoma: Response rates and outcomes in elderly patients unfit for surgery. Int J Dermatol 61: 911-915, 2022.
137. Voruganti IS, Poon I, Husain ZA, Bayley A, Barnes EA, Zhang L, Chin L, Erler D, Higgins K, Enepekides D, *et al*: Stereotactic body radiotherapy for head and neck skin cancer. Radiother Oncol 165: 1-7, 2021.