SPANDIDOS PUBLICATIONS

MOLECULAR MEDICINE REPORTS 14: 3676-3682, 2016

Expressing human *SHOX* in *Shox2*$^{\text{SHOX KI/KI}}$ mice leads to congenital osteoarthritis-like disease of the temporomandibular joint in postnatal mice

WENNA LIANG[1*], XIHAI LI[2*], HOUHUANG CHEN[2], XIANG SHAO[2], XUEJUAN LIN[1], JIANYING SHEN[1,3], SHANSHAN DING[1,3], JIE KANG[1,3] and CANDONG LI[1]

[1]Research Base of Traditional Chinese Medicine Syndrome; [2]Academy of Integrative Medicine; [3]Fujian Key Laboratory of Traditional Chinese Medicine Health State, Fujian University of Traditional Chinese Medicine, Fuzhou, Fujian 350122, P.R. China

Received September 2, 2015; Accepted August 2, 2016

DOI: 10.3892/mmr.2016.5715

Abstract. The temporomandibular joint (TMJ), a unique synovial joint whose development differs from that of other synovial joints, develops from two distinct mesenchymal condensations that grow toward each other and ossify through different mechanisms. The short stature homeobox 2 (*Shox2)* gene serves an important role in TMJ development and previous studies have demonstrated that *Shox2*$^{\text{SHOX KI/KI}}$ mice display a TMJ defective phenotype, congenital dysplasia and premature eroding of the articular disc, which is clinically defined as a TMJ disorder. In the present study, *Shox2*$^{\text{SHOX KI/KI}}$ mouse models were used to investigate the mechanisms of congenital osteoarthritis (OA)-like disease during postnatal TMJ growth. *Shox2*$^{\text{SHOX KI/KI}}$ mice were observed to develop a severe muscle wasting syndrome from day 7 postnatal. Histological examination indicated that the condyle and glenoid fossa of *Shox2*$^{\text{SHOX KI/KI}}$ mice was reduced in size in the second week after birth. The condyles of *Shox2*$^{\text{SHOX KI/KI}}$ mice exhibited reduced expression levels of collagen type II and Indian hedgehog, and increased expression of collagen type I. A marked increase in matrix metalloproteinase 9 (MMP9) and MMP13 in the condyles was also observed. These cellular and molecular defects may contribute to the observed (OA)-like phenotype of *Shox2*$^{\text{SHOX KI/KI}}$ mouse TMJs.

Correspondence to: Professor Candong Li, Research Base of Traditional Chinese Medicine Syndrome, Fujian University of Traditional Chinese Medicine, 1 Qiuyang Road, Shangjie Minhou University Town, Fuzhou, Fujian 350122, P.R. China
E-mail: fjzylcd@126.com

[*]Contributed equally

Key words: temporomandibular joint, extracellular matrix, matrix metalloproteinases, hedgehog signaling

Introduction

The temporomandibular joint (TMJ) is a complex structure that consists of the condyle, fibrocartilaginous disc and glenoid fossa, which is essential for jaw movement and is only found in mammals (1,2). Osteoarthritis (OA) is a TMJ disorder that affects 8-16% of the human population, and can lead to chewing difficulties and chronic myofacial pains (3). Degradation of the condyle cartilage is one of the main factors that lead to TMJ OA (4). Condyle structure and function are affected extracellular matrix (ECM) components, including collagens, glycosaminoglycans (GAGs) and proteoglycans (PGS) (5,6). Investigation of the alterations that may occur in condyle composition is important for understanding the basis of the pathological process of TMJ OA (7).

The ECM components, which are critical for resistance to compressive forces and for maintaining tensile properties, are altered in several cartilage-related pathologies and at different stages of the same pathological process (8). Additionally, cartilage degradation results from an imbalance between anabolic and catabolic cytokine signaling pathways, which can lead to an increase in matrix-degrading proteases and a decrease in matrix synthesis (9,10). These alterations are characterized by the significant upregulation of matrix metalloproteinases (MMPs), which are responsible for the significant degradation of cartilage ECM proteins (11). MMPs function to cleave aggrecan and collagens, the two most abundant ECM components of skeletal tissue (12). MMP9, an MMP subtype implicated in the degradation of cartilage ECM proteins, has been observed to play a central role in connective tissue remodeling and basement membrane turnover (2,5). MMP13, a member of the MMP family of neutral endopeptidases, is highly overexpressed in chondrocytes and synovial cells during OA (13,14).

The short stature homeobox 2 (*Shox2)* gene is important for the development of all long bones that undergoes endochondral ossification (15,16). A previous study has demonstrated that mice expressing human *SHOX* (*Shox2*$^{\text{SHOX KI/KI}}$ mice) do not exhibit TMJ dysplasia and ankylosis at birth, but display a postnatal, prematurely eroded articular disc (2). This suggests

that, although human *SHOX* can exert similar functions to mouse *Shox2* in the regulation of early TMJ development, the human gene has a distinct function in regulating TMJ growth in postnatal mice (2). Therefore, the cellular and molecular alterations that contribute to the congenital OA-like disease of the TMJ in *Shox2*$^{SHOX\ KI/KI}$ mice were investigated in the present study.

Materials and methods

Mouse details. Animal procedures used in the present study were approved by the Institutional Animal Care and Use Committee of the Fujian University of Traditional Chinese Medicine (Fuzhou, China). The generation of *Shox2*$^{SHOX\ KI/KI}$ mice from the lab of Dr Yiping Chen (Department of Cell and Molecular Biology, Tulane University, New Orleans, LA, USA) was conducted as described previously (2,17). A total of 96 mice (48 male and 48 female; 5/cage) were bred on a C57BL/6 J background (42 wild-type *Shox2*$^{+/+}$ mice, 12 *Shox2*$^{SHOX\ KI/+}$ mice and 42 *Shox2*$^{SHOX\ KI/KI}$ mice). All mice were exposed to a 12-h light/dark cycle, in a temperature (22±1˚C) and humidity (56±5%)-controlled environment and maintained on a 0.3% sodium diet. Mice were sacrificed using carbon dioxide (CO_2) and the heads from postnatal day 0 (P0), P7, P14 and P21 mice were fixed and decalcified in Surgipath's Decalcifier I® (Leica Biosystems GmbH, Wetzlar, Germany) for a variable time-period (2-7 days) that was dependent on the age of the mice (2,5).

Histological analyses. A total of 36 mouse heads were dehydrated using a graded ethanol series, cleared with xylene (Sigma-Aldrich, St. Louis, MO, USA), paraffin-embedded and sectioned at 10 μm using a microtome. Histological analysis of TMJ sections was performed as previously described using standard hematoxylin-eosin (HE) staining (18), Safranin O-Fast Green staining (19) and azon red/anilin blue (Sigma-Aldrich) staining (2,16).

Bone staining. A total of 6 P21 wild-type *Shox2*$^{+/+}$ and *Shox2*$^{SHOX\ KI/KI}$ mice were fixed in 90% ethanol for a minimum of 1 week. Prior to fixation, the skins, adipose tissues, eyeballs and thoracoabdominal organs were removed. Specimens were placed in 85% ethanol containing 1.5% potassium hydroxide (KOH) and 1% Alizarin Red S (Sigma-Aldrich) for 7 days. The specimens were macerated in 1% aqueous KOH and cleared in a 50% glycerin solution.

Immunohistochemical analyses. A total of 54 mouse heads were dehydrated using a graded ethanol series, cleared with xylene, paraffin-embedded and sectioned at 8 μm for immunohistochemical analysis. Immunohistochemical staining was performed as previously described (2). Paraffin sections were de-paraffinized and rehydrated in a series of alcohol dilutions, incubated for 20 min at 100˚C in 10 mM sodium citrate buffer (pH 6.0) for antigen retrieval and then cooled to room temperature. Sections were blocked using goat serum (1:10, Invitrogen; Thermo Fisher Scientific, Inc., Waltham, MA, USA) and incubated for 15 min at room temperature. This was followed by overnight incubation at 4°C with polyclonal antibodies against runt-related transcription factor 2 (1:1,000; ab76956), sex determining region Y-box 9 (1:500; ab26414), collagen type I (col I; 1:500; ab34710), collagen type II (col II; 1:200; ab53047), aggrecan (1:500; ab36861), MMP9 (1:300; ab38898), MMP13 (1:50; ab75606) and Indian hedgehog (Ihh; 1:200; ab39634). Antibodies were obtained from Abcam (Cambridge, MA, USA). Slides were then washed 3 times using phosphate-buffered saline (PBS), followed by incubation with a biotinylated horseradish peroxidase goat anti-rabbit secondary antibody (1:1,000; Thermo Fisher Scientific, Inc.) for 20 min at 37°C. Slides were then washed 3 times using PBS. Immunolabeled samples were visualized by incubating in 0.05% diaminobenzidine (Invitrogen; Thermo Fisher Scientific, Inc.) diluted in PBS for 5 min at room temperature, followed by rinsing for 10 min under a running water tap. Immunohistochemically stained mouse TMJs were visualized using an Olympus BH-2 light microscope (Olympus Corporation, Tokyo, Japan).

Statistical analysis. Experiments were repeated a minimum of 3 times and presented as the mean ± standard deviation. Statistical analysis of the data was achieved using one-way analysis of variance with SPSS software (version 13.0; SPSS, Inc., Chicago, IL, USA). $P<0.05$ was considered to indicate a statistically significant difference.

Results

Shox2$^{SHOX\ KI/KI}$ *mice develop a severe muscle wasting syndrome*. The majority of *Shox2*$^{SHOX\ KI/KI}$ mice survived beyond 7 days after birth but gradually developed a severe muscle wasting syndrome (Fig. 1). At P21, 5/20 (25%) *Shox2*$^{SHOX\ KI/KI}$ mice survived following weaning, but were notably reduced in size compared with *Shox2*$^{SHOX\ KI/+}$ and wild-type *Shox2*$^{SHOX+/+}$ mice (Fig. 1A and B). Body weight analysis at P0, P7, P14, and P21 demonstrated that wild-type *Shox2*$^{SHOX+/+}$, *Shox2*$^{SHOX\ KI/+}$ and *Shox2*$^{SHOX\ KI/KI}$ mice displayed a similar body weight at birth (P0); however, *Shox2*$^{SHOX\ KI/KI}$ mice displayed a significant reduction in body weight at P7 ($P<0.0001$), P14 ($P<0.0001$) and P21 ($P<0.0001$) compared with wild-type *Shox2*$^{SHOX+/+}$ mice (Fig. 1C).

Shox2$^{SHOX\ KI/KI}$ *mice exhibit an abnormal TMJ*. Histological analysis of TMJ development in postnatal mice using HE staining (Fig. 2A), Safranin O-Fast green staining (Fig. 2B) and azon red/anilin blue staining (Fig. 2C), demonstrated that *Shox2*$^{SHOX\ KI/KI}$ mice displayed congenital cartilage degradation from P7. To investigate the *Shox2*$^{SHOX\ KI/KI}$ TMJ phenotype further, changes in condyle and glenoid fossa width, starting from the region that displayed the most significant change, was investigated at P0, P7, P14 and P21 time points. The average glenoid fossa and condyle width in wild-type *Shox2*$^{SHOX+/+}$ mice at each time point was defined as 100%. The glenoid fossa and condyle width was similar in wild-type *Shox2*$^{SHOX+/+}$, *Shox2*$^{SHOX\ KI/+}$ and *Shox2*$^{SHOX\ KI/KI}$ mice at P0 (Fig. 2D and E). However, the glenoid fossa and condyle width in *Shox2*$^{SHOX\ KI/KI}$ mice was significantly reduced when compared with wild-type *Shox2*$^{SHOX+/+}$ and *Shox2*$^{SHOX\ KI/+}$ mice at P14 ($P<0.0001$) and P21 ($P<0.0001$) stages (Fig. 2D and E). Notably, these developmental alterations of the TMJ, led to restrained jaw movement and eating and drinking difficulties, which is clinically defined as TMJ OA.

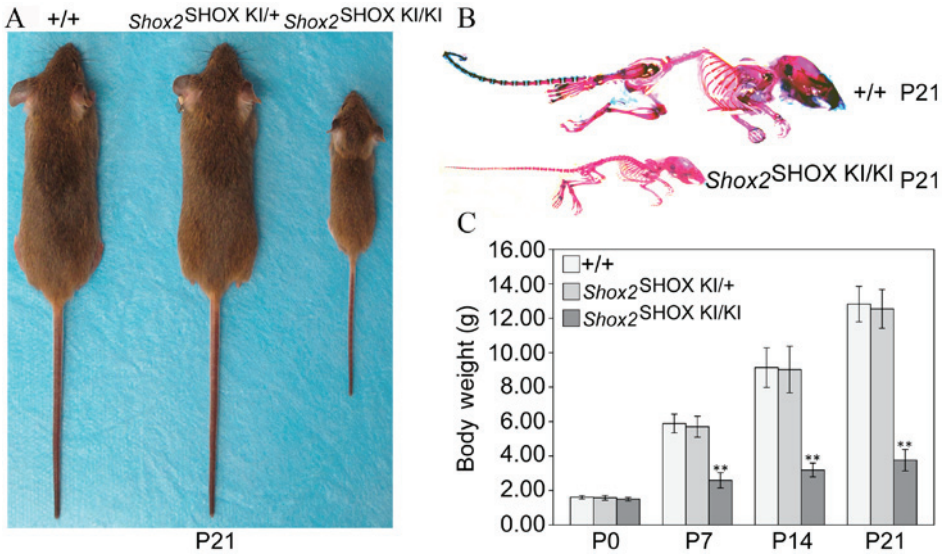

Figure 1. *Shox2*$^{SHOX\ KI/KI}$ mice develop a severe muscle wasting syndrome. (A) Photograph of a wild-type *Shox2*$^{+/+}$, *Shox2*$^{SHOX\ KI/+}$ and *Shox2*$^{SHOX\ KI/KI}$ mice at P21. (B) Bone staining of a wild-type *Shox2*$^{+/+}$ and *Shox2*$^{SHOX\ KI/KI}$ mice at P21. (C) Comparison of wild-type *Shox2*$^{+/+}$, *Shox2*$^{SHOX\ KI/+}$ and *Shox2*$^{SHOX\ KI/KI}$ mice body weights at P0, P7, P14 and P21 time points. Error bars represent the standard deviation. **P<0.01 vs. wild-type *Shox2*$^{+/+}$ mice. Shox, short stature homeobox; P21, postnatal day 21.

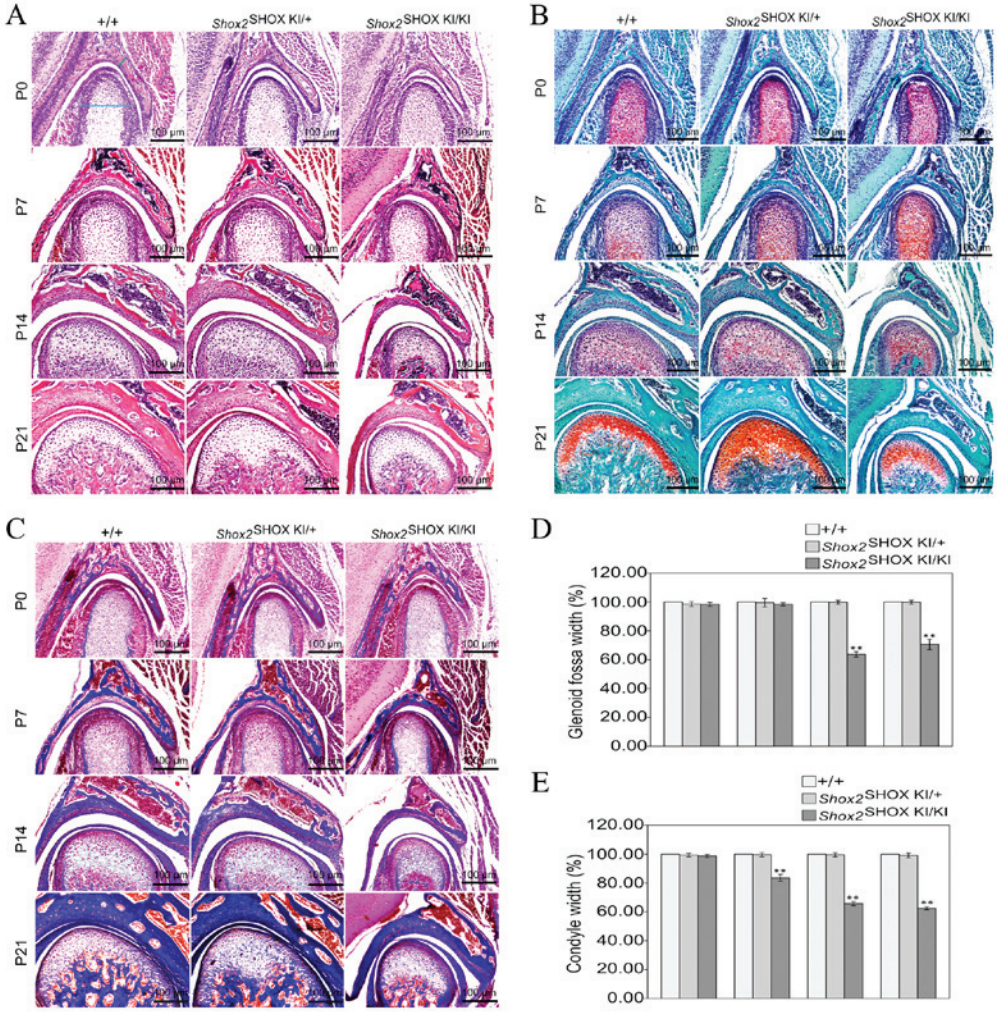

Figure 2. Postnatal *Shox2*$^{SHOX\ KI/KI}$ mice demonstrate congenital cartilage degradation in the TMJ. Coronal sections of the TMJ in wild-type *Shox2*$^{+/+}$, *Shox2*$^{SHOX\ KI/+}$ and *Shox2*$^{SHOX\ KI/KI}$ mice at P0, P7, P14 and P21 with (A) hematoxylin-eosin, (B) Safranin O-Fast Green and (C) azon red/anilin blue staining. Comparison of TMJ (D) glenoid fossa and (E) condyle width in *Shox2*$^{SHOX\ KI/+}$ and *Shox2*$^{SHOX\ KI/KI}$ mice relative to wild-type *Shox2*$^{+/+}$ mice (100%). Green and blue lines in P0 wild-type *Shox2*$^{+/+}$ mice in (A) indicate the positions at which glenoid fossa and condyle widths were measured on tissue sections. Error bars represent the standard deviation. **P<0.01 vs. wild-type *Shox2*$^{+/+}$ mice. TMJ, temporomandibular joint; Shox, short stature homeobox; P0, postnatal day 0.

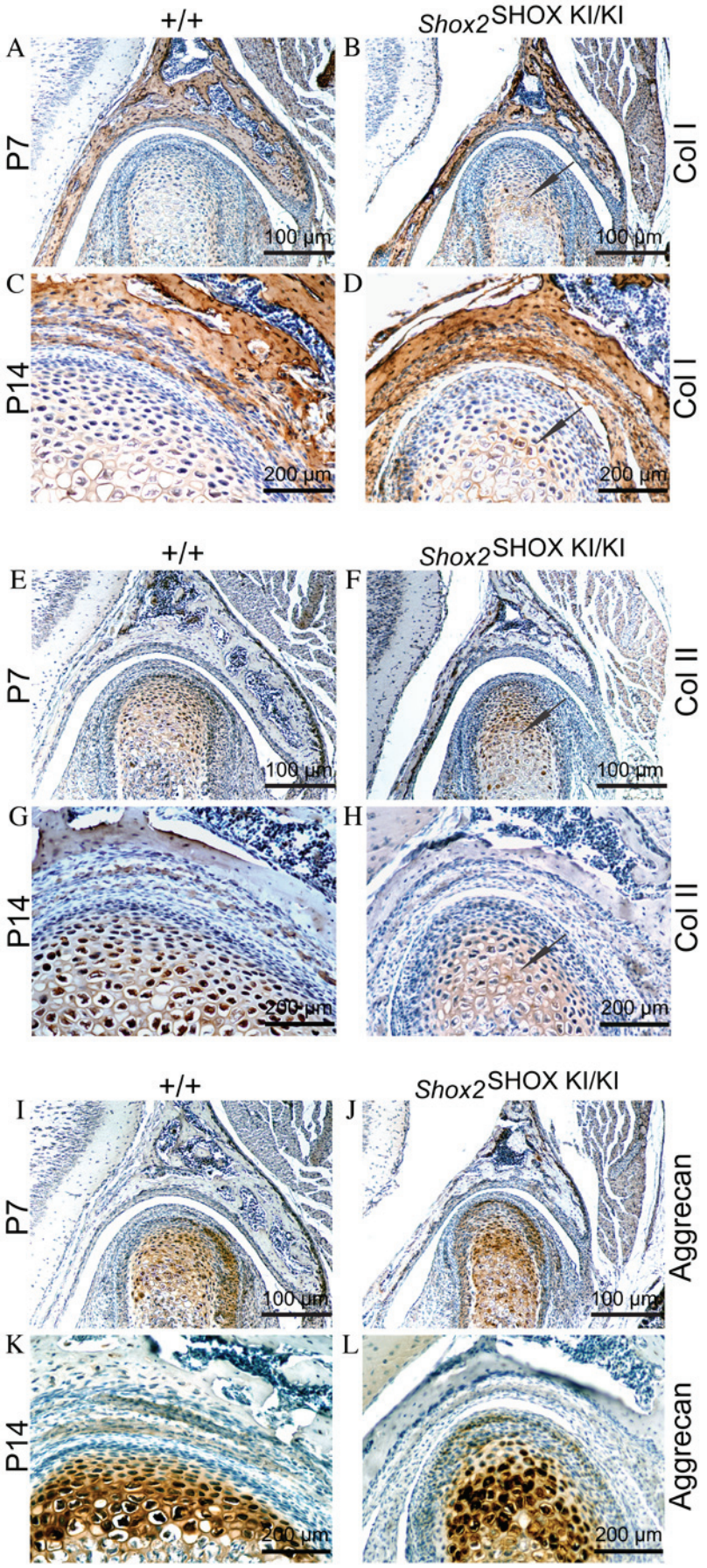

Figure 3. Altered expression patterns of extracellular matrix proteins and Ihh in the TMJ of *Shox2*$^{SHOX\ KI/KI}$ mice. Immunohistochemical staining of (A-D) collagen type I, (E-H) collagen type II and (I-L) aggrecan in the coronal sections of TMJs in postnatal wild-type *Shox2*$^{+/+}$ and *Shox2*$^{SHOX\ KI/KI}$ mice at P7 and P14. Arrows indicate regions of the condyle and glenoid fossa where protein expression is altered. Ihh, Indian hedgehog; TMJ, temporomandibular joint; Shox, short stature homeobox; P7, postnatal day 7.

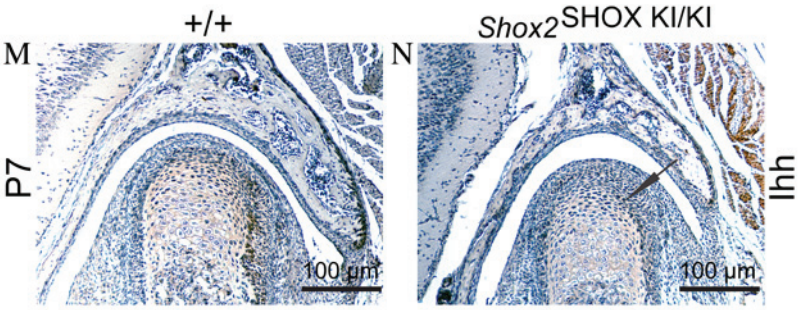

Figure 3. Continued. Immunohistochemical staining of (M and N) Ihh in the coronal sections of TMJs in postnatal wild-type *Shox2*$^{+/+}$ and *Shox2*$^{SHOX\ KI/KI}$ mice at P7 and P14. Arrows indicate regions of the condyle and glenoid fossa where protein expression is altered. Ihh, Indian hedgehog; TMJ, temporomandibular joint; Shox, short stature homeobox; P7, postnatal day 7.

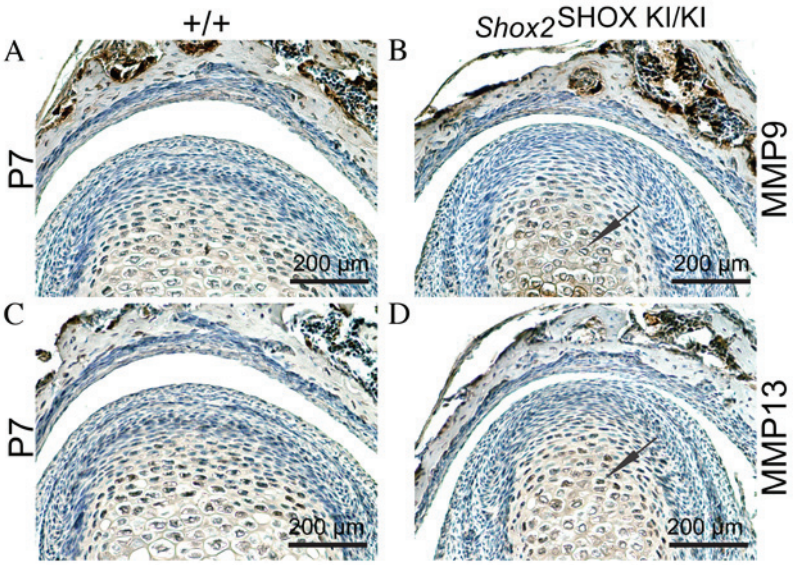

Figure 4. Increased expression of MMP9 and MMP13 in the TMJ of postnatal *Shox2*$^{SHOX\ KI/KI}$ mice. Immunohistochemical staining of (A and B) MMP9 and (C and D) MMP13 in the coronal sections of TMJs in postnatal wild-type *Shox2*$^{+/+}$ and *Shox2*$^{SHOX\ KI/KI}$ mice at P7. Arrows indicate regions of the condyle and glenoid fossa where protein expression is altered. MMP, matrix metalloproteinase; P7, postnatal day 7; TMJ, temporomandibular joint; Shox, short stature homeobox.

Upregulation of col I and downregulation of col II and Ihh in the condyle of the Shox2$^{SHOX\ KI/KI}$ *mice*. The ECM of the condyle is composed of collagens, PGS, GAGs and aggrecan (20). ECM components serve an important role in maintaining tensile properties and resistance to compressive forces. Alterations in ECM components are associated with TMJ cartilage degradation (8). Therefore, the expression levels of the matrix proteins col I, col II, aggrecan and Ihh were investigated in the present study, in order to determine an association between the observed TMJ growth alterations in postnatal *Shox2*$^{SHOX\ KI/KI}$ mice and changes in ECM components. Immunohistochemical analysis demonstrated an increase in col I expression levels in the condyles of *Shox2*$^{SHOX\ KI/KI}$ mice compared with wild-type *Shox2*$^{SHOX+/+}$ mice at P7 and P14, whereas col II expression levels were reduced (Fig. 3A-H). However, no difference in the expression levels of aggrecan in the condyles of *Shox2*$^{SHOX\ KI/KI}$ mice and wild-type *Shox2*$^{SHOX+/+}$ mice were observed (Fig. 3I-L). The expression levels of Ihh were determined using immunohistochemical analysis at P7. The results demonstrated that Ihh expression levels in *Shox2*$^{SHOX\ KI/KI}$ mouse condyles were significantly downregulated compared with wild-type *Shox2*$^{SHOX+/+}$ mice (Fig. 3M and N). Therefore, upregulation of col I and downregulation of col II and Ihh in the condyles may be responsible for the observed congenital cartilage degradation in *Shox2*$^{SHOX\ KI/KI}$ mice.

Upregulation of MMP9 and MMP13 in the condyle of the Shox2$^{SHOX\ KI/KI}$ *mice*. MMP9 and MMP13 are zinc-dependent endopeptidases that function to degrade ECM collagens, and have been observed to be elevated in TMJ OA (21). Therefore, the next aim of the present study was to investigate whether the observed reduction in col II expression levels in *Shox2*$^{SHOX\ KI/KI}$ mouse TMJs was caused by increased MMP9 and MMP13 activity. To test this hypothesis, immunohistochemical analysis was conducted to determine MMP9 and MMP13 protein expression levels in *Shox2*$^{SHOX\ KI/KI}$ and wild-type *Shox2*$^{SHOX\ +/+}$ mouse TMJs. As presented in Fig. 4D, MMP9 and MMP13 exhibited increased expression levels in *Shox2*$^{SHOX\ KI/KI}$ mouse TMJs at P7 compared with the wild-type *Shox2*$^{SHOX+/+}$ mice. These results indicate that increased MMP9 and MMP13 activity may be responsible for the observed reduction in col II expression levels and the

congenital cartilage degradation in *Shox2*$^{SHOX\ KI/KI}$ mouse TMJs.

Discussion

Conditional inactivation of *Shox2* has been observed to result in dysplasia of the condyle and glenoid fossa and articular disc ankylosis (16). Additionally, *Shox2*$^{SHOX\ KI/KI}$ mice exhibit premature erosion of the articular disc (2). These results support the putative functional role of *Shox2* in TMJ formation and development. In the present study, alterations in TMJ growth in postnatal *Shox2*$^{SHOX\ KI/KI}$ mice were observed. The results demonstrate that the downregulation of col II and Ihh, and upregulation of col I, MMP9 and MMP13 may contribute to the congenital OA-like phenotype observed in postnatal *Shox2*$^{SHOX\ KI/KI}$ mouse TMJs.

To further investigate the mechanism of the congenital OA-like disease, the present study focused on the changes in ECM composition, Ihh and MMPs in the postnatal *Shox2*$^{SHOX\ KI/KI}$ mouse TMJs. Understanding the alterations that occur in the ECM composition of TMJ are necessary to elucidate the pathological process of TMJ OA (6). Cartilage destruction, mediated by the loss of col II and PGS, is a characteristic feature of OA (22,23). The initial loss of col II occurs in the superficial and upper-middle zones of the TMJ and extends into the deeper zones, with increasing destruction accompanied by the pathological process of OA (24). In normal hyaline cartilage, the predominant collagen type is col II, which is produced by chondrocytes. However, col I is also involved in the pathogenesis of OA; the relative concentrations of carboxyterminal telopeptides of col I and II may therefore act as a marker of cartilage degradation (25). The cleavage of fibrillar collagens by MMPs contributes to the substantial degradation of tissues during OA. MMP9 and MMP13 demonstrate a preference for degrading fibrillar collagen substrates, such as col II, however, also possess the ability to degrade the large hydrodynamic cartilage proteoglycan aggregate (26,27). Ihh, a regulator of chondrocyte and chondroprogenitor proliferation as well as chondrocyte maturation, has been observed to be essential for embryonic and postnatal TMJ development (28-30). Therefore, in order to investigate the mechanisms of congenital OA-like disease development in *Shox2*$^{SHOX\ KI/KI}$ mice in the present study, the composition of ECM proteins (col I, col II and aggrecan), Ihh, MMP9 and MMP13 protein expression levels in postnatal *Shox2*$^{SHOX\ KI/KI}$ mouse TMJs were determined. Using immunohistochemical staining, the results demonstrated decreased expression of col II and Ihh, and increased expression of col I, MMP9 and MMP13 in *Shox2*$^{SHOX\ KI/KI}$ condyles compared with wild-type *Shox2*$^{+/+}$ mice at stages P7 and P14. This provides additional evidence that OA-like disease occurred in *Shox2*$^{SHOX\ KI/KI}$ mouse TMJs. It is currently unknown whether the observed reduction in Ihh expression levels confers elevated MMP activity and loss of col II in postnatal *Shox2*$^{SHOX\ KI/KI}$ mouse TMJs. However, the Ihh signaling pathway serves an important role in regulating tissue structure homeostasis during TMJ development and requires further investigation.

In conclusion, postnatal *Shox2*$^{SHOX\ KI/KI}$ mouse TMJs were observed to develop congenital OA-like disease, which provides a novel *in vivo* model for studying the molecular and cellular mechanisms of TMJ OA.

Acknowledgements

The present study was supported by grants from the National Natural Science Foundation of China (grant nos. 81202645 and 81230087), the Program for New Century Excellent Talents in Fujian Province University (grant no. JA14150), and the Fujian University of Traditional Chinese Medicine Tube Project (grant no. X2015021). The authors appreciate the assistance of Dr Yiping Chen (Department of Cell and Molecular Biology, Tulane University, USA).

References

1. Wang Y, Liu C, Rohr J, Liu H, He F, Yu J, Sun C, Li L, Gu S and Chen Y: Tissue interaction is required for glenoid fossa development during temporomandibular joint formation. Dev Dyn 240: 2466-2473, 2011.
2. Li X, Liu H, Gu S, Liu C, Sun C, Zheng Y and Chen Y: Replacing Shox2 with human SHOX leads to congenital disc degeneration of the temporomandibular joint in mice. Cell Tissue Res 355: 345-354, 2014.
3. Wang XD, Zhang JN, Gan YH and Zhou YH: Current understanding of pathogenesis and treatment of TMJ osteoarthritis. J Dent Res 94: 666-673, 2015.
4. Embree MC, Iwaoka GM, Kong D, Martin BN, Patel RK, Lee AH, Nathan JM, Eisig SB, Safarov A, Koslovsky DA, *et al*: Soft tissue ossification and condylar cartilage degeneration following TMJ disc perforation in a rabbit pilot study. Osteoarthritis Cartilage 23: 629-639, 2015.
5. Li X, Liang W, Ye H, Weng X, Liu F and Liu X: Overexpression of Shox2 leads to congenital dysplasia of the temporomandibular joint in mice. Int J Mol Sci 15: 13135-13150, 2014.
6. Su SC, Tanimoto K, Tanne Y, Kunimatsu R, Hirose N, Mitsuyoshi T, Okamoto Y and Tanne K: Celecoxib exerts protective effects on extracellular matrix metabolism of mandibular condylar chondrocytes under excessive mechanical stress. Osteoarthritis Cartilage 22: 845-851, 2014.
7. Wilusz RE, Zauscher S and Guilak F: Micromechanical mapping of early osteoarthritic changes in the pericellular matrix of human articular cartilage. Osteoarthritis Cartilage 21: 1895-1903, 2013.
8. Garnero P, Rousseau JC and Delmas PD: Molecular basis and clinical use of biochemical markers of bone, cartilage, and synovium in joint diseases. Arthritis Rheum 43: 953-968, 2000.
9. Polur I, Lee PL, Servais JM, Xu L and Li Y: Role of HTRA1, a serine protease, in the progression of articular cartilage degeneration. Histol Histopathol 25: 599-608, 2010.
10. Hill A, Duran J and Purcell P: Lubricin protects the temporomandibular joint surfaces from degeneration. PLoS One 9: e106497, 2014.
11. Asakawa-Tanne Y, Su S, Kunimatsu R, Hirose N, Mitsuyoshi T, Okamoto Y, Tanaka E, Tanne K and Tanimoto K: Effects of enzymatic degradation after loading in temporomandibular joint. J Dent Res 94: 337-343, 2015.
12. Gepstein A, Arbel G, Blumenfeld I, Peled M and Livne E: Association of metalloproteinases, tissue inhibitors of matrix metalloproteinases, and proteoglycans with development, aging, and osteoarthritis processes in mouse temporomandibular joint. Histochem Cell Biol 120: 23-32, 2003.
13. Xu L, Flahiff CM, Waldman BA, Wu D, Olsen BR, Setton LA and Li Y: Osteoarthritis-like changes and decreased mechanical function of articular cartilage in the joints of mice with the chondrodysplasia gene (cho). Arthritis Rheum 48: 2509-2518, 2003.
14. Inada M, Wang Y, Byrne MH, Rahman MU, Miyaura C, López-Otín C and Krane SM: Critical roles for collagenase-3 (Mmp13) in development of growth plate cartilage and in endochondral ossification. Proc Natl Acad Sci USA 101: 17192-17197, 2004.
15. Cobb J, Dierich A, Huss-Garcia Y and Duboule D: A mouse model for human short-stature syndromes identifies Shox2 as an upstream regulator of Runx2 during long-bone development. Proc Natl Acad Sci USA 103: 4511-4515, 2006.

16. Gu S, Wei N, Yu L, Fei J and Chen Y: Shox2-deficiency leads to dysplasia and ankylosis of the temporomandibular joint in mice. Mech Dev 125: 729-742, 2008.
17. Liu H, Chen CH, Espinoza-Lewis RA, Jiao Z, Sheu I, Hu X, Lin M, Zhang Y and Chen Y: Functional redundancy between human SHOX and mouse Shox2 genes in the regulation of sinoatrial node formation and pacemaking function. J Biol Chem 286: 17029-17038, 2011.
18. Liu YD, Liao LF, Zhang HY, Lu L, Jiao K, Zhang M, Zhang J, He JJ, Wu YP, Chen D and Wang MQ: Reducing dietary loading decreases mouse temporomandibular joint degradation induced by anterior crossbite prosthesis. Osteoarthritis Cartilage 22: 302-312, 2014.
19. Liang W, Li X, Gao B, Gan H, Lin X, Liao L and Li C: Observing the development of the temporomandibular joint in embryonic and post-natal mice using various staining methods. Exp Ther Med 11: 481-489, 2016.
20. Gu Z, Feng J, Shibata T, Hu J and Zhang Z: Type II collagen and aggrecan mRNA expression by in situ hybridization in rabbit temporomandibular joint posterior attachment following disc displacement. Arch Oral Biol 48: 55-62, 2003.
21. Jackson MT, Moradi B, Smith MM, Jackson CJ and Little CB: Activation of matrix metalloproteinases 2, 9, and 13 by activated protein C in human osteoarthritic cartilage chondrocytes. Arthritis Rheumatol 66: 1525-1536, 2014.
22. Lindhorst E, Wachsmuth L, Kimmig N, Raiss R, Aigner T, Atley L and Eyre D: Increase in degraded collagen type II in synovial fluid early in the rabbit meniscectomy model of osteoarthritis. Osteoarthritis Cartilage 13: 139-145, 2005.
23. Megías J, Guillén MI, Bru A, Gomar F and Alcaraz MJ: The carbon monoxide-releasing molecule tricarbonyldichlororuthenium(II) dimer protects human osteoarthritic chondrocytes and cartilage from the catabolic actions of interleukin-1beta. J Pharmacol Exp Ther 325: 56-61, 2008.
24. Rogart JN, Barrach HJ and Chichester CO: Articular collagen degradation in the Hulth-Telhag model of osteoarthritis. Osteoarthritis Cartilage 7: 539-547, 1999.
25. Miosge N, Hartmann M, Maelicke C and Herken R: Expression of collagen type I and type II in consecutive stages of human osteoarthritis. Histochem Cell Biol 122: 229-236, 2004.
26. Kim JH, Jeon J, Shin M, Won Y, Lee M, Kwak JS, Lee G, Rhee J, Ryu JH, Chun CH and Chun JS: Regulation of the catabolic cascade in osteoarthritis by the zinc-ZIP8-MTF1 axis. Cell 156: 730-743, 2014.
27. Flannelly J, Chambers MG, Dudhia J, Hembry RM, Murphy G, Mason RM and Bayliss MT: Metalloproteinase and tissue inhibitor of metalloproteinase expression in the murine STR/ort model of osteoarthritis. Osteoarthritis Cartilage 10: 722-733, 2002.
28. Purcell P, Joo BW, Hu JK, Tran PV, Calicchio ML, O'Connell DJ, Maas RL and Tabin CJ: Temporomandibular joint formation requires two distinct hedgehog-dependent steps. Proc Natl Acad Sci USA 106: 18297-18302, 2009.
29. Ochiai T, Shibukawa Y, Nagayama M, Mundy C, Yasuda T, Okabe T, Shimono K, Kanyama M, Hasegawa H, Maeda Y, *et al*: Indian hedgehog roles in post-natal TMJ development and organization. J Dent Res 89: 349-354, 2010.
30. Shibukawa Y, Young B, Wu C, Yamada S, Long F, Pacifici M and Koyama E: Temporomandibular joint formation and condyle growth require Indian hedgehog signaling. Dev Dyn 236: 426-434, 2007.