

Whole exome sequencing identifies a mutation in *EYA1* and *GLI3* in a patient with branchio-otic syndrome and esophageal atresia: Coincidence or a digenic mode of inheritance?

FRANZISKA KAUSE¹, HEIKO REUTTER^{1,2}, FLORIAN MARSCH¹, HOLGER THIELE³,
JANINE ALTMÜLLER^{3,4}, MICHAEL LUDWIG⁵ and RONG ZHANG^{1,6}

¹Institute of Human Genetics, University Hospital of Bonn; ²Department of Neonatology and Pediatric Intensive Care, Children's Hospital, University Hospital of Bonn, D-53127 Bonn; ³Cologne Center for Genomics; ⁴Institute of Human Genetics, University of Cologne, D-50931 Cologne; ⁵Department of Clinical Chemistry and Clinical Pharmacology, University Hospital of Bonn; ⁶Department of Genomics, Life and Brain Center, D-53127 Bonn, Germany

Received August 15, 2017; Accepted November 9, 2017

DOI: 10.3892/mmr.2017.8196

Abstract. Branchio-otic (BO) syndrome is a clinically and genetically heterogeneous disorder that presents with variable branchial arch and otic anomalies. Dominant mutations in the human homologues of the *Drosophila eyes absent* (*EYA1*) gene, and the *Drosophila sine oculis* homeobox 1 and 5 (*SIX1* and *SIX5*, respectively) genes have been causally associated with BO syndrome. Esophageal atresia (EA), with or without tracheo-esophageal fistula (TEF), is the most common type of malformation of the upper digestive tract. To date, its causes are poorly understood. The present study investigated a family with three affected members who all presented with classic BO associated symptoms. Notably, the index patient also presented with the most common EA/TEF subtype type 3b. Whole exome sequencing (WES) was performed in the index patient, and prioritized genetic variants and their segregation in the family were analyzed by Sanger sequencing. WES demonstrated a known disease-causing heterozygous *EYA1* splice variant in the patient, as well as his sister and mother; all of whom were affected with BO syndrome. A further GLI family zinc finger 3 (*GLI3*) splice variant of unknown significance, inherited from the unaffected father, was also detected in the index patient. *EYA1* and *GLI3* are involved in the Sonic Hedgehog transcriptional network and *GLI3* seems to be involved in human foregut malformations. Therefore, one may hypothesize a digenic inheritance model involving *EYA1* and *GLI3*, where the effect of the *GLI3* variant observed here only emerges in the background of the *EYA1* defect.

Introduction

The branchio-otic (BO) syndrome is characterized by branchial arch and otic anomalies. It presents heterogeneously, both clinically and genetically, and manifests with reduced penetrance and variable expressivity (1). BO syndrome is a rare autosomal-dominant disorder with a birth prevalence of about 1:40,000 (1). The first identified causative gene was the human homologue of the *Drosophila eyes absent* gene, *EYA1* (2). Vincent *et al* (3) demonstrated that BOR (branchio-oto-renal syndrome 1, BOR1; OMIM #113650) and BOS (branchio-otic syndrome 1, BOS1; OMIM #602588) are allelic disorders. Subsequently, mutations in the two human homologues of the *Drosophila sine oculis* homeobox 1 and 5 genes (*SIX1*, *SIX5*) have been detected (4,5). To date, defects of *SIX5* have been exclusively found in patients who additionally presented with congenital renal anomalies, whereas *SIX1* mutations have been found in patients with the classic BO phenotype. Evidence for further genetic heterogeneity of BO syndrome was provided by Kumar *et al*, who linked an additional form (BOS2; OMIM #120502) to a region on chromosome 1q31 (6).

Esophageal atresia (EA) with or without tracheo-esophageal fistula (TEF) are the most common malformations of the upper digestive tract. EA/TEF comprises five anatomical subtypes and these are classified on the basis of the location and the type of anastomosis that exists between the trachea and the esophagus (7). The birth prevalence of EA/TEF has been reported with 1 in 3,000 live births (8). Approximately 50% of affected individuals show an isolated phenotype, while the remaining patients present EA/TEF in combination with other congenital malformations, e.g., cardiac or renal anomalies (9). Furthermore, EA/TEF have been observed in over 50 distinct genetic syndromes, associations and sequences (9). The likely causes of EA/TEF are heterogeneous and, to date, remain poorly understood. However, previous study has implicated several developmental genes with emphasis on effectors of the Sonic Hedgehog (SHH) signaling pathway [*SHH*, GLI family zinc finger 1 (*GLI1*), *GLI2*, *GLI3*] in mouse

Correspondence to: Mrs. Rong Zhang, Institute of Human Genetics, University Hospital of Bonn, Sigmund-Freud-Str. 25, D-53127 Bonn, Germany
E-mail: rongzhang@uni-bonn.de

Key words: branchio-otic syndrome, esophageal atresia, *Drosophila eyes absent*, GLI family zinc finger 3, whole exome sequencing

models (10). In this context, Motoyama *et al* (10) found that in *Gli2*^{-/-} mice, a reduction of 50% in the gene dosage of *Gli3* in a *Gli2*^{-/-} background resulted in EA/TEF and a severe lung phenotype, suggestive of a possible digenic inheritance model.

In the present study, we investigated a family with three affected members who all presented with classic BO-associated symptoms. Interestingly, the index patient also showed the most common EA/TEF subtype type 3b according to Vogt (7).

Materials and methods

Subjects. Blood samples were collected from all family members of the index patient and a further 18 patients with EA/TEF and BO syndrome-associated anomalies, such as hearing loss or malformation of the ears. Written informed consent was obtained from all participants or from their proxies in the case of legal minors. The study was approved by the ethics committee of the Medical Faculty of the University of Bonn and was conducted in accordance with the principles of the Declaration of Helsinki.

Whole exome sequencing (WES) and data analysis. Blood samples were obtained from the family under study and isolation of genomic DNA from blood was carried out using a Chemagic Magnetic Separation Module I (Chemagen, Baesweiler, Germany).

Mutation analysis was performed on our patient by WES (enrichment kit: Nimble Gene SeqCap ES Human Exome Library 2.0) with the Genome Analyzer II (Illumina). Read alignment and detection of variants was done with genome analyzing software (Varbank; www.varbank.ccg.uni-koeln.de/). In particular, we filtered for high quality (coverage of more than six reads, a minimum quality score of 10, VQSLOD greater than -8) and rare (allele frequency <0.5%) autosomal variants in *EYAI*, *SIX1* and *EYAI-SIX1* pathway-related genes. In order to exclude pipeline specific artifacts, we also filtered against an in-house epilepsy cohort (n=511, AF <2%) of variations, which were created with the same analysis pipeline. The filter conditions were set to be more sensitive following manual inspections of aligned reads.

Variation analysis. Variations identified by WES were amplified from genomic DNA by polymerase chain reaction (PCR) and automated sequence analysis was carried out using standard procedures. In brief, primers were directed to all observed variations and the resultant PCR products were subjected to direct automated BigDye terminator sequencing (3130XL Genetic Analyzer; Applied Biosystems; Thermo Fisher Scientific, Inc., Waltham, MA, USA). Both strands from each amplicon were sequenced and segregation of the variations in the family was investigated by sequencing the respective PCR product in all members. Primer sequences for all gene variants under investigation are available upon request.

Data from the observed allele frequencies harboring the variants were obtained from the ExAc database (exac.broadinstitute.org). Interpretation of identified missense variants was carried out with the following prediction programs: MutPred (www.mutpred1.mutdb.org), Polyphen-2 (www.genetics.bwh.harvard.edu/pph2/), HumVar (included in Polyphen-2), SIFT (sift.jcvi.org) and PROVEAN (included

in SIFT). The *GLI3* splice variant was analyzed according to Shapiro and Senapathy (11) and Human Splicing Finder 3.0 (12).

Results

Clinical observations. The investigated family has three affected members who all presented with classic BO-associated symptoms (Table I and Fig. 1). Interestingly, the index patient (II.3) presented with branchial anomalies (bilateral branchial cleft fistulas and preauricular pits) and the most common EA/TEF subtype type 3b according to Vogt (7). The sister (II.2) and the mother (I.2) of the patient also presented with BO syndrome-associated symptoms (hearing loss or impairment, ear and neck fistulas). His elder brother (II.1) had a preauricular tag. The father showed no anomalies (Fig. 1). To the best of our knowledge, this is the first report on the concurrence of BO syndrome and EA/TEF to date.

WES and segregation of identified variants. In the context of the index patient reported here, Eisner *et al* (13) were recently able to show that several of the EA/TEF-associated SHH pathway genes *GLI1*, *GLI2*, and *GLI3* interact with the BO syndrome-associated *EYAI-SIX1* pathway genes. Hence, we performed whole-exome sequencing (WES) in the index patient (i) to identify disease causing variants in *EYAI-SIX1* pathway genes (ii) and to identify variants in EA/TEF-associated SHH pathway genes (13). Mutation analysis was performed on our patient with WES and the applied filtering identified more than 50 variants (data not shown). From these, one obvious genetic variant explains most of the congenital anomalies seen in the family. An *EYAI* mutation (c.966+5G>A, according to ENSEMBL transcript ENST00000340726, with the A of the start methionine as no. 1) was present in the donor splice site of exon 10 in the index patient. Sanger sequencing confirmed the mutation in the patient as well as two other affected family members (sister: II.2, and the mother, I.2; Fig. 1 and Table I). This mutation is known to cause exon skipping with a premature termination codon in the resultant mRNA (14).

Our second analysis of the index patient's WES dataset focused on candidate variants with an allele frequency of <0.01 in SHH signaling pathway genes with special emphasis on *GLI1*, *GLI2*, *GLI3*, *SUFU*, *NRP1*, *NRP2*, and *SMO*. In this context, we detected additional heterozygous variants in *GLI1* (p.Thr176Met), *GLI3* (splice variant c.1028+3A>G, according to ENSEMBL transcript ENST00000395025, with the A of the start methionine as no.1), *NRP1* (p.Asp601Asn) and *SMO* (p.Arg168His) (Table II). Apart from the four variants in *GLI1*, *GLI3*, *NRP1* and *SMO*, WES did not detect any further variations that might be attributable to EA/TEF in our patient. Sanger sequencing confirmed all four variants in the index patient (Fig. 1). Two of the four variants in *GLI1* and *SMO* were transmitted from the *EYAI* carrying mother and the other two variants in *GLI3* and *NRP1* were transmitted from the healthy father (Fig. 1). Since the mother did not present with EA/TEF we excluded the two variants in *GLI1* and *SMO* as EA/TEF disease causing. As the variant in *NRP1* is located in a region of low conservation (Table II), it was also excluded.

Table I. Phenotypic features identified in patients with the *Drosophila* eyes absent c.966+5G>A mutation.

Author, year	Patient	Hearing loss	Ear anomalies	Branchial anomalies	Renal anomalies	Other features	(Refs.)
Kause <i>et al</i> Kause <i>et al</i>	I.2	Unilateral inner ear (unspecified)	Middle ear	Unilateral fistula (ear)	-	-	Present study
	II.2	-	-	Bilateral fistula (ear), unilateral fistula (neck)	-	-	Present study
Kause <i>et al</i>	II.3	-	-	Bilateral fistula (ear), bilateral fistula (neck)	-	Esophageal atresia (Vogt 3b)	Present study
	8	Mild	-	Not specified fistula and cyst, bilateral preauricular pit	URA	-	(14) ^a
Stockley <i>et al</i> , 2009	9	Yes, unspecified	-	n/a	URA	-	(14) ^a
	10	Mild-to-moderate (mixed)	Cup shaped ears, posteriorly rotated	Not specified fistula and cyst, unilateral preauricular pit	URA, VUR	-	(14) ^a
Krug <i>et al</i> , 2011 Song <i>et al</i> , 2013	1,291	-	-	Yes (unspecified)	-	Bilateral cataract	(15) ^a
	7	Bilateral (mixed, unspecified)	Cochlear hypoplasia (bi), dilated vestibule (bi), enlarged vestibular aqueduct (bi); middle ear: Ossicular anomaly (bi) and deviated facial nerve (bi); enlarged endolymphatic sac (l) and duct (bi)	-	n/a	-	(16) ^b
Bekheirnia <i>et al</i> , 2017	Family 3	-	-	-	VUR, multicystic dysplastic kidney	-	(17) ^a

No phenotypic findings were given for two additional families reported by Stockley *et al* (14). ^aMutation initially termed c.867G>A in this paper; ^bmutation initially termed c.699+5G>A in this paper; n/a, not available; VUR, vesico-ureteric reflux; URA, unilateral renal agenesis; bi, bilateral; l, left.

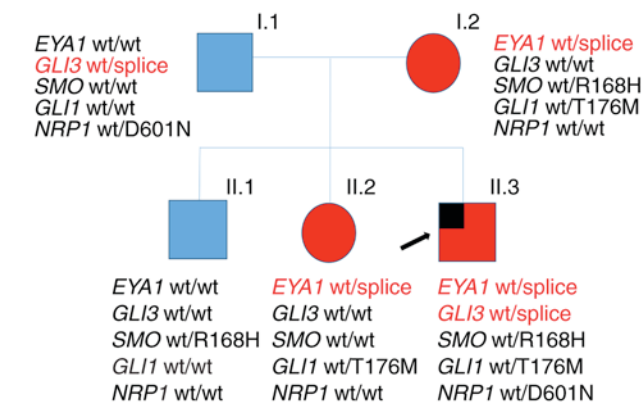


Figure 1. Pedigree of the family with BO syndrome. The index patient, also presenting with esophageal atresia, is marked by an arrow. The presence/absence of gene variants detected by whole-exome sequencing is indicated. Members affected with BO are shown in red, while unaffected members are shown in blue; males and females are indicated by squares and circles, respectively. BO, branchio-otic; wt, wild type; *EYA1*, *Drosophila eyes absent*; *GLI*, *GLI* family zinc finger; *SMO*, smoothened, frizzled class receptor; *NRP1*, neuropilin 1.

The remaining *GLI3* splice site variation, c.1028+3A>G, is an extremely rare variant (rs368499795), observed only once in the ExAc database (n=121,314 alleles). According to Shapiro and Senapathy (11), the A-to-G substitution slightly reduces the consensus value (CV) for splice site recognition from a CV of 0.887 for the wildtype sequence to a CV of 0.854 for the mutant one. As Human Splicing Finder 3.0 (12) also predicts this variation as most probably affecting splicing, these data imply that this *GLI3* variant interferes to a certain extent with correct mRNA processing.

To elucidate a more common involvement of *EYA1* in the etiology of EA/TEF, we screened a further 18 patients with EA/TEF and BO syndrome-associated anomalies, such as hearing loss or malformation of the ears, for variants in *EYA1*. Sanger sequencing revealed 15 intronic and exonic common SNPs (allele frequencies all >0.08) and three further intronic variants with no influence on a splice site or a branch point (data not shown).

Discussion

The initial objective of the present study was to identify a genetic etiology of BO syndrome and EA/TEF in the index patient. Initially, WES demonstrated a heterozygous splice mutation in *EYA1*. To date, this c.966+5G>A mutation has been reported in nine other unrelated patients (Table I) (14-17), where it caused a pleiotropic spectrum of features. Stockley *et al* (14) reported the c.966+5G>A mutation in three BO syndrome patients, who each presented with the most severe renal phenotype in their cohort. However, it was associated without branchial and renal anomalies in a patient reported by Song *et al* (16), and only with branchial anomalies and congenital cataract in another patient (15). Most recently, Bekheirnia *et al* (17) detected the c.966+5G>A mutation in a patient solely affected with a renal phenotype, i.e., vesicoureteral reflux and multicystic dysplastic kidney. In the patient's family, the *EYA1* mutation caused branchial anomalies in the index patient (II.3) and all other affected subjects (I.2, II.2) as well as additional unilateral

Table II. Gene-prediction of the exonic variants with an amino-acid substitution and their conservation status.

Gene	Variation	Substitution	Mm	Dr	Gg	Xt	Polyphen	SIFT	MutPred (probability of deleterious mutation)	Variation frequency
<i>GLI1</i>	c.527C>T	T176M	T	T	T	T	Probably damaging	Damaging	0.290	rs755035040 (5.912x10 ⁻⁵)
<i>GLI3</i>	c.1028+3A>G	-	-	-	-	-	n/a	n/a	n/a	rs368499795 (8.24x10 ⁻⁶)
<i>NRP1</i>	c.1801G>A	D601N	D	-	D	A	Possibly damaging	Damaging	0.326	rs145594886 (4.97x10 ⁻⁵)
<i>SMO</i>	c.503G>A	R168H	R	K	K	K	Possibly damaging	Damaging	0.524	rs61746143 (0.009458)

Variation frequency was determined using Exome Aggregation Consortium (exac.broadinstitute.org). Mm, *Mus musculus*; Dr, *Danio rerio*; Gg, *Gallus gallus*; Xt, *Xenopus tropicalis*; n/a, not applicable as prediction programs do not score splice variants, however, Human Splicing Finder 3.0 (12) predicts that it most probably affects splicing; *GLI*, *GLI* family zinc finger; *SMO*, smoothened, frizzled class receptor; *NRP1*, neuropilin 1; SIFT, scale-invariant feature transform.

hearing loss in the mother (I.2). The older brother (II.1) of the index patient only presented with unilateral preauricular tag, a common benign congenital malformation of the external ear (18) possibly attributable to BO syndrome. Consequently, he was negative for the *EYA1* mutation. In conclusion, the detected *EYA1* mutation should explain all of the BO features observed in the index patient and the other family members.

Our second analysis of the index patient's WES dataset focused on candidate variants with an allele frequency of <0.01 in SHH signaling pathway genes. Evaluation of prioritized genes revealed the presence of an additional potential pathogenic *GLI3* splice variant (c.1028+3A>G) in the index case. Heterozygous mutations in *GLI3* are a most likely cause of Greig cephalopolysyndactyly syndrome (GCPS; OMIM #175700) and Pallister-Hall syndrome (PHS; OMIM #146510), both inherited as an autosomal dominant trait (19,20). Both disorders manifest polyaxial polydactyly with other overlapping features. However, neither a literature review nor the reviews of 174 GCPS/PHS patients, provided by Johnston *et al* (19,20), revealed the presence of our *GLI3* splice variant or EA/TEF in these patients. Yet, Yang *et al* (21) reported a *de novo* missense *GLI3* variant (p.M111T) in a patient with EA with hemivertebrae, resembling the phenotypic spectrum in murine models as reported by Motoyama *et al* (10).

Human Splicing Finder 3.0 (12), predicted the consequence of the c.1028+3A>G variant as most probably affecting splicing. However, according to Shapiro and Senapathy (11), the A-to-G substitution only slightly reduces the CV for splice site recognition, suggesting formation of a relevant amount of normally spliced mRNA, thereby avoiding *GLI3* functional haploinsufficiency. This would explain the absence of typical phenotypic features caused by autosomal dominant *GLI3* mutations, as observed in patients with Pallister-Hall syndrome, Greig cephalopolysyndactyly syndrome or different forms of polydactyly (22). However, a small decrease in the formation of correct *GLI3* transcripts may interfere with the fine-tuning of the *Eya1-Six1*-SHH pathway. In mutant mice lungs, Lu *et al* (23) have shown that *Six1* and *Eya1* act together to regulate SHH/*Gli3* signaling activity. Lewandowski and coworkers reported that more than 40 GLI target genes in the mammalian limb bud are predominantly regulated by *GLI3*, but show a different spatio-temporal requirement for SHH signaling (24). Moreover, it has been reported that in murine peri-cloacal mesenchyme, *Six1* and *Eya1* functionally interact with the SHH pathway and that both these transcripts are down regulated in SHH mutants (25). Based on these observations, and since segregation analysis revealed the inheritance of the *GLI3* splice variant from the unaffected father, one may speculate about a digenic inheritance model involving *EYA1* and *GLI3*, where the effect of the *GLI3* variant emerges only in the background of the *EYA1* defect.

However, the recent work of Eisner *et al* (13), who described *Eya1* and *Six1* as key components of the Shh transcriptional network with *Eya1* and *Six1* as co-regulators of *Gli* transcriptional activators during normal organ development, and several other findings are suggestive of a direct involvement of *EYA1/Eya1* in esophageal development in vertebrates. In mice, *Eya1* has been shown to play a critical role in epithelial, mesenchymal and vascular morphogenesis of the embryonic

lung as an upstream coordinator of SHH fibroblast growth factor 10 (*Fgf10*) signaling (26). It has been shown that the foregut epithelium gives rise to the esophagus, trachea, lungs, thyroid, stomach, liver, pancreas, and hepatobiliary system and there is experimental evidence that they are derived from a common progenitor cell population in the ventral foregut (27). Hence, in case of *EYA1* haploinsufficiency, impairment of this SHH-FGF10 cascade might also interfere with correct esophageal development. In zebra fish, requirement of Shh and *Fgf10* for esophageal morphogenesis has been reported (28) and similarly, disruption of the *Fgf10* gene during the critical period of separation of the trachea and esophagus caused tracheo-esophageal malformations in a mouse model (29). Moreover, it has been shown in mice that the Shh-Fgf10 cascade controls the patterning of the tracheal cartilage rings (30), and that defective Shh and Fgf signaling plays a role in the pathogenesis of EA/TEF (31). Here, the coexistence of the *EYA1* mutation and the additional variant in trans in *GLI3* of our patient is suggestive of a possible digenic mode of inheritance and might explain the co-occurrence of BO syndrome and EA/TEF in our patient. Screening of 18 EA/TEF patients with BO syndrome-associated phenotypic features did not reveal any additional *EYA1* mutation. While investigations of larger EA/TEF cohorts with BO syndrome-associated phenotypic features are warranted, our present approach to elucidate the coincidence of BO syndrome and EA/TEF in the index patient did not imply trio-based WES analysis. Hence, we cannot exclude any other possibly disease causing *de novo* mutations as the cause of EA/TEF in our patient.

Acknowledgements

We thank the family for their invaluable help. Pia Uerdingen is acknowledged for excellent assistance. F.K. was supported by the BONFOR program of the University of Bonn (grant no. O-149.0096). H.R. was supported by a grant from the Else Kröner-Fresenius-Stiftung (EKFS; grant no. 2014_A14) and by two grants from the German Research Foundation (Deutsche Forschungsgemeinschaft, DFG; grant nos. RE 1723/1-1 and RE 1723/2-1). M.L. was supported by a grant from the German Research Foundation (DFG; grant no. LU 731/3-1).

References

- Fraser FC, Sproude JR and Halal F: Frequency of the branchio-oto-renal (BOR) syndrome in children with profound hearing loss. *Am J Med Genet* 7: 341-349, 1980.
- Abdelhak S, Kalatzis V, Heilig R, Compain S, Samson D, Vincent C, Weil D, Cruaud C, Sahly I, Leibovici M, *et al*: A human homologue of the *Drosophila eyes absent* gene underlies Branchio-Oto-Renal (BOR) syndrome and identifies a novel gene family. *Nat Genet* 15: 157-164, 1997.
- Vincent C, Kalatzis V, Abdelhak S, Chaib H, Compain S, Helias J, Vaneecclo FM and Petit C: BOR and BO syndromes are allelic defects of EYA1. *Eur J Hum Genet* 5: 242-246, 1997.
- Ruf RG, Xu PX, Silvius D, Otto EA, Beekmann F, Muerb UT, Kumar S, Neuhaus TJ, Kemper MJ, Raymond RM Jr, *et al*: SIX1 mutations cause branchio-oto-renal syndrome by disruption of EYA1-SIX1-DNA complexes. *Proc Natl Acad Sci USA* 101: 8090-8095, 2004.
- Hoskins BE, Kramer CH, Silvius D, Zou D, Raymond RM, Orten DJ, Kimberling WJ, Smith RJ, Weil D, Petit C, *et al*: Transcription factor SIX5 is mutated in patients with branchio-oto-renal syndrome. *Am J Hum Genet* 80: 800-804, 2007.

6. Kumar S, Deffenbacher K, Marres HA, Cremers CW and Kimberling WJ: Genomewide search and genetic localization of a second gene associated with autosomal dominant branchio-oto-renal syndrome: Clinical and genetic implications. *Am J Hum Genet* 66: 1715-1720, 2000.
7. Vogt EC: Congenital esophageal atresia. *Am J Roentgenol* 22: 463-465, 1929.
8. Depaepe A, Dolk H and Lechat MF: The epidemiology of tracheo-esophageal fistula and oesophageal atresia in Europe. EUROCAT Working Group. *Arch Dis Child* 68: 743-748, 1993.
9. De Jong EM, Douben H, Eussen BH, Felix JF, Wessels MW, Poddighe PJ, Nikkels PG, de Krijger RR, Tibboel D and de Klein A: 5q11.2 deletion in a patient with tracheal agenesis. *Eur J Hum Genet* 18: 1265-1268, 2010.
10. Motoyama J, Liu J, Mo R, Ding Q, Post M and Hui CC: Essential function of Gli2 and Gli3 in the formation of lung, trachea and oesophagus. *Nat Genet* 20: 54-57, 1998.
11. Shapiro MB and Senapathy P: RNA splice junctions of different classes of eukaryotes: Sequence statistics and functional implications in gene expression. *Nucleic Acids Res* 15: 7155-7174, 1987.
12. Desmet FO, Hamroun D, Lalande M and Collod-Bérout G, Claustres M and Bérout C: Human splicing finder: An online bioinformatics tool to predict splicing signals. *Nucleic Acids Res* 37: e67, 2009.
13. Eisner A, Pazyra-Murphy MF, Durreesi E, Zhou P, Zhao X, Chadwick EC, Xu PX, Hillman RT, Scott MP, Greenberg ME and Segal RA: The *eya1* phosphatase promotes shh signaling during hindbrain development and oncogenesis. *Dev Cell* 33: 22-35, 2015.
14. Stockley TL, Mendoza-Londono R, Propst EJ, Sodhi S, Dupuis L and Papsin BC: A recurrent *EYA1* mutation causing alternative RNA splicing in branchio-oto-renal syndrome: Implications for molecular diagnostics and disease mechanism. *Am J Med Genet A* 149A: 322-327, 2009.
15. Krug P, Morinière V, Marlin S, Koubi V, Gabriel HD, Colin E, Bonneau D, Salomon R, Antignac C and Heidet L: Mutation screening of the *EYA1*, *SIX1* and *SIX5* genes in a large cohort of patients harboring branchio-oto-renal syndrome calls into question the pathogenic role of *SIX5* mutations. *Hum Mutat* 32: 183-190, 2011.
16. Song MH, Kwon TJ, Kim HR, Jeon JH, Baek JI, Lee WS, Kim UK and Choi JY: Mutational analysis of *EYA1*, *SIX1* and *SIX5* genes and strategies for management of hearing loss in patients with BOR/BO syndrome. *PLoS One* 8: e67236, 2013.
17. Bekheirnia MR, Bekheirnia N, Bainbridge MN, Gu S, Coban Akdemir ZH, Gambin T, Janzen NK, Jhangiani SN, Muzny DM, Michael M, *et al*: Whole-exome sequencing in the molecular diagnosis of individuals with congenital anomalies of the kidney and urinary tract and identification of a new causative gene. *Genet Med* 19: 412-420, 2017.
18. Firat Y, Şireci Ş, Yakinci C, Akarçay M, Karakaş HM, Firat AK, Kizilay A and Selimoğlu E: Isolated preauricular pits and tags: Is it necessary to investigate renal abnormalities and hearing impairment? *Eur Arch Otorhinolaryngol* 265: 1057-1060, 2008.
19. Johnston JJ, Olivos-Glander I, Killoran C, Elson E, Turner JT, Peters KF, Abbott MH, Aughton DJ, Aylsworth AS, Bamshad MJ, *et al*: Molecular and clinical analyses of greig cephalopolysyndactyly and pallister-hall syndromes: Robust phenotype prediction from the type and position of *GLI3* mutations. *Am J Hum Genet* 76: 609-622, 2005.
20. Johnston JJ, Sapp JC, Turner JT, Amor D, Aftimos S, Aleck KA, Bocian M, Bodurtha JN, Cox GF, Curry CJ, *et al*: Molecular analysis expands the spectrum of phenotypes associated with *GLI3* mutations. *Hum Mutat* 31: 1142-1154, 2010.
21. Yang L, Shen C, Mei M, Zhan G, Zhao Y, Wang H, Huang G, Qiu Z, Lu W and Zhou W: De novo *GLI3* mutation in esophageal atresia: Reproducing the phenotypic spectrum of *Gli3* defects in murine models. *Biochim Biophys Acta* 1842: 1755-1761, 2014.
22. Al-Qattan MM, Shamseldin HE, Salih MA and Alkuraya FS: *GLI3*-related polydactyly: A review. *Clin Genet*, 2017.
23. Lu K, Reddy R, Berika M, Warburton D and El-Hashash AH: Abrogation of *Eya1/Six1* disrupts the saccular phase of lung morphogenesis and causes remodeling. *Dev Biol* 382: 110-123, 2013.
24. Lewandowski JP, Du F, Zhang S, Powell MB, Falkenstein KN, Ji H and Vokes SA: Spatiotemporal regulation of *GLI* target genes in the mammalian limb bud. *Dev Biol* 406: 92-103, 2015.
25. Wang C, Gargollo P, Guo C, Tang T, Mingrin G, Sun Y and Li X: *Six1* and *Eya1* are critical regulators of peri-cloacal mesenchyme progenitors during genitourinary tract development. *Dev Biol* 360: 186-194, 2011.
26. El-Hashash AH, Al Alam D, Turcatel G, Bellusci S and Warburton D: Eyes absent 1 (*Eya1*) is a critical coordinator of epithelial, mesenchymal and vascular morphogenesis in the mammalian lung. *Dev Biol* 350: 112-126, 2011.
27. Zaret KS: Genetic programming of liver and pancreas progenitors: Lessons for stem-cell differentiation. *Nat Rev Genet* 9: 329-340, 2008.
28. Korzh S, Winata CL, Zheng W, Yang S, Yin A, Ingham P, Korzh V and Gong Z: The interaction of epithelial *Ihha* and mesenchymal *Fgf10* in zebrafish esophageal and swimbladder development. *Dev Biol* 359: 262-276, 2011.
29. Hajduk P, Murphy P and Puri P: *Fgf10* gene expression is delayed in the embryonic lung mesenchyme in the adriamycin mouse model. *Pediatr Surg Int* 26: 23-27, 2010.
30. Sala FG, Del Moral PM, Tiozzo C, Al Alam D, Warburton D, Grikscheit T, Veltmaat JM and Bellusci S: *FGF10* controls the patterning of the tracheal cartilage rings via *Shh*. *Development* 138: 273-282, 2011.
31. Spilde T, Bhatia A, Ostlie D, Marosky J, Holcomb G III, Snyder C and Gittes G: A role for sonic hedgehog signaling in the pathogenesis of human tracheoesophageal fistula. *J Pediatr Surg* 38: 465-468, 2003.