SPANDIDOS PUBLICATIONS

ONCOLOGY LETTERS 4: 682-684, 2012

Facial reconstruction with a bone-anchored prosthesis following destructive cancer surgery

MONICA C.P. MELLO, JOAQUIM AUGUSTO OLIVEIRA PIRAS, ROBERTO M. TAKIMOTO, ONIVALDO CERVANTES, MÁRCIO ABRAHÃO and LUCIANO L. DIB

Department of Otorhinolaryngology and Head and Neck Surgery, Federal University of São Paulo, Paulista School of Medicine, São Paulo, Brazil

Received March 6, 2012; Accepted June 15, 2012

DOI: 10.3892/ol.2012.816

Abstract. Reconstruction of craniofacial defects following cancer surgery may be performed using several techniques and materials. This case report describes surgery for a large tumor, as well as the rehabilitation process which involved a craniofacial prosthesis covering the whole defect of the anterior brain, orbit, mid-face and hard palate. The results suggest that a craniofacial prosthesis anchored on titanium implants is a viable alternative as a retention system, and also a good alternative to other reconstructive surgeries.

Introduction

Treatment for head and neck cancer is usually performed using a combination of radiotherapy, chemotherapy and surgery. Following surgery, patients are often left with large defects in the craniofacial region, with reduced sensory and motor function in several organ systems (1). Rehabilitation can be performed using different grafting procedures and/or prosthetic techniques (2,3). In this case report, the large craniofacial defect was rehabilitated by a bone-anchored prosthesis (1).

Case report

In 2002, a 54-year-old male sought care at different public service centers with a one-year symptom of headaches on the left side of the cranium, together with nausea and vomiting. He had no previous history of disease. He was a retired person and was not aware of any exposure to any hazardous drugs or chemical products during his working life, although he had smoked for 30 years. At clinical examination, he presented with rhinorrea and protrusion of the left eye, although his vision was normal. However, after one month the patient did not return for follow-up and to receive the planned treatment. In June 2004, 2 years after the first consultation, the patient returned with a large tumor on the left side of the face that had developed extensively since the previous examination (Fig. 1A). The initial diagnosis had been a maxillary sinus inverted polyp, which in 10% of cases transforms into a squamous cell carcinoma (4). After the period of extensive growth, when the patient returned for consultation, the radiograph of the maxillofacial region indicated an expansive process in the left maxilla with destruction of the medial and lateral bone. Following a biopsy, the histopathological results revealed a malignant neoplasm which originated in the epithelial cells from the mucosa of the maxillary left sinus. The malignant cells were thought to be moderately differentiated. The tumor was invasive and metastases were observed in certain cervical lymph nodes in the surrounding areas. The final diagnosis was squamous cell carcinoma (Fig. 1A).

A CT scan, followed by an MRI scan, revealed a solid tumor measuring 8.5x8.0x7.5 cm. As mentioned previously, the tumor originated in the left maxillary sinus, where there was a squamous cell carcinoma invading the orbit and destroying the anterior, medial and posterior bone of the maxilla, orbital bone walls, nasal cavity, pterygopalatine fossa, hard palate and masticatory muscles. There was also a destruction of bone in the anterior cranial fossa, and the tumor was advancing towards the brain tissue (Fig. 1B).

The tumor classification was: T4, N0, M0, stage 4. Endoscopy of the nose, epipharynx and oral cavity also revealed a large squamous cell carcinoma originating in the maxillary sinus mucosa. Surgery was performed immediately. A pericoronal flap was used to access the tumor and perform resection.

The tumor resection also included a maxillectomy of the left side, removal of the left orbit and left nasal cavity, and left side ethymoidectomy (Fig. 2). The resection of all cervical lymph nodes on the tumor side was also necessary, as metastasis was detected during the surgery and also in the frozen biopsies. The left tumor cavity was closed with skin flaps following resection but a perforation was left in the hard palate. The surgical result was acceptable.

The patient was administered postoperative radiotherapy 20 days after surgery. Radiation was performed with Cobalt^{60}

Correspondence to: Ms. Monica C.P. Mello, Department of Dentistry Clinic Implantology, Federal University of São Paulo, Paulista School of Medicine, 714 São Guater Avenue, São Paulo 05455001, Brazil
E-mail: monicapitymello@hotmail.com

Key words: cancer, rehabilitation facial, prosthesis, extraoral implants

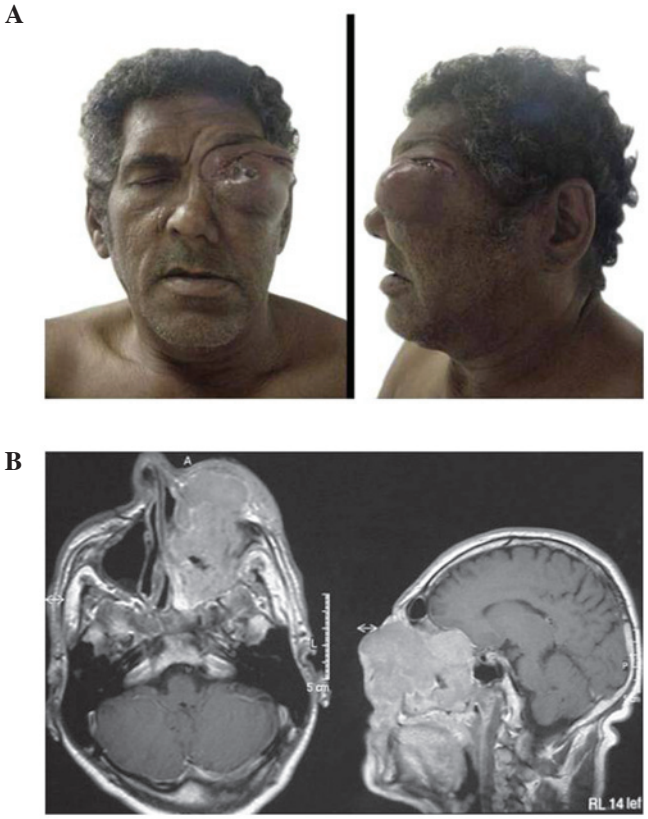

Figure 1. (A) Clinical status of tumor prior to surgery and radiotherapy. (B) MRI of the patient shows tumor originating in maxillary sinus and destruction of bone in the nose, ethmoid, orbit, palate and frontal part of brain.

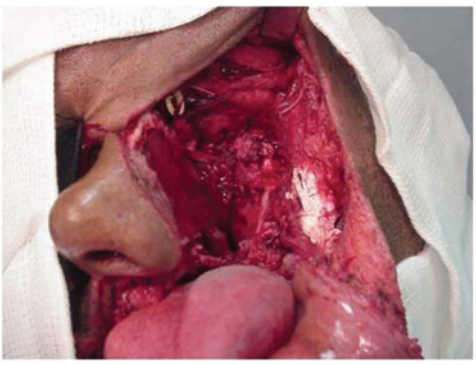

Figure 2. A cranial incision was used to access the tumor.

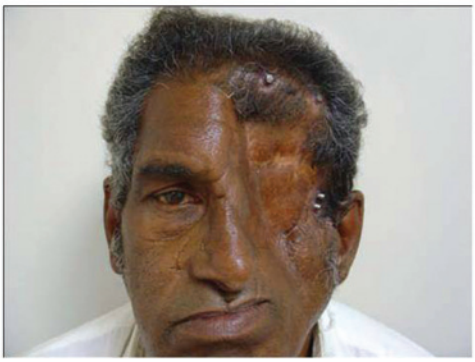

Figure 3. At implant surgery, five fixtures were installed in the frontal bone, temporal bone and zygoma.

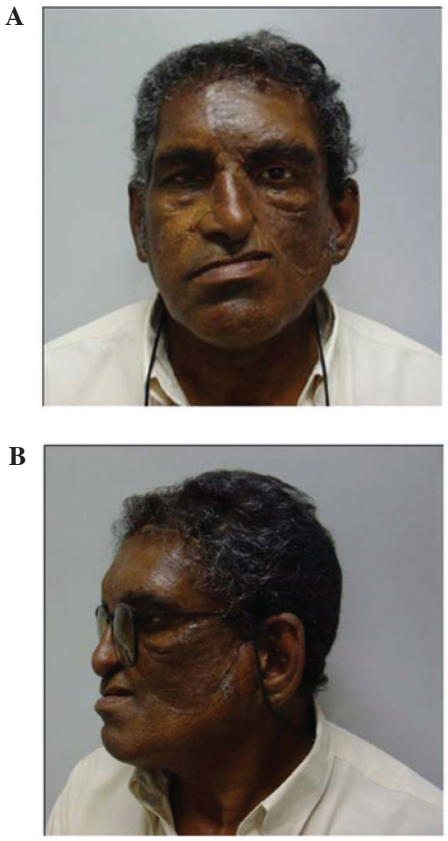

Figure 4. (A) Frontal projection of patient wearing the prosthesis. (B) Lateral projection of patient with facial prosthesis in place.

using a linear accelerator at a total dose of 60 Gy for 30 days. Postoperative chemotherapy was also administered using cisplatin and 5-fluorouracil, in 3 cycles. The patient had difficulties with swallowing, eating and drinking during the first 30 days. Following his recovery, a dental prosthesis was constructed to close the nasopalatal perforation. This prosthesis was replaced after the postoperative period, as the swelling of the tissue had diminished. With the new prosthesis, the patient could eat, swallow and speak without problems. He also regained weight in the months following the treatment while wearing the full dentures.

The patient experienced some side effects from the radiotherapy, including dermatitis in the tumor cavity and mucosal necrosis of the hard palate. After postoperative healing a facial reconstructive treatment started. The patient was followed up regularly for many years considering the possible tumor recurrence. He was given full dentures with a maxillary obturator to allow him to eat and speak with greater ease. When the patient remained tumor-free after 5 years of follow-up, a new facial prosthesis was planned, to be anchored by titanium implants fixed at the remanescent bone. A CT scan with 3-D reconstruction was performed to optimize treatment planning with extra-oral implants and a special cosmetic prosthesis.

In 2009, the implant surgery was performed. This was undertaken under general anesthesia. During the surgery, five fixtures (Conexão Sistema de Proteses®, Sao Paulo, Brazil), were installed, two in the frontal bone (6 mm in length), one in the zygoma (7 mm) and two in the temporal bone (3 and 4 mm

in length, respectively; Fig. 3). Following implant surgery and a healing period of 6 months, the second phase of surgery was performed using abutment connection. This surgery was also undertaken under general anesthesia. Standard abutments 4 mm in length (Conexão Sistema de Proteses) were attached to the osseointegrated implants and the subcutaneous tissue thickness was reduced.

Following the implant surgery, there was a healing period of three weeks, then preparation of the facial prosthesis started. An impression of the tumor defect was taken and a model was constructed from plaster of Paris. The prosthesis had an acrylic base and was attached to the abutments with magnets. The prosthesis was sculptured in wax and made in one piece. The edges of the wax model were very thin to facilitate the acquisition of the skin color, as well as to blend with the silicon prosthesis. The final prosthesis was made of silicon [LSR-4340 Silicone Elastomer, Rhodia (Factor II; Lakeside, AZ, USA)]. It was colored by Functional Intrinsic II Silicone Coloring System (Factor II). The right side of the patient's face was used as the model for the professional to achieve the appropriate colour. Rayon Fiber Flocking (Factor II) was used to mimic minor blood vessels. The cosmetic result was good (Figs. 4A and B). The patient has been followed up since the fitting of the prosthesis. He is now able to go out and socialize as before. His functions are also good; he can speak, eat, chew and swallow without problems and is a good singer. There was no recurrence of the tumor until the last follow-up some months ago, and he is wearing the prosthesis daily. Taking into account the treatment for the malignant tumor as well as the prosthetic reconstruction, we consider this to be a successful clinical case, particularly given the extreme nature of the surgery and extent of the tissue destruction. The prosthesis has allowed the patient to have almost a normal life. In addition, the patient has survived for over 5 years, which is very uncommon.

Discussion

Head and neck cancer surgery may be mutilating, leaving the patient with large craniofacial defects; however, such surgery may be necessary in order to save the patient's life. Radiotherapy and chemotherapy contribute to cancer treatment, but in certain cases these treatments may only be performed following surgery, as they may affect tissues and alter the healing process (1,2). Rehabilitation following cancer therapy may therefore be compromising in several ways, and lead to complications such as reduced healing capacity, wound infections, graft necrosis and implant failures.

There are many aspects to be considered when rehabilitating a cancer patient with large bone and soft tissue defects. The patient may have a limited life expectancy due to the cancer, as it may recur and/or metastasize. Also, the patient may have other diseases that affect rehabilitation. The use of a facial prosthesis allows inspection of the area to check for possible cancer recurrence. Anchoring the prosthesis on extra-oral implants is secure for the patient in comparison to anchoring it by glue (1,3).

Rehabilitation is not only useful for improved cosmetic appearance but also helps to promote function and social rehabilitation (5). In a case such as this, it was important to close the defect of the hard palate with a dental prosthesis to improve speech, chewing and swallowing function. Secondly, it was important to cover the frontal part of the brain with the facial prosthesis. This can be done in several ways; for example, by bone grafting or by covering the defect with a titanium or acrylic plate. By utilizing modern techniques for 3-D imaging and rapid prototyping, well-fitting plates can be constructed and implanted (4).

Difficult cases such as the one presented here are rare and in such cases rehabilitation should not be standardized but should be planned and performed individually (6). When there is sufficient bone left in the region, extra-oral osseointegrated implants may be used to improve the retention of the facial prosthesis. If there is insufficient bone, different grafting procedures may be performed to correct the defect (4). One of the advantages of the prosthetic solution is that it allows the possibility to inspect the tumor cavity in order to check for possible future tumor recurrences (7). If such a recurrence occurs, it is necessary for the patient to undergo complementary treatment for the tumor. If a patient has been tumor-free for many years, as happened in the present case, he/she is not disqualified from other rehabilitation procedures, although this is very uncommon.

Currently, alternatives to reconstructive surgery and prosthetic rehabilitation could be achieved by partial or total facial transplantation. A number of cases have been identified in the last five years, some of which have been published (4). The long-term outcome of these techniques is yet not clear, and the possible side effects from the postoperative immunosuppressants are also not known. However, a patient that has been rehabilitated with bone-anchored prosthesis is not excluded from receiving a future facial transplantation or grafting procedure.

References

1. Gentile P, Nicoli, F, Caruso R, Gravante G and Cervelli V: Alternative strategy to reconstruct the nose after excision: extra-oral implant anchored to bone. Br J Oral Maxillofac Surg 47: 50-51, 2009.
2. Müller A, Krishnan KG, Uhl E and Mast G: The application of rapid prototyping techniques in cranial reconstruction and preoperative planning in neurosurgery. J Craniofac Surg 14: 899-914, 2003.
3. Wolfaardt J, Wilkes G and Granström G: Craniofacial reconstruction. In: The Osseointegration Book. From Calvarium to Calcaneus. Brånemark P-I (ed). Quintessence Publishing Co, Chicago, pp387-418, 2005.
4. Lee JT, Bhuta S and Castro DJ: Isolated inverting papilloma of the sphenoid sinus. Laryngoscope 113: 41-44, 2003.
5. Gliklich RE, Rounds MF, Cheney ML and Varvares MA: Combining free flap reconstruction and craniofacial prosthetic technique for orbit, scalp, and temporal defects. Laryngoscope 108: 482-487, 1998.
6. Granström G, Andersson L, Kahnberg KE and Pogrel MA: Compromized wound healing. In: Oral and Maxillofacial Surgery. Andersson L, Kahnberg KE and Pogrel MA (eds). Wiley and Sons, 171-176, 2010.
7. Guntinas-Lichius O: Outcomes 18 months after the first human partial face transplantation. N Engl J Med 358: 79-80, 2008.