SPANDIDOS PUBLICATIONS

ONCOLOGY LETTERS 5: 360-362, 2013

Sporadic renal haemangioblastoma: Case report and review of the literature

YADONG WANG[1*], CAN WEI[1*], LISHA MOU[2], QIANG ZHANG[1], ZHIWEN CUI[1], XIANXIN LI[1], JIONGXIAN YE[3] and YONGQING LAI[1]

[1]Department of Urology; [2]Guangdong Key Laboratory of Male Reproductive Medicine and Genetics, Peking University Shenzhen Hospital, Shenzhen PKU-HKUST Medical Center, Shenzhen 518036; [3]Hong Kong University Shenzhen Hospital, Shenzhen 518053, P.R. China

Received June 23, 2012; Accepted September 14, 2012

DOI: 10.3892/ol.2012.942

Abstract. Haemangioblastoma is a benign tumour which generally occurs in a relatively restricted area of the central nervous system. Renal haemangioblastoma are extremely rare. We report a rare case of renal haemangioblastoma occurring in a 61-year-old male with a solid mass, which was detected during a routine examination. The patient was asymptomatic and abdominal computed tomography (CT) revealed a solid mass in the right kidney. No definitive preoperative diagnosis could be established. Surgical resection of the tumour revealed sporadic renal haemangioblastoma by pathological examination. The patient was followed up at 1 year without any problems. We also present a supplementary review of previously published cases and literature.

Introduction

Haemangioblastoma is a slowly growing, highly vascular solid mass of uncertain histogenesis, also known as capillary haemangioblastoma (1). It typically occurs within the central nervous system (CNS), predominantly in the cerebellum (2). Renal haemangioblastoma is an extremely uncommon disease with a poorly established diagnosis due to a lack of descriptions of typical symptoms. To the best of our knowledge, there are 6 cases reported previously (Table I) (3,4). In the present study, we report the case of a patient with haemangioblastoma involving the kidney, which may be mistaken for other renal tumours, in particular renal cell carcinoma (RCC). The study was approved by the ethics committee of Peking University Shenzhen Hospital, Shenzhen, China. Written informed patient consent was obtained from the patient.

Correspondence to: Professor Jiongxian Ye, Hong Kong University Shenzhen Hospital, Baishi Road, Shenzhen 518053, P.R. China
E-mail: yjx66@126.com

Professor Yongqing Lai, Department of Urology, Peking University Shenzhen Hospital, 1120 Lianhua Road, Shenzhen 518036, P.R. China
E-mail: yqlord@163.com

*Contributed equally

Key words: haemangioblastoma, von Hippel-Lindau disease, renal neoplasm

Case report

A 61-year-old male, who was found to have a right renal tumour during a routine examination, was admitted to our department for further examination on April 20, 2011. The patient was asymptomatic with a normal appetite, no abdominal pain and no weight changes. The patient had no urinary, respiratory or cardiovascular symptoms, no constitutional symptoms and had not previously undergone surgery. His family history was unremarkable. Physical examination revealed a well-developed and well-nourished male. The patient was afebrile and had a pulse of 66 beats per min, temperature 36.7˚C, blood pressure 120/60 mmHg and respiration 20 per min. The chest was clear to percussion and auscultation and no masses were palpable on abdominal examination.

Laboratory examination revealed that haemoglobin was 12.3 g/dl, white blood cell count was 7.21×10^9/l, with 61.4% granulocytes. Glucose was 5.88 mmol/l, blood urea nitrogen was 8.25 mmol/l and serum creatinine was 82.2 μmol/l. Liver function tests and serum electrolytes were within normal limits. Urinalysis was unremarkable. Chest X-ray was normal. A non-contrast computed tomography (CT) scan of the kidneys revealed a 6.5x6.2-cm round hypodense mass [48.2-54.2 Hounsfield units (HU)] in the upper pole of the right kidney (Fig. 1A and B). A contrast-enhanced CT revealed a heterogeneously enhanced mass with a non-enhanced hypodense region in the centre (Fig. 1C and D).

A right radical nephrectomy was performed on April 25, 2011. Tumour invasion to the adjacent tissue was not observed. Grossly, the tumour was a solid and well-encapsulated mass 6.5 cm in diameter. Microscopic examination revealed polygonal cells diffusely positive for α-inhibin, neuron-specific enolase (NSE) and S100 and confirmed renal haemangioblas-

Table I. Reported cases of renal haemangioblastoma.

Case	Author	Year	Age (years)/ gender	Chief complaint	Size (cm)	Clinical features	VHL (yes/no)	Immunohistochemical staining	Follow-up (months) prognosis
1	Nonaka	2007	71/female	Asymptomatic	6.8	Right renal upper pole	No	S100$^+$, SMA$^+$, MSA$^+$, calponin$^+$, vimentin$^+$	108, without disease
2	Ip	2010	58/male	Haematuria and polycythaemia	5.5	Right renal upper pole	No	S100$^+$, NSE$^+$, α-inhibin$^+$	24, alive
3	Ip	2010	55/female	Low back pain	3.5	Right renal upper pole	No	S100$^+$, NSE$^+$, α-inhibin$^+$	48, alive
4	Verine	2011	64/male	Other disease	3.2	Left renal upper pole	No	CA-IX$^+$, S100$^+$, NSE$^+$, α-inhibin$^+$	12, no recurrence
5	Wang	2012	29/male	Other disease	2.7	Right renal	No	S100$^+$, NSE$^+$, α-inhibin$^+$	20, without disease
6	Liu	2012	16/female	Haematuria	1.2	Left renal upper pole	No	AE1/AE3$^-$, S100$^+$, NSE$^+$, α-inhibin$^+$	6, no recurrence
7	Present	2012	61/male	Checkup	6.5	Right renal upper pole	No	S100$^+$, NSE$^+$, α-inhibin$^+$	12, no recurrence

VHL, von Hippel-Lindau; NSE, neuron-specific enolase.

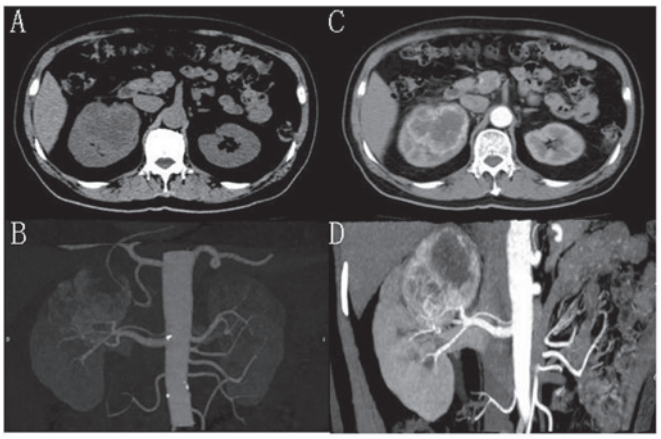

Figure 1. Computed tomography (CT) scan of kidneys. (A and B) A 6.5x6.2-cm round hypodense mass [48.2-54.2 Hounsfield units (HU)] in the upper pole of the right kidney (non-contrast CT); (C and D) a heterogeneously enhanced mass with a non-enhanced hypodense region in the centre.

toma. There was no clinical evidence of von Hippel-Lindau (VHL) disease. Magnetic resonance imaging (MRI) revealed no other tumours.

The patient was discharged on the fifth postoperative day after an uncomplicated post-surgical recovery. No evidence of recurrence or residual disease appeared on CT scans at follow-up (1 year).

Discussion

Capillary haemangioblastoma is a benign tumour of uncertain histogenesis that generally occurs in a relatively restricted area of the CNS (2). In microscopic views, the tumours may exhibit significant nuclear pleomorphism, mimicking carcinoma or other malignancies (1,2). A majority of cases arise sporadically, whereas 25% are a manifestation of VHL disease (5). This tumour typically occurs within the CNS, predominantly in the cerebellum (2). Haemangioblastoma has also been rarely reported in sites outside of the CNS, including peripheral nerves, liver, lung, pancreas, retroperitoneum, kidney, pancreas, bladder, soft tissues of the ankle and popliteal fossa and nasal skin, usually in the setting of known VHL disease (6).

There are only a few studies concerning sporadic haemangioblastoma occurring outside the central nervous system. Sporadic renal haemangioblastoma are extremely rare, with only 6 cases reported previously (3,4). We describe the 7th sporadic renal haemangioblastoma. The diagnosis in the present case was based on the presence of typical morphology and immunophenotype (S100$^+$, NSE$^+$, α-inhibin$^+$) (5).

CT scanning, with and without the administration of contrast material, is necessary to take full advantage of the contrast enhancement characteristics of highly vascular renal parenchymal tumours. In general, any renal mass that enhances with intravenous administration of contrast material on CT scanning by more than 15 HU should be considered an RCC until proven otherwise (7). In this patient, a contrast-enhanced CT revealed a heterogeneously enhanced mass (more than 20 HU; Fig. 1). The mass was thus highly suggestive of RCC. Until now, characteristic imaging features of renal haemangioblastoma remained unknown (3,5).

Haemangioblastoma is likely to be an underrecognised tumour of the kidney as it mimics numerous tumour types morphologically and is usually not considered in the differential diagnosis (8). A correct diagnosis is important for patients as haemangioblastoma is a benign disease, unlike malignant RCC (3). It is not necessary for patients with sporadic renal haemangioblastoma to receive further treatment (e.g., molecular targeted therapy) and their follow-up is different from that of patients with RCC (3).

We report a solid lesion of the kidney found to be a sporadic renal haemangioblastoma. Our review of published studies revealed only 6 cases reported previously. Haemangioblastoma is likely to be an underrecognised tumour of the kidney, as it mimics a number of tumour types morphologically and is usually not considered in the differential diagnosis. A correct diagnosis is important to avoid overdiagnosis and unnecessary clinical treatment.

Acknowledgements

This study was supported by the National Natural Science Foundation of China (No. 81101922).

References

1. Karabagli H, Karabagli P, Alpman A and Durmaz B: Congenital supratentorial cystic hemangioblastoma. Case report and review of the literature. J Neurosurg 107 (Suppl 6): 515-518, 2007.
2. Hussein MR: Central nervous system capillary haemangioblastoma: the pathologist's viewpoint. Int J Exp Pathol 88: 311-324, 2007.
3. Wang CC, Wang SM and Liau JY: Sporadic hemangioblastoma of the kidney in a 29-year-old man. Int J Surg Pathol: Jan 23, 2012 (Epub ahead of print).
4. Liu Y, Qiu XS and Wang EH: Sporadic hemangioblastoma of the kidney: a rare renal tumor. Diagn Pathol: May 1, 2012 (Epub ahead of print).
5. Ip YT, Yuan JQ, Cheung H and Chan JK: Sporadic hemangioblastoma of the kidney: an underrecognized pseudomalignant tumor? Am J Surg Pathol 34: 1695-1700, 2010.
6. Verine J, Sandid W, Miquel C, Vignaud JM and Mongiat-Artus P: Sporadic hemangioblastoma of the kidney: an underrecognized pseudomalignant tumor? Am J Surg Pathol 35: 623-624, 2011.
7. Zagoria RJ and Dyer RB: The small renal mass: detection, characterization, and management. Abdom Imaging 23: 256-265, 1998.
8. Nonaka D, Rodriguez J and Rosai J: Extraneural hemangioblastoma: a report of 5 cases. Am J Surg Pathol 31: 1545-1551, 2007.