

Pregnancy-induced hypertension caused by all-*trans* retinoic acid treatment in acute promyelocytic leukemia: A case report

KUI SONG¹ and MIN LI²

Departments of ¹Hematology and ²Pharmacy, The First Affiliated Hospital of Jishou University, Jishou, Hunan 416000, P.R. China

Received July 16, 2014; Accepted March 25, 2015

DOI: 10.3892/ol.2015.3190

Abstract. A 23-year-old pregnant female presented with fever and diarrhea during the sixth month of gestation. The patient was diagnosed with acute promyelocytic leukemia (APL) at 26 weeks gestation and was treated with all-*trans* retinoic acid (ATRA) at an initial dose of 45 mg/m²/day, which was reduced to 25 mg/m²/day 14 days later. The patient experienced chest distress, polypnea, hypertension, general dropsy and dysfunction of the kidneys and heart on day 3 of the treatment, which suggested pregnancy-induced hypertension. Intrauterine fetal demise was apparent on day 8. A cesarean delivery was performed, however, intrauterine fetal mortality had occurred. A favorable outcome was achieved for the patient following treatment, although hematological complete remission was slow. To the best of our knowledge, the present study is the first to describe an APL patient with pregnancy-induced hypertension following treatment with ATRA, and thus ATRA remains a suitable for therapy for APL during pregnancy.

Introduction

Acute leukemia is a rare comorbidity during pregnancy, with an incidence of 1 in 100,000 pregnancies (1). Acute promyelocytic leukemia (APL), a subtype of acute myelogenous leukemia (AML), is a far more rare disease, accounting for 10-15% of all adult AMLs (2). A diagnosis is confirmed by morphological analysis, and immunological and cytogenetic studies (3). In total, ~40 cases of APL during pregnancy or in the postpartum period have so far been reported (4).

Current therapies, including all-*trans* retinoic acid (ATRA) and anthracycline-based induction, and anthracycline-based consolidation and maintenance, have been proven to be extremely effective, with 5-year disease-free survival rates

of 70-80% (5). However, ATRA has certain side-effects, a number of which may be fatal. The present study describes the case of a pregnant patient with APL and pregnancy-induced hypertension following the administration of ATRA. Written informed consent was obtained from the patient.

Case report

A 23-year-old female (gravida 2, para 1) was admitted to hospital during the sixth month of gestation with symptoms of fever and diarrhea that had been apparent for 4 days. The results of a routine blood test were abnormal, with a white blood cell count of 1.44x10⁹/l (normal range, 4.0-10.0x10⁹/l), a neutrophil value of 0.68% (normal range, 50-70%), a hemoglobin level of 95 g/l (normal range, 110-150g/l) and a platelet count of 31x10⁹/l (normal range, 100-300x10⁹/l). The results of the blood cell count that had been performed during an antenatal examination two months prior had been normal. The patient was transferred to The First Affiliated Hospital of Jishou University (Jishou, China) on August 12, 2008. A physical examination revealed tenderness of the sternum, a pot belly and mild dropsy in the lower extremities.

Blood chemistry on admission revealed 5.5 g/dl total protein (normal range, 60.0-80.0 g/l) and 28 g/l albumin (normal range, 40.0-55.0 g/l). Urine protein (++) , 75 μmol/l serum creatinine (normal range, 44-97 μmol/l) and 4.7 mmol/l blood urea nitrogen levels (normal range, 3.2-7.1 mmol/l) were within the normal limits. The International Organized Ratio was 0.9, the activated partial thromboplastin time was normal (32 sec; control, 36 sec), the level of fibrinogen (FIB) was reduced to 0.8 g/l (normal range, 2.0-4.0 g/l), and the level of fibrin degradation products (FDP) was elevated to 40±80 mg/ml (normal range, 0±10 mg/ml). In addition, the level of D-Dimers was increased to 988 mg/l (normal range, 0±0.3 mg/l). A bone marrow examination revealed that >70% of the marrow cells were abnormal promyelocytic cells (Fig. 1). A chromosomal abnormality, t(15;17), and an abnormal fusion gene product, promyelocytic leukemia-retinoic acid receptor α (PML-RARα), were detected by fluorescence *in situ* hybridization (Fig. 2). A diagnosis of APL, AML French-American-British classification M3, was established. The patient was subsequently treated with 45 mg/m²/day ATRA at 26 weeks gestation. Within 4 days, the white blood cell count rose to 20x10⁹/l, the hemoglobin level increased to 98.5 g/l, the platelet count reached 46x10⁹/l, the

Correspondence to: Dr Min Li, Department of Pharmacy, The First Affiliated Hospital of Jishou University, Shiji Avenue, Jishou, Hunan 416000, P.R. China
E-mail: zs_hematology@163.com

Key words: pregnancy-induced hypertension, acute promyelocytic leukemia, all-*trans* retinoic acid

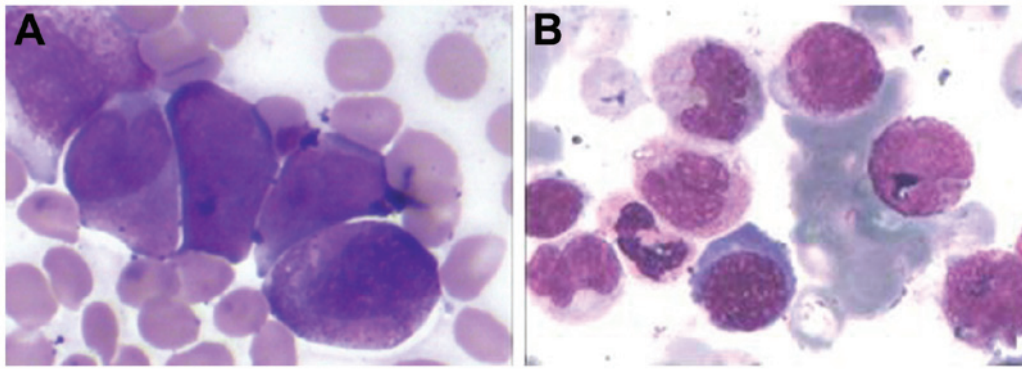


Figure 1. Bone marrow smear stained with Wright-Giemsa prior to and subsequent to treatment with ATRA. (A) Promyelocytes appearing in the bone marrow aspiration prior to treatment with ATRA (myeloblast, 2%; promyelocyte, 71.5%). (B) Complete remission was achieved on day 33 (myeloblast, 1.5%; promyelocyte, 1.5%). ATRA, all-*trans* retinoic acid.

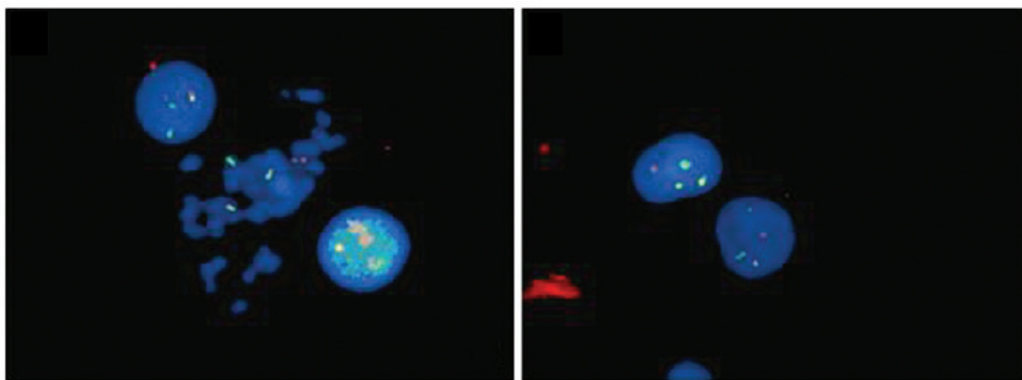


Figure 2. Fluorescence *in situ* hybridization analysis of a nucleus in metaphase was performed with a specific PML/RAR α dual-color DNA probe using 400 cells. t(15,17) was detected with a positive rate of 95%. A PML/RAR α fusion signal is shown by a yellow signal (PML in red and RAR α in green). PML, promyelocytic leukemia; RAR α , retinoic receptor α .

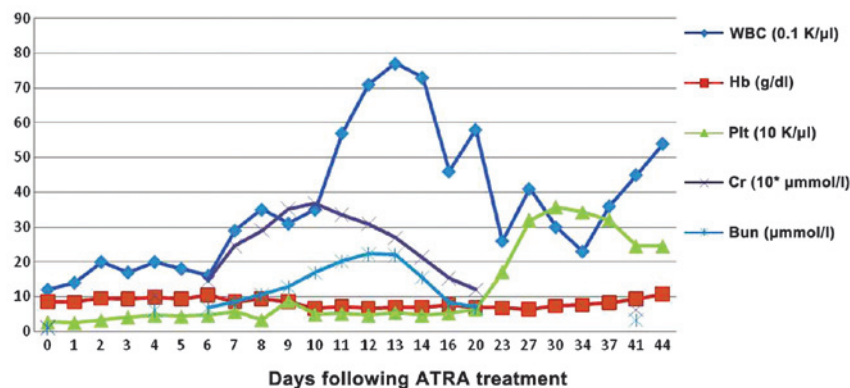


Figure 3. Changes to hemogram and renal function in the patient. Following ~20 days of treatment, the platelet count returned to normal and the renal function recovered completely. The hemoglobin level remained below the normal limit until day 54. The white cell count changed markedly prior to and subsequent to the surgery, and slowly returned to normal until day 44. WBC, white blood cell; Hb, hemoglobin; Plt, platelet; Cr, creatine; Bun, blood urea nitrogen.

level of FIB rose to 1.8 g/l and the level of FDP and D-dimers normalized. However, on day 3 of treatment with ATRA, the patient complained of chest distress and polypnea. A physical examination revealed dropsy all over the body and an elevated blood pressure (149/103 mmHg) and heart rate (110 bpm). Laboratory tests performed on the sixth day revealed a hemoglobin level of 103 g/l, a platelet count of 46×10^9 /l, a white blood cell count of 1.6×10^9 /l with 76.9% neutrophils, 28 g/l albumin,

246 μ mol/l blood creatinine and urine protein (++) . The patient was diagnosed with pregnancy-induced hypertension syndrome, rather than retinoic acid syndrome (RAS), following the presentation of pancytopenia. Fetal mortality *in utero* was established by ultrasonic inspection on the eighth day. A cesarean delivery was performed in order to terminate the pregnancy. Post-surgery, the patient's blood pressure and heart rate returned to normal. The dose of ATRA was reduced to

25 mg/m²/day from day 14. Although the recovery of peripheral blood was slow, bone marrow tests revealed complete remission morphologically and cytogenetically, with no PML-RARa fusion transcript expression on day 33. Hemogram remission was achieved on day 44 (Fig. 3).

Discussion

APL management is dependent upon the onset of pregnancy-induced hypertension. If a diagnosis is established during the first trimester, termination of the pregnancy followed by the induction of leukemia-targeted therapies should be discussed with the patient. As the pregnancy progresses into the second and third trimester, the decision becomes problematic (6). Surgery appears to be the optimal approach and the easiest to be accepted. When a decision has been reached, the importance of normalized clotting function should be emphasized to the patient. As disseminated intravascular coagulation (DIC) is the leading cause of mortality in M3 patients, correcting clotting function prior to abortion effectively decreases the risk of bleeding (7). In the present study, induced abortion under a condition of reduced FIB posed the risk of DIC and increased bleeding. Therefore, clotting function was corrected prior to the abortion. The clotting function had almost returned to normal within 4 days of ATRA treatment. However, the symptoms became progressively worse and intrauterine fetal mortality occurred. This was believed to be associated with severe anemia. Fortunately, the patient survived the abortion and achieved bone marrow complete remission on day 26 of continuous ATRA treatment.

Although ATRA is an effective drug for the treatment of APL, a number of side-effects, including hypercalcemia, male infertility, bone marrow necrosis and fibrosis, acute pancreatitis, acute damage of the liver and kidneys, erythema nodosum, hyperhistaminemia, granulomatous proliferation, and certain pulmonary complications may occur. In addition, ATRA confers the risk of severe teratogenicity to the fetus during pregnancy (8). However, data concerning the use of ATRA in pregnancy is limited. Previous studies demonstrated that ATRA was reasonably safe and well tolerated if not administered during the first trimester of pregnancy. However, the most common maternal side-effect of ATRA is the potentially lethal RAS, which is characterized by fever, dyspnea, pulmonary infiltrates, pleural or pericardial effusion and episodic hypotension (9). In the present study, similar symptoms presented during ATRA treatment. However, due to the presentation of pancytopenia, a diagnosis of RAS was not made. Instead, due to no previous history of chronic hypertension, urinary tract infection or renal disease, or additional complaints of polypnea or palpitation, the symptoms were more likely to have resulted from hypertension in pregnancy induced by treatment with ATRA. An APL patient with ATRA-induced hypertension during pregnancy has not been

previously reported. Therefore, data concerning diagnoses and therapeutic policies were limited.

Pregnancy-induced hypertension is a maternal hypertension syndrome diagnosed during the later part of pregnancy, usually after the 20th week of gestation (10). Due to the prompt aggravation of the function of the kidneys and heart, it was suggested that the pregnancy-induced hypertension in the present study may have resulted from ATRA management. This is because pregnancy-induced hypertension is less frequently observed in the second trimester of pregnancy, and heart failure is rare in clinical course (11). In addition, the ATRA treatment may have initiated or aggravated the pregnancy-induced hypertension during the administration process. Therefore, it was concluded that the pregnancy-induced hypertension in the present study resulted from ATRA treatment.

To the best of our knowledge, limited data exists with regard to the treatment of such patients. In the present study, the patient demonstrated a good response to the treatment. It is important for clinicians to carefully consider the administration of ATRA, particularly in APL patients who are pregnant.

References

1. Murrin RJ, Adjety V, Harrison P and Warwick A: Acute promyelocytic leukaemia presenting as postpartum haemorrhage. *Clin Lab Haematol* 26: 233-237, 2004.
2. Tallman MS: The expanding role of arsenic in acute promyelocytic leukemia. *Semin Hematol* 45 (3 Suppl 2): S25-S29, 2008.
3. Sham RL and Tallman MS: Treatment of acute promyelocytic leukemia in the very elderly: Case report and review of the literature. *Leuk Res* 28: 1347-1350, 2004.
4. Carradice D, Austin N, Bayston K and Ganly PS: Successful treatment of acute promyelocytic leukaemia during pregnancy. *Clin Lab Haematol* 24: 307-311, 2002.
5. Lo-Coco F, Ammatuna E, Montesinos P and Sanz MA: Acute promyelocytic leukemia: Recent advances in diagnosis and management. *Semin Oncol* 35: 401-409, 2008.
6. Fadilah SA, Hatta AZ, Keng CS, Jamil MA and Singh S: Successful treatment of acute promyelocytic leukemia in pregnancy with all-trans retinoic acid. *Leukemia* 15: 1665-1666, 2001.
7. Morimatsu Y, Matsubara S, Hirose N, Ohkuchi A, Izumi A, Ozaki K, Ozawa K and Suzuki M: Acute promyelocytic leukemia: An unusual cause showing prolonged disseminated intravascular coagulation after placental abruption. *Arch Gynecol Obstet* 277: 267-270, 2008.
8. Giagounidis AA, Beckmann MW, Giagounidis AS, Aivado M, Emde T, Germing U, Riehs T, Heyll A and Aul C: Acute promyelocytic leukemia and pregnancy. *Eur J Haematol* 64: 267-271, 2000.
9. Tallman MS, Andersen JW, Schiffer CA, Appelbaum FR, Feusner JH, Ogden A, Shepherd L, Rowe JM, François C, Larson RS and Wiernik PH: Clinical description of 44 patients with acute promyelocytic leukemia who developed the retinoic acid syndrome. *Blood* 95: 90-95, 2000.
10. Satpathy HK, Fleming A, Frey D, Barsoom M, Satpathy C and Khandalavala J: Maternal obesity and pregnancy. *Postgrad Med* 120: E01-E09, 2008.
11. Alwan S, Polifka JE and Friedman JM: Angiotensin II receptor antagonist treatment during pregnancy. *Birth Defects Res A Clin Mol Teratol* 73: 123-130, 2005.