SPANDIDOS PUBLICATIONS

ONCOLOGY LETTERS 10: 3756-3760, 2015

Expression of Skp2 and p27^{kip1} proteins in hypopharyngeal squamous cell carcinoma and its clinical significance

LIANSHENG QIU[1], JIABAO LV[2], YIMIN CHEN[1], JIARONG WANG[1] and RUISHAN WU[1]

[1]Department of Otorhinolaryngology, The Second Affiliated Hospital of Fujian Medical University, Quanzhou, Fujian 362000; [2]Department of Otorhinolaryngology, The Second Hospital of Xiamen, Xiamen, Fujian 361000, P.R. China

Received September 27, 2014; Accepted May 20, 2015

DOI: 10.3892/ol.2015.3799

Abstract. The aim of the present study was to determine the effect of S-phase kinase-associated protein 2 (Skp2) and cyclin-dependent kinase inhibitor p27$^{kinase\text{-}interacting\ protein\ 1}$ (p27^{kip1}) protein expression on the occurrence and development of hypopharyngeal squamous cell carcinoma. The protein expression levels of Skp2 and p27^{kip1} were detected in 42 hypopharyngeal squamous cell carcinoma and 15 normal hypopharyngeal mucous membrane specimens using the an immunohistochemical PV-9000 two-step method. The expression levels of Skp2 protein were significantly different in hypopharyngeal squamous cell carcinomas and normal hypopharyngeal mucous membranes (61.90 vs. 26.67%; P<0.05). By contrast, the protein expression levels of Skp2 were significantly positively correlated with tumor T stage (r_s=0.329, P<0.05) and cervical lymph node metastasis (r_s=0.402, P<0.05). Furthermore, the expression levels of p27^{kip1} protein were significantly different in hypopharyngeal squamous cell carcinomas and normal hypopharyngeal mucous membranes (11.9 vs. 53.33%; P<0.05), while p27^{kip1} protein expression was significantly negatively correlated with tumor T-stage (r_s=-0.351, P<0.05) and cervical lymph node metastasis (r_s=-0.371, P<0.05). Notably, a significant negative correlation was observed between the expression levels of Skp2 and p27^{kip1} proteins in hypopharyngeal squamous cell carcinoma (P<0.05). In addition, abnormal expression levels of Skp2 and p27^{kip1} proteins were observed in hypopharyngeal squamous cell carcinoma tissues. Thus, Skp2 and p27^{kip1} proteins may be involved in the development of hypopharyngeal squamous cell carcinoma. The current study proposed that combined detection of Skp2 and p27^{kip1} may be useful for assessing the characteristics and prognosis of hypopharyngeal squamous cell carcinoma.

Correspondence to: Professor Liansheng Qiu, Department of Otorhinolaryngology, The Second Affiliated Hospital of Fujian Medical University, 34 Zhongshan North Road, Quanzhou, Fujian 362000, P.R. China
E-mail: lianshengqiu@126.com

Key words: hypopharyngeal carcinoma, cancer, squamous cell, S-phase kinase-associated protein 2, cyclin-dependent kinase inhibitor p27$^{kinase\text{-}interacting\ protein\ 1}$, immunohistochemistry

Introduction

The major features of malignant cancer are uncontrolled cell growth and proliferation, while cell cycle disorder is an important pathogenesis mechanism. The primary function of S-phase kinase-associated protein 2 (Skp2) is its role as the substrate recognition subunit of ubiquitin ligase complex by specific recognition of the phosphorylated substrate, and its ability to mediate ubiquitin ligase complex polyubiquitination and degradation (1,2). Cyclin-dependent kinase (CDK) inhibitor (CKI), p27$^{kinase\text{-}interacting\ protein\ 1}$ (p27^{kip1}), is an important negative regulator of the cell cycle (1). As a well-recognized tumor suppressor gene, it is able to control cell cycle transition from G_1 to S phase. Thus far, various cell cycle regulators have been identified, including the tumor suppressor p27^{kip1}, p21^{wafl}, cyclin A and p53, all of which may be degraded via the Skp2-mediated ubiquitin-proteasome pathway (2,3). Thus, Skp2 is key in the p27^{kip1} ubiquitin degradation pathway and may inhibit the proliferation of a variety of cell types through the ubiquitin-proteasome pathway (4-7). Skp2 and p27^{kip1} have been to demonstrated to exhibit varying degrees of abnormal expression in a number of solid tumors, including lung cancer (8), oesophageal squamous cell carcinoma and oral squamous cell carcinoma (9,10), laryngeal squamous cell carcinoma (11) and breast cancer (12). They are considered to be closely associated with the occurrence, development and prognosis of malignant tumors (8-12). The expression levels of Skp2 and p27^{kip1} proteins have rarely been investigated in hypopharyngeal squamous cell carcinoma. Therefore, the present study used immunohistochemistry to detect the expression of Skp2 and p27^{kip1} proteins in normal hypopharyngeal mucosa and hypopharyngeal squamous cell carcinoma tissues. The correlation between their expression, and the occurrence and development of hypopharyngeal squamous cell carcinoma, as well as clinical and pathological features, was then analyzed.

Materials and methods

Specimen collection. Hypopharyngeal squamous cell carcinoma specimens (n=42) were obtained from patients treated at the Second Affiliated Hospital of Fujian Medical University (Quanzhou, China) between January 1996 and February 2009. A diagnosis of hypopharyngeal squamous cell carcinoma was confirmed by pathological examination. No

patients underwent radiotherapy or chemotherapy prior to the surgery. The 42 cases included 39 males and 3 females, and the median age was 54.8 years. Approval for the present study was obtained from the Ethics Committee of Fujian Medical University. Written informed consent was obtained from all the participants. According to different primary focus of tumors, 21 cases occurred in the piriform sinus, 15 occurred in the posterior wall and 6 in the postcricoid area. According to the differentiation degrees, there were 15 well-differentiated, 17 moderately-differentiated and 10 poorly-differentiated cancer cases. In addition, 37 cases exhibited cervical lymph node metastasis, while 5 cases did not present metastasis. According to the 2002 classification criteria of the Union for International Cancer Control TNM staging system (13), there were 15 T1/T2 stage and 27 T3/T4 stage cases, including T1N0M0 (2 cases), T1N1M0 (1 case), T2N0M0 (2 cases), T2N1M0 (3 cases), T2N2M0 (7 cases),; T3N0M0 (2 cases), T3N1M0 (8 cases), T3N2M0 (9 cases), T4N0M0 (1 case), T4N1M0 (2 cases), T4N2M0 (3 cases) and T4N3M0 (2 cases). Normal hypopharyngeal mucous membranes without cancer cells were identified by observation from the piriform sinus or postcricoid area of specimens obtained during total laryngectomy and used as the control group. Specimens were obtained from 15 patients with laryngeal carcinoma who underwent total laryngectomy at the Second Affiliated Hospital of Fujian Medical University. The specimens were located 3-4 cm from the tumor margin. The patients included 14 males and 1 female, and had an age range of 47-71 years (mean age, 59.1 years). There was no significant difference in age or gender between the control and experimental groups. The normal tissue samples (n=15) were confirmed to be healthy hypopharyngeal mucous membranes by performing a hematoxylin and eosin staining assay.

Immunohistochemical assay. The immunohistochemical assay used a PV-9000 (SP) two-step staining kit (Zhongshan Jinqiao Biotechnology Co., Ltd., Beijing, China), according to the manufacturer's instructions. p27^{kip1} and Skp2 rat anti-human monoclonal antibodies (1:40 dilutions; catalog nos. ZM-0340 and ZM-0454, respectively), polymer helper and polyperoxidase anti-rat IgG (1:100 dilution) were all purchased from Zhongshan Jinqiao Biotechnology Co., Ltd. Furthermore, breast cancer tissue specimens (ZSGB-BIO Co., Ltd., Beijing, China) were used as the positive control and phosphate-buffered saline (PBS) was used as the negative control.

Analysis of experimental results. To analyze the results of the current study, Skp2 positive cell counts were performed in a minimum of 10 fields per sample under an optical microscope (magnification, x400; BX51; Olympus Corporation, Tokyo, Japan). In the positive cells counts, ≥100 tumor cells were present in each field. According to a previous study (8), Skp2-positive cells were visualized as brown-yellow particles in the nucleus and negative control cells were normal hypopharyngeal mucous membranes in close proximity to the tumor tissues. Skp2 protein expression was classified as follows: <5% positive cells, (-); 6-25% positive cells, (+); 26-50% positive cells, (++); and >50% positive cells, (+++). Furthermore, >25% positive cells represented a high expression of Skp2.

Table I. Comparison of Skp2 and p27^{kip1} protein expression levels in hypopharyngeal squamous cell carcinoma tissue and normal hypopharyngeal mucous membrane samples.

	High expression, n		
Index	Hypopharyngeal squamous cell carcinoma	Normal hypopharyngeal mucous membrane	P-value
Skp2	26	4	0.019
p27^{kip1}	5	8	0.002

Skp2, S-phase kinase-associated protein 2; p27^{kip1}, p27$^{kinase\text{-}interacting\ protein\ 1}$.

For the expression of p27^{kip1}, positive cells were visualized as brown-yellow particles in the nucleus. p27^{kip1} protein expression was classified as follows: 0% positive cells, (-); <5% positive cells, (+); 5-50% positive cells, (++); and >50% positive cells, (+++). Furthermore, >50% positive cells represented a high expression of p27^{kip1} . All the results were evaluated by two experienced pathologists using a double-blinded method.

Statistical analysis. Statistical analyses were performed using the SPSS software (version 13.0; SPSS, Inc., Chicago, IL, USA) and data are presented as the mean ± standard deviation. χ^2 and Fisher's tests were used to compare data between the groups, while Spearman's rank correlation analysis was used for data correlation. P<0.05 was considered to indicate a statistically significant difference.

Results

Skp2 and p27^{kip1} protein expression levels. Immunohistochemical staining revealed that Skp2 protein, which was visualized as brown-yellow particles, was predominantly located in the nucleus and rarely located in the cytoplasm (Fig. 1). High Skp2 protein expression was observed in 61.90% (26/42 samples) and 26.67% (4/15 samples) of hypopharyngeal squamous cell carcinoma tissues and normal hypopharyngeal mucous membranes, respectively. Thus, the expression of Skp2 protein was significantly higher in hypopharyngeal squamous cell carcinoma compared with that in normal hypopharyngeal mucous membranes (P<0.05). The expression levels of Skp2 and p27kip1 proteins in normal hypopharyngeal mucosa of the control group were not significantly correlated (χ^2=1.26, Pearson coefficient of continency, C=0.2756). p27^{kip1} protein presented as brown-yellow particles located in the nucleus (Fig. 2). Weak p27^{kip1} expression was observed in hypopharyngeal squamous cell carcinoma tissues, with only 5 cases exhibiting high expression. In addition, high p27^{kip1} protein expression was observed in 11.90% (5/42) and 53.33% (8/15) of hypopharyngeal squamous cell carcinoma tissues and normal hypopharyngeal mucous membranes, respectively. This difference was statistically significant (P<0.05; Table I).

Correlation of Skp2 and p27^{kip1} protein expression levels with clinicopathological characteristics. No statistically

Table II. Association of high Skp2 and $p27^{kip1}$ protein expression with clinicopathological characteristics in patients with hypopharyngeal squamous cell carcinoma.

		Skp2		$p27^{kip1}$	
Pathological characteristic	Case, n	High expression, n	P-value	High expression, n	P-value
Gender					
Male	39	26	0.049	4	0.323
Female	3	0		1	
Age, years					
≥60	11	6	0.720	1	1.000
<60	31	20		4	
Cervical lymph node metastasis					
+	37	26	0.005	2	0.008
-	5	0		3	
Primary location of the tumor[a]					
Piriform sinus	21	12	>0.0125	3	>0.0125
Postcricoid area	6	4		1	
Posterior wall	15	10		1	
T stage					
T1 + T2	15	6	0.029	4	0.047
T3 + T4	27	20		1	
Differentiation degree					
High to moderate	32	18	0.270	3	0.577
Low	10	8		2	

[a]Calculated using a χ^2 test. The expression of Skp2 protein was compared between the piriform sinus and the postcricoid area (P=1.000), the piriform sinus and the posterior wall (P=0.563), and the postcricoid area and the posterior wall (P=1.000). Overall, no statistically significant difference was observed (P>0.0125). In addition, the expression of $p27^{kip1}$ protein was compared between the piriform sinus and the postcricoid area (P=1.000), the piriform sinus and the posterior wall (P=0.626), and the postcricoid area and the posterior wall (P=0.500). Overall, no statistically significant difference was observed (P>0.0125). Skp2, S-phase kinase-associated protein 2; $p27^{kip1}$, $p27^{kinase\text{-}interacting\ protein\ 1}$.

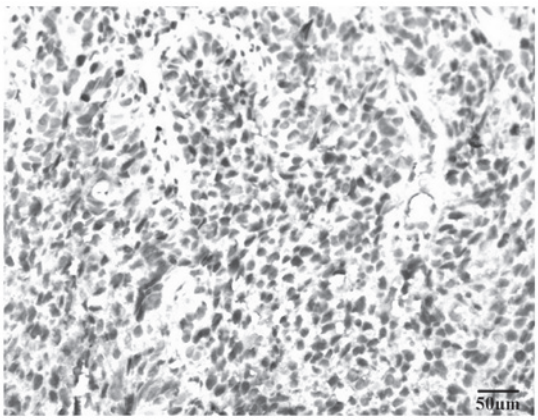

Figure 1. Positive immunohistochemical expression of S-phase kinase-associated protein 2 in hypopharyngeal squamous cell carcinoma tissues (scale bar, 50 μm). Streptavidin-peroxidase staining; magnification, x200.

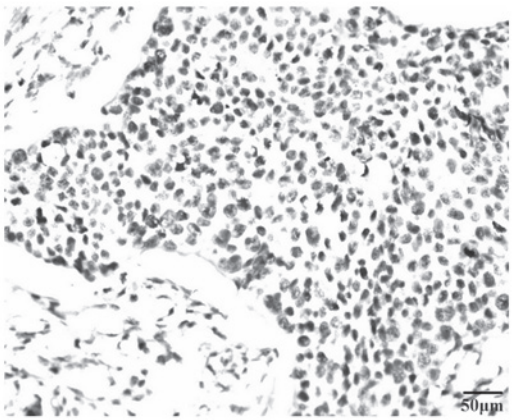

Figure 2. Positive immunohistochemical expression of cyclin-dependent kinase inhibitor, $p27^{kinase\text{-}interacting\ protein\ 1}$, in hypopharyngeal squamous cell carcinoma tissues (scale bar, 50 μm). Streptavidin-peroxidase staining; magnification, x200.

significant differences were detected between the age or differentiation degree of patients and the expression of Skp2 protein (P>0.05). However, a significant difference was identified between gender and the expression of Skp2 protein (P<0.05). Despite this significant association, the study population had a 1:13 female : male ratio and the P-value was close to 0.05. Thus, the present authors consider that there may be no significant difference between gender and the expression of Skp2 protein. Notably, there was an significant difference between high expression of Skp2 protein and cervical lymph

Table III. Association between Skp2 and p27^{kip1} protein expression in hypopharyngeal squamous cell carcinoma.

	p27^{kip1} expression, n			
Skp2 expression	High	Low	P-value	r_s
High	1	25		
Low	4	12	0.041	-0.317

Skp2, S-phase kinase-associated protein 2; p27^{kip1}, p27$^{kinase-interacting protein 1}$; r_s, Spearman's correlation coefficient.

node metastasis (P<0.01), as well as between T stage and the high expression of Skp2 protein (P<0.05). Spearman's rank correlation analysis indicated that the expression of Skp2 protein was positively correlated with cervical lymph node metastasis [Spearman's correlation coefficient (r_s)=0.402, P<0.01] and T staging (r_s=0.033, P<0.05) in hypopharyngeal squamous cell carcinoma.

The present study also identified no significant correlation between the gender, age and differentiation degree of patients, and the expression of p27^{kip1} protein (P>0.05). However, low expression of p27^{kip1} protein was significantly associated with cervical lymph node metastasis (P<0.01) and T stage (P<0.05). Furthermore, Spearman's rank correlation analysis indicated that the expression of p27^{kip1} protein was negatively correlated with cervical lymph node metastasis (r_s=-0.016, P<0.05) and T stage (r_s=-0.351, P<0.05) in hypopharyngeal squamous cell carcinoma (Table II).

Correlation analysis between Skp2 and p27^{kip1} protein expression levels. Spearman's rank correlation analysis indicated that there was a negative correlation between the high expression of Skp2 protein and low expression of p27^{kip1} protein in hypopharyngeal squamous cell carcinoma (r_s=-0.317, P=0.041; Table III).

Discussion

Skp2 was initially cloned from human fibroblasts in 1995 (13). Skp2 is predominantly located in the S phase of malignant cells and reacts with the cyclin A-CDK complex; thus, it is termed S-phase kinase-associated protein 2. Skp2 behaves as an oncogene in cell systems and is an established protooncogene causally involved in the pathogenesis of lymphomas. Skp2 expression, encoded by the *Skp2* gene, appears to be closely correlated with the occurrence and development of carcinomas through binding to various targeting ubiquitinated proteins (2,14). Furthermore, it has been demonstrated that numerous cell cycle proteins exert their effects via a Skp2-dependent ubiquitin proteasome signaling pathway, including cyclin D1, cyclin E, p27^{kip1} and p53 (2,3). Thus, Skp2 specifically may be involved in the regulation of cell proliferation and apoptosis (15). In addition, Skp2 acts as oncogene through the degradation of p27^{kip1}, with the expression of Skp2 and p27^{kip1} differing in each stage of the cell cycle. Typically, Skp2 expression initially occurs during the G_1-S phase, increases at the S-G_2 phase and then quickly decreased at the M phase. A number of previous studies have indicated that p27^{kip1} is specifically recognized and targeted for ubiquitination by Skp2 (15,16). For instance, Skp2 may recognize the cyclin E-CDK2 and cyclin D-CDK2 complexes, causing phosphorylation of threonine-187 in p27 (15,16). Skp2 is particularly important for regulating the degradation of p27^{kip1} in the G_1-S phase. Disorder of cell cycle regulation is a critical molecular biological event in tumorigenesis; thus, cell cycle regulating factors may be relevant to tumorigenesis. For example, CKIs exhibit negative effects on cell cycle regulation. In particular, p27^{kip1}, which a member of the CKI family functioning as a negative regulating factor of the cell cycle, may play a key role in cell proliferation. Currently, p27^{kip1} is known as a tumor-suppressing gene (17). A previous study proposed that mutations of the p27 gene are rare in tumors (18); however, abnormal p27 protein expression was observed in the tumors investigated in the present study. This abnormal expression may be the result of low gene transcription or high protein activity. Various tumors, including colon cancer, rectum cancer, cervical carcinoma, oral squamous cell carcinoma, gastric cancer, lung cancer and prostatic cancer, have been found to exhibit a high expression of Skp2 protein but low expression of p27^{kip1} protein (19,20), and a negative correlation was identified between Skp2 and p27^{kip1} protein expression (8-12). Furthermore, tumor malignancy and prognosis were correlated with Skp2 expression (21,22).

In the present study, 26/42 samples (61.9%) exhibited Skp2 protein expression in hypopharyngeal squamous cell carcinoma tissues; however, Skp2 protein expression was low in 11/15 and high in 4/15 of normal hypopharyngeal mucous membranes. In addition, p27^{kip1} protein expression was observed in 5/42 (11.9%) samples of hypopharyngeal squamous cell carcinoma and high p27^{kip1} protein expression was observed in 8/15 (53.33%) samples of normal hypopharyngeal mucous membranes. This difference was statistically significance (P<0.05). Spearman's rank correlation analysis identified that overexpression of Skp2 protein was negatively correlated with low expression of p27^{kip1} protein in hypopharyngeal squamous cell carcinoma tissues (r_s=-0.317, P=0.041). The current results were similar to those of previous studies conducted (5,10), and indicate that Skp2 downregulates the expression of p27^{kip1} through ubiquitination in hypopharyngeal squamous cell carcinoma. Thus, high expression of Skp2 protein and low expression of p27^{kip1} protein may promote tumor cell progression from G_1 to S phase. p27^{kip1} is unable to effectively inhibit aberrant cell proliferation, but can accelerate cell malignancy (18,21). Therefore, it is proposed that Skp2 promotes the development of hypopharyngeal squamous cell carcinoma through degradation of p27^{kip1} protein.

In numerous malignant tumors, including gastric (8), breast (12), prostate (18) and colon cancer (8), increased Skp2 protein expression is observed concurrently with reduced p27^{kip1} protein expression. Increased Skp2 protein expression indicates a poorer prognosis and more highly-differentiated tumors. Furthermore, p27^{kip1} appears to be involved in regulating cell differentiation and intercellular adhesion, which are processes associated with tumor infiltration and metastasis, respectively. This may be due to lack of p27^{kip1} transcription or decreased p27^{kip1} protein expression causing inhibition of the cell proliferation, disorder of the cell cycle and low cell differentiation. Furthermore, p27^{kip1} regulates

intercellular adhesion by aggregating N-cadherin to prevent normal cells from binding to stroma or receiving extracellular signals (8,9,12,17,18). In a previous study, $p27^{kip1}$ protein expression caused a reduction in tumor cell adhesion and tumor metastasis (17). The current results demonstrated that high expression of Skp2 protein and low expression of $p27^{kip1}$ protein were significantly associated with cervical lymph node metastasis and T-stage in 42 samples of hypopharyngeal squamous cell carcinomas. Furthermore, correlation analysis identified a positive correlation between high expression of Skp2 protein, and cervical lymph node metastasis and T-stage, and a negative correlation between low expression of $p27^{kip1}$ protein, and cervical lymph node metastasis and T-stage. By contrast, the expression levels of Skp2 and $p27^{kip1}$ protein were not significantly associated with age, gender or differentiation degree ($P>0.05$). The aforementioned results were similar to those obtained in the present study, which indicated that high expression of Skp2 protein and low expression of $p27^{kip1}$ protein may aid in predicting the degree of tumor infiltration and cervical lymph node metastasis in hypopharyngeal squamous cell carcinoma. Furthermore, these two proteins may be useful for assessing the biological characteristics of hypopharyngeal squamous cell carcinoma.

However, Dowen *et al* (23) opposed the aforementioned theory that increased Skp2 protein expression decreases the expression of $p27^{kip1}$ protein. Instead, the authors proposed that the significance of high Skp2 protein expression in tumors was associated with the degradation of $p27^{kip1}$ protein, as well as other mechanisms, which may require further investigation.

In conclusion, Skp2 may degrade $p27^{kip1}$ protein through the ubiquitin-proteasome pathway, thus, participating in the occurrence and development of hypopharyngeal squamous cell carcinoma. Furthermore, the abnormal protein expressions Skp2 and $p27^{kip1}$ appear to be associated with the poor prognosis of hypopharyngeal squamous cell carcinoma. Therefore, combined detection of Skp2 and $p27^{kip1}$ may provide significant guidance for comprehensively determining the malignant degree and prognosis of patients with hypopharyngeal squamous cell carcinoma.

References

1. Slingerland J and Pagano M: Regulation of the cdk inhibitor p27 and its deregulation in cancer. J Cell Physiol 183: 10-17, 2000.
2. Inuzuka H, Gao D, Finley LW, *et al*: Acetylation-dependent regulation of Skp2 function. Cell 150: 179-193, 2012.
3. Ezoe S, Matsumura I, Nakata S, *et al*: GATA-2/estrogen receptor chimera regulates cytokine-dependent growth of hematopoietic cells through accumulation of p21(WAF1) and p27(Kip1) proteins. Blood 100: 3512-3520, 2002.
4. Sicari BM, Troxell R, Salim F, Tanwir M, Takane KK and Fiaschi-Taesch N: c-myc and skp2 coordinate p27 degradation, vascular smooth muscle proliferation, and neointima formation induced by the parathyroid hormone-related protein. Endocrinology 153: 861-872, 2012.
5. Dai DM and Zhu H: Expression of P27kip1 and Skp2 in basal cell carcinoma and its clinical pathological characters. Int Oncol 38: 158-160, 2011.
6. Suzuki S, Fukasawa H, Misaki T, *et al*: The amelioration of renal damage in Skp2-deficient mice canceled by p27kipl deficiency in Skp2-/-p27/-mice. PLoS One 7: e36249, 2012.
7. Nakayama K, Nagahama H, Minamishima YA, *et al*: Targeted disruption of Skp2 results in accumulation of cyclin E and p27(Kip1) polyploidy and centrosome overduplication. EMBO J 19: 2069-2081, 2000.
8. Gstaiger M, Jordan R, Lim M, Catzavelos C, Mestan J, Slingerland J and Krek W: Skp2 is oncogenic and overexpressed in human cancers. Proc Natl Acad Sci USA 98: 5043-5048, 2001.
9. Kudo Y, Kitajima S, Sato S, Miyauchi M, Ogawa I and Takata T: High expression of S-phase kinase-interacting protein 2, human F-box protein, correlates with poor prognosis in oral squamous cell carcinomas. Cancer Res 61: 7044-7047, 2001.
10. Shintani S, Li C, Mihara M, Hino S, Nakashiro K and Hamakawa H: Skp2 and Jab1 expression are associated with inverse expression of p27(KIP1) and poor prognosis in oral squamous cell carcinomas. Oncology 65: 355-362, 2003.
11. Dong Y, Sui L, Watanabe Y, Sugimoto K and Tokuda M: S-phase kinase-associated protein 2 expression in laryngeal squamous cell carcinomas and its prognostic implications. Oncol Rep 10: 321-325, 2003.
12. Signoretti S, Di Marcotullio L, Richardson A, *et al*: Oncogenic role of the ubiquitin ligase subunit Skp2 in human breast cancer. J Clin Invest 110: 633-641, 2002.
13. Patel SG and Shah JP: TNM staging of cancers of the head and neck: striving for uniformity among diversity. CA Cancer J Clin 55: 242-258, quiz 261-262, 264, 2005.
14. Zhang H, Kobayashi R, Galaktionov K and Beach D: p19Skp1 and p45Skp2 are essential elements of the cyclin A-CDK2 S phase kinase. Cell 82: 915-925, 1995.
15. Carrano AC, Eytan E, Hershko A and Pagano M: SKP2 is required for ubiquitin-mediated degradation of the CDK inhibitor p27. Nat Cell Biol 1: 193-199, 1999.
16. Yokoi S, Yasui K, Saito-Ohara F, *et al*: A novel target gene, SKP2, within the 5p13 amplicon that is frequently detected in small cell lung cancers. Am J Pathol 161: 207-216, 2002.
17. Coats S, Flanagan WM, Nourse J and Roberts JM: Requirement of p27Kip1 for restriction point control of the fibroblast cell cycle. Science 272: 877-880, 1996.
18. Nakatsuka S, Liu A, Yao M, *et al*: Methylation of promoter region in p27 gene plays a role in the development of lymphoid malignancies. Int J Oncol 22: 561-568, 2003.
19. Ewald JA and Jarrard DF: Decreased skp2 expression is necessary but not sufficient for therapy-induced senescence in prostate cancer. Transl Oncol 5: 278-287, 2012.
20. Rose AE, Wang G, Hanniford D, *et al*: Clinical relevance of SKP2 alterations in metastatic melanoma. Pigment Cell Melanoma Res 24: 197-206, 2011.
21. Baresova P, Pitha PM and Lubyova B: Kaposi sarcoma-associated herpesvirus vIRF-3 protein binds to F-box of Skp2 protein and acts as a regulator of c-Myc protein function and stability. J Biol Chem 287: 16199-16208, 2012.
22. Tschen SI, Georgia S, Dhawan S and Bhushan A: Skp2 is required for incretin hormone-mediated β-cell proliferation. Mol Endocrinol 25: 2134-2143, 2011.
23. Dowen SE, Scott A, Mukherjee G and Stanley MA: Overexpression of Skp2 in carcinoma of the cervix does not correlate inversely with p27 expression. Int J Cancer 105: 326-330, 2003.