SPANDIDOS PUBLICATIONS

ONCOLOGY LETTERS 12: 4821-4828, 2016

Prognostic significance of *AKR1B10* gene expression in hepatocellular carcinoma and surrounding non-tumorous liver tissue

FUMINORI SONOHARA[1,2], YOSHIKUNI INOKAWA[1,2], MITSUHIRO HISHIDA[1], MITSURO KANDA[1], YOKO NISHIKAWA[1], SUGURU YAMADA[1], TSUTOMU FUJII[1], HIROYUKI SUGIMOTO[1], YASUHIRO KODERA[1] and SHUJI NOMOTO[1,2]

[1]Department of Gastroenterological Surgery, Nagoya University Graduate School of Medicine, Nagoya, Aichi 466-8550; [2]Department of Surgery, Aichi-Gakuin University School of Dentistry, Nagoya, Aichi 464-8651, Japan

Received May 22, 2015; Accepted September 30, 2016

DOI: 10.3892/ol.2016.5240

Abstract. When assessing outcome in hepatocellular carcinoma (HCC), it is important to consider prognostic factors in background non-tumorous liver tissue as well as in the tumor, since multiple occurrence is associated with background liver status such as hepatitis. The current study aimed to elucidate molecular prognostic predictors that have an association with HCC background non-tumorous tissue. Microarray expression profiling identified aldo-keto reductase family 1, member B10 (*AKR1B10)* as a putative non-tumorous prognostic factor, and *AKR1B10* gene expression was investigated in 158 curatively resected HCC cases by reverse transcription-quantitative polymerase chain reaction. *AKR1B10* expression (*AKR1B10* value/*GAPDH* value x 1,000) was significantly higher in tumor tissue (median, 9.2200; range, 0.0003-611.0200; n=158) than in the corresponding non-tumorous tissue (median, 0.5461; range, 0.0018-69.0300; n=158) (P<0.001). When the samples were grouped according to *AKR1B10* expression in tumor tissue relative to non-tumorous tissue, tumor<non-tumorous expression (n=26) significantly correlated with poor recurrence-free survival (P=0.0074) and overall survival (OS) (P<0.0001), and was an independent prognostic factor for OS (P=0.0011) in a multivariate analysis. The ratio of AKR1B10 messenger RNA levels in HCC and corresponding non-tumorous tissues may predict prognosis after curative hepatectomy, with low expression in HCC tissue relative to non-tumorous tissue indicative of poor prognosis.

Correspondence to: Professor Shuji Nomoto, Department of Surgery, Aichi-Gakuin University School of Dentistry, 2-11 Suemori-dori, Chikusa-ku, Nagoya, Aichi 464-8651, Japan
E-mail: snomoto@dpc.agu.ac.jp

Key words: AKR1B10, hepatocellular carcinoma, hepatectomy, microarray analysis, prognosis

Introduction

Hepatocellular carcinoma (HCC) is the fifth most common malignancy and the third most common cause of cancer-related mortality worldwide (1). Although hepatectomy is one of the most effective options for HCC without distant metastases (2-4), 80% of HCC patients experience intrahepatic recurrence even after curative resection, and 50% die within 5 years (5). The types of intrahepatic recurrence are mainly divided into two types: Intrahepatic metastasis (IM), which involves the development of HCC foci from primary tumor cells and their spread to the remnant liver via the portal vein before or during hepatectomy; and multicentric occurrence (MO), which involves the development of new HCC foci due to chronic active hepatitis or cirrhosis provoked by viruses, alcohol, toxins or other HCC risk factors (6-9). In other words, when the clinicopathological factors for HCC recurrence are divided into two categories such as tumor factors and background liver factors, IM tends to be related to tumor factors and MO is rather related to background liver factors, since IM reflects the characteristics of the primary tumor and MO exhibits different genetic features from the primary lesions.

The clinical progression and outcomes of IM and MO differ significantly, as determined by several studies (8-10). Therefore, distinguishing between these conditions is important for designing therapeutic strategies and predicting prognosis. Usually, the pattern of HCC intrahepatic recurrence is determined histologically, but it is sometimes difficult to distinguish them (11). The present authors previously examined mutations in the mitochondrial genome (12) and hypermethylation in tumor suppressor gene promoters (13) in HCC, and found distinctions between MO and IM. Our findings suggested that MO was more common than IM. However, the study of another group demonstrated that the proportion of two recurrence patterns was almost the same (14). In any case, MO recurrence pattern makes HCC totally different from other solid carcinomas in view of recurrence.

Considering this unique MO pattern in HCC, simply focusing on tumor tissue is insufficient; comparison of tumor tissue and background non-tumorous liver tissue is also

Table I. Characteristic of patients with hepatocellular carcinoma (n=158).

Characteristic	Value
Age (years), median (range)	65 (37-84)
Sex (male:female), n (%)	132 (84):26 (16)
Viral infection (HBV:HCV:non-HBV/HCV), n (%)	41 (26):92 (58):28 (18)
Child-Pugh classification (A:B), n (%)	148 (94):9 (6)
Liver damage classification (A:B:C), n (%)	126 (83):25 (16):1 (1)
Albumin (mg/dl), median (range)	3.9 (2.3-4.9)
Total bilirubin, (mg/dl), median (range)	0.7 (0.2-7.3)
PT (%), median (range)	89.7 (46.9-138.0)
AFP (ng/ml), median (range)	17 (0.8-119,923.0)
Tumor size (cm), median (range)	3.50 (0.15-15.00)
Tumor number (single:multiple), n (%)	124 (78):34 (22)
ICG-R15 (%), median (range)	11.5 (1.6-35.2)
Japanese stage (I:II:III:IV), n (%)	17 (11):82 (52):40 (26):17 (11)

HBV, hepatitis B virus; HCV, hepatitis C virus; PT, prothrombin time; AFP, alpha-fetoprotein; ICG-R15, retention rate of indocyanine green 15 min after administration.

important. When genetic and epigenetic changes related to HCC carcinogenesis and recurrence are tried to be elucidated, many investigators have attempted to evaluate only tumor tissue. However, we hypothesized that molecular changes in the latter may directly cause MO or indirectly affect the malignancy of the primary HCC. The present study was designed to identify a unique molecular marker of HCC, perhaps in background non-tumorous liver tissue, and to assess the predictive value of the marker.

Materials and methods

Sample collection. For microarray analysis, non-tumorous liver tissue, referred to as for corresponding normal (CN), was obtained from a typical HCC patient during hepatectomy. The patient was a 58-year-old man; his HCC resulted from chronic hepatitis, and recurred 3 years after resection at Nagoya University Hospital (Nagoya, Japan). Pathology confirmed the absence of cancerous regions from the CN sample. As controls, non-cancerous liver tissue (not affected by hepatitis), referred to as super normal (SN), was obtained from 11 patients with liver metastases who underwent hepatectomy at Nagoya University Hospital. Their primary diseases were colorectal cancer (n=5), gastrointestinal stromal tumor (n=2), or gastric cancer, esophageal cancer, cervical cancer or tongue cancer (n=1 each). The samples were collected between January 1998 and December 2011

For reverse transcription-quantitative polymerase chain reaction (RT-qPCR) assays, HCC and CN tissue was collected from 158 consecutive patients who underwent curative primary hepatectomy at Nagoya University Hospital between January 1998 and December 2011. Median patient age was 65 years (range, 37-84 years), and the male:female ratio was 84:16. The median follow-up duration was 48.5 months (range, 0.3-193.8 months). Patient characteristics are summarized in Table I. All tumor tissue samples were histologically confirmed as HCC.

All surgically obtained tissue samples were immediately frozen in liquid nitrogen and stored at -80˚C until analysis. This study was approved by our institutional review board of at Nagoya University (Nagoya, Japan), and all patients provided written informed consent.

Microarray procedure. Total RNA was extracted from the CN and SN samples using a miRNeasy Mini-kit (Qiagen, Inc., Valencia, CA, USA). The 11 SN samples were mixed to eliminate individual differences. RNA integrity was assessed using an Agilent 2100 bioanalyzer (Agilent Technologies, Inc., Santa Clara, CA, USA); an RNA integrity number ≥8 was indicative of good quality RNA. RNA was labeled with cyanine-3 dye using a Quick Amp Labeling kit (Agilent Technologies, Inc.) and hybridized to Agilent whole human genome (4x44 K) microarrays (Agilent Technologies, Inc.) for 17 h in a rotating SciGene model 700 oven (SciGene, Sunnyvale, CA, USA). The arrays were scanned with a DNA microarray scanner (Agilent Technologies, Inc.), and the data were feature-extracted using Feature Extraction software 10.5.1.1 (Agilent Technologies, Inc.) and statistically analyzed using the default settings for GeneSpring GX 11.0.1 software (Agilent Technologies, Inc.) (15).

RT-qPCR. PCR was performed using SYBR Premix Ex Taq II (Takara Bio, Inc., Otsu, Japan) under the following conditions: 95˚C for 10 sec, and 40 cycles at 95˚C for 5 sec and 60˚C for 30 sec. The SYBR Green signal was detected in real time using a StepOne Plus Real-Time PCR system (Thermo Fisher Scientific, Inc., Waltham, MA, USA). The PCR primers used to generate a 144-bp fragment of *AKR1B10* were 5'-GTGGGG GAAGCCATCCAAGA-3' (sense, exon 2) and 5'-CAGCTT CAGGTCCTTGAGGG-3' (antisense, exon 3). The primers used to generate an 85-bp fragment of Ras-related protein Rab-25 (*RAB25)* were 5'-AAAGTGACCTCAGCCAGGCC-3' (sense, exon 3) and 5'-GTCTCCAGGAAGAGCAGTCC-3' (antisense, exon 4). The primers used to generate a 95-bp

Table II. Hepatocellular carcinoma-related genes identified in microarrays.

Gene	RefSeq accession #[a]	Fold change CN vs. SN	Regulation CN vs. SN	CN value	SN value	Flags[b] CN	Flags SN
AKR1B10	NM_020299	55.37	Up	14609.94	218.97	Detected	Detected
RAB25	NM_020387	43.96	Up	527.62	9.96	Detected	Not detected
EPB41L4B	NM_019114	36.51	Up	272.23	6.19	Detected	Not detected
LHFPL1	NM_178175	35.45	Up	290.66	6.80	Detected	Not detected

[a]RefSeq accession numbers were obtained from the National Center for Biotechnology Information (www.ncbi.nlm.nih.gov/nuccore/NM_020299.3, https://www.ncbi.nlm.nih.gov/nuccore/NM_020387, https://www.ncbi.nlm.nih.gov/nuccore/NM_019114 and https://www.ncbi.nlm.nih.gov/nuccore/NM_178175). [b]Flags indicate detectability of signal intensity. CN, corresponding normal; SN, super normal; *AKR1B10*, aldo-keto reductase family 1, member B10; *EPB41L4B*, erythrocyte membrane protein band 4.1 like 4B; *LHFPL1*, lipoma HMGIC fusion partner-like 1; *RAB25,* Ras-related protein Rab-25.

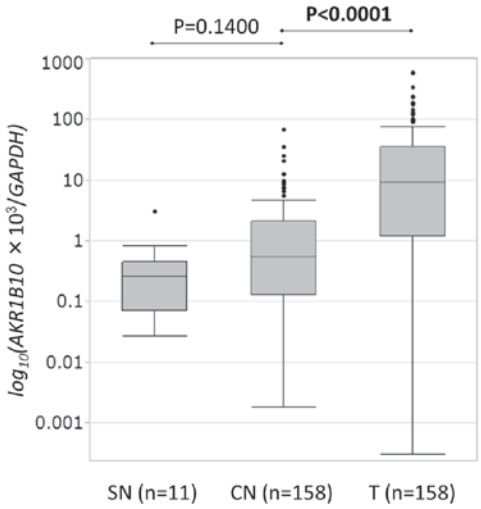

Figure 1. AKR1B10 messenger RNA levels in hepatocellular carcinoma and non-tumor tissue were quantified via reverse transcription-quantitative polymerase chain reaction. *AKR1B10* expression (*AKR1B10* score/GAPDH score x 1,000) was significantly higher in T tissue (median, 9.2200; range, 0.0003-611.0200; n=158) than in CN tissue (median, 0.5461; range, 0.0018-69.0300; n=158) (P<0.001). However, there was no significant difference between expression in CN tissue and SN tissue (median, 0.2616; range, 0.0272-3.1250; n=11 vs. median, 0.5461; range, 0.0018-69.0300; n=158, respectively) (P=0.1400). CN, corresponding normal; SN, super normal; T, tumor; AKR1B10, aldo-keto reductase family 1, member B10.

fragment of erythrocyte membrane protein band 4.1 like 4B (*EPB41L4B)* were 5'-AGCCTCTCACTGACCCTGGA-3' (sense, exon 19) and 5'-GCAGGTGTTCCTGGACTCAG-3' (antisense, exon 20). The primers used to generate a 145-bp fragment of lipoma HMGIC fusion partner-like 1 (*LHFPL1)* were 5'-GGCTGCTGATAAGCTCAGGC-3' (sense, exon 3) and 5'-GCTCCACCTCCAGCACAGTA-3' (antisense, exon 4). *GAPDH* expression was quantified in each sample for standardization purposes. The primers used to generate a 226-bp fragment of GAPDH were 5'-GAAGGTGAAGGTCGG AGTC-3' (sense) and 5'-GAAGATGGTGATGGGATTTC-3' (antisense). All RT-qPCR experiments were performed at least three times, including negative controls without a template. The absolute quantification method was used to determine input copy number, which is based on a standard curve, due to its advantages in studies with large sample numbers (16). The expression of each gene was calculated as follows: Value of the expressed gene/value of *GAPDH* x 10^3.

Statistical analysis. Continuous variables were expressed as median and range and compared using the Mann-Whitney *U*-test. Categorical variables were compared using the χ^2 or Fisher's exact tests, as appropriate. Recurrence-free survival (RFS) and overall survival (OS) rates were estimated using the Kaplan-Meier method and compared using the log-rank test. Univariate and multivariate Cox proportional hazards models were used to determine the independent risk factors associated with RFS and OS. All statistical analyses were performed using JMP Pro software version 11.0.0 (SAS International Inc., Cary, NC, USA). P-values are two-tailed, and P<0.05 was considered to indicate a statistically significant difference.

Results

Expression profiling via microarray analysis. To identify novel tumor-related genes in the normal liver tissue surrounding an HCC, the gene expression profiles of a CN sample and the pooled SN samples were compared. Microarray analysis revealed that *AKR1B10*, *RAB25*, *EPB41L4B* and *LHFPL1* were upregulated in the CN sample (Table II). We focused on *AKR1B10* as a CN-expressed prognostic factor.

RT-qPCR analysis of HCC and CN tissue. As determined via RT-qPCR, overall *AKR1B10* expression (expression score/*GAPDH* x 1,000) was significantly higher in HCC tissue (median, 9.2200; range, 0.0003-611.0200; n=158) than in CN tissue (median, 0.5461; range, 0.0018-69.0300; n=158) tissues (P<0.001). However, there was no significant difference in expression between SN and CN tissue (Fig. 1).

Correlation between AKR1B10 expression and the clinicopathological characteristics of HCC. *AKR1B10* expression significantly correlated with liver damage (Child-Pugh score B or C vs. A) (P=0.035) and capsule infiltration (P=0.0284) (Table III). For example, 18 of 26 cases with liver damage scores of B or C had significantly greater amounts of AKR1B10 messenger RNA (mRNA) in CN tissue than in HCC tissue.

Table III. Association between the clinicopathological characteristics of patients with hepatocellular carcinoma and *AKR1B10* expression.

	AKR1B10 expression		
Clinicopathological factor	T<CN	T≥CN	P-value
Age (years)			0.8321
≥65	13	69	
<65	13	63	
Gender			0.3191
Male	20	112	
Female	6	20	
Virus infection			0.9517
HCV	15	77	
Others	11	55	
Albumin (mg/dl)			0.1501
<3.5	8	24	
≥3.5	18	107	
PT (%)			0.3187
<70	5	14	
≥70	21	117	
ICG-R15 (%)			0.1183
≥15	7	22	
<15	10	73	
Liver cirrhosis			0.1092
(+)	5	50	
(-)	20	80	
Child-Pugh			0.1705
B	3	6	
A	23	125	
Liver damage			0.0305
B or C	8	18	
A	17	109	
Tumor number			0.6017
Multiple	4	30	
Solitary	22	102	
Tumor size (cm)			0.1264
≥2	24	103	
<2	1	22	
AFP (ng/ml)			0.0556
≥20	16	53	
<20	10	76	
Differentiation			1.0000
Poor	2	10	
Well/moderate	23	119	
Growth form			0.5454
Infiltrative	5	18	
Expansive	21	111	
Formation of capsule			0.1036
(-)	4	42	
(+)	22	90	
Infiltration to capsule			0.0284
(+)	19	69	
(-)	6	63	
Septal formation			0.2419
(-)	5	44	
(+)	19	86	
Serosal invasion			0.2108
(+)	8	26	
(-)	16	95	
Portal vein or hepatic vein invasion			0.8830
(+)	7	36	
(-)	19	91	
Surgical margin			0.7663
(+)	3	21	
(-)	21	102	
Japanese stage			0.7670
III/IV	9	49	
I/II	17	81	

Fisher's exact test or χ^2 test was applied as appropriate. T, tumor; CN, corresponding normal; HCV, hepatitis C virus; PT, prothrombin time; ICG-R15, retention rate of indocyanine green 15 min after administration; AFP, alpha fetoprotein; *AKR1B10*, aldo-keto reductase family 1, member B10.

Association between AKR1B10 expression and prognosis in 158 HCC cases. The clinical relevance of *AKR1B10* expression was assessed in terms of its prognostic ability in HCC. The 158 HCC cases were divided into two groups based on *AKR1B10* expression levels in HCC or CN tissue. Analysis of several pairings did not reveal any significant correlation between *AKR1B10* expression and RFS or OS. The cases were also grouped as follows: i) *AKR1B10* expression in HCC tissue was higher than or equal to *AKR1B10* expression in CN tissue (HCC≥CN, n=132) and ii) *AKR1B10* expression was lower in HCC tissue than in CN tissue (HCC<CN, n=26). The HCC<CN group had significantly worse RFS (P=0.022) and OS (P<0.0001) than the HCC≥CN group (Fig. 2).

A multivariate analysis with those factors that displayed significant difference in an univariate analysis was next performed. The risk associated with this approach is that certain variables that were not significant in univariate analysis may have the potential to be significant in multivariate analysis. However, in situations when there is not enough information about the importance of each factor, this approach seems to be feasible. In the multivariate analysis, the finding for OS was confirmed (P=0.0011) (Table IV), whereas the finding for RFS was not (P=0.1884) (Table V). Multivariate analysis also revealed significant associations between survival (both OS and RFS) and serosal invasion (P=0.0407), and between OS and vascular invasion (P=0.0104) (Tables IV and V). Our

Table IV. Univariate and multivariate analysis of overall survival.

	Univariate analysis			Multivariate analysis		
Clinicopathological factor	HR	95% CI	P-value	HR	95% CI	P-value
Age (years)						
≥65 vs. <65	1.55	0.98-2.48	0.0585			
Gender						
Male vs. female	1.25	0.69-2.52	0.4709			
Virus infection						
HCV vs. others	1.50	0.94-2.46	0.0848			
Albumin (mg/dl)						
<3.5 vs. ≥3.5	1.65	0.95-2.75	0.0731			
PT (%)						
<70 vs. ≥70	1.75	0.90-3.12	0.0914			
ICG-R15 (%)						
≥15 vs. <15	1.74	0.92-3.19	0.0836			
Liver cirrhosis						
(+) vs. (-)	1.29	0.80-2.06	0.2876			
Child-Pugh						
B vs. A	1.63	0.63-3.48	0.2824			
Liver damage						
B or C vs. A	2.07	1.16-3.50	0.0149			
Tumor number						
Multiple vs. single	1.68	0.99-2.75	0.0534			
Tumor size (cm)						
≥2 vs. <2	2.02	0.95-5.23	0.0681			
AFP (ng/ml)						
≥20 vs. <20	2.06	1.30-3.30	0.0022	1.40	0.79-2.46	0.2368
Differentiation						
Poor vs. well/moderate	2.29	1.05-4.38	0.0365	1.35	0.43-3.46	0.5732
Growth form						
Infiltrative vs. expansive	1.57	0.86-2.71	0.1334			
Formation of capsule						
(-) vs. (+)	0.91	0.54-1.49	0.7282			
Infiltration to capsule						
(+) vs. (-)	0.97	0.61-1.54	0.9168			
Septal formation						
(-) vs. (+)	1.05	0.64-1.70	0.8221			
Serosal invasion						
(+) vs. (-)	2.51	1.48-4.17	0.0009	1.86	1.02-3.28	0.0407
Portal vein or hepatic vein invasion						
(+) vs. (-)	2.25	1.38-3.62	0.0014	2.15	1.20-3.76	0.0104
Surgical margin						
(+) vs. (-)	1.84	1.00-3.18	0.0498	1.37	0.63-2.71	0.4034
Japanese stage						
III/IV vs. I/II	1.56	0.97-2.47	0.0622			
AKR1B10 expression						
T<CN vs. T≥CN	3.14	1.81-5.23	<0.0001	3.06	1.58-5.71	0.0011

A multivariate Cox proportional hazard model was used to investigate independent risk factors for overall survival. HR, hazard ratio; CI, confidence interval; HCV, hepatitis C virus; PT, prothrombin time; ICG-R15, retention rate of indocyanine green 15 min after administration; AFP, alpha fetoprotein; T, tumor; CN, corresponding normal; *AKR1B10*, aldo-keto reductase family 1, member B10.

Table V. Univariate and multivariate analysis of recurrence-free survival.

	Univariate analysis			Multivariate analysis		
Clinicopathological factor	HR	95% CI	P-value	HR	95% CI	P-value
Age (years)						
≥65 vs. <65	1.11	0.77-1.61	0.5539			
Gender						
Male vs. female	1.57	0.95-2.78	0.0755			
Virus infection						
HCV vs. others	1.45	1.00-2.15	0.0496	1.14	0.65-2.02	0.6440
Albumin (mg/dl)						
<3.5 vs. ≥3.5	1.74	1.10-2.68	0.0189	1.48	0.76-2.80	0.2373
PT (%)						
<70 vs. ≥70	1.33	0.75-2.20	0.3092			
ICG-R15 (%)						
≥15 vs. <15	2.31	1.40-3.71	0.0012	1.72	0.90-3.19	0.0939
Liver cirrhosis						
(+) vs. (-)	1.23	0.84-1.80	0.2742			
Child-Pugh						
B vs. A	1.66	0.74-3.20	0.1981			
Liver damage						
B or C vs. A	1.87	1.15-2.92	0.0121			
Tumor number						
Multiple vs. single	1.65	1.05-2.49	0.0277	1.41	0.66-2.72	0.3432
Tumor size (cm)						
≥2 vs. <2	1.81	1.03-3.49	0.0352	0.88	0.42-1.97	0.7536
AFP (ng/ml)						
≥20 vs. <20	1.43	0.98-2.08	0.0614			
Differentiation						
Poor vs. well/moderate	1.44	0.70-2.64	0.2899			
Growth form						
Infiltrative vs. expansive	1.18	0.68-1.93	0.5158			
Formation of capsule						
(-) vs. (+)	0.67	0.43-1.01	0.0577			
Infiltration to capsule						
(+) vs. (-)	1.18	0.82-1.72	0.3606			
Septal formation						
(-) vs. (+)	1.01	0.67-1.50	0.9240			
Serosal invasion						
(+) vs. (-)	2.75	1.76-4.19	<0.0001	2.23	1.17-4.14	0.0151
Portal vein or hepatic vein invasion						
(+) vs. (-)	1.94	1.28-2.88	0.0019	1.56	0.84-2.79	0.1481
Surgical margin						
(+) vs. (-)	1.16	0.68-1.86	0.5608			
Japanese stage						
III/IV vs. I/II	1.37	0.93-1.99	0.1012			
AKR1B10 expression						
T<CN vs. T≥CN	1.90	1.14-3.01	0.0138	1.59	0.78-3.04	0.1884

A multivariate Cox proportional hazard model was used to investigate independent risk factors of recurrence-free survival. HR, hazard ratio; CI, confidence interval; HCV, hepatitis C virus; PT, prothrombin; ICG-R15, retention rate of indocyanine green 15 min after administration; AFP, alpha fetoprotein; *AKR1B10*, aldo-keto reductase family 1, member B10; T, tumor; CN, corresponding normal.

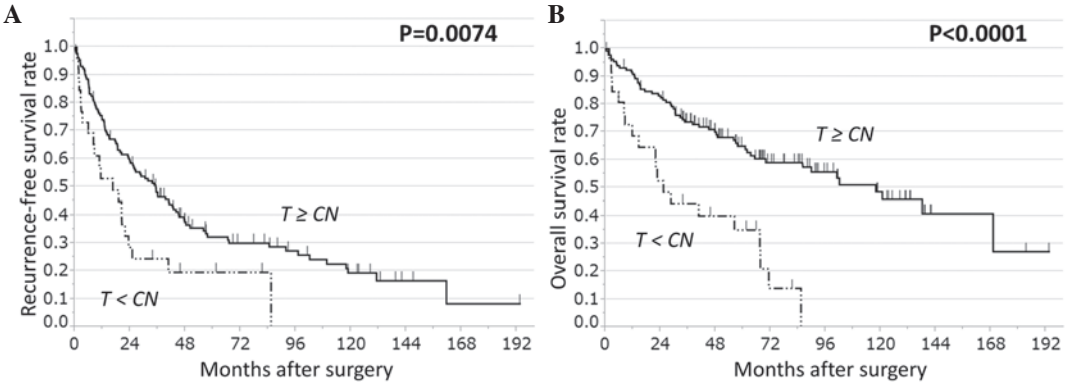

Figure 2. RFS and OS rates in patients with HCC based on *AKR1B10* expression in T and CN tissue. HCC cases (n=158) were stratified on the basis of *AKR1B10* expression in T tissue relative to CN tissue, either T≥CN (n=132) or T<CN (n=26). T<CN cases have significantly worse (A) RFS and (B) OS rates than T≥CN cases (log-rank test: RFS, P=0.0074; OS, P<0.0001). CN, corresponding normal; T, tumor; RFS, recurrence-free survival; OS, overall survival; *AKR1B10*, aldo-keto reductase family 1, member B10; HCC, hepatocellular carcinoma.

findings suggest that the ratio of AKR1B10 mRNA levels in HCC and CN tissues predicts prognosis after curative hepatectomy, with low expression in HCC tissue relative to normal liver tissue being indicative of poor prognosis.

Discussion

A major obstacle in HCC treatment is the high frequency of tumor recurrence even after curative resection and liver transplantation (17), and even in cases of small, well-differentiated tumors (18). We previously reported that MO was more common than IM in HCC (12,13). Accordingly, the detection of metachronous multicentric recurrent carcinoma at an early stage and the instigation of appropriate therapy may prolong survival (14). Furthermore, evaluation of CN liver tissue may provide useful information regarding MO risk along with the evaluation of the cancer tissue.

In the present study, microarray analysis revealed that four genes, including *AKR1B10,* were more highly expressed in CN tissue than in SN tissue. We decided to further investigate *AKR1B10* as a potential non-tumor prognostic predictor of HCC outcome.

NAD(P)H-dependent oxidoreductases catalyze the reduction of a variety of carbonyl compounds, and AKR1B10, a member of this superfamily, efficiently reduces aliphatic and aromatic aldehydes (19). *AKR1B10* is expressed in the kidney, nasal epithelium, liver and cervical epithelium, according to GeneCards (http://www.genecards.org/), and in several cancer cell lines, including liver, kidney, lung, colon, brain, prostate, cervix and breast (20). In non-small cell lung cancers, especially squamous cell carcinomas, AKR1B10 expression highly correlates with smoking (21). As shown by Zhang *et al* (22), AKR1B10 promotes pancreatic carcinogenesis via modulation of the K-RAS/E-cadherin pathway. Several studies demonstrated AKR1B10 expression in HCC via immunohistochemistry (23-26). To the best of our knowledge, however, there are no reports comparing *AKR1B10* expression in HCC and CN tissue or determining its association with HCC prognosis.

In this study, and as determined by RT-qPCR, *AKR1B10* expression was significantly higher in HCC than in CN samples, but not significantly different in SN and CN samples. Although the result of microarray analysis demonstrated higher *AKR1B10* expression in CN than in SN, it was only one typical HCC case that was used to compare. Therefore, *AKR1B10* expression is not an HCC marker specific to CN tissue. There was no significant correlation between *AKR1B10* expression and HCC prognosis when these parameters were compared in 158 HCC surgical samples. However, when samples were grouped according to *AKR1B10* expression in HCC tissue relative to CN tissue (expression in HCC≥CN or expression in HCC<CN), it was observed that HCC<CN was associated with significantly worse RFS and OS rates, and that *AKR1B10* was an independent risk factor for OS in a multivariate analysis using a Cox hazard model.

Via immunohistochemistry, a previous study reported that AKR1B10 levels were higher in HCC than in surrounding tissue, and suggested that this enzyme may be useful for distinguishing HCC from benign hepatic tumors (25). Other studies found that HCCs with low AKR1B10 levels were highly proliferative, poorly differentiated and had a poor prognosis (23,24). In agreement with these studies, the present study identified that AKR1B10 mRNA levels were elevated in HCCs, and that prognosis (RFS and OS) was worse in cases in which the amounts of AKR1B10 mRNA were lower in HCC tissue than in CN tissue. *AKR1B10* expression also correlated with capsule infiltration and liver damage. Capsule infiltration may cause genetic changes in non-tumorous liver tissue adjacent to HCCs and may be related to cell invasiveness. Liver damage may increase *AKR1B10* expression in CN tissue. Sato *et al* (27) demonstrated that chronic hepatitis C-mediated AKR1B10 upregulation correlated with serum alpha-fetoprotein levels and HCC recurrence. Higher *AKR1B10* expression in CN tissue may be associated with the oncogenic status of the background liver tissue, while lower *AKR1B10* expression in HCC tissue may indicate HCC malignancy. Interestingly, factors considered to be prognostic such as vascular invasion (28-30) were unrelated to *AKR1B10* expression. Therefore, changes in *AKR1B10* expression may be worth considering as prognostic predictors, even if other prognostic factors are not observed.

HCC-resected patients with a low tumor-to-CN ratio of AKR1B10 mRNA could be offered a more intense follow-up program consisting of frequent examinations with ultrasonography or computed tomography, and adjuvant therapy

should be considered if possible in the future. Further study is required to elucidate how genes such as *AKR1B10* in tumor-adjacent normal liver tissue respond to HCC development and recurrence. Such knowledge would facilitate the design of novel approaches for prediction, prevention and treatment of HCC.

In conclusion, our findings suggest that the ratio of *AKR1B10* expression in HCC tissue and background non-tumorous liver tissue may be a prognostic indicator in patients receiving curative hepatectomies. Its combination with other prognostic factors may more accurately predict HCC prognosis.

Acknowledgements

This work was supported by the Japanese Society for the Promotion of Science (Tokyo, Japan) through a KAKENHI Grant-in-Aid for Scientific Research (C) (grant number 25461979).

References

1. Parkin DM, Bray F, Ferlay J and Pisani P: Global cancer statistics, 2002. CA Cancer J Clin 55: 74-108, 2005.
2. Rahbari NN, Mehrabi A, Mollberg NM, Müller SA, Koch M, Büchler MW and Weitz J: Hepatocellular carcinoma: Current management and perspectives for the future. Ann Surg 253: 453-469, 2011.
3. Kobayashi A, Kawasaki S, Miyagawa S, Miwa S, Noike T, Takagi S, Iijima S and Miyagawa Y: Results of 404 hepatic resections including 80 repeat hepatectomies for hepatocellular carcinoma. Hepatogastroenterology 53: 736-741, 2006.
4. Chen MS, Li JQ, Zheng Y, Guo RP, Liang HH, Zhang YQ, Lin XJ and Lau WY: A prospective randomized trial comparing percutaneous local ablative therapy and partial hepatectomy for small hepatocellular carcinoma. Ann Surg 243: 321-328, 2006.
5. Taura K, Ikai I, Hatano E, Fujii H, Uyama N and Shimahara Y: Implication of frequent local ablation therapy for intrahepatic recurrence in prolonged survival of patients with hepatocellular carcinoma undergoing hepatic resection: An analysis of 610 patients over 16 years old. Ann Surg 244: 265-273, 2006.
6. Chen PJ, Chen DS, Lai MY, Chang MH, Huang GT, Yang PM, Sheu JC, Lee SC, Hsu HC and Sung JL: Clonal origin of recurrent hepatocellular carcinomas. Gastroenterology 96: 527-529, 1989.
7. Imamura H, Matsuyama Y, Tanaka E, Ohkubo T, Hasegawa K, Miyagawa S, Sugawara Y, Minagawa M, Takayama T, Kawasaki S and Makuuchi M: Risk factors contributing to early and late phase intrahepatic recurrence of hepatocellular carcinoma after hepatectomy. J Hepatol 38: 200-207, 2003.
8. Portolani N, Coniglio A, Ghidoni S, Giovanelli M, Benetti A, Tiberio GA and Giulini SM: Early and late recurrence after liver resection for hepatocellular carcinoma: Prognostic and therapeutic implications. Ann Surg 243: 229-235, 2006.
9. Cucchetti A, Piscaglia F, Caturelli E, Benvegnù L, Vivarelli M, Ercolani G, Cescon M, Ravaioli M, Grazi GL, Bolondi L and Pinna AD: Comparison of recurrence of hepatocellular carcinoma after resection in patients with cirrhosis to its occurrence in a surveilled cirrhotic population. Ann Surg Oncol 16: 413-422, 2009.
10. Matsuda M, Fujii H, Kono H and Matsumoto Y: Surgical treatment of recurrent hepatocellular carcinoma based on the mode of recurrence: Repeat hepatic resection or ablation are good choices for patients with recurrent multicentric cancer. J Hepatobiliary Pancreat Surg 8: 353-359, 2001.
11. Morimoto O, Nagano H, Sakon M, Fujiwara Y, Yamada T, Nakagawa H, Miyamoto A, Kondo M, Arai I, Yamamoto T, *et al*: Diagnosis of intrahepatic metastasis and multicentric carcinogenesis by microsatellite loss of heterozygosity in patients with multiple and recurrent hepatocellular carcinomas. J Hepatol 39: 215-221, 2003.
12. Nomoto S, Yamashita K, Koshikawa K, Nakao A and Sidransky D: Mitochondrial D-loop mutations as clonal markers in multicentric hepatocellular carcinoma and plasma. Clin Cancer Res 8: 481-487, 2002.
13. Nomoto S, Kinoshita T, Kato K, Otani S, Kasuya H, Takeda S, Kanazumi N, Sugimoto H and Nakao A: Hypermethylation of multiple genes as clonal markers in multicentric hepatocellular carcinoma. Br J Cancer 97: 1260-1265, 2007.
14. Kumada T, Nakano S, Takeda I, Sugiyama K, Osada T, Kiriyama S, Sone Y, Toyoda H, Shimada S, Takahashi M and Sassa T: Patterns of recurrence after initial treatment in patients with small hepatocellular carcinoma. Hepatology 25: 87-92, 1997.
15. Stangegaard M: Gene expression analysis using agilent DNA microarrays. Methods Mol Biol 529: 133-145, 2009.
16. Tsai SJ and Wiltbank MC: Quantification of mRNA using competitive RT-PCR with standard-curve methodology. Biotechniques 21: 862-866, 1996.
17. Wang Z, Zhang G, Wu J and Jia M: Adjuvant therapy for hepatocellular carcinoma: Current situation and prospect. Drug Discov Ther 7: 137-143, 2013.
18. Takenaka K, Adachi E, Nishizaki T, Hiroshige K, Ikeda T, Tsuneyoshi M and Sugimachi K: Possible multicentric occurrence of hepatocellular carcinoma: A clinicopathological study. Hepatology 19: 889-894, 1994.
19. Cao D, Fan ST and Chung SS: Identification and characterization of a novel human aldose reductase-like gene. J Biol Chem 273: 11429-11435, 1998.
20. Endo H, Shiroki T, Nakagawa T, Yokoyama M, Tamai K, Yamanami H, Fujiya T, Sato I, Yamaguchi K, Tanaka N, *et al*: Enhanced expression of long non-coding RNA HOTAIR is associated with the development of gastric cancer. PLoS One 8: e77070, 2013.
21. Kang MW, Lee ES, Yoon SY, Jo J, Lee J, Kim HK, Choi YS, Kim K, Shim YM, Kim J and Kim H: AKR1B10 is associated with smoking and smoking-related non-small-cell lung cancer. J Int Med Res 39: 78-85, 2011.
22. Zhang W, Li H, Yang Y, Liao J and Yang GY: Knockdown or inhibition of aldo-keto reductase 1B10 inhibits pancreatic carcinoma growth via modulating Kras-E-cadherin pathway. Cancer Lett 355: 273-280, 2014.
23. Heringlake S, Hofdmann M, Fiebeler A, Manns MP, Schmiegel W and Tannapfel A: Identification and expression analysis of the aldo-ketoreductase1-B10 gene in primary malignant liver tumours. J Hepatol 52: 220-227, 2010.
24. Schmitz KJ, Sotiropoulos GC, Baba HA, Schmid KW, Müller D, Paul A, Auer T, Gamerith G and Loeffler-Ragg J: AKR1B10 expression is associated with less aggressive hepatocellular carcinoma: A clinicopathological study of 168 cases. Liver Int 31: 810-816, 2011.
25. Matkowskyj KA, Bai H, Liao J, Zhang W, Li H, Rao S, Omary R and Yang GY: Aldoketoreductase family 1B10 (AKR1B10) as a biomarker to distinguish hepatocellular carcinoma from benign liver lesions. Hum Pathol 45: 834-843, 2014.
26. Tsuzura H, Genda T, Sato S, Murata A, Kanemitsu Y, Narita Y, Ishikawa S, Kikuchi T, Mori M, Hirano K, *et al*: Expression of aldo-keto reductase family 1 member b10 in the early stages of human hepatocarcinogenesis. Int J Mol Sci 15: 6556-6568, 2014.
27. Sato S, Genda T, Hirano K, Tsuzura H, Narita Y, Kanemitsu Y, Kikuchi T, Iijima K, Wada R and Ichida T: Up-regulated aldo-keto reductase family 1 member B10 in chronic hepatitis C: Association with serum alpha-fetoprotein and hepatocellular carcinoma. Liver Int 32: 1382-1390, 2012.
28. Kosuge T, Makuuchi M, Takayama T, Yamamoto J, Shimada K and Yamasaki S: Long-term results after resection of hepatocellular carcinoma: Experience of 480 cases. Hepatogastroenterology 40: 328-332, 1993.
29. Izumi R, Shimizu K, Ii T, Yagi M, Matsui O, Nonomura A and Miyazaki I: Prognostic factors of hepatocellular carcinoma in patients undergoing hepatic resection. Gastroenterology 106: 720-727, 1994.
30. Hanazaki K, Kajikawa S, Koide N, Adachi W and Amano J: Prognostic factors after hepatic resection for hepatocellular carcinoma with hepatitis C viral infection: Univariate and multivariate analysis. Am J Gastroenterol 96: 1243-1250, 2001.