

Advances in recurrence and malignant transformation of sinonasal inverted papillomas (Review)

QINGJIA SUN, LIFENG AN, JUN ZHENG and DONGDONG ZHU

Department of Otorhinolaryngology Head and Neck Surgery,
The China-Japan Union Hospital of Jilin University, Changchun, Jilin 130033, P.R. China

Received March 3, 2016; Accepted January 26, 2017

DOI: 10.3892/ol.2017.6089

Abstract. Sinonasal inverted papilloma (SIP) is a benign tumor of the nasal cavity and sinus. SIP is characterized by aggressive malignant transformation and a high rate of recurrence. Inadequate removal of the tumor during surgery is one of the most significant contributors to SIP recurrence. A growing body of evidence suggests that molecular alteration in SIP, including human papilloma virus infections, single nucleotide polymorphisms of key genes, deregulation of signaling pathways and immunological changes, may lead to SIP occurrence and malignant transformation. However, the extent to which these molecular mechanisms contribute to SIP pathology and transformation remains unclear due to limited research. Further studies are warranted to elucidate the primary dependent factors that contribute to SIP etiology. The present article reviewed risk factors of progression and recurrence of SIP, including outdoor and industrial occupational exposure, smoking, septal deviation, SIP location, recurrent cases, stage of SIP-associated squamous cell carcinoma and choice of surgical method.

Contents

1. Introduction
2. Clinical risk factors for SIP recurrence
3. Clinical prevention for the recurrence of SIP
4. Potential mechanisms underlying the recurrence and malignant transformation of SIP
5. Conclusion

Correspondence to: Professor Dongdong Zhu, Department of Otorhinolaryngology Head and Neck Surgery, The China-Japan Union Hospital of Jilin University, 126 Xiantai Street, Changchun, Jilin 130033, P.R. China
E-mail: asd830915@163.com

Key words: sinonasal inverted papilloma, recurrence, malignant transformation

1. Introduction

Sinonasal inverted papilloma (SIP) is a benign tumor which originates from the sinonasal Schneiderian mucosa and accounts for 0.5 to 4% of all nasal and sinus neoplasm (1). Pathologically, SIP epithelium inverts into submucosal stroma, which is distinguished from other types of nasal papilloma. Unlike other benign tumors, SIP exhibits remarkable aggressive behaviors, including invasiveness, recurrence and malignant transformation (~10%) (2). Therefore, SIP can spread into the sphenoidal sinus, orbit, and cranial base, which can lead to poor prognosis for SIP patients (2).

To date, the treatment for SIP includes surgery and surgery combined with radiotherapy for SIP-associated squamous cell carcinoma (SIP/SCC). Currently, the majority of surgeons prefer endoscopic methods to traditional external approaches, due to similar success rates, less trauma and no facial scars. However, the common view is that SIP recurrence is due to inadequate removal during the first surgery (2-4). Therefore, preoperative evaluation as well as postoperative follow up is very important.

2. Clinical risk factors for SIP recurrence

Understanding clinical risk factors is critical for preventing the recurrence of SIP. Similar to other head and neck tumors, smoking has been identified as a risk factor of SIP recurrence in two previous studies (containing 132 and 162 SIP patients, respectively) (5,6). Outdoor and industrial occupations may be another potential environmental risk factor, particularly exposure to organic solvents, including diethylnitrosamine (7-9). These factors include smoking history, smoking amount, and occupation environment (5-9). Recently, Nomura *et al* (10) found that the SIP-affected area was significantly associated with the concave side of the septal deviation. Considering that the high wall shear stress of high-velocity airflow in this location, the study may suggest a causative role of human papilloma virus (HPV) and chemicals in the occurrence of sinonasal papilloma due to the traumatic effects caused by airflow (10). However, whether nasal septal reconstruction should be performed following SIP surgery remains to be determined.

In the majority of head and neck tumors, the clinical stage is associated with recurrence and poor prognosis (11). The clinical stage of SIP has been defined using the Krouse staging

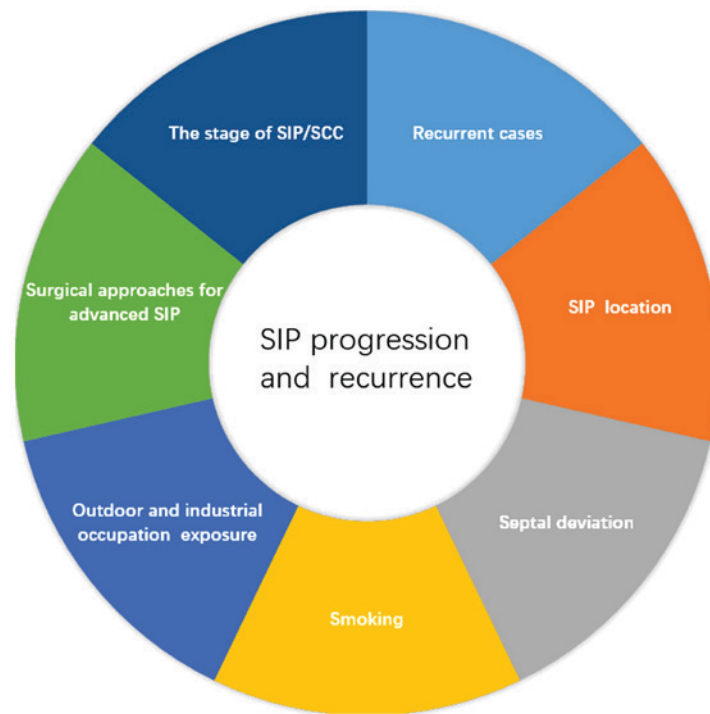


Figure 1. Clinical risk factors of progression and recurrence of SIP. These factors may involve smoking, outdoor and industrial occupational exposure, septal deviation, SIP location, recurrent cases, stage of SIP-associated squamous cell carcinoma and choice of surgical method for advanced SIP. SIP, sinonasal inverted papilloma.

system (12), the Furuta staging system (13), the Cannady staging system (14) and the Han staging system (15). The Krouse staging system is currently the most widely used (16). While certain authors have emphasized the role of SIP stage system on SIP recurrence (17,18), it is not clear whether clinical stage is associated with SIP recurrence. An association between Krouse stage system and recurrence of SIP was not identified in a recent study involving 156 SIP patients (19). In a multicenter study involving 578 SIP patients, three stage systems (the Krouse staging system, the Furuta staging system and the Cannady staging system) did not associate with SIP recurrence rates (2). This study also suggested that patients with advanced stage of SIP who underwent single endoscopic surgery presented a higher recurrence rate. Furthermore, the study also found that SIP involving the frontal sinus or maxillary sinus was associated with higher recurrence rates (2). Consistently, in 57 patients with SIP based within the sphenoid sinus, a multi-institutional retrospective study revealed that the attachment site of SIP over the optic nerve and carotid artery correlated with a 14.6% rate of recurrence (20). Our previous study conducted by the present authors did not show the correlation between Han staging systems and recurrence rates of SIP in 89 SIP cases, but indicated that there is a statistically higher recurrence rate (27.3%) in patients who underwent secondary surgery (21). Consistent with this study, a recent study reported a 50% SIP recurrence rate following secondary surgery compared with a 12% rate following primary resection (18). However, this study did not classify the SIP as benign or SIP/SCC. Recently, two studies, involving 87 and 32 SIP/SCC patients, suggested that advanced American Joint Committee on Cancer (AJCC) stages and therapeutic methods may be risk factors for poor prognosis (22,23). To the best of

our knowledge, these are the largest series of SIP/SCC cases reported to date. Collectively, these studies proposed that smoking, chemical exposure, septal deviation, SIP location, secondary surgery and AJCC stage of SIP/SCC may be clinical risk factors for progression and recurrence of SIP. Notably, the AJCC stage of SIP/SCC may contribute to treatment selection (Fig. 1) (22,23).

The choice of surgical methods may be another potential risk factor for SIP recurrence. Although endoscopic sinus surgery (ESS) has been considered the treatment of choice for the majority of SIP cases, surgical decisions should take into account the extent, volume, and lesion location (24). A study of 212 SIP patients demonstrated that SIP lesions with an extensive involvement of the frontal sinus and/or supraorbital cell may require a combined approach (25). In addition, the Korean multicenter study suggested that surgeons should consider combined approaches to reduce recurrence for advanced SIP [Krouse staging system: T3 stage (12); Furuta staging system: T3-A stage (13); Cannady staging system: group B (14)], particularly for novice surgeons (2). Although certain authors propose that SIP involving attachment sites within the maxillary sinus require an endoscopic-external combined technique (1,26), emerging evidence suggests that novel tailored ESS techniques (endoscopic modified medial maxillectomy, and transnasal endoscopic anterior and medial maxillectomy) allow enhanced visualization and preserve important structures, including the inferior turbinate and nasolacrimal duct (27-29). However, other authors proposed that the endoscopic-external combined approach remains essential for recurrent maxillary SIP (30). Therefore, a multicenter study or large meta-analysis is required to determine the most significant factors affecting progression and recurrence of SIP.

Table I. Collision between SIP and other patterns of tumor/disease.

Pathologic collision	Treatment	References
SIP and esthesioneuroblastoma	Surgery, adjuvant concomitant chemoradiation	(48)
NK/T-cell lymphoma (nasal type) and SIP	Surgery, chemotherapy	(49)
Unilateral SIP and angiofibroma	Surgery	(50)
SIP and MFSS	Surgery, postoperative adjuvant radiotherapy and subsequent chemotherapy	(51)
SIP and fungal ball	Surgery	(52)

SIP, sinonasal inverted papilloma; MFSS, monophasic fibrous synovial sarcoma; NK, natural killer.

In summary, the location of SIP, secondary surgery, AJCC stage of SIP/SCC and the choice of surgical method for advanced SIP directly contribute to incomplete or inadequate removal of tumors. Therefore, incomplete or inadequate removal is a direct cause of recurrence. SIP location, secondary surgery, AJCC stage of SIP/SCC, and surgical approaches for advanced SIP are the direct risk factors of SIP recurrence.

3. Clinical prevention for the recurrence of SIP

The management of risk factors of SIP recurrence involves precise identification of the SIP attachment site, anatomical anomalies in sinonasal regions, careful planning of surgical procedures and a well-planned postoperative follow-up (19). The use of computed tomography (CT) and magnetic resonance imaging (MRI) is critical for preoperative prediction of SIP attachment sites and differentiation (31,32). Radical ablation of SIP attachment sites is crucial for the first surgical resection. Therefore, imaging is important in preoperative prediction of SIP attachment sites.

Since the majority of recurrence is localized to the same site as the primary tumor, the accurate preoperative prediction of SIP attachment sites is crucial for the first surgical resection (3). Notably, SIPs with an origin in close proximity to vital structures, including the optic nerve and carotid artery, may be associated with higher rates of recurrence (20), which may be a factor for consideration when choosing the surgical approach.

Prior reports have suggested that focal osteitis within the SIP tissue may be a predictor of SIP origin (31). While the mechanisms underlying the origin of SIP-induced osteitis remains to be determined, certain studies report that the SIP attachment site provides blood supply to the large bulky tumor volume, which leads to hypervascularization of the attachment site (31). Hypervascularization within the origin site may cause bone growth (31), driven by bone morphogenetic protein 4 expressed by SIP cells (33) or cytokines released due to inflammation (34). Bhalla *et al* (34) found that the predictive value of osteitis was 95% via CT scan, and similar results were also reported by Yousuf *et al* (35). Lee *et al* (31) evaluated 55 lesions associated with focal hyperostosis using CT images and revealed that the location of hyperostosis coincided with the actual tumor attachment sites in 49 (89.1%) of all the lesions. Notably, Lee *et al* (31) suggested that areas of cone-shaped hyperostosis matched with the SIP origin rather than plaque-like hyperostosis.

Accurate tumor mapping is likely to be challenging due to inadequate differentiation of the tumor from pathological inflammation (36) and squamous cell carcinoma (32). MRI may have an advantage in differentiating soft tissue. MRI is able to identify inflammation more clearly and is also able to identify tumor margin, tumor extent (32) and convoluted cerebriform pattern (CCP), which is considered a valuable SIP characteristic (37). Wang *et al* (38) have demonstrated that there were significant differences between SIP and malignancy in T2 homogeneity, CCP and other MRI parameters. The authors concluded that non-enhanced and static combined with dynamic contrast-enhanced MRI facilitates the identification of SIP and malignant tumors (38). Another study demonstrated the diagnostic value of tumor blood flow obtained by pseudocontinuous arterial spin labeling is able to effectively differentiate between SCC, non-aggressive SIP and aggressive SIP using a 3.0-T MRI (39). Nakamaru *et al* (40) analyzed 10 consecutive patients with SIP and diagnosis in these patients was confirmed by histological assessment. The study indicated that MRI indicated greater specificity compared with CT scan and suggested that a combination of preoperative CT and MRI may be able to provide more useful information compared with using either CT or MRI alone (40).

Currently, there are no distinct clinical signs and symptoms that differentiate SIP and malignant transformation of SIP (2,32). The diagnosis of SIP malignant transformation is based on the observation of synchronous transformation, which appears at the same time as papilloma, and metachronous transformation, which appears at the site of a previous papilloma (41).

Furthermore, preoperative histological examination is difficult and ineffective to differentiate SIP and malignant transformation of SIP (22). Several investigators have suggested that CT/MRI may be ineffective in distinguishing SIP from SCC (42), while others have reported that bone invasion may be a differentiating feature of synchronous malignant transformation of SIP on CT scan (43). Therefore, recent studies introduced fluorine-18-fluorodeoxyglucose (18F-FDG) positron emission tomography (PET) /CT for the identification of SIP, which depends on the extent of FDG uptake by different tissues through glycolysis (44). Allegra *et al* (42) analyzed 12 patients (7 with primary diagnosis of SIP and 5 with suspected recurrence of SIP) using 18FDG-PET/CT for the diagnosis of SIP with a sensitivity and specificity rate of 100% (42). Similarly, a 2015 study containing 27 patients

Table II. Putative factors underlying mechanisms leading to SIP malignant transformation.

Materials	Methods	Putative factors	References
Tissue samples	IHC	p53, p63	(80)
Tissue samples	IHC	FSCN1	(87)
Tissue samples	IHC	Ki-67, PCNA	(65)
Tissue samples	IHC, TMA	p16, p53	(80)
Tissue samples	IHC	p21, p16, p63	(79)
Tissue samples, venous blood samples	IHC	MT2A-5A/G (rs28366003)	(85)
Tissue samples	IHC, western blotting, fluorescence microscopy	Reduced expression of TFPI-2	(86)
Tissue samples	IHC, FISH	SOX-2	(88)
Tissue samples	IHC, PCR	DSG-3	(92)
Tissue samples	IHC, gene chip analysis, PCR	CTSS, stefin A	(94)
Tissue samples	IHC, TMA	COX-2	(96,97)
Tissue samples	IHC, RT-qPCR	DLEC1	(98)
Tissue samples	IHC	PTEN, HIF-1 α	(74)
Tissue samples	IHC	IQGAP1	(99)
Tissue samples	IHC	E-cadherin, β -catenin	(95)
Tissue samples	IHC	Wnt pathways (β -catenin, cyclin D1 and Dvl-1)	(82)
Tissue samples	PCR, IHC	MSX2, topoII α	(89,90)
Tissue samples	IHC	TopoII- α , Ki-67	(84)
Tissue samples	IHC, PCR	HPV integration, pRb	(100)
Tissue samples	TMA, DIPS-PCR	HPV, EGFR	(78)
Tissue samples	IHC	Survivin, PCNA	(83)
Tissue samples	IHC	Smac, survivin	(93)
Tissue samples	IHC	MMP-2, HPV-16/18	(76)
Tissue samples	IHC	OPN, MSX2	(91)
Tissue samples, peripheral blood	Flow cytometry, Boyden chamber assay, IHC, Luminex analyzer	Treg cells	(101)
Tissue samples, SIP/SCC cell lines	Ion AmpliSeq cancer hotspot panel, Sanger sequencing, western blotting, proliferation assay	EGFR mutations	(77)

COX-2, cyclooxygenase-2; CTSS, cathepsin S; DIPS-PCR, detection of integrated papillomavirus sequences by ligation-mediated-polymerase chain reaction; DLEC1, deleted in lung and esophageal cancer protein 1; DSG-3, desmoglein-3; Dvl-1; Segment polarity protein dishevelled homolog DVL-1; EGFR, epidermal growth factor receptor; FSCN1, fascin; HIF-1 α , hypoxia-inducible factor 1- α ; HPV, human papilloma virus; IHC, immunohistochemistry; IQGAP1, IQ motif containing GTPase activating protein 1; RT-qPCR, reverse transcription-quantitative polymerase chain reaction; MSX-2, homeobox protein MSX-2; MT2A; metallothionein-2A; PCNA; proliferating cell nuclear antigen reverse transcription; qPCR, quantitative polymerase chain reaction; pRb, retinoblastoma protein; PTEN, phosphatidylinositol 3,4,5-trisphosphate 3-phosphatase and dual-specificity protein phosphatase; MMP-2, matrix metalloproteinase-2; OPN, osteopontin; SIP/SCC, sinonasal inverted papilloma-associated squamous cell carcinoma; SOX-2, sex determining region Y-box 2; TMA, tissue microarray; Treg, regulatory T cells; Smac, second mitochondria-derived activator of caspase; TFPI-2, tissue factor pathway inhibitor 2; topoII- α , topoisomerase II α .

demonstrated that 18FDG-PET/CT is able to distinguish polyposis, SIP and SCC by distinct standardized uptake value (SUV_{max}) values (45). Shojaku *et al* (46) confirmed that higher SIP SUV_{max} values may indicate the probability of an associated malignancy, even when preoperative biopsy indicates a benign papilloma. By contrast, another study containing 8 patients reported a wide discrepancy between MRI and PET/CT findings (47). Taken together, these studies suggest that preoperative SIP imaging should involve a combination of CT, MRI and PET/CT.

Histologically, the most common malignancy associated with SIP is SCC. However, growing evidence has demonstrated a pathologic collision exists between SIP and other tumors. Karam *et al* (48) reported a case with a pathologic collision of SIP with esthesioneuroblastoma. The tumor was resected; however the postoperative surgical margin was positive, and neck lymph nodes were metastatic. Therefore the patient was treated with adjuvant concomitant chemoradiation, and evidence of tumor recurrence was not detected in the 42-month follow-up (48). In another study, a patient with nasal type natural killer/T-cell

Table III. Putative factors underlying mechanisms leading to SIP occurrence and recurrence.

Materials	Methods	Putative factors	References
Tissue samples	IHC	PLUNC	(65)
Tissue samples	IHC	CK14, Ki-67	(66)
Tissue samples	IHC	Survivin, Bcl-2	(67)
Tissue samples	IHC, ELISA, PCR	OPN, VEGF	(68)
Tissue samples	IHC	FSCN1, MVD	(69)
Tissue samples	-	CCAAT enhancer binding proteins	(71)
Tissue samples	IHC	COX-2	(72)
Tissue samples	IHC, RT-PCR, western blot	AMOT	(73)
Tissue samples	IHC	MVD	(70)
Tissue samples	IHC	PTEN, HIF-1 α	(74)
Tissue samples	IHC, PCR	HPV, STMN1	(75)

AMOT, angiominin; Bcl-2, B-cell lymphoma 2; CK14, keratin, type I cytoskeletal 14; COX-2, cyclooxygenase-2; ELISA, enzyme-linked immunosorbent assay; FSCN1, fascin; HIF-1 α , hypoxia-inducible factor 1- α ; HPV, human papilloma virus; IHC, immunohistochemistry; MVD, mean vessel density; OPN, osteopontin; PLUNC, palate, lung, and nasal epithelium clone protein; PTEN, phosphatidylinositol 3,4,5-trisphosphate 3-phosphatase and dual-specificity protein phosphatase; RT-PCR, reverse transcription polymerase chain reaction; STMN1, stathmin1; VEGF, vascular endothelial growth factor.

lymphoma and SIP, received surgery with postoperative chemotherapy. Tumor recurrence was not observed in the subsequent 10-month follow-up (49). Shahrjerdi *et al* (50) reported a case of co-existing unilateral SIP and angiofibroma. The nasal mass was treated by radical surgical resection, and the 3-month follow-up indicated that the patient was asymptomatic with no signs of cancer recurrence (50). Additionally, a patient with SIP and accompanying monophasic fibrous synovial sarcoma in the sphenoid sinus was also reported (49). The treatment for this case involved surgery, postoperative adjuvant radiotherapy and subsequent chemotherapy. There were no signs of recurrence following the 50-month follow-up (51). Furthermore, SIP with fungal ball in the maxillary sinus has also been reported (52). SIP accompanied with a malignancy of a different pathology is extremely rare, which may lead to pretherapeutic misdiagnosis (51) and an increased risk of recurrence potentially due to a lack of therapeutic regimen such as surgical margin, dose and cycles of radiotherapy, selection of chemotherapeutic agent, and lack of evidence-based analysis of in large well-controlled studies (Table I).

Apart from histological variations of SIP, exceptional clinical cases should also be emphasized. It has been reported that SIP may spread to the middle ear and temporal bone. The spread of SIP may be mediated either due to migration via the eustachian tube or due to embryological migration of the Schneiderian mucosa into the middle ear (53,54). Garcia *et al* (55) reported that SIP/SCC in the maxillary sinus may extend to the mouth as an early symptom. Furthermore, as a common unilateral nasal occurrence, a case with a bilateral SIP involving both sides of frontal sinus was reported in Keskin *et al* (56). Sharma *et al* (57) reported a patient with a history of multiple locations, who presented with recurrent SIP with a pathologically benign large mass on the left side of the upper neck. Additionally, another study reported that SIP/SCC is associated with neck metastasis (58). These cases demonstrate that SIP may origin from multiple sites and therefore

should not be ignored. Preoperative examinations should include a complete head and neck assessment.

A number of studies suggest that the length follow-up for SIP was usually >3 years (2,16). Unfortunately, it is difficult to distinguish inflammation from SIP recurrence using nasal endoscopy (19,59). MRI and PET/CT may be recommended for post-surgery follow-up. In addition to imaging techniques, the serum level of squamous cell carcinoma antigen may also be used as a molecular marker for the recurrence of SIP (59,60).

4. Potential mechanisms underlying the recurrence and malignant transformation of SIP

A literature search on PubMed (<https://www.ncbi.nlm.nih.gov/pubmed/>) was performed using the following key words: 'Inverted papilloma'; 'sinonasal inverted papilloma'; 'inverted papilloma malignant transformation'; 'inverted papilloma recurrence'; and 'inverted papilloma malignant'. The search found that a majority of the clinical literature focused on diagnosis, surgery and prognosis. The majority of the studies were retrospective analyses. A number of studies focused on surgical methods and were published in prominent otorhinolaryngology journals in 2015 and 2016 (61-64). Notably, there were a limited number of experimental studies. To the best of our knowledge, the present study is the first to clearly identify the clinical etiology and problems concerning SIP malignancy and recurrence.

The mechanisms leading to the occurrence, recurrence and malignant transformation of SIP remain a matter of debate. To date, many studies have aimed to resolve this issue (Tables II and III). Putative aberrant mediators that may participate in the recurrence of SIP include palate, lung, and nasal epithelium clone protein (65), keratin, type I cytoskeletal 14 (66), Ki-67 (66), survivin (67), B-cell lymphoma 2 (67), osteopontin (OPN) (68), vascular endothelial growth factor (68), fascin (69), mean vessel density (69,70),

CCAAT enhancer binding proteins (71), cyclooxygenase-2 (COX-2) (72), angiominin (73), phosphatidylinositol 3,4,5-trisphosphate 3-phosphatase and dual-specificity protein phosphatase (PTEN) (74), hypoxia-inducible factor 1- α (HIF-1 α) (74), HPV infection and stathmin (75).

Malignant transformation of SIP may be associated with the following factors: HPV 16/18 infection (76), epidermal growth factor receptor (EGFR) 1 (77,78); cell cycle proteins [p21 (79); p16 (79,80); p53 (80,81); p63 (79,81); p27; cyclin D1 (82); proliferating cell nuclear antigen reverse transcription (65,83); Ki-67 (65,84); metallothionein-2-5A/G (reference single nucleotide polymorphisms cluster ID, 28366003) (85); TFPI-2 (86); fascin (87); matrix metalloproteinase-2 (76); sex determining region Y-box 2 (88); topoisomerase II- α (84,89,90); OPN (91); homeobox protein MSX-2 (89-91); desmoglein 3 (92); survivin (83,93); cathepsin S (94); stefin A (94); E-cadherin (95); β -catenin (82,95); COX-2 (96,97); deleted in lung and esophageal cancer protein 1 (98); IQ motif containing GTPase activating protein 1 (99); Smac (93); PTEN (74); HIF-1 α (74); Dvl-1 (82); retinoblastoma protein (100); and regulatory T cells (101). However, there were several key limitations in these studies. The materials and methods used were simple (1). The majority of literature analyzed primary resected SIP tissue samples and performed immunohistochemistry as a common method. However, accurate research on molecular biological mechanisms requires comprehensive materials and methods. For instance, the establishment of SIP cell lines and animal models is necessary for research on SIP (2). The major dependent factors of SIP. The basement of target therapy is that tumor cells depended on a core factor for their progression. Starska *et al* (85) emphasized EGFR mutations as a regulator of SIP to SIP/SCC. Variations in the EGFR gene have been identified as a key factor that are associated with poor prognosis in head and neck squamous cell carcinoma (102). It is likely that EGFR may be a target for SIP treatment; however further studies are required to confirm this hypothesis.

5. Conclusion

In summary, the clinical risk factors of SIP progression and recurrence include smoking, outdoor and industrial occupational exposure, septal deviation, SIP location, recurrent cases, stage of SIP/SCC and choice of surgical method for advanced SIP. The best preventative measure for SIP recurrence is the complete removal of the tumor during the first surgery and a comprehensive follow-up. Additionally, further studies are required to elucidate the molecular mechanisms underlying the recurrence and malignant transformation of SIP.

References

- Wood JW and Casiano RR: Inverted papillomas and benign nonneoplastic lesions of the nasal cavity. *Am J Rhinol Allergy* 26: 157-163, 2012.
- Kim DY, Hong SL, Lee CH, Jin HR, Kang JM, Lee BJ, Moon JJ, Chung SK, Rha KS, Cho SH, *et al*: Inverted papilloma of the nasal cavity and paranasal sinuses: A Korean multicenter study. *Laryngoscope* 122: 487-494, 2012.
- Saha SN, Ghosh A, Sen S, Chandra S and Biswas D: Inverted papilloma: A clinico-pathological dilemma with special reference to recurrence and malignant transformation. *Indian J Otolaryngol Head Neck Surg* 62: 354-359, 2010.
- Busquets JM and Hwang PH: Endoscopic resection of sinonasal inverted papilloma: A meta-analysis. *Otolaryngol Head Neck Surg* 134: 476-482, 2006.
- Moon JJ, Lee DY, Suh MW, Han DH, Kim ST, Min YG, Lee CH and Rhee CS: Cigarette smoking increases risk of recurrence for sinonasal inverted papilloma. *Am J Rhinol Allergy* 24: 325-329, 2010.
- Hong SL, Kim BH, Lee JH, Cho KS and Roh HJ: Smoking and malignancy in sinonasal inverted papilloma. *Laryngoscope* 123: 1087-1091, 2013.
- Sham CL, Lee DL, van Hasselt CA and Tong MC: A case-control study of the risk factors associated with sinonasal inverted papilloma. *Am J Rhinol Allergy* 24: e37-e40, 2010.
- d'Errico A, Zajacova J, Cacciatore A, Baratti A, Zanelli R, Alfonso S and Beatrice F: Occupational risk factors for sinonasal inverted papilloma: A case-control study. *Occup Environ Med* 70: 703-708, 2013.
- Herrold KM: Epithelial papillomas of the nasal cavity; Experimental induction in syrian hamsters. *Arch Pathol* 78: 189-195, 1964.
- Nomura K, Ogawa T, Sugawara M, Honkura Y, Oshima H, Arakawa K, Oshima T and Katori Y: Association between septal deviation and sinonasal papilloma. *Tohoku J Exp Med* 231: 315-319, 2013.
- Teymoortash A and Werner JA: Current advances in diagnosis and surgical treatment of lymph node metastasis in head and neck cancer. *GMS Curr Top Otorhinolaryngol Head Neck Surg* 11: Doc04, 2012.
- Krouse JH: Development of a staging system for inverted papilloma. *Laryngoscope* 110: 965-968, 2000.
- Oikawa K, Furuta Y, Nakamaru Y, Oridate N and Fukuda S: Preoperative staging and surgical approaches for sinonasal inverted papilloma. *Ann Otol Rhinol Laryngol* 116: 674-680, 2007.
- Cannady SB, Batra PS, Sautter NB, Roh HJ and Citardi MJ: New staging system for sinonasal inverted papilloma in the endoscopic era. *Laryngoscope* 117: 1283-1287, 2007.
- Han JK, Smith TL, Loehrl T, Toohill RJ and Smith MM: An evolution in the management of sinonasal inverting papilloma. *Laryngoscope* 111: 1395-1400, 2001.
- Lin GC, Akkina S, Chinn S, Prince ME, McHugh JB, Carey T and Zacharek MA: Sinonasal inverted papilloma: Prognostic factors with emphasis on resection margins. *J Neurol Surg B Skull Base* 75: 140-146, 2014.
- Gras-Cabrerizo JR, Montserrat-Gili JR, Massegur-Solench H, León-Vintró X, De Juan J and Fabra-Llopis JM: Management of sinonasal inverted papillomas and comparison of classification staging systems. *Am J Rhinol Allergy* 24: 66-69, 2010.
- Tomazic PV, Hubmann F and Stammberger H: The problem of high recurrence rate in endoscopic revision surgery for inverted papilloma. *Laryngorhinotologie* 94: 447-450, 2015 (In German).
- Xiao-Ting W, Peng L, Xiu-Qing W, Hai-Bo W, Wen-Hui P, Bing L, Er-Peng Z and Guang-Gang S: Factors affecting recurrence of sinonasal inverted papilloma. *Eur Arch Otorhinolaryngol* 270: 1349-1353, 2013.
- Suh JD, Ramakrishnan VR, Thompson CF, Woodworth BA, Adappa ND, Nayak J, Lee JM, Lee JT, Chiu AG and Palmer JN: Inverted papilloma of the sphenoid sinus: Risk factors for disease recurrence. *Laryngoscope* 125: 544-548, 2015.
- Jiang XD, Dong Z, Li GY, Gao G and Zhu DD: Endoscopic surgery for 89 cases of nasal inverted papilloma. *Zhonghua Er Bi Yan Hou Tou Jing Wai Ke Za Zhi* 45: 186-189, 2010 (In Chinese).
- Yu HX and Liu G: Malignant transformation of sinonasal inverted papilloma: A retrospective analysis of 32 cases. *Oncol Lett* 8: 2637-2641, 2014.
- Liang QZ, Li DZ, Wang XL, Huang H, Xu ZG and Wu YH: Survival outcome of squamous cell carcinoma arising from sinonasal inverted papilloma. *Chin Med J (Engl)* 128: 2457-2461, 2015.
- Osuch-Wójcikiewicz E, Wojas O, Nyckowska J, Chęciński P, Sielska-Badurek E, Bruzgielewicz A, Szwedowicz P and Niemczyk K: Management of recurrent sinonasal inverted papilloma in the experience of ENT department medical university of warsaw. *Otolaryngol Pol* 64: 73-76, 2010 (In Polish).
- Lombardi D, Tomenzoli D, Buttà L, Bizzoni A, Farina D, Sberze F, Karligkiotis A, Castelnuovo P and Nicolai P: Limitations and complications of endoscopic surgery for treatment for sinonasal inverted papilloma: A reassessment after 212 cases. *Head Neck* 33: 1154-1161, 2011.

26. Lawson W, Kaufman MR and Biller HF: Treatment outcomes in the management of inverted papilloma: An analysis of 160 cases. *Laryngoscope* 113: 1548-1556, 2003.
27. Liu Q, Yu H, Minovi A, Wei W, Wang D, Zheng C, Li F and Zhang Z: Management of maxillary sinus inverted papilloma via transnasal endoscopic anterior and medial maxillectomy. *ORL J Otorhinolaryngol Relat Spec* 72: 247-251, 2010.
28. Wada K, Ishigaki T, Ida Y, Yamada Y, Hosono S and Edamatsu H: Endoscopic modified medial maxillectomy for resection of an inverted papilloma originating from the entire circumference of the maxillary sinus. *Case Rep Otolaryngol* 2015: 952923, 2015.
29. Erbek SS, Koycu A and Buyuklu F: Endoscopic modified medial maxillectomy for treatment of inverted papilloma originating from the maxillary sinus. *J Craniofac Surg* 26: e244-e246, 2015.
30. Lian F and Juan H: Different endoscopic strategies in the management of recurrent sinonasal inverted papilloma. *J Craniofac Surg* 23: e44-e48, 2012.
31. Lee DK, Chung SK, Dhong HJ, Kim HY, Kim HJ and Bok KH: Focal hyperostosis on CT of sinonasal inverted papilloma as a predictor of tumor origin. *AJNR Am J Neuroradiol* 28: 618-621, 2007.
32. Gomaa MA, Hammad MS, Abdelmoghny A, Elsherif AM and Tawfik HM: Magnetic resonance imaging versus computed tomography and different imaging modalities in evaluation of sinonasal neoplasms diagnosed by histopathology. *Clin Med Insights Ear Nose Throat* 6: 9-15, 2013.
33. Okamoto T, Kodama S, Nomi N, Umemoto S and Suzuki M: Expression of bone morphogenic protein in sinonasal inverted papilloma with new bone formation. *Allergy Rhinol (Providence)* 2: 16-20, 2011.
34. Bhalla RK and Wright ED: Predicting the site of attachment of sinonasal inverted papilloma. *Rhinology* 47: 345-348, 2009.
35. Yousuf K and Wright ED: Site of attachment of inverted papilloma predicted by CT findings of osteitis. *Am J Rhinol* 21: 32-36, 2007.
36. Sham CL, King AD, van Hasselt A and Tong MC: The roles and limitations of computed tomography in the preoperative assessment of sinonasal inverted papillomas. *Am J Rhinol* 22: 144-150, 2008.
37. Jeon TY, Kim HJ, Chung SK, Dhong HJ, Kim HY, Yim YJ, Kim ST, Jeon P and Kim KH: Sinonasal inverted papilloma: Value of convoluted cerebriform pattern on MR imaging. *AJNR Am J Neuroradiol* 29: 1556-1560, 2008.
38. Wang X, Zhang Z, Chen X, Li J and Xian J: Value of magnetic resonance imaging including dynamic contrast-enhanced magnetic resonance imaging in differentiation between inverted papilloma and malignant tumors in the nasal cavity. *Chin Med J (Engl)* 127: 1696-1701, 2014.
39. Fujima N, Nakamaru Y, Sakashita T, Homma A, Tsukahara A, Kudo K and Shirato H: Differentiation of squamous cell carcinoma and inverted papilloma using non-invasive MR perfusion imaging. *Dentomaxillofac Radiol* 44: 20150074, 2015.
40. Nakamaru Y, Fujima N, Takagi D, Tsukahara A, Yoshida D and Fukuda S: Prediction of the attachment site of sinonasal inverted papillomas by preoperative imaging. *Ann Otol Rhinol Laryngol* 123: 468-474, 2014.
41. Mirza S, Bradley PJ, Acharya A, Stacey M and Jones NS: Sinonasal inverted papillomas: Recurrence, and synchronous and metachronous malignancy. *J Laryngol Otol* 121: 857-864, 2007.
42. Allegra E, Cristofaro MG, Cascini LG, Lombardo N, Tamburrini O and Garozzo A: 18FDG uptake in sinonasal inverted papilloma detected by positron emission tomography/computed tomography. *ScientificWorldJournal* 2012: 943412, 2012.
43. Myers EN, Fernau JL, Johnson JT, Tabet JC and Barnes EL: Management of inverted papilloma. *Laryngoscope* 100: 481-490, 1990.
44. Vansteenkiste JF, Stroobants SG, Dupont PJ, De Leyn PR, Verbeke EK, Deneffe GJ, Mortelmans LA and Demedts MG: Prognostic importance of the standardized uptake value on (18) F-fluoro-2-deoxy-glucose-positron emission tomography scan in non-small-cell lung cancer: An analysis of 125 cases. *Leuven Lung Cancer Group. J Clin Oncol* 17: 3201-3206, 1999.
45. Yilmaz I, Reyhan M, Canpolat T, Yilmazer C, Erkan AN, Yaşar M, Akdoğan V and Özlüoğlu LN: Positron emission tomography evaluation of sinonasal inverted papilloma and related conditions: A prospective clinical study. *Kulak Burun Bogaz Ihtis Derg* 25: 9-15, 2015.
46. Shojaku H, Fujisaka M, Yasumura S, Ishida M, Tsubota M, Nishida H, Watanabe Y, Kawano M, Shimizu M and Fukuoka J: Positron emission tomography for predicting malignancy of sinonasal inverted papilloma. *Clin Nucl Med* 32: 275-278, 2007.
47. Allegra E, Lombardo N, Cascini G, La Boria A, Garozzo A and Tamburrini O: Possible role of 18FDG-PET/CT for the surveillance of sinonasal inverted papilloma. *Clin Otolaryngol* 35: 249-251, 2010.
48. Karam SD, Jay AK, Anyanwu C, Steehler MK, Davidson B, Debritto P and Harter KW: Pathologic collision of inverted papilloma with esthesioneuroblastoma. *Front Oncol* 4: 44, 2014.
49. Roy AD, Tuli IP and Joshi D: NK/T cell lymphoma with inverted papilloma: A rare coexistence. *Australas Med J* 7: 318-322, 2014.
50. Shahrjerdi B, Angoyaroko A and Abdullah B: Co-existing of sinonasal inverted papilloma and angiofibroma: Case report and review of the literature. *Acta Inform Med* 20: 261-263, 2012.
51. Jiang X, Huang Q, Tang J and Hoffman MR: Monophasic epithelial synovial sarcoma accompanied by an inverted papilloma in the sphenoid sinus. *Case Rep Med* 2012: 379720, 2012.
52. Hsin LJ and Yang SW: Concomitant inverted papilloma and fungus ball in unilateral maxillary sinus. *B-ENT* 9: 71-75, 2013.
53. Barbosa JL, Pinheiro SD, Freitas MR, Nunes AA and Leite EB: Sinonasal inverted papilloma involving the middle ear and the mastoid. *Braz J Otorhinolaryngol* 78: 122, 2012.
54. Liu ZW, Walden A and Lee CA: Sinonasal inverted papilloma involving the temporal bone via the eustachian tube: Case report. *J Laryngol Otol* 127: 318-320, 2013.
55. Garcia AS, Bravo-Calderón DM, Ferreira MP and Oliveira DT: Squamous cell carcinoma arising from inverted Schneiderian papilloma: A case report with oral involvement. *Case Rep Otolaryngol* 2014: 478092, 2014.
56. Keskin IG, Topdağ M, İla K, Topdağ DÖ and Öztürk M: Bilateral inverted papilloma originating from the frontal sinus. *Kulak Burun Bogaz Ihtis Derg* 24: 349-353, 2014 (In Turkish).
57. Sharma J, Goldenberg D, Crist H and McGinn J: Multifocal inverted papillomas in the head and neck. *Ear Nose Throat J* 94: E20-E23, 2015.
58. Mathew P and Idiculla JJ: Malignant sinonasal papilloma with neck metastasis: A rare report and literature review. *Int J Oral Maxillofac Surg* 41: 368-370, 2012.
59. Matoušek P, Zelenik K, Safarčík K, Cáblová L and Komínek P: Squamous cell carcinoma antigen as a marker of sinonasal inverted papilloma. *Eur Arch Otorhinolaryngol* 271: 535-538, 2014.
60. Suzuki M, Deng Z, Hasegawa M, Uehara T, Kiyuna A and Maeda H: Squamous cell carcinoma antigen production in nasal inverted papilloma. *Am J Rhinol Allergy* 26: 365-370, 2012.
61. Healy DY Jr, Chhabra N, Metson R, Holbrook EH and Gray ST: Surgical risk factors for recurrence of inverted papilloma. *Laryngoscope* 126: 796-801, 2016.
62. Adriaensens GF, van der Hout MW, Reinartz SM, Georgalas C and Fokkens WJ: Endoscopic treatment of inverted papilloma attached in the frontal sinus/recess. *Rhinology* 53: 317-324, 2015.
63. Akkari M, Lassave J, Mura T, Gascou G, Pierre G, Cartier C, Garrel R and Crampette L: Atypical presentations of sinonasal inverted papilloma: Surgical management and influence on the recurrence rate. *Am J Rhinol Allergy* 30: 149-154, 2016.
64. Karligkiotis A, Lepera D, Volpi L, Turri-Zanoni M, Battaglia P, Lombardi D, Accorona R, Bignami M, Nicolai P and Castellnuovo P: Survival outcomes after endoscopic resection for sinonasal squamous cell carcinoma arising on inverted papilloma. *Head Neck* 38: 1604-1614, 2016.
65. Tsou YA, Huang HJ, Wang TC, Tai CJ, Chen CM and Chen CY: Evaluation of correlation of cell cycle proteins and Ki-67 interaction in paranasal sinus inverted papilloma prognosis and squamous cell carcinoma transformation. *Biomed Res Int* 2014: 634945, 2014.
66. Gunia S, Liebe D and Koch S: Loss of basal cell keratin 14 reflects increased risk of recurrence in surgically resected sinonasal inverted papilloma. *J Clin Pathol* 61: 707-712, 2008.
67. Liang J, Gao S, Zhang J, Ao H, Wei X and Luo H: Expression of survivin and Bcl-2 in sinonasal inverted papilloma. *Lin Chung Er Bi Yan Hou Tou Jing Wai Ke Za Zhi* 23: 933-935, 2009 (In Chinese).
68. Liu W, Li Z, Luo Q, Lai Y, Zhang J, Chen F, Shi J, Li H, Xiong G, Xu G and Wang H: The elevated expression of osteopontin and vascular endothelial growth factor in sinonasal inverted papilloma and its relationship with clinical severity. *Am J Rhinol Allergy* 25: 313-317, 2011.
69. Cai Y and Zhang J: Expression of fascin and correlation with MVD in sinonasal inverted papilloma. *Lin Chung Er Bi Yan Hou Tou Jing Wai Ke Za Zhi* 26: 629-632, 2012 (In Chinese).

70. Pajor AM, Danilewicz M, Stasikowska-Kanicka O and Józefowicz-Korczyńska M: The immunoexpression of CD34, Bcl-2, and Ki-67 antigens in sinonasal inverted papillomas. *Am J Rhinol Allergy* 28: e31-e34, 2014.
71. Shabana EH, Depondt J, Hourseau M, Walker F and Berdal A: Production and significance of CCAAT enhancer binding proteins alpha and beta in sinonasal inverted papilloma. *Histol Histopathol* 28: 53-60, 2013.
72. Suh JD, Palma-Diaz F, Bhuta S and Wang MB: COX-(2) overexpression in sinonasal inverted papilloma. *Int Forum Allergy Rhinol* 3: 997-1000, 2013.
73. Byun JY, Lee SH, Shin JM, Baek BJ and Lee JY: Overexpression of angiotensin in sinonasal inverted papilloma. *Int Forum Allergy Rhinol* 4: 512-516, 2014.
74. Zhang W, Wen S, Zhang T, Wang B, Gao W and Li L: Expression and significance of PTEN and HIF-1 α proteins in sinonasal inverted papilloma. *Zhonghua Er Bi Yan Hou Tou Jing Wai Ke Za Zhi* 49: 399-403, 2014 (In Chinese).
75. Lin H, Lin D and Xiong XS: Roles of human papillomavirus infection and stathmin in the pathogenesis of sinonasal inverted papilloma. *Head Neck* 38: 220-224, 2016.
76. Lee HJ and Kim JW: Immunohistochemical study on the expression of matrix metalloproteinase 2 and high-risk human papilloma virus in the malignant progression of papillomas. *J Korean Assoc Oral Maxillofac Surg* 39: 224-230, 2013.
77. Udager AM, Rolland DC, McHugh JB, Betz BL, Murga-Zamalloa C, Carey TE, Marentette LJ, Hermesen MA, DuRoss KE, Lim MS, *et al*: High-frequency targetable EGFR mutations in sinonasal squamous cell carcinomas arising from inverted sinonasal papilloma. *Cancer Res* 75: 2600-2606, 2015.
78. Scheel A, Lin GC, McHugh JB, Komarck CM, Walline HM, Prince ME, Zacharek MA and Carey TE: Human papillomavirus infection and biomarkers in sinonasal inverted papillomas: Clinical significance and molecular mechanisms. *Int Forum Allergy Rhinol* 5: 701-707, 2015.
79. Kim SG, Lee OY, Choi JW, Park YH, Kim YM, Yeo MK, Kim JM and Rha KS: Pattern of expression of cell cycle-related proteins in malignant transformation of sinonasal inverted papilloma. *Am J Rhinol Allergy* 25: 75-81, 2011.
80. Lin GC, Scheel A, Akkina S, Chinn S, Graham M, Komarck C, Walline H, McHugh JB, Prince ME, Carey TE and Zacharek MA: Epidermal growth factor receptor, p16, cyclin D1, and p53 staining patterns for inverted papilloma. *Int Forum Allergy Rhinol* 3: 885-889, 2013.
81. Oncel S, Cosgul T, Calli A, Calli C and Pinar E: Evaluation of p53, p63, p21, p27, ki-67 in paranasal sinus squamous cell carcinoma and inverted papilloma. *Indian J Otolaryngol Head Neck Surg* 63: 172-177, 2011.
82. Jung YG, Lee HW, Kim MG, Dhong HJ, Cho KS and Roh HJ: Role of Wnt signaling pathway in progression of sinonasal inverted papilloma to squamous cell carcinoma. *Am J Rhinol Allergy* 29: e81-e86, 2015.
83. Peng L, Shan C, Feng Z and Yang L: Expression and significance of survivin and PCNA in sinonasal inverted papilloma. *Lin Chung Er Bi Yan Hou Tou Jing Wai Ke Za Zhi* 27: 264-266, 2013 (In Chinese).
84. Hadar T, Shvero J, Yaniv E, Shvili I, Leabu M and Koren R: Human topoisomerase II-alpha is highly expressed in sinonasal-inverted papilloma, but not in inflammatory polyp. *J Cell Mol Med* 12: 1551-1558, 2008.
85. Starska K, Bryś M, Forma E, Olszewski J, Pietkiewicz P, Lewy-Trenda I, Stasikowska-Kanicka O, Danilewicz M and Krześlak A: Metallothionein 2A core promoter region genetic polymorphism and its impact on the risk, tumor behavior, and recurrences of sinonasal inverted papilloma (Schneiderian papilloma). *Tumour Biol* 36: 8559-8571, 2015.
86. Yu H, Liu Q, Wang H, Wang D, Hu L, Sun X and Liu J: The role of tissue factor pathway inhibitor-2 in malignant transformation of sinonasal inverted papilloma. *Eur Arch Otorhinolaryngol* 271: 2191-2196, 2014.
87. Wu HH, Zafar S, Huan Y, Yee H, Chiriboga L and Wang BY: Fascin over expression is associated with dysplastic changes in sinonasal inverted papillomas: A study of 47 cases. *Head Neck Pathol* 3: 212-216, 2009.
88. Schröck A, Göke F, Wagner P, Bode M, Franzen A, Braun M, Huss S, Agaimy A, Ihrler S, Menon R, *et al*: Sex determining region Y-box 2 (SOX2) amplification is an independent indicator of disease recurrence in sinonasal cancer. *PLoS One* 8: e59201, 2013.
89. Wu Q, Yang Y, Wu X, Zhao C, Cong L, Ruan B and Zhang J: Expression and significance of Msx2 and topo II-alpha in sinonasal inverted papilloma. *Lin Chung Er Bi Yan Hou Tou Jing Wai Ke Za Zhi* 26: 343-346, 2012 (In Chinese).
90. Zhang J, Yang Y, Tang Y, Wu X, Cong L and Ruan B: The quantification and significance of muscle segment homeobox gene Msx2, human topoisomerase II- α , HPV16 and VEGF in sinonasal inverted papilloma. *Lin Chung Er Bi Yan Hou Tou Jing Wai Ke Za Zhi* 28: 1819-1823, 2014 (In Chinese).
91. Wu Y, Cui S, Wu Q, Ma Z and Yuan W: Expression and significance of osteopontin and muscle segment homeobox gene Msx2 in sinonasal inverted papilloma. *Lin Chung Er Bi Yan Hou Tou Jing Wai Ke Za Zhi* 27: 1114-1117, 2013 (In Chinese).
92. Huang CC, Lee TJ, Chang PH, Lee YS, Chuang CC, Jhang YJ, Chen YW, Chen CW and Tsai CN: Desmoglein 3 is overexpressed in inverted papilloma and squamous cell carcinoma of sinonasal cavity. *Laryngoscope* 120: 26-29, 2010.
93. Yang L, Shan C, Huang H, Sun Y, Zhao Y, Wang L and Jia W: The expression of Smac and survivin in sinonasal inverted papilloma. *Lin Chung Er Bi Yan Hou Tou Jing Wai Ke Za Zhi* 27: 407-410, 2013 (In Chinese).
94. Huang CC, Lee TJ, Chang PH, Lee YS, Chuang CC, Jhang YJ, Chen YW, Chen CW, Fu CH and Tsai CN: Expression of cathepsin S and its inhibitor stefin A in sinonasal inverted papilloma. *Rhinology* 48: 352-357, 2010.
95. Koo BS, Jung BJ, Kim SG, Liang ZL, Yeong MK and Rha KS: Altered expression of E-cadherin and β -catenin in malignant transformation of sinonasal inverted papillomas. *Rhinology* 49: 479-485, 2011.
96. Lee GH, Yoon YH, Kim YM, Yeo MK, Liang ZL, Kim JM and Rha KS: Pattern of expression of cyclooxygenase-2 in malignant transformation of sinonasal inverted papilloma. *Am J Otolaryngol* 33: 585-589, 2012.
97. Yoon BN, Chon KM, Hong SL, Lee JH, Kim JY, Cho KS and Roh HJ: Inflammation and apoptosis in malignant transformation of sinonasal inverted papilloma: The role of the bridge molecules, cyclooxygenase-2, and nuclear factor κ B. *Am J Otolaryngol* 34: 22-30, 2013.
98. Chang PH, Huang CC, Lee TJ, Lee YS and Tsai CN: Downregulation of DLEC1 in sinonasal inverted papilloma and squamous cell carcinoma. *J Otolaryngol Head Neck Surg* 41: 94-101, 2012.
99. Jin J, Lee JW, Rha KS, Kim DW and Kim YM: Expression pattern of IQGAP1 in sinonasal inverted papillomas and squamous cell carcinomas. *Laryngoscope* 122: 2640-2646, 2012.
100. Yamashita Y, Hasegawa M, Deng Z, Maeda H, Kondo S, Kyuna A, Matayoshi S, Agena S, Uehara T, Kouzaki H, *et al*: Human papillomavirus infection and immunohistochemical expression of cell cycle proteins pRb, p53, and p16(INK4a) in sinonasal diseases. *Infect Agent Cancer* 10: 23, 2015.
101. Lou H, Fang J, Li P, Zhou W, Wang Y, Fan E, Li Y, Wang H, Liu Z, Xiao L, *et al*: Frequency, suppressive capacity, recruitment and induction mechanisms of regulatory T cells in sinonasal squamous cell carcinoma and nasal inverted papilloma. *PLoS One* 10: e0126463, 2015.
102. Sharafinski ME, Ferris RL, Ferrone S and Grandis JR: Epidermal growth factor receptor targeted therapy of squamous cell carcinoma of the head and neck. *Head Neck* 32: 1412-1421, 2010.