SPANDIDOS PUBLICATIONS

ONCOLOGY LETTERS 24: 449, 2022

A huge retroperitoneal ganglioneuroma in a middle-aged patient: Report of a diagnostically challenging case with review of the literature

RAWA BAPIR[1-3], TAHIR A. HAWRAMI[4], ISMAEEL AGHAWAYS[4], RAWA M. ALI[2,5], DILAN S. HIWA[4], DLSOZ M. HUSSEIN[2], FAHMI H. KAKAMAD[2-4] and ABDULWAHID M. SALIH[2,4]

[1]Department of Urology, Surgical Teaching Hospital; [2]Scientific Affair Department, Smart Health Tower; [3]Kscien Organization; [4]Department of Surgery, College of Medicine, University of Sulaymaniyah; [5]Department of Histopathology, Shorsh General Teaching Hospital, Pathology Lab, Sulaymaniyah, Kurdistan 46000, Iraq

Received April 12, 2022; Accepted August 3, 2022

DOI: 10.3892/ol.2022.13569

Abstract. Ganglioneuromas (GNs) are benign, slow-growing tumors of neural crest cell origin. On rare occasions, adipose cells have been detected in these tumors. The present study reported a case of a huge retroperitoneal GN misdiagnosed and mismanaged as a liposarcoma. A 54-year-old male patient presented with gradually progressing dull back pain with abdominal discomfort for the past 6 months. The patient had abdominal distention and mild right abdominal tenderness. Ultrasound of the abdomen and pelvis revealed a large right-sided retroperitoneal mass. Contrast-enhanced computed tomography findings were consistent with sarcoma. Cytologic examination was suggestive of liposarcoma. A decision was made to start neoadjuvant radiochemotherapy, which proved ineffective. Complete surgical excision of the mass was performed via a midline laparotomy. Histopathology of the mass confirmed the diagnosis of GN. At two years post-operation, the patient developed a recurrence in the subhepatic area with the same diagnosis and the recurrent mass was surgically removed. Initially, the imaging findings were not sufficiently specific to establish the diagnosis. Rarely, cytologic techniques have detected adipose cells in these tumors, resulting in misdiagnosis. Hence, histopathology is the gold standard for definitive diagnosis. Preoperative diagnosis of GN is difficult due to the lack of specific clinical manifestations, radiological confusion with other tumors and the presence of adipocytes in rare cases, leading to misdiagnosis and mismanagement.

Correspondence to: Dr Fahmi H. Kakamad, Department of Surgery, College of Medicine, University of Sulaymaniyah, 334 Madam Mitterrand Street, Sulaymaniyah, Kurdistan 46000, Iraq
E-mail: fahmi.hussein@univsul.edu.iq

Key words: ganglioneuroma, retroperitoneum, liposarcoma, misdiagnosis, mismanagement

Introduction

Ganglioneuromas (GNs) are highly differentiated benign tumors that arise from neural crest cells and may develop anywhere along the sympathetic chain (1). They are most commonly present in the posterior mediastinum (41.5%) and the retroperitoneum (37.5%) (2). The tumors are usually detected incidentally during radiological imaging for unrelated conditions. However, GN may also present when the tumor has grown sufficiently in size to the point that it may cause compression-related symptoms (3,4). These tumors are frequently non-secretory, but rare cases of hormone-secreting GNs have also been reported (5). The gold standard for the diagnosis of GN is histopathological examination, which characteristically indicates an admixture of ganglion cells and Schwann cells with the absence of immature elements (neuroblasts) (6). Less commonly, fine-needle aspiration (FNA) has also been suggested to aid in the diagnosis of GNs (7). On rare occasions, the presence of adipose cells has been detected in these tumors (8). This may result in the diagnostic confusion of GN via imaging and cytologic diagnostic approaches with other, more aggressive tumors, such as liposarcoma, leading to inappropriate management (9).

The present study reported a case of a huge retroperitoneal GN that was initially diagnosed and managed as liposarcoma and to acknowledge the possible presence of adipose cells in sporadic cases of GN. In the writing of the current paper, the SCARE 2020 Guidelines were taken into account (10).

Case report

Case presentation. A 54-year-old male patient presented to the Sulaymaniyah Surgical Teaching Hospital (Sulaymaniyah, Iraq) in August 2018 with gradually progressing dull backache and abdominal discomfort for the past six months. The pain radiated to the anterior thigh, with no relation to daily physical activity. There were no associated gastrointestinal symptoms. Having assumed a musculoskeletal origin for his pain, the patient had used different kinds of non-steroidal anti-inflammatory drugs and other analgesics without any improvement.

The patient had been diagnosed with type 2 diabetes mellitus and was on metformin 500 mg twice daily.

Clinical findings. The patient's vital signs were stable. Physical examination revealed abdominal distension and mild tenderness on the right side of the abdomen.

Diagnostic approach. Ultrasound of the abdomen and pelvis revealed a large right-sided retroperitoneal mass; however, it was unable to show the detailed characteristics of the mass. Contrast-enhanced computed tomography (CT) of the abdomen and pelvis indicated a right-sided multilobulated retroperitoneal mass with the dimensions of 45x22x23 cm. The mass displaced the right kidney anteromedially and extended up to the liver. The radiological features were consistent with sarcoma (Fig. 1). CT scan of the chest was normal. FNA and core biopsy were performed on the mass and the pathologic examination was suggestive of myxoid liposarcoma. The multidisciplinary team (MDT) discussed the case and a decision was made to start neoadjuvant radiochemotherapy. The patient received 25 sessions of radiation therapy followed by four cycles of ifosfamide and doxorubicin according to the National Comprehensive Cancer Network (NCCN) guidelines (11). However, in the middle of the cycles, a new CT scan was performed to assess the patient's response to the treatments, which indicated no reduction in the mass size. The patient's condition was discussed once again by the MDT and surgical resection of the mass was determined to be the best course of action.

Therapeutic intervention and perioperative diagnosis. The operation was performed through a midline laparotomy under general anesthesia and the mass was resected *en bloc* (Fig. 2). The post-operative period was uneventful and the patient was discharged on the fourth postoperative day. The mass measured 45x35x25 cm and weighed 10 kilograms. Histopathologic examination according to standard protocols indicated an encapsulated, hypocellular tumor composed of ganglion cells within an edematous, collagenous to myxoid background. Immunohistochemical analysis indicated positive reaction of the tumor cells to vimentin, S-100 and neuron-specific enolase (NSE), while stains for smooth muscle actin (SMA) and calretinin were negative. According to standard protocols, the following antibodies were used for immunohistochemistry: S100 (cat. no. Z0311; dilution, 0.3:100; Dako Denmark A/S), NSE (cat. no. BSB 5824; dilution, 0.7:100; Bio SB), Vimentin (cat. no. M0725; dilution, 1.3:100; Dako Denmark A/S), calretinin (cat. no. M7245; dilution, 2:100; Dako Denmark A/S) and SMA (cat. no. M0851; dilution, 1.3:100; Dako Denmark A/S). The overall histology combined with the immunohistochemical findings were consistent with a diagnosis of ganglioneuroma (Fig. 3).

Follow-up and outcome. In October 2020, a follow-up MRI showed 2 recurrent masses in the right subphrenic area. The patient underwent a second operation in December 2020. In all aspects, the recurrence was the same as the primary tumor, radiologically and pathologically. In May 2021, imaging follow-up showed another recurrence in the same position and the patient underwent a third operation in July 2021 with similar postoperative histopathological findings. Unfortunately, the mass recurred again in February 2022, and a 6-cm mass was observed on a CT scan. The patient refused further intervention and rapid enlargement of the size of the mass was seen on follow-up. In May 2022, the mass had reached a size of 18 cm. The patient passed away in June 2022 due to a cardiovascular event.

Discussion

A literature review was performed through the CINAHL, PubMed/MEDLINE, Cochrane Library, Web of Science and EMBASE databases to identify studies published up to January 2022. The search was performed using the following key words: Ganglioneuroma, retroperitoneal, retroperitoneum, liposarcoma, misdiagnosis, mismanagement.

GNs are benign, slow-growing tumors of neural crest cell origin that arise along the sympathetic chain (1). The tumor was first described in 1870 (6). Less commonly, GN may involve the medulla of the adrenal glands, the parapharyngeal region and the visceral ganglia (3). Although most studies indicate a higher prevalence among females (9,12), other studies have indicated no gender preference (13). The current case was a male with a huge GN presenting in the retroperitoneum.

GNs are mostly asymptomatic. Symptoms, when present, are relatively non-specific and include abdominal, back and neck pain, vomiting, hemoptysis and shortness of breath due to the pressure exerted on adjacent orangs by the enlarging tumor. Referred pain to the lower limbs with paresthesia and numbness to due to big retroperitoneal ganglioneuroma has also been documented (2,14-16). The patient of the present study had abdominal and back pain. Rare cases of hormonally active GN have been reported in the literature with symptoms of palpitation, tremor, anxiety, flushing, diaphoresis, diarrhea and hypertension, which are due to the secretion of catecholamine, cortisol or vasoactive intestinal peptide by the tumor (17).

Imaging techniques (CT scan or magnetic resonance imaging) in patients with retroperitoneal masses are utilized to describe the tumor's size and location, and to delineate its anatomic relationship with the neighboring structures, which is essential for surgical management, as most retroperitoneal tumors are malignant (18,19). A CT scan of GN generally indicates a well-demarcated oval mass with low to intermediate attenuation and punctate calcifications in 20% of cases. These findings, however, are not diagnostic and are insufficient to make an accurate diagnosis (20). Misdiagnosis of GN as sarcoma has been reported via CT scan in certain cases due to irregular mixed density (9). Workup of the initial CT of the patient of the present study was also suggestive of sarcoma.

FNA has been suggested to assist in the diagnosis of GN (7,21). The cytologic features of GN have been described as reasonably distinctive, provided that the smear contains both ganglion and spindle cell components. The ganglioneuroma elements are composed of relatively mature ganglion cells, Schwann cells and nerve fibers. The ganglion cells may be identified by their abundant eosinophilic cytoplasm, large nuclei and prominent nucleoli, and the lipomatous areas consist of mature adipocytes without atypia (8). However, in the present case, FNA was suggestive of myxoid liposarcoma due to the presence of adipocytes and the lack

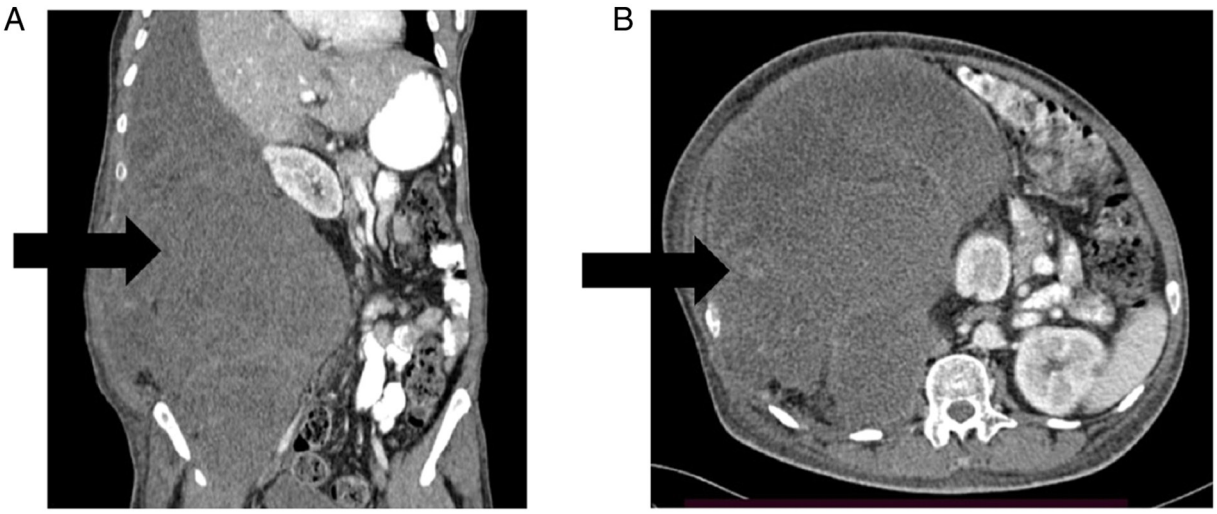

Figure 1. (A) Coronal and (B) Axial CT scans indicating a large right-sided retroperitoneal mass (arrows), medially displacing the right kidney and liver.

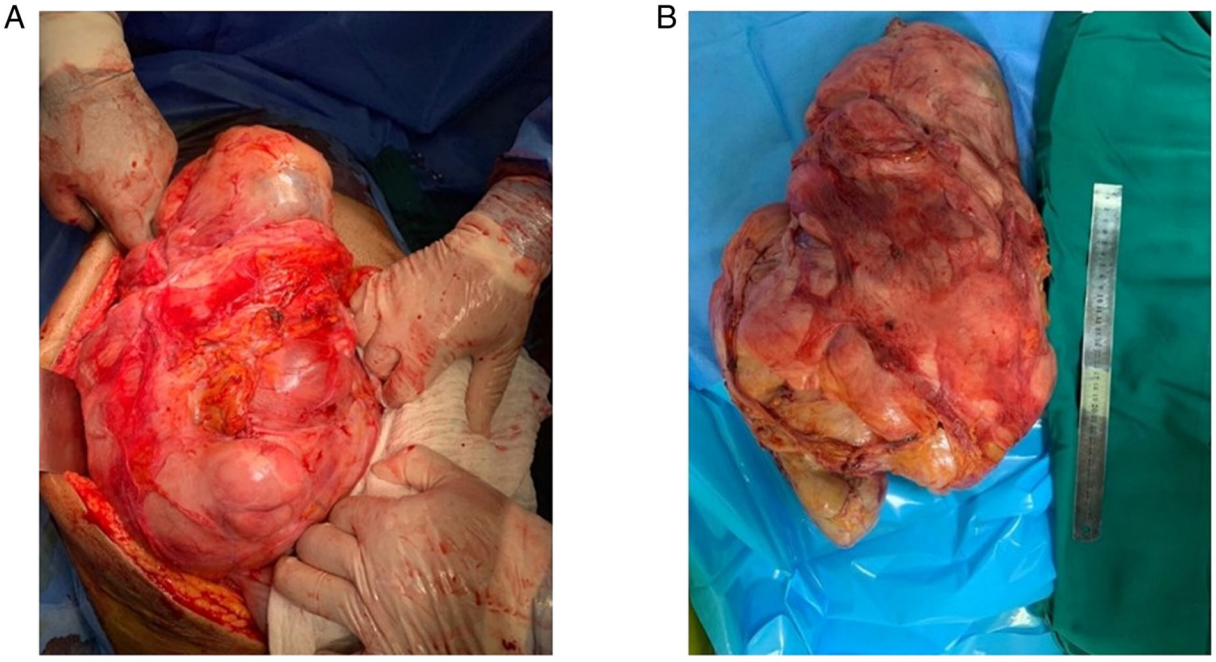

Figure 2. (A) Intraoperative picture indicating a big mass occupying the entire abdomen. (B) Gross appearance of the mass after it was totally removed.

of spindle cells and ganglion cells in the smear, and due to this misdiagnosis, chemotherapy and radiation were administered to the patient. Similar observations have been made in other rare cases of GN, as showcased by Meng *et al* (22). Radiological features and even FNA give crucial clues but are not diagnostic as is histopathological examination of the specimen.

There are two hypotheses for the histogenesis of fat in GN: First, spontaneous degeneration of the tumor leads to fatty replacement in the tumor, which is a reasonable explanation in the present case, considering the large size and the time it took to reach that size. The second hypothesis is that due to the origin of GNs from neural crest cells, which are regarded as ectomesenchyme, they may have the potential to undergo lipometaplasia and differentiate into adipocytes (22).

Although GNs represent the benign end of the spectrum compared to their ganglion tumor counterparts, ganglioneuroblastoma, and neuroblastoma constitute the malignant end of the spectrum. Among a total of 49 patients with GN, two cases of malignant transformation and metastasis have been documented (13). This leads to a controversy regarding GN management in circumstances where complete resection of the tumor imposes a high risk of mortality and morbidity on the patient.

Surgical removal of GN is curative in most cases, with a low incidence of recurrence (2). Xiao *et al* (9) demonstrated that among 32 patients with GN, two patients chose surveillance instead of an operation and the tumor remained stable during follow-up in both cases. Among the other 30 patients, four had the tumor incompletely resected and they still did

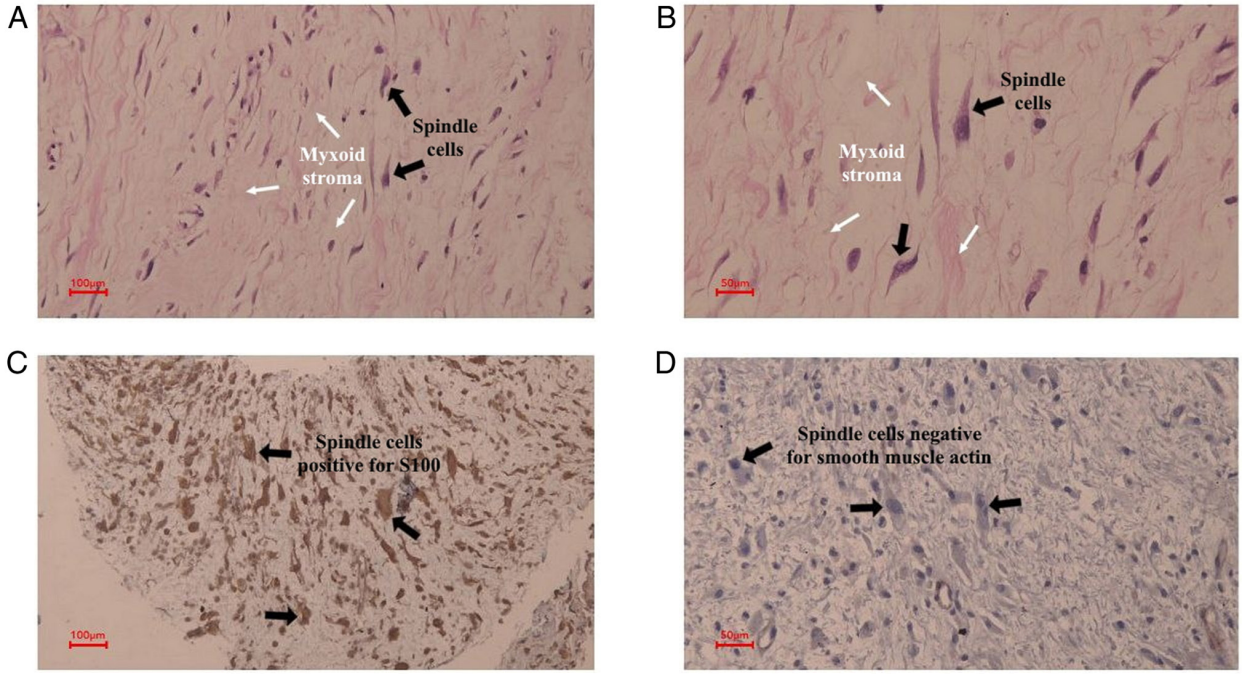

Figure 3. Histopathologic examination of the mass. (A) The tumor is hypocellular and is composed of scattered spindle cells; certain cells had large, round nuclei with fine chromatin and occasional nucleoli (black arrows), lying within a loose, edematous, focally myxoid stroma (white arrows) (H&E; scale bar, 100 μm; magnification, x20). (B) Magnified window from A (scale bar, 50 μm; magnification, x40). (C) The spindle cells, including the ones with larger nuclei (black arrows), are positive for S100 in a strong, cytoplasmic and nuclear pattern (scale bar, 100 μm; magnification, x20). (D) The spindle cells (black arrows) are negative for smooth muscle actin (scale bar, 50 μm; magnification, x40).

not exhibit any signs of progression or malignancy during follow-up (9). However, the present case exhibited a recurrence of GN in the subhepatic area two years after the operation. Histopathology remains the gold standard for diagnosing GN, which characteristically indicates an admixture of Schwann cells and ganglion cells in the absence of immature cells (neuroblasts). Immunohistochemistry further supports the diagnosis (6). What made the diagnosis difficult in the present case was that the tumor enlarged rapidly and the FNA indicated atypical cells, which was misleading to the pathologist.

There were certain limitations to this report, as no molecular analysis was performed. For GN, no molecular test appeared to be available; however, a test for liposarcoma exists, but there was no access to it at our hospital.

In conclusion, preoperative diagnosis of GN is difficult due to radiological confusion with other tumors and a lack of specific clinical manifestations, leading to misdiagnosis and mismanagement. FNA may help with the diagnosis, but the current case demonstrated the importance of taking aspirates from multiple sites, particularly for large tumors, due to the confounding presence of adipocytes in rare cases of GN. Histopathological examination is the only method for a definitive diagnosis.

Acknowledgements

Not applicable.

Funding

No funding was received.

Availability of data and materials

The datasets used and/or analyzed during the current study are available from the corresponding author on reasonable request.

Authors' contributions

RB: Surgeon performing the operation, major contribution to the conception of the study, literature review, final approval of the manuscript. FHK: Literature review, writing the manuscript, final approval of the manuscript, major contribution to the conception of the study. RMA: Pathological examination, major contribution to the conception of the study and revision of the manuscript. DSH and DMH: Acquisition of data and revision of the manuscript.. TAH, IA and AMS: Major contribution to the conception of the study and revision and final revision of the manuscript. RB and FHK confirm the authenticity of all the raw data All authors read and approved the final manuscript.

Ethics approval and consent to participate

Not applicable.

Patient consent for publication

The patient and patient's family provided written informed consent for the publication of the patient's data and images.

Competing interests

The authors declare that they have no competing interests.

References

1. Yang Y, Ren M, Yuan Z, Li K, Zhang Z, Zhang J, Xie L and Yang Z: Thoracolumbar paravertebral giant ganglioneuroma and scoliosis: A case report and literature review. World J Surg Oncol 14: 65, 2016.
2. Silveira CRS, Vieira CGM, Pereira BM, Junior LE, Gerson G, Távora DGF and Chhabra A: Magnetic resonance neurography in the diagnosis of a retroperitoneal ganglioneuroma: Case report and literature review. Radiol Case Rep 13: 380-385, 2018.
3. Yam B, Walczyk K, Mohanty SK, Coren CV and Katz DS: Radiology-pathology conference: Incidental posterior mediastinal ganglioneuroma. Clin Imaging 33: 390-394, 2009.
4. Hussain MH, Iqbal Z, Mithani MS and Khan MN: Retroperitoneal ganglioneuroma in a patient presenting with vague abdominal pain. Cureus 12: e9133, 2020.
5. Shah A, Thummar D, Mehta M, Shah D, Suryanarayan U and Anand D: Hormone-secreting ganglioneuroma: A rare entity. J Radiat Cancer Res 12: 131-133, 2021.
6. Spinelli C, Rossi L, Barbetta A, Ugolini C and Strambi S: Incidental ganglioneuromas: A presentation of 14 surgical cases and literature review. J Endocrinol Invest 38: 547-554, 2015.
7. Domanski HA: Fine-needle aspiration of ganglioneuroma. Diagn Cytopathol 32: 363-366, 2005.
8. Adachi S, Kawamura N, Hatano K, Kakuta Y, Takada T, Hara T and Yamaguchi S: Lipomatous ganglioneuroma of the retroperitoneum. Pathol Int 58: 183-186, 2008.
9. Xiao J, Zhao Z, Li B and Zhang T: Primary retroperitoneal ganglioneuroma: A retrospective cohort study of 32 patients. Front Surg 8: 642451, 2021.
10. Agha RA, Franchi T, Sohrabi C, Mathew G and Kerwan A; SCARE Group: The SCARE 2020 guideline: Updating consensus Surgical CAse REport (SCARE) guidelines. Int J Surg 84: 226-230, 2020.
11. Von Mehren M, Randall RL, Benjamin RS, Boles S, Bui MM, Ganjoo KN, George S, Gonzalez RJ, Heslin MJ, Kane JM, *et al*: Soft tissue sarcoma, version 2.2018, NCCN clinical practice guidelines in oncology. J Natl Compr Canc Netw 16: 536-563, 2018.
12. De Bernardi B, Gambini C, Haupt R, Granata C, Rizzo A, Conte M, Tonini GP, Bianchi M, Giuliano M, Luksch R, *et al*: Retrospective study of childhood ganglioneuroma. J Clin Oncol 26: 1710-1716, 2008.
13. Geoerger B, Hero B, Harms D, Grebe J, Scheidhauer K and Berthold F: Metabolic activity and clinical features of primary ganglioneuromas. Cancer 91: 1905-1913, 2001.
14. Esen HK, Esen O and Irsi C: Retroperitoneal ganglioneuroma: Mimicking an ovarian mass in a child. Pak J Med Sci 31: 724-726, 2015.
15. Hayat J, Ahmed R, Alizai S and Awan MU: Giant ganglioneuroma of the posterior mediastinum. Interact Cardiovasc Thorac Surg 13: 344-345, 2011.
16. Papaetis GS, Georgiadis CP, Tsitskari MA, Constantinou PG and Antoniou AP: Retroperitoneal ganglioneuroma causing chronic lower back and leg pain in an 80-year-old man: A case report. Ann Med Surg (Lond) 61: 101-103, 2020.
17. Erem C, Fidan M, Civan N, Cobanoglu U, Kangul F, Nuhoglu I and Alhan E: Hormone-secreting large adrenal ganglioneuroma in an adult patient: A case report and review of literature. Blood Press 23: 64-69, 2014.
18. Zografos GN, Farfaras A, Vasiliadis G, Pappa T, Aggeli C, Vasilatou E, Kaltsas G and Piaditis G: Laparoscopic resection of large adrenal tumors. JSLS 14: 364-368, 2010.
19. Al-Ali MHM, Salih AM, Ahmed OF, Kakamad FH, Mohammed SH, Hassan MN, Sidiq SH, Mustafa MQ, Najar KA and Abdullah IY: Retroperitoneal lipoma; a benign condition with frightening presentation. Int J Surg Case Rep 57: 63-66, 2019.
20. Duffy S, Jhaveri M, Scudierre J, Cochran E and Huckman M: MR imaging of a posterior mediastinal ganglioneuroma: Fat as a useful diagnostic sign. AJNR Am J Neuroradiol 26: 2658-2662, 2005.
21. Jain M, Shubha BS, Sethi S, Banga V and Bagga D: Retroperitoneal ganglioneuroma: Report of a case diagnosed by fine-needle aspiration cytology, with review of the literature. Diagn Cytopathol 21: 194-196, 1999.
22. Meng QD, Ma XN, Wei H, Pan RH, Jiang W and Chen FS: Lipomatous ganglioneuroma of the retroperitoneum. Asian J Surg 39: 116-119, 2016.