SPANDIDOS PUBLICATIONS

ONCOLOGY LETTERS 25: 60, 2023

Differential diagnostic value of magnetic resonance diffusion-weighted imaging and apparent diffusion coefficient for renal clear cell carcinoma and non-clear cell carcinoma

XIAOZHONG LI[1], XUYANG XIANG[2] and HUI TING LIN[2]

[1]Department of Radiology, Affiliated Hospital of Gansu University of Chinese Medicine, Lanzhou, Gansu 730020; [2]The First Clinical Medical School, Gansu University of Chinese Medicine, Lanzhou, Gansu 730000, P.R. China

Received July 11, 2022; Accepted December 5, 2022

DOI: 10.3892/ol.2022.13647

Abstract. Accurate identification of renal cell carcinoma (RCC) subtypes before surgery is important to determine appropriate surgical methods and clinical prognosis. The objective of the present study was to investigate the differential diagnostic value of magnetic resonance diffusion-weighted imaging (MRI-DWI) and the measured apparent diffusion coefficient (ADC) in clear cell (cc) RCC and non-ccRCC. Imaging data (DWI and ADC) from 100 patients with pathologically confirmed RCC from March 2018 to March 2021 in Affiliated Hospital of Gansu University of Chinese Medicine, (Lanzhou, China) were retrospectively analyzed, including 32 cases of non-ccRCC (21 cases of chromophobe and 11 cases of papillary cell carcinoma) and 68 cases of ccRCC. Patients underwent MRI examination, including high and low B-value DWI, to compare the imaging features of the two RCC subtypes and the ADC values of tumor sites were measured. The results of the DWI and ADC were statistically different between the two RCC subtypes ($P<0.01$). The DWI of ccRCC was primarily low, equal or slightly high signal. ADC of ccRCC was mainly equal or slightly high signal and the high B-value DWI signal was lower than the low B-value DWI. DWI of non-ccRCC was mostly obviously high signal. ADC of non-ccRCC was mostly uniform, obviously low signal and the high B-value DWI signal was markedly higher than the low B-value DWI. The ADC values of non-ccRCC were lower than those of ccRCC, and the ADC values $<1.42\pm0.48\times10^{-3}$ mm^2/s were mostly non-ccRCC. In conclusion, MRI-DWI and ADC can be used to differentiate subtypes of RCC to determine appropriate surgical methods and clinical prognosis.

Correspondence to: Dr Xiaozhong Li, Department of Radiology, Affiliated Hospital of Gansu University of Chinese Medicine, 732 Jiayuguan West Road, Lanzhou, Gansu 730020, P.R. China
E-mail: lixiaozhong925@163.com

Key words: non-clear cell renal cell carcinoma, MRI, clear cell renal cell carcinoma, diffusion-weighted imaging, apparent diffusion coefficient, differential diagnosis

Introduction

Renal cell carcinoma (RCC) is the most common type of malignant tumor of the kidney with incidence and mortality rates of 2-3 and 1-2% (according to the National Cancer Registration Annual Report 2015-2019 in China) (1), respectively. The specific cause of RCC is still unknown. In general, smoking, drinking and other living habits, taking hormone drugs and basic diseases are the main factors leading to the onset of renal cell carcinoma (2). The most common RCC subtypes are clear cell (cc) and non-ccRCC. Surgery is ccRCC and non-ccRCC typically treated. Due to higher malignancy in non-ccRCC, surgical treatment and clinical prognosis are also different; the malignant degree of non-ccRCC is higher than that of ccRCC, cc-RCC only remove the tumor and retain the normal part of the kidney. non-ccRCC must expand the scope of surgery, or even remove the entire the diseased kidney. The prognosis of CC-RCC is better than that of non-ccRCC (2,3). Accurate identification of RCC subtypes before surgery is important to determine appropriate surgical methods and clinical prognosis. Currently, imaging differentiation of ccRCC and non-ccRCC is primarily based on dynamic enhancement scans of magnetic resonance imaging (MRI) (4,5). Different image characteristics are also shown on MRI-enhanced examination due to the different hemodynamic performances of different subtypes of RCC (1,6-8). ccRCC is a tumor with multiple blood supply on MRI contrast-enhanced, while non-ccRCC is a tumor with less blood supply but, enhanced examination may cause allergic reaction to contrast agent. MRI-DWI sequence is a fast excitation signal in magnetic field, which can detect the movement of water molecules. ADC is the apparent dispersion coefficient. Certain types of malignant tumors have dense growth cells, less free water, limited diffusion in malignant tumors, MRI-DWI is high signal whereas ADC is low signal, which can be used to diagnose tumors. The objective of the present study was to investigate the differential diagnostic value of MRI-DWI and ADC in ccRCC and non-ccRCC.

Patients and methods

Patient information. Imaging data from 100 patients with RCC confirmed by pathology Affiliated Hospital of Gansu

University of Chinese Medicine, (Lanzhou, China) from March 2018 to March 2021 were retrospectively analyzed. The inclusion criteria were patients with pathologically proven RCC. The exclusion criteria: All patients with renal cancer diagnosed and treated by drugs or surgery. The patients were assigned to two groups according to RCC subtype (ccRCC and non-ccRCC). The ccRCC group consisted of 68 cases (42 males and 26 females) with a tumor size range of 0.6-5.4 cm, median tumor size of 3.4 cm, and the following tumor stages: Grade 1 in 15 cases, grade 2 in 32 cases, grade 3 in 11 cases and grade 4 in 10 cases. staging and typing criteria: the pathological staging of renal cell carcinoma shall refer to the American Joint Cancer Commission The TNM staging system and pathological classification of renal cell carcinoma refer to the classification standard formulated by the World Health Organization (9,10). The age of the patients in the ccRCC group was 35-59 years with a median age of 52 years. The course of the disease ranged from 6 months to 2.5 years, with a median of 1.7 years. There were 32 cases in the non-ccRCC group (21 cases of chromophobe and 11 cases of papillary cell carcinoma), with a tumor size range of 2.4-6.5 cm, median tumor size of 4.4 cm and the following tumor stages: Grade 1 in 9 cases, grade 2 in 14 cases, grade 3 in 5 cases and grade 4 in 4 cases. Patients in the non-ccRCC group included 20 males and 12 females, aged 34-60 years, with a median age of 58 years. The course of the disease ranged from 5 months to 2 years, with a median of 1.5 years. Patient characteristics and tumor staging information are listed in Tables I and II, respectively. The study was approved [approval no. (2018)25] by the Affiliated Hospital of Gansu University of Chinese Medicine Ethics Committee. Written consent was obtained from all patients to participate.

MRI examination. All patients underwent routine MRI examinations, including high and low B-value DWI and ADC determination. The 1.5 T superconducting MRI instrument provided by Shanghai United Imaging Healthcare Co., Ltd. was used. The scanning parameters were as follows: Coronal T2W1, echo time (TE) 93 ms, repetition time (TR) 700 ms. DWI was imaged using echo planar imaging-DWI with the following parameters: TR/TE, 3200/94 ms; slice thickness, 6 mm; field of view, 350x350 mm; B-value, 50 or 800 s/mm^2. The ADC of the solid part of the tumor was also measured using the Function software (version no: V4.2; Beijing Si Chuang Guan Yu Technology Development Co., Ltd.) that came with the device. The intensity of DWI and ADC signals were observed and interpreted by two experienced associate physicians (LX and XY) in the MRI room for blind diagnostic reading. In the event of disagreement, a final decision was made by mutual consultation.

Observation indicators and standards. According to the study by Erbay *et al* (3), DWI signal was defined relative to renal parenchyma as follows: low, obviously low, equal, high, slightly high, significantly high signal. The ADC signal was judged by the same criteria. In addition, if the ADC signal of the lesion was significantly lower than the renal parenchyma, it was judged as a significantly low signal.

Statistical analysis. SPSS 20.0 (IBM Corp.) was used to analyze the study data. χ^2 test (using mean ± SD) represented the measured data. P<0.05 was considered to indicate a statistically significant difference. ADC threshold was determined by the receiver operating characteristic (ROC) curve.

Results

Patient information. There were no significant differences in general characteristics between the two groups (Table I). There was no significant association between tumor size and identification using MRI-DWI and ADC (Table II).

DWI and ADC assessment. There were significant differences in DWI and ADC signal between the ccRCC and non-ccRCC groups (Table III). For B-800, the sensitivity and specificity of predicting ccRCC with MRI-DWI was 0.912 and 0.437, respectively. The sensitivity and specificity of predicting non-ccRCC with MRI-DWI was 0.954 and 0.426, respectively. The area under the red ROC curve was 0.873 (Fig. 1).

The median average ADC value of ccRCC was 2.84±1.35x10^{-3} mm^2/s, meanwhile, non-ccRCC papillary cell carcinoma was 1.42±0.78x10^{-3} mm^2/s and chromophobe cell carcinoma was 1.34±0.52x10^{-3} mm^2/s. The median average ADC value of ccRCC was significantly higher than that of non-ccRCC.

Imaging characteristics of DWI and ADC in the diagnosis of non-ccRCC. Of the 32 non-ccRCC cases, there were 21 cases of chromophobe cell carcinoma. For DWI B-value=50 s/mm^2, 17 of the 21 cases (80.95%) were judged as a slightly high and four cases (19.05%) as high signal. For DWI B-value=800 s/mm^2, five of the 21 cases (23.81%) were judged as high and 16 cases (76.19%) as significantly high signal. Additionally, for ADC, 4 cases (19.05%) were judged as low and 17 cases (80.95%) as significantly low signal. Representative MRI scans are depicted in Fig. 2.

In 11 cases of papillary cell carcinoma, for DWI B-value=50 s/mm^2, eight cases (72.73%) were judged as slightly high and three cases (27.28%) as high signal. For DWI B-value=800 s/mm^2, two cases (18.18%) were judged as high signal and nine cases (81.82%) as significantly high signal. Additionally, for ADC, three cases (27.27%) were judged as low signal and eight cases (72.73%) as significantly low signal. Representative MRI scans are depicted in Fig. 3.

Imaging characteristics of DWI and ADC in the diagnosis of ccRCC. There were 68 cases of ccRCC. For DWI B-value=50 s/mm^2, 52 of 68 cases (76.47%) were judged as slightly high and 16 cases (23.53%) as high signal. For DWI B-value=800 s/mm^2, 19 cases (27.94%) were judged as slightly high, 16 cases (23.53%) as equal and 33 cases (48.53%) as low signal. Meanwhile, for ADC, 14 cases were judged as low signal (20.59%), 23 (33.82%) as equisignal and 31 cases (45.59%) as slightly high signal. Representative MRI scans are depicted in Fig. 4.

Discussion

RCC accounts for 85-90% of renal tumors (9). Papillary cell carcinoma and ccRCC are the two most common of the five

Table I. Patient characteristics.

Disease subtype	Male, n	Female, n	Age range, years	Median age, years	Median disease course, years
ccRCC	42	26	35-59	52	1.7
Non-ccRCC	20	12	34-60	58	1.5

ccRCC, clear cell renal cell carcinoma.

Table II. Tumor stage[a] and size.

Disease subtype	1	2	3	4	Tumor size range, cm	Median tumor size, cm
ccRCC	15	32	11	10	0.6-5.4	3.4
Non-ccRCC	9	14	5	4	2.4-6.5	4.4

[a]Determined based on classification standard formulated by the World Health Organization (9,10). ccRCC, clear cell renal cell carcinoma.

Table III. Comparison of DWI and ADC assessment between the ccRCC (n=68) and non-ccRCC (n=32) groups.

Assessment method	DWI (B=50)		DWI (B=800)		ADC	
Disease subtype	ccRCC	Non-ccRCC	ccRCC	Non-ccRCC	ccRCC	Non-ccRCC
Signal						
Low, n	0	0	33	0	14	7
Obviously low, n	0	0	0	0	0	25
Equal, n	0	0	16	0	23	0
Slightly high, n	52	25	19	0	31	0
High, n	16	7	0	7	0	0
Significantly high, n	0	0	0	25	0	0
P-value	<0.001		<0.001		<0.001	
Sensitivity	0.941	0.923	0.912	0.954	0.912	0.928
Specificity	0.344	0.328	0.437	0.426	0.531	0.536

Signal was defined as described by Erbay *et al* (3). ADC, apparent diffusion coefficient; ccRCC, clear cell renal cell carcinoma; DWI, diffusion-weighted imaging.

subtypes of RCC, accounting for 10-15 and 70-80%, respectively. According to a previous study, the 5-year survival rate of chromophobe and papillary cell carcinoma is 87-100% (10), while the 5-year survival rate of ccRCC is ~69% (11). Therefore, preoperative MRI examination to determine the subtype of RCC is key to formulate a reasonable surgical approach and accurately evaluate the prognosis.

At present, in differentiating ccRCC and non-ccRCC, the commonly used method for dynamic enhanced MRI (12), the CT plain scan, has no obvious value in the diagnosis of cc carcinoma and non-cc carcinoma (13). Triphasic dynamic-enhanced MRI in renal tissue involves cortical, parenchyma phase and delayed phase. The tumor in cortical phase is significantly enhanced, and the tumor in cortical phase is not enhanced, and the tumor in the delayed phase is enhanced (14,15). In the present study, only MRI plain scan, DWI and ADC distinguished ccRCC from non-ccRCC. The ADC value of ccRCC was lower than that of non-ccRCC, and DWI signal intensity of ccRCC was higher than that of non-ccRCC. DWI and ADC therefore distinguished between ccRCC and non-ccRCC. Compared with traditional MRI, there is no marked difference in the image identification of ccRCC and non-ccRCC on T1 and T2. Compared with traditional MRI T1 and T2, the signal strength of DWI and the quantitative analysis of ADC have good discriminating value in image identification of ccRCC and non-ccRCC (13).

In the present study, of non-cc chromophobe cell carcinoma cases, 80.95% analyzed using DWI B-value=50 s/mm^2 were judged as slightly high signal, 76.19% using DWI B-value=800 s/mm^2 were significantly high signal and 80.95% using ADC were

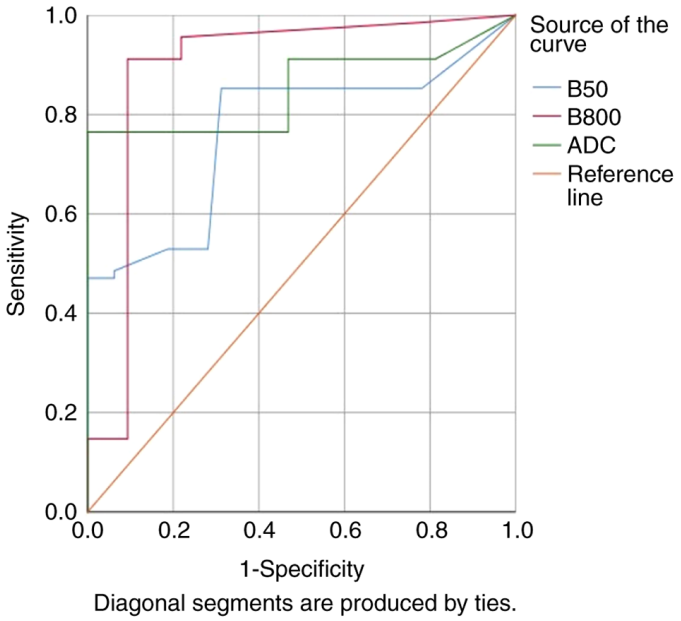

Figure 1. ROC curves of the two diffusion-weighted imaging groups (B50 and B800) and ADC. ADC, apparent diffusion coefficient; ROC, receiver operating characteristic.

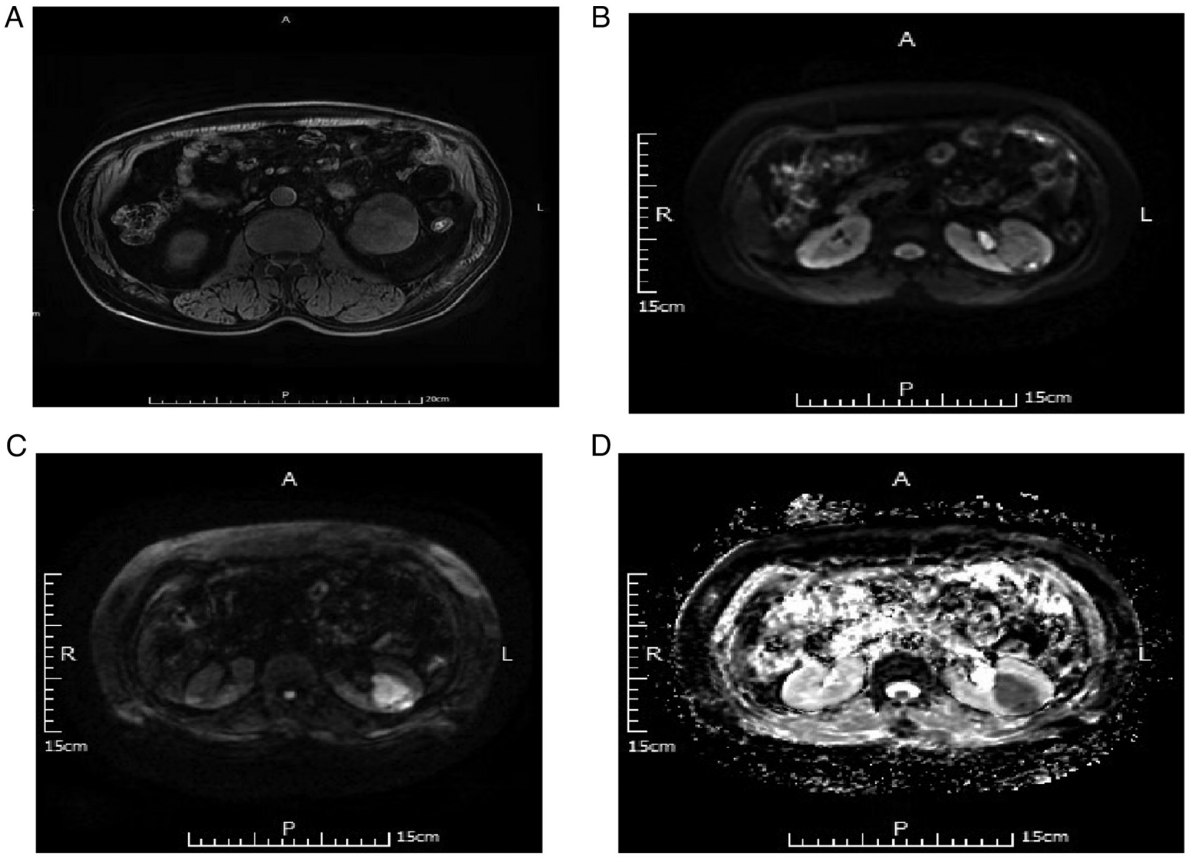

Figure 2. MRI scans of a 56-year-old male with pathologically confirmed chromophobe cell carcinoma of the left kidney. (A) T1WI, left renal tumor with low signal. (B) DWI B=50, left renal tumor with low signal. (C) DWI B=800, left renal tumor with obvious high signal. (D) Apparent diffusion coefficient with obviously low signal. DWI, diffusion-weighted imaging.

significantly low signal. The results of the present study therefore showed that the DWI signal of chromophobe cell carcinoma with using high B-value was higher than that with the low B-value, while ADC with an obvious, uniform low signal was observed in most cases, which may be associated with less cystic degeneration and necrosis in non-cc carcinoma.

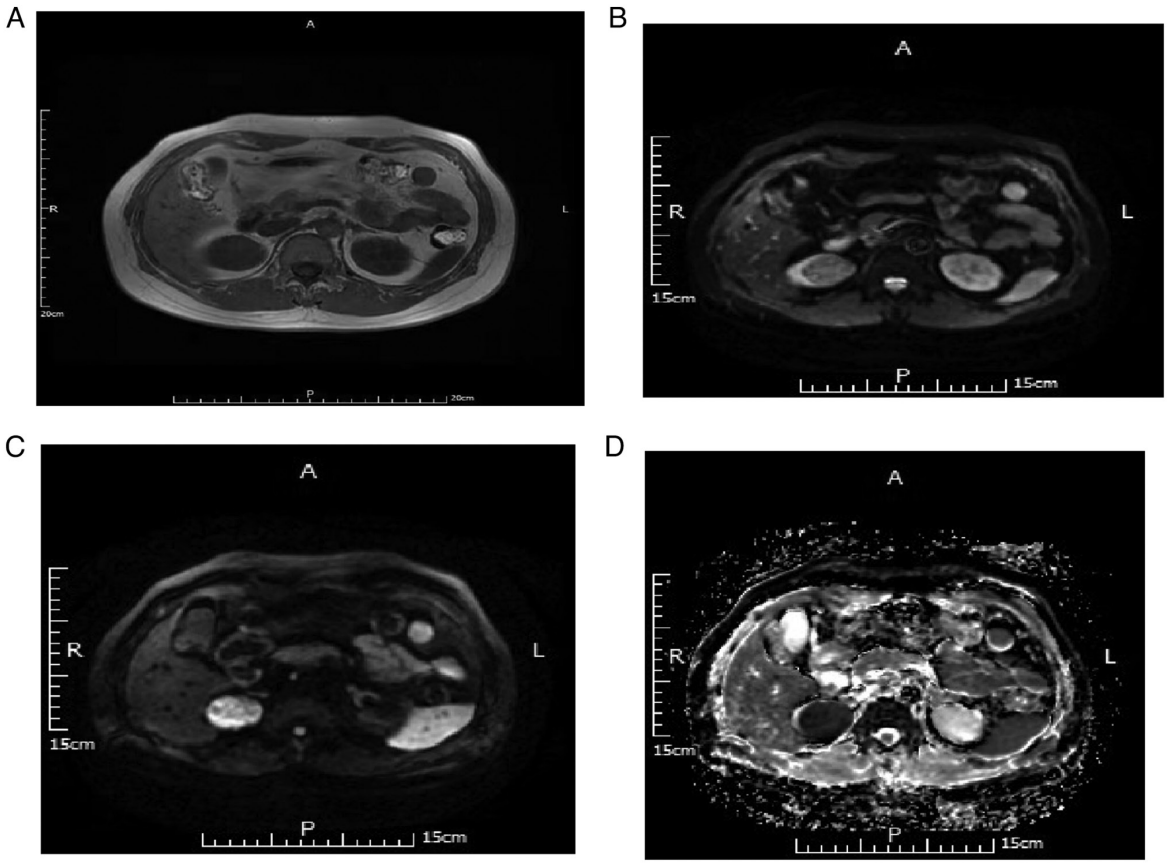

Figure 3. MRI scans of a 63-year-old male with pathologically confirmed renal papillary carcinoma of the right kidney. (A) T1WI, right renal tumor with low signal. (B) DWI B=50, right renal tumor with low signal. (C) DWI B=800, right renal tumor with high signal. (D) Apparent diffusion coefficient with low signal. DWI, diffusion-weighted imaging.

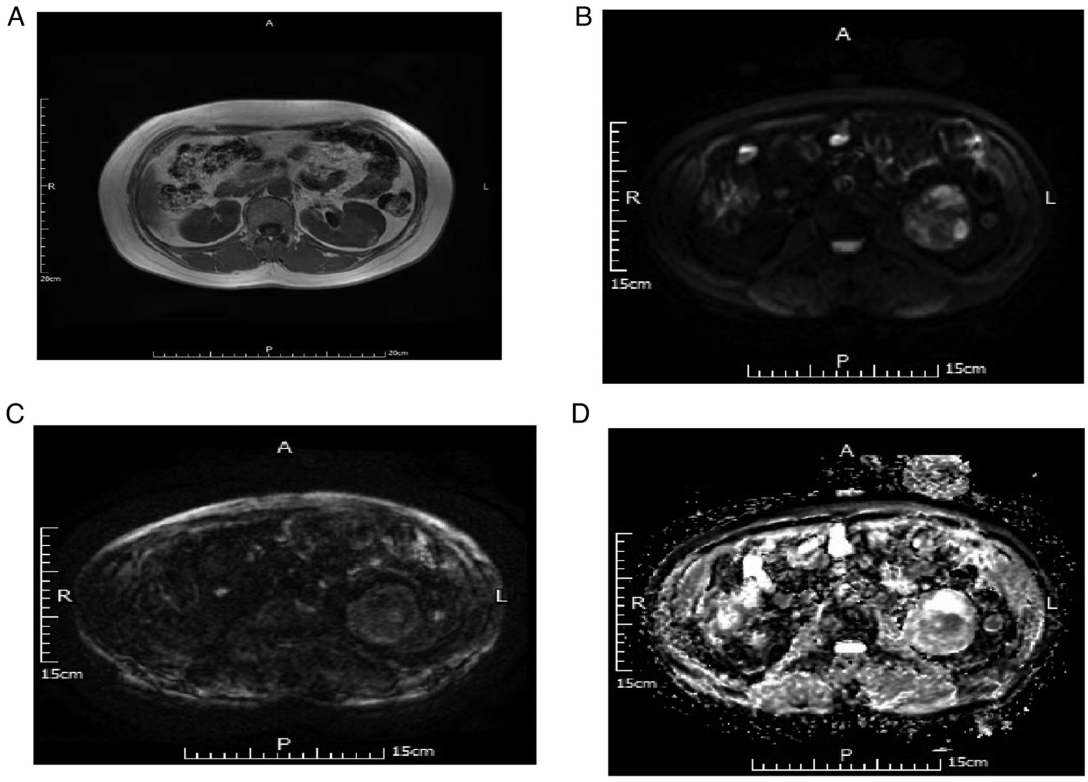

Figure 4. MRI scans of a 62-year-old male with pathologically confirmed renal clear cell carcinoma of the left kidney. (A) T1WI, left renal tumor with low signal. (B) DWI B=50, left renal tumor with high and low confounding signal. (C) DWI B=800, left renal tumor with low confounding signal. (D) Apparent diffusion coefficient with slightly high signal. DWI, diffusion-weighted imaging.

For papillary cell carcinoma, 72.73% of cases analyzed using DWI B-value=50 s/mm^2 were slightly high signal, 81.82% using DWI B-value=800 s/mm^2 were significantly high signal and 72.73% using ADC were obviously low signal. Therefore, the high B-value signal of papillary cell carcinoma DWI was higher than that of the low B-value signal and most ADCs measured were significantly low signal. In the present study, it was difficult to distinguish chromophobe from papillary cell carcinoma.

For ccRCC, 76.47% of cases analyzed using DWI B-value=50 s/mm^2 were judged as slightly higher signal, 48.53% using DWI B-value=800 s/mm^2, were low signal and 79.41% using ADC were equal or slightly high signal. Therefore, the high B-value signal in DWI of ccRCC was lower than that of the low B-value signal, while the majority of ADC signal was equal or slightly high signal; this is the opposite to results for non-ccRCC and may be because ccRCC is prone to sac necrosis, sac necrosis can lead to DWI signal decreased and ADC signal increased (10). In the present study, only one case with small kidney cancer of the tumor diameter <1 cm did not have cystic degeneration. Therefore cystic degeneration is a characteristic of ccRCC, which is similar to the results reported in the existing literature (14). T2WI signals of ccRCC are mostly mixed and the DWI and ADC signals of individual cases are higher due to the T2 penetration effect (8).

In the present study, the median average ADC value of ccRCC was 2.84±1.35x10^{-3} mm^2/s, of non-ccRCC papillary cell carcinoma was 1.42±0.78x10^{-3} mm^2/s and that of chromophobe cell carcinoma was 1.34±0.52x10^{-3} mm^2/s. The median average ADC value of ccRCC was significantly higher than that of non-ccRCC. By contrast, Chen *et al* (16) reported that the median average ADC value of ccRCC was 1.67x10^{-3} mm^2/s and that of non-ccRCC was 3.67x10^{-3} mm^2/s. According to a previous study, signals with ccRCC on T2WI are mostly mixed signals and ADC signals are mostly slightly low signals (16,17), which is inconsistent with the present study. The selected cases in this study had a long the course of illness and large tumor growth, large tumors are prone to cystic change, which leads to signal reduction). However, other studies have reported that ccRCC is prone to cystic degeneration, necrosis and hemorrhage, which is consistent with the results in the present study (16,17).

In conclusion, in the present study, DWI and ADC measurements were different between ccRCC and non-ccRCC groups. DWI of ccRCC was mostly low, equal or slightly high signal and ADC was mostly equal or slightly high signal. In addition, high B-value DWI signal was lower than low B-value DWI. DWI of non-ccRCC was mostly obvious high signal and ADC was mostly uniform, obviously low signal. In addition, high B-value DWI signal was significantly higher than low B-value DWI. Therefore, DWI and ADC had notable differential diagnostic value for ccRCC and non-ccRCC.

Acknowledgements

Not applicable.

Funding

The present study was supported by the Health Industry Plan Project of Gansu Province (grant no. GSWSKY2020-09) and the Science and Technology Project of Chengguan District, Lanzhou (grant no. 2020SHFZ0007).

Availability of data and materials

The datasets used and/or analyzed during the current study are available from the corresponding author on reasonable request.

Authors' contributions

XL designed the study and collected patient data. XL and HL confirm the authenticity of all the raw data. XX and HL performed the statistical data analysis. All authors have read and approved the final manuscript.

Ethics approval and consent to participate

All participants provided written informed consent. The methods of the study met the criteria of the Declaration of Helsinki for human rights and the study was approved by the Affiliated Hospital of Gansu University of Chinese Medicine Ethics Committee [Lanzhou, China; approval no. (2018)25].

Patient consent for publication

Not applicable.

Competing interests

The authors declare that they have no competing interests.

References

1. Wang H, Cheng L, Zhang X, Wang D, Guo A, Gao Y and Ye H: Renal cell carcinoma: Diffusion-weighted MR imaging for subtype differentiation at 3.0 T. Radiology 257: 135-143, 2010.
2. Chowdhury S and Choueiri TK: Recent advances in the systemic treatment of metastatic papillary renal cancer. Expert Rev Anticancer Ther 9: 373-379, 2019.
3. Erbay G, Koc Z, Karadeli E, Kuzgunbay B, Goren MR and Bal N: Evaluation of malignant and benign renal lesions using diffusion-weighted MRI with multiple b values. Acta Radiol 3: 359-365, 2012.
4. Dale BM, Braithwaite AC, Boll DT and Merkle EM: Field strength and diffusion encoding technique affect the apparent diffusion coefficient measurements in diffusion-weighted imaging of the abdomen. Invest Radiol 45: 104-108, 2010.
5. Srinivasan A, Dvorak R, Perni K, Rohrer S and Mukherji SK: Differentiation of benign and malignant pathology in the head and neck using 3T apparent diffusion coefficient values: Early experience. AJNR Am J Neuroradiol 29: 40-44, 2008.
6. Manenti G, Di Roma M, Mancino S, Bartolucci DA, Palmieri G, Mastrangeli R, Miano R, Squillaci E and Simonetti G: Malignant renal neoplasms: Correlation between ADC values and cellularity in diffusion weighted magnetic resonance imaging at 3 T. Radiol Med 113: 199-213, 2008 (In English, Italian).
7. Chen J, Sun J, Xing W, Ding J, Chen T, Dai Y, Sun J and Hu J: Prediction of nuclear grade of clear cell renal cell carcinoma with MRI: Intratumoral susceptibility signal intensity versus necrosis. Acta Radiol 55: 378-384, 2014.
8. Hartman DS, Davis CJ Jr, Johns T and Goldman SM: Cystic renal cell carcinoma. Urology 28: 145-153, 1986.
9. Parienty RA, Pradel J and Parienty I: Cystic renal cancers: CT characteristics. Radiology 157: 741-744, 1985.
10. Özgök Y, Ateş M, Hoşcan MB, İstanbulluoğlu O, Başal Ş and Zor M: Renal cell carcinoma dwelling upon a renal cyst wall and laparoscopic management. Urol J 10: 1165-1167, 2014.

11. Bielsa O, Lloreta J and Gelabert-Mas A: Cystic renal cell carcinoma: Pathological features, survival and implications for treatment. Br J Urol 82: 16-20, 1998.
12. Huan L: Comparison of CT and MRI in the diagnosis of renal cell carcinoma of different pathological subtypes. Contemp Med 19: 139-140, 2021.
13. Robbin ML, Lockhart ME and Barr RG: Renal imaging with ultrasound contrast: Current status. Radiol Clin North Am 41: 963-978, 2003.
14. Israel GM, Hindman N and Bosniak MA: Evaluation of cystic renal masses: Comparison of CT and MR imaging by using the Bosniak classification system. Radiology 231: 365-371, 2004.
15. Park BK, Kim B, Kim SH, Ko K, Lee HM and Choi HY: Assessment of cystic renal masses based on Bosniak classification: Comparison of CT and contrast-enhanced US. Eur J Radiol 61: 310-314, 2007.
16. Chen Y, Wu N, Xue T, Hao Y and Dai J: Comparison of contrast-enhanced sonography with MRI in the diagnosis of complex cystic renal masses. J Clin Ultrasound 43: 203-209, 2015.
17. Mühlfeld AS, Lange C, Kroll G, Floege J, Krombach GA, Kuhl C, Eitner F and Schrading S: Pilot study of non-contrast-enhanced MRI vs ultrasound in renal transplant recipients with acquired cystic kidney disease: A prospective intra-individual comparison. Clin Transplant 27: 694-701, 2013.