SPANDIDOS PUBLICATIONS

ONCOLOGY LETTERS 25: 162, 2023

Spindle cell carcinoma with cystic brain metastasis: Successful treatment with stereotactic radiotherapy and anti-programmed cell death-1 antibodies: A case report

KENTA HAMABE[1], YOSHIAKI KUROSHIMA[2,3], HISASHI TAKAYA[4], SHOJIROH MORINAGA[5], SHINICHI OKUZUMI[1], TOMOO KAKIMOTO[1] and NAOTO MINEMATSU[1]

Departments of [1]Medicine and [2]Neurosurgery, Hino Municipal Hospital, Tokyo 191-0062; [3]Department of Neurosurgery, Hiratsuka City Hospital, Hiratsuka-shi, Kanagawa 254-0065; [4]Department of Respiratory Medicine, Toranomon Hospital Kajigaya, Kawasaki-shi, Kanagawa 213-8587; [5]Department of Diagnostic Pathology, Hino Municipal Hospital, Tokyo 191-0062, Japan

Received December 29, 2022; Accepted February 7, 2023

DOI: 10.3892/ol.2023.13748

Abstract. Cystic brain metastasis is a rare condition that mainly originates from lung or breast adenocarcinomas. By contrast, pulmonary spindle cell carcinoma, a rare type of non-small cell carcinoma, has not been reported with this condition. Cystic brain metastases are characterized by larger tumor sizes with increased peritumoral edema compared with solid metastases. Therefore, specific treatment strategies are required for intracranial disease control. Immunotherapy has recently been demonstrated to be crucial for treating pulmonary sarcomatoid carcinomas based on high programmed cell death-ligand 1 (PD-L1) expression observed in these cancers. The present report describes the case of an 82-year-old man diagnosed with pulmonary spindle cell carcinoma, a rare subtype of sarcomatoid carcinoma. At 7 months after the diagnosis, the patient complained of a walking disturbance for which *de novo* brain metastasis with peritumoral edema was the causative agent. The brain tumor had a large cystic component, and thus, an Ommaya reservoir catheter was implanted for cyst aspiration but collapsed early without sufficient volume reduction. The patient was transferred to receive twice-split gamma knife treatment, which shrank the solid compartment and reduced the cyst volume, thereby relieving neurological defects. The patient was subsequently treated with immunotherapy targeting programmed cell death-1 based on the high PD-L1 expression in the lung tumor specimen. The thoracic tumors regressed following immunotherapy and progression-free survival was maintained for 16 months. To the best of our knowledge, the present report provides the first description of focal and systemic therapies for pulmonary spindle cell carcinoma with cystic brain metastasis. The report also discusses the treatment strategies for cystic brain metastases and reviews cases of pulmonary spindle cell carcinoma treated with immune checkpoint inhibitors.

Correspondence to: Dr Naoto Minematsu, Department of Medicine, Hino Municipal Hospital, 4-3-1 Tamadaira, Hino-shi, Tokyo 191-0062, Japan
E-mail: n.minematsu@hinohosp.jp

Abbreviations: BM, brain metastasis; GK, gamma knife; PD-1, programmed cell death-1; PD-L1, programmed cell death ligand-1; SpCC, spindle cell carcinoma; SRS, stereotactic radiosurgery; TPS, tissue proportion score

Key words: cystic brain metastasis, GK, immune checkpoint inhibitors, lung cancer, SpCC, sarcomatoid carcinoma, SRS

Introduction

Cystic brain metastases (BMs) are rare in lung carcinoma cases. Adenocarcinoma is the leading pathological type that results in cystic BMs, followed by squamous cell carcinoma (1). However, pulmonary sarcomatoid carcinoma or its rare subtype of spindle cell carcinoma has not been previously reported with cystic BMs. Sarcomatoid carcinomas occupied approximately 0.2-0.3% of all lung carcinomas, while spindle cell carcinomas (SpCCs) are rarer, accounting for 13.3% of pulmonary sarcomatoid carcinomas (2,3). According to the World Health Organization, pulmonary SpCCs are resected samples consisting solely of spindle cells, whereas biopsy samples with similar pathological findings are referred to as non-small cell carcinoma with SpCC (2). However, biopsy-proven SpCCs, consisting solely of spindle cells, have been widely discussed in the literature since 70% of patients with lung cancer present at advanced and unresectable stages (2). Clinical studies of biopsy-proven rare malignancies are particularly important for providing clinical information to guide treatment of patients with advanced disease stages.

Cystic BMs are characterized by larger tumor sizes with increased peritumoral edema compared with solid BMs, resulting in poor prognosis (4,5). Therefore, specific treatment strategies are clinically examined including cyst aspiration and stereotactic radiotherapy for cystic BMs (6-8). Also, the crucial role of immunotherapy targeting programmed cell

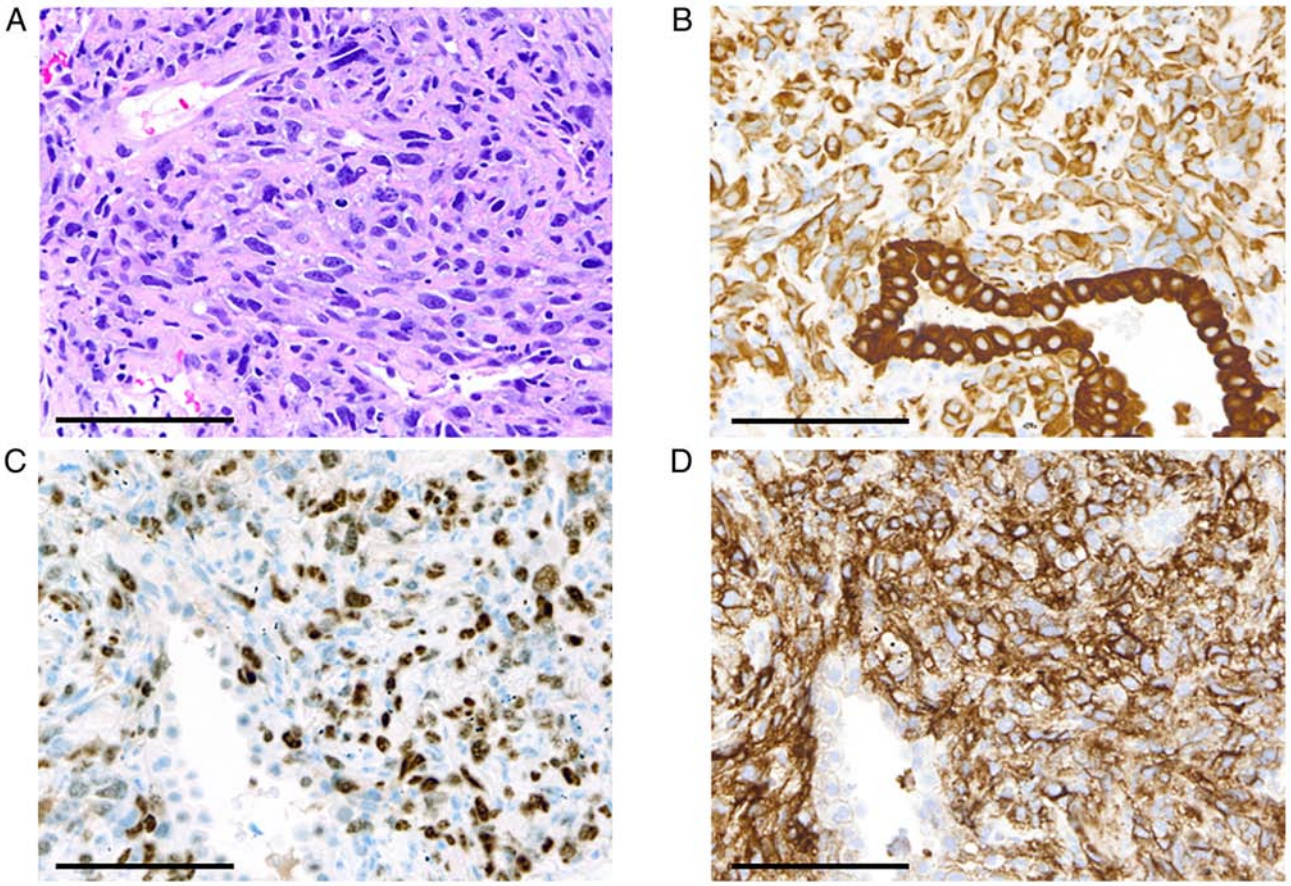

Figure 1. Pathological findings of the tumor specimen. (A) The tumor was composed of monotonous spindle-shaped cells (hematoxylin and eosin staining) that were positive for (B) AE1/AE3 and (C) p53. (D) Programmed cell death-1 ligand was expressed in 90% of tumor cells. Original magnification, x400. Scale bars, 100 μm.

death-1 (PD-1)/programmed cell death-ligand 1 (PD-L1) is recently highlighted in treating pulmonary sarcomatoid carcinomas based on high PD-L1 expression in these tumors (9).

Herein, we report a rare case of biopsy-proven pulmonary SpCC with solitary cystic BM. BM was initially managed with stereotactic irradiation, and subsequent immunotherapy targeting PD-1 conferred long-term disease control. The present report provides the first description of the successful management with focal and systemic therapies for pulmonary SpCC with cystic BM.

Case report

An 82-year-old male was diagnosed with pulmonary SpCC at the clinical stage of T3N2M0 in August of Year X-1 based on the pathological findings of a tumor specimen obtained by transcutaneous core needle biopsy. The biopsy sample was entirely composed of monotonous spindle-shaped tumor cells that were positive for AE1/AE, CK7, and p53 and negative for CK5/6, p40, TTF-1, or Napsin A by immunostaining, which was indicative of SpCC (Fig. 1A-C). The programmed cell death ligand-1 (PD-L1) expression in tumor cells was evaluated by immunostaining using 22C3 PharmDx Dako (Agilent, Santa Clara, CA, United States) (Fig. 1D). The tissue proportion score (TPS) was calculated by dividing the total tumor cells into PD-L1-positive tumor cells and expressed as a percentage, which was high at 90% in the present case. In contrast, oncogene addiction was negative. Owing to the age of the asymptomatic patient, the patient was receiving supportive care at Toranomon Hospital Kajigaya.

In March of Year X, the patient was admitted to Hino Municipal Hospital complaining of a walking disturbance. The patient was conscious, and his vital signs were intact. Neurological examination revealed unilateral spatial neglect and mild hemiparesis of the left extremities. Chest radiography and computed tomography revealed a primary lung tumor (maximum diameter, 60 mm) invading the chest wall in the left upper lobe and subaortic lymphadenopathy (Fig. 2A-C) without any other metastatic sites. Gadolinium-enhanced magnetic resonance imaging showed a solitary brain tumor in the right parietal lobe (maximum diameter, 40 mm) consisting of solid and cystic components (estimated cyst volume, 37.5 ml) (Fig. 3, reference group). A retrospective review of imaging examinations revealed that the lung tumor was 20 mm in diameter, and brain metastasis was absent 1 year ago. Cyst aspiration of the BM followed by surgical resection or stereotactic irradiation was recommended for the rapid control of neurological symptoms. The patient underwent placement of an Ommaya reservoir catheter, and 7 ml of bloody-yellowish aspirate was collected, in which cohesive pleomorphic malignant cells were detected. Unfortunately, the catheter collapsed early, resulting in insufficient tumor shrinkage. While catheter replacement or surgical resection of the BM were treatment options, split gamma knife (GK) was performed to minimize the patient's

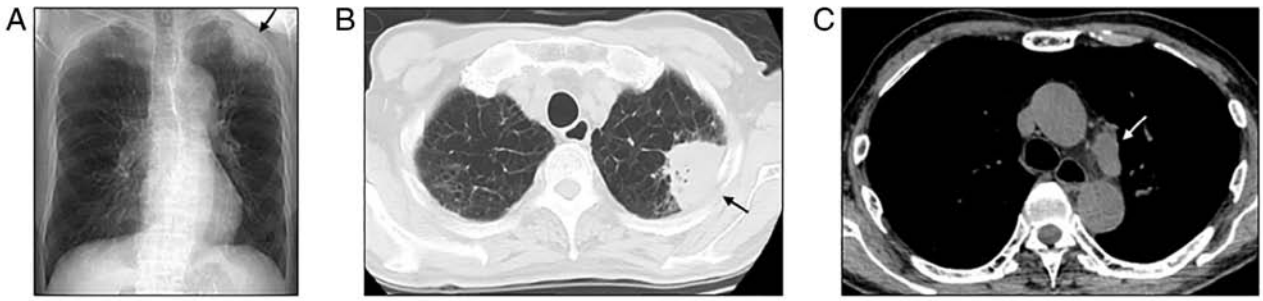

Figure 2. Radiological images in March of Year X. (A) Chest radiograph showing a tumor in the left upper field (arrow). Chest computed tomography showing (B) a primary lung tumor located in the left upper lobe (arrow) with (C) subaortic mediastinal lymph node metastasis (arrow).

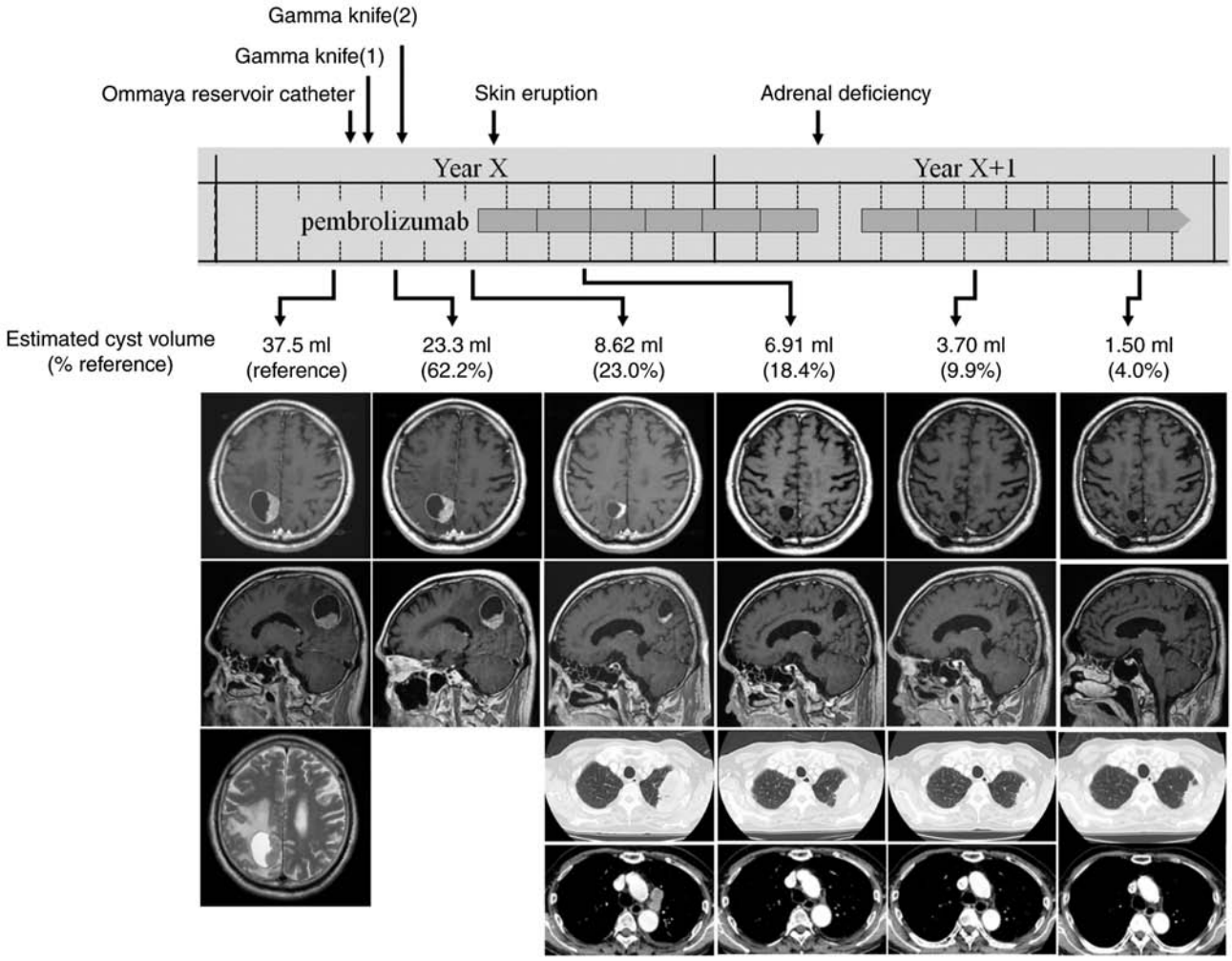

Figure 3. A schematic presentation of the clinical course. The treatment and clinical events are shown at the top. T1 images of gadolinium-enhanced MRI of the brain are chronologically displayed in the middle. A T2 image of brain MRI (reference group) and contrast medium-enhanced computed tomography images of the chest (other groups) are shown at the bottom. Estimated cyst volumes and a solid portion of brain metastasis were reduced with the gamma knife treatment. The primary lung tumor and brain metastasis regressed following subsequent immunotherapy using pembrolizumab. MRI, magnetic resonance imaging.

therapeutic burden and allow an earlier initiation of immunotherapy. A twice-split GK was performed with a prescription dose to tumor margin of 14 Gy each, resulting in a shrinkage of the solid portion and reduction in cyst volume by 62.2 and 23.0% following the first and second rounds of GK, respectively (Fig. 3). During the period of GK treatment, the patient's neurological symptoms improved to the point where he was able to walk independently and was discharged from the hospital. In July of Year X, the patient started anti-PD-1 immunotherapy (pembrolizumab, 400 mg intravenous administration, every 6 weeks). After two cycles of treatment, substantial regression was observed in the primary tumor and a mediastinal lymph node, thereby indicating a partial response (Fig. 3). In addition, the solitary compartment of the brain metastasis disappeared, and the cyst volume further decreased by 18.4% during this period. Skin eruption and adrenal deficiency appeared after

Table I. Pulmonary spindle cell carcinoma cases treated with immune checkpoint inhibitors.

First author/s, year	Age, years	Sex	Samples	PD-L1, %	Stages	BMs	Regimen	Treatment lines	Maximum response	Outcomes	(Refs.)
Mizushina *et al*, 2021	52	M	Surgical specimen	>95	Post-operation recurrence	+	Pemb (q3w)	2nd	PR	11 cycles, dead	(23)
Oshiro *et al*, 2021	70	M	Surgical specimen	100	Post-operation recurrence	-	Pemb (q3w)	1st	PR	23 cycles, alive	(24)
Akaba *et al*, 2021	72	F	Surgical specimen	100	Post-operation recurrence	-	CBDCA/PTX/Bev/Atezo (induction therapy); Bev/Atezo (maintenance therapy)	1st	PR	4 cycles; 15 months, alive	(25)
Oshiro *et al*, 2021	75	F	Surgical specimen	90	Stage IVB	-	Pemb (q3w)	1st	CR	29 cycles, alive	(24)
Awobajo *et al*, 2020	69	F	Biopsy	90	Post-radiotherapy recurrence	+	Pemb (q3w)	1st	PR	2 cycles, alive	(26)
Tsurumi *et al*, 2020	76	M	Biopsy	>90	Stage IVB	-	Pemb (q3w)	1st	PR	7 cycles, alive	(27)
Present study	82	M	Biopsy	90	Stage IVB	+	Pemb (q6w)	1st	PR	12 cycles, alive	-

Atezo, atezolizumab; Bev, bevacizumab; BMs, brain metastases; CBDCA, carboplatin; CR, complete response; F, female; M, male; PD-L1, programmed cell death-ligand 1; Pemb, pembrolizumab; PR, partial response; PTX, paclitaxel; q3w, every 3 weeks; q6w, every 6 weeks.

the first and sixth cycles of pembrolizumab treatment, respectively, and were treated appropriately. The patient is currently continuing pembrolizumab for 12 cycles and has maintained progression-free survival. The patient did not complain of any neurological or physical symptoms.

Discussion

The present report provides clinical observations of biopsy-proven SpCC with cystic BM. Cystic BMs are rare and account for 1.7-18.8% of all metastatic brain tumors (4-6,10-12). The lungs and breasts were the two leading primary cancer sites that resulted in cystic BMs, and non-small cell lung carcinomas were less frequently accompanied by cystic BMs (7/1099 patients, 0.6%) than breast cancers (11/317 patients, 3.5%) (6,10-12). Xu *et al* (1) evaluated the histopathological types of 33 cases of lung cancer with cystic BMs, including 26 adenocarcinomas (78.8%) and seven squamous cell carcinomas (21.2%). Few studies have reported small cell lung carcinomas with cystic BMs (13,14). Cystic BM has not been reported with any subtype of pulmonary sarcomatoid carcinoma including SpCC. The mechanisms underlying cyst formation in non-mucinous carcinomas are not fully understood; however, literature suggests that exudate collection results from the breakdown of blood-brain barriers by tumor invasion (15).

BMs are frequently associated with neurological symptoms and poor prognosis without appropriate treatment (16). Poor prognosis has been reported in patients with lung carcinomas (5) and breast cancers (4) with cystic BMs compared to those with solid BMs. Other studies have reported comparable overall survivals of patients with either type of BM following stereotactic radiosurgery (SRS); however, these studies also reported a lower local control rate, slower tumor shrinkage, and higher recurrence rate in cystic BMs (11,12,15). Predictive factors associated with SRS failure include large tumor size, non-lung primary tumor, prior history of whole brain irradiation, and the presence of cystic components (11,15,17). Therefore, prior cyst aspiration was clinically examined to minimize the target volumes and eventually showed time-efficient tumor shrinkage, minimized peritumoral edema, and rapid symptom relief following SRS treatment (6-8). In the present case, the patient had a symptomatic BM with a large cyst volume (37.5 ml), indicative that cyst aspiration was required; however, the Ommaya reservoir catheter collapsed early, resulting in insufficient tumor shrinkage. The catheter was not replaced because the direction of the tube route is one of the relevant factors for successful drainage (18), suggesting that simple replacement would not be sufficient. Alternatively, the patient was dispositioned to receive twice-split GK treatment based on previous reports showing favorable outcomes and safe management by hypo-fractionated SRS for large BMs (19,20). The present case showed effective and safe management of a large cystic BM of pulmonary SpCC using split GK.

Although pulmonary SpCCs are treated using the guidelines for non-small cell lung carcinomas, SpCCs are usually chemoresistant, leading to poor prognosis. In contrast, the use of immunotherapy targeting PD-1/PD-L1 has emerged with recent studies showing high PD-L1 expression and tumor mutation burden in pulmonary sarcomatoid carcinomas (9). Two studies estimated an objective response rate of 26.1-64.8%, disease control rate of 64.8-69.6%, and overall survival of 12.7-18.2 months in patients with sarcomatoid carcinoma following immunotherapy (21,22). Notably, immunotherapy was the only treatment that prolonged the overall survival of patients with pulmonary sarcomatoid carcinomas, whereas platinum-based chemotherapy or molecular targeted therapy for oncogene addiction did not (22). Furthermore, an additive platinum doublet in immunotherapy did not improve the overall survival (22). Six reported cases of pulmonary SpCC have been treated with immune checkpoint inhibitors (Table I) (23-27). Of these cases and the present case, four were diagnosed using surgical specimens and three were diagnosed using biopsy-proven SpCCs. Tumor PD-L1 expression was high (TPS >90%) in all the cases. All cases except one used monotherapy with pembrolizumab in the first (n=5) or second (n=1) treatment line. Notably, all cases showed partial or complete responses for the maximum response, and four cases, including the present case, maintained progression-free survival for more than one year at the reported date. While the therapeutic perspective for pulmonary SpCC is still in debate, immunotherapy is expected to provide a good prognosis for SpCC as other types of sarcomatoid carcinomas.

In summary, we concluded that the large cystic BM of SpCC was radiosensitive and successfully managed using split GK. The present case and current literature indicated the crucial role of immunotherapy targeting PD-1/PD-L1 in treating pulmonary SpCC.

Acknowledgements

Not applicable.

Funding

No funding was received.

Availability of data and materials

The datasets used and/or analyzed during the current study are available from the corresponding author on reasonable request.

Authors' contributions

KH, YK, HT and NM substantially conceived and designed the study. YK, HT, SM, SO and TK acquired, analyzed and interpreted the data. SM reviewed the pathological specimens. KH, SM and NM drafted the manuscript. SM, SO and TK created the figures. YK, HT, SO and TK critically revised the manuscript for important intellectual content. KH and NM confirm the authenticity of all the raw data. All authors have read and approved the final manuscript.

Ethics approval and consent to participate

Not applicable.

Patient consent for publication

Written informed consent was obtained from the patient for his information to be published in this case report.

Competing interests

The authors declare that they have no competing interests.

References

1. Xu YB, Zhang Y, Song Z, Wang W and Shao L: Treatment and prognosis of solid and cystic brain metastases in patients with non-small-cell lung cancer. Cancer Manag Res 13: 6309-6317, 2021.
2. World Health Organization (WHO). WHO Classification of Tumours. In: Thoracic Tumours. 5th Edition. International Agency for Research on Cancer, Lyon, 2021.
3. Rossi G, Cavazza A, Sturm N, Migaldi M, Facciolongo N, Longo L, Maiorana A and Brambilla E: Pulmonary carcinomas with pleomorphic, sarcomatoid, or sarcomatous elements: A clinicopathologic and immunohistochemical study of 75 cases. Am J Surg Pathol 27: 311-324, 2003.
4. Brigell RH, Cagney DN, Martin AM, Besse LA, Catalano PJ, Lee EQ, Wen PY, Brown PD, Phillips JG, Pashtan IM, *et al*: Local control after brain-directed radiation in patients with cystic versus solid brain metastases. J Neurooncol 142: 355-363, 2019.
5. Sun B, Huang Z, Wu S, Ding L, Shen G, Cha L, Wang J and Song S: Cystic brain metastasis is associated with poor prognosis in patients with advanced breast cancer. Oncotarget 7: 74006-74014, 2016.
6. Franzin A, Vimercati A, Picozzi P, Serra C, Snider S, Gioia L, Ferrari da Passano C, Bolognesi A and Giovanelli M: Stereotactic drainage and Gamma Knife radiosurgery of cystic brain metastasis. J Neurosurg 109: 259-267, 2008.
7. Ebinu JO, Lwu S, Monsalves E, Arayee M, Chung C, Laperriere NJ, Kulkarni AV, Goetz P and Zadeh G: Gamma knife radiosurgery for the treatment of cystic cerebral metastases. Int J Radiat Oncol Biol Phys 85: 667-671, 2013.
8. Horiguchi T, Yanagi S, Yatsushiro K, Tsubouchi H, Matsumoto N and Nakazato M: A case of impaired consciousness due to large cystic metastatic brain tumors from lung adenocarcinoma successfully controlled with Ommaya reservoir placement. Respir Med Case Rep 30: 101069, 2020.
9. Ağaçkıran Y, Aksu F, Akyürek N, Ercan C, Demiröz M and Aksu K: Programmed death ligand-1 expression levels, clinicopathologic features, and survival in surgically resected sarcomatoid lung carcinoma. Asia Pac J Clin Oncol 17: 280-288, 2021.
10. Higuchi F, Kawamoto S, Abe Y, Kim P and Ueki K: Effectiveness of a 1-day aspiration plus Gamma Knife surgery procedure for metastatic brain tumor with a cystic component. J Neurosurg 117 (suppl): S17-S22, 2012.
11. Yamanaka Y, Shuto T, Kato Y, Okada T, Inomori S, Fujino H and Nagano H: Ommaya reservoir placement followed by Gamma Knife surgery for large cystic metastatic brain tumors. J Neurosurg 105 (suppl): S79-S81, 2006.
12. Wang H, Liu X, Jiang X, Song Y, Wang X, Wang J, Dong Y, Li F, Wu Z, Zhang Y and Yuan Z: Cystic brain metastases had slower speed of tumor shrinkage but similar prognosis compared with solid tumors that underwent radiosurgery treatment. Cancer Manag Res 11: 1753-1763, 2019.
13. Ismailoglu O, Albayrak BS and Ciris M: Cerebral metastasis of small-cell lung carcinoma mimicking a supratentorial cystic astrocytoma. Am J Med Sci 342: 520, 2011.
14. Takeda T, Saitoh M and Takeda S: Solitary cystic brain metastasis of small-cell lung carcinoma controlled by a stereotactically inserted Ommaya reservoir. Am J Med Sci 337: 215-217, 2009.
15. Gardner WJ, Collis JS Jr and Lewis LA: Cystic brain tumors and the blood-brain barrier. Comparison of protein fractions in cyst fluids and sera. Arch Neurol 8: 291-298, 1963.
16. Owonikoko TK, Arbiser J, Zelnak A, Shu HK, Shim H, Robin AM, Kalkanis SN, Whitsett TG, Salhia B, Tran NL, *et al*: Current approaches to the treatment of metastatic brain tumours. Nat Rev Clin Oncol 11: 203-222, 2014.
17. Pan HC, Sheehan J, Stroila M, Steiner M and Steiner L: Gamma knife surgery for brain metastases from lung cancer. J Neurosurg 102 (suppl): S128-S133, 2005.
18. Oshima A, Kimura T, Akabane A and Kawai K: Optimal implantation of Ommaya reservoirs for cystic metastatic brain tumors preceding gamma knife radiosurgery. J Clin Neurosci 39: 199-202, 2017.
19. Minniti G, D'Angelillo RM, Scaringi C, Trodella LE, Clarke E, Matteucci P, Osti MF, Ramella S, Enrici RM and Trodella L: Fractionated stereotactic radiosurgery for patients with brain metastases. J Neurooncol 117: 295-301, 2014.
20. Feuvret L, Vinchon S, Martin V, Lamproglou I, Halley A, Calugaru V, Chea M, Valéry CA, Simon JM and Mazeron JJ: Stereotactic radiotherapy for large solitary brain metastases. Cancer Radiother 18: 97-106, 2014.
21. Domblides C, Leroy K, Monnet I, Mazières J, Barlesi F, Gounant V, Baldacci S, Mennecier B, Toffart AC, Audigier-Valette C, *et al*: Efficacy of immune checkpoint inhibitors in lung sarcomatoid carcinoma. J Thorac Oncol 15: 860-866, 2020.
22. Chang CL, Hsieh MS, Shih JY, Lee YH, Liao WY, Hsu CL, Yang CY, Chen KY, Lee JH, Ho CC, *et al*: Real-world treatment patterns and outcomes among patients with advanced non-small-cell lung cancer with spindle cell and/or giant cell carcinoma. Ther Adv Med Oncol 14: 17588359221133889, 2022.
23. Mizushina Y, Ohyanagi F, Shiihara J, Nomura M, Ohta H, Oshiro H, Tsubochi H, Kusaka G and Yamaguchi Y: Clinical case of lung spindle cell carcinoma markedly responsive to pembrolizumab. Thorac Cancer 12: 2279-2282, 2021.
24. Oshiro Y, Suzuki S, Sakurada A, Hamada K, Yamamoto R and Kazama A: A long-term survival in two cases of pulmonary spindle cell carcinoma treated with pembrolizumab. Jpn J Lung Cancer 16: 327-335, 2021 (In Japanese).
25. Akaba T, Shiota Y, Onizawa F, Isaka T, Nagashima Y and Tagaya E: Recurrent spindle cell carcinoma of the lung successfully treated by chemoimmunotherapy. Respirol Case Rep 9: e00757, 2021.
26. Awobajo MD, Vaporciyan AA, Lu C and Gandhi SJ: Stereotactic body radiation therapy (SBRT) in the management of pulmonary spindle cell carcinoma. BMJ Case Rep 13: e234779, 2020.
27. Tsurumi K, Kawashima Y, Akahira J, Saito R, Toi Y, Nakamura A, Yamanda S, Kimura Y, Honda Y and Sugawara S: A remarkable clinical response to pembrolizumab in a rare spindle cell carcinoma of the lung. JMA J 3: 83-86, 2020.