Breast cancer metastases to the thyroid and stomach: A case report

XUE BAI[1*], CANBIN FANG[2*], BINLIANG LIU[3], JIAYI HUAGN[1], XUELIAN CHEN[1], XIAOFENG XIE[1], QIUYI ZHANG[1], MEIDI LIU[1], JINYAN LIANG[1], JINFENG GUO[1], LIN SONG[1], XIAOFENG LAN[1], LIPING CHEN[1], SUNI HUANG[1], WENCUI DENG[1], ZHENZHEN LUO[1] and CAIWEN DU[1]

[1]Department of Medical Oncology, National Cancer Center/National Clinical Research Center for Cancer/Cancer Hospital & Shenzhen Hospital, Chinese Academy of Medical Sciences and Peking Union Medical College, Shenzhen, Guangdong 518116; [2]Cancer Center and Department of Breast and Thyroid Surgery, Xiang'an Hospital of Xiamen University, Xiamen, Fujian 361100; [3]Department of Breast Cancer Medical Oncology, Hunan Cancer Hospital/The Affiliated Cancer Hospital of Xiangya School of Medicine, Central South University, Changsha, Hunan 410013, P.R. China

Received January 30, 2023; Accepted June 7, 2023

DOI: 10.3892/ol.2023.13972

Abstract. The most common sites of metastasis for breast cancer are the soft tissues, bones, lungs, liver and brain; however, metastases to the gastrointestinal tract and thyroid gland from breast cancer rarely occur. The present study describes the case of a 30-year-old woman who developed gastric and thyroid metastases 5 years after her initial diagnosis of invasive ductal breast carcinoma. The initial pathological diagnosis when receiving modified radical mastectomy was invasive ductal carcinoma, and further immunohistochemical examination revealed the cancer to be estrogen receptor (-), progesterone receptor (-), human epidermal growth factor receptor 2 (HER2; ++) and Ki-67 (70%). Genetic testing indicated the HER2 amplification mutation, whereas BRCA1/2 testing was negative. A total of 21 months after surgery, during regular follow-up, the patient was revealed to have developed an enlarged lymph node in the left side of the neck and the first recurrence was confirmed. Approximately 5 years after surgery, the patient gradually developed multi-site metastasis, and developed metastases to the thyroid gland and stomach confirmed by pathology and imaging. Combined chemotherapy and targeted therapy were administered and exhibited good efficacy; however, the patient subsequently died due to heart failure. This case report describes the occurrence of gastric and thyroid metastases from breast cancer, and highlights the importance of distinguishing between metastatic and primary tumors. Distinguishing between a metastatic and primary tumor is crucial as treatment protocols vary significantly for these two types of tumors. For patients with a history of breast cancer it should first be considered whether they have metastasis of the primary disease or discomfort caused by treatment; however, the possibility of a second primary tumor cannot be ignored. If the patient has symptoms such as loss of appetite, nausea, vomiting, stomach pain and stomach discomfort, a gastroscopy should be performed in a timely manner.

Correspondence to: Dr Caiwen Du, Department of Medical Oncology, National Cancer Center/National Clinical Research Center for Cancer/Cancer Hospital & Shenzhen Hospital, Chinese Academy of Medical Sciences and Peking Union Medical College, 113 Baohe Road, Shenzhen, Guangdong 518116, P.R. China
E-mail: dusumc@aliyun.com

[*]Contributed equally

Key words: breast cancer, thyroid metastasis, gastric metastasis, chemotherapy, targeted therapy

Introduction

Breast cancer refers to a heterogeneous collection of tumors characterized by distinct histological morphology, genomic profiles, molecular behavior and treatment responses. Invasive ductal carcinoma (IDC) is the most prevalent histological type, comprising 72-80% of all invasive breast cancer cases. By contrast, invasive lobular carcinoma (ILC) accounts for 5-15% of all invasive breast cancer cases and is less common worldwide (1). Bone, liver, lung and brain are the most frequent sites of breast cancer metastasis, whereas metastases to the gastrointestinal (GI) tract and thyroid gland are less common. GI metastasis, which accounts for 5% of all recurrent cases, is a rare occurrence (2). Furthermore, cases of GI metastasis from breast cancer have been estimated to range between 2 and 18% in some reports (3).

ILC is more likely to metastasize to the GI tract than IDC (3,4). In particular, luminal-type breast cancer [estrogen receptor (ER)-positive] or ILC tend to metastasize to the stomach at a higher rate than other types of breast cancer (5). Notably, in some studies, 97% of GI metastases from breast cancer were revealed to be derived from ILC (3,4). Typically, ductal tumors have a higher tendency to metastasize to the liver, lung and brain (6), with intestinal metastases occurring in some cases. The clinical presentation of gastric metastases is nonspecific, and the endoscopic appearance of gastric metastases varies, with solitary and submucosal lesions within the gastric wall constituting the most prevalent findings (7,8).

Typically, 5-7 years pass between the initial diagnosis of breast cancer and the development of stomach metastases (9).

The clinical presentation of metastases to the stomach or thyroid is highly unspecific, and the endoscopic appearance can be heterogeneous. In particular, the most prevalent findings of gastric metastases are solitary and submucosal lesions in the gastric wall, which can appear several years after the initial breast cancer diagnosis (7,8). Similarly, thyroid gland metastases are uncommon and can be easily missed; they account for 1.4-3% of all patients who have surgery for suspected thyroid cancer, with the most common primary cancer types being soft tissue sarcoma, renal cell, colorectal, lung and breast cancer (10). Metastatic thyroid disease commonly results from cancer spreading via the bloodstream, typically originating from a distant cancer or the neoplastic process applying directly or through lymphatic channels to the thyroid gland from nearby organs. Elderly patients, particularly those in their 60s and 70s, are more likely to develop metastatic thyroid tumors (8).

The present study describes a rare case of a young patient diagnosed with human epidermal growth factor receptor 2 (HER2)-positive IDC who eventually developed stomach and thyroid metastases following local and systemic treatment. This case highlights the atypical metastatic patterns of breast cancer and emphasizes the importance of considering distant metastases in patients with a history of breast cancer. The present study followed the CARE case report guidelines (11).

Case report

In November 2013, a 30-year-old woman was diagnosed with IDC of the right breast and underwent a modified radical mastectomy at Futian People's Hospital of Guangdong Medical College (Shenzhen, China). Pathological examination confirmed IDC with extensive high-grade ductal carcinoma *in situ*, non-special type, grade III, without lymphovascular invasion. Immunohistochemistry revealed ER (-), progesterone receptor (PR -) and HER2 (++), with a Ki-67 index of 70%. Pathological TNM staging was pT3N0M0 [T=12 cm; N (0/16)] (12). Medical imaging, including thoracic and abdominal computed tomography (CT) scans and bone scans, showed no distant metastasis. Fluorescence *in situ* hybridization for HER2 was not determined at the time. Post-operative treatment included six cycles (3 weeks per cycle) of adjuvant chemotherapy with 5-fluorouracil, epirubicin and cyclophosphamide.

After surgery, the patient was followed up every 3 months for 2 years and every 6 months for 3-5 years. Tumor markers, breast ultrasound, chest, abdominal and pelvic CT, and brain MRI examinations were performed regularly, and positron emission tomography (PET)/CT examinations were additionally performed when necessary. In August 2015, 21 months after the surgery, the patient developed an enlarged lymph node in the left side of their neck and underwent lymph node biopsy. The immunohistochemical staining revealed: ER (-), PR (-), HER2 (+++), Ki-67 (65%). Chest CT showed bilateral hilar lymph nodes, bilateral supraclavicular lymph nodes and axillary lymph nodes metastasis. The first-line regimen included paclitaxel liposome and Nedaplatin combined with trastuzumab for six cycles (3 weeks per cycle), and the best efficacy observed was complete response PET/CT examination was completed and no tumor signs were found. Trastuzumab maintenance therapy was then followed; however, in March 2016, metastases were detected in the chest wall and pleura, and a small amount of fluid had accumulated in the right thoracic cavity.

Tumor markers (blood tests for CEA, CA125 and CA153) were elevated and efficacy evaluation showed progressive disease. Progression-free survival (PFS) represents the survival time of patients without tumor progression; PFS1 represents PFS after first-line treatment and PFS2 represents PFS after second-line treatment. The PFS1 for the patient was 6.5 months. The second-line treatment regimen included gemcitabine combined with trastuzumab for six cycles (3 weeks per cycle), and the best efficacy observed was stable disease. Maintenance therapy with capecitabine and trastuzumab was then followed; however, the size of the tumor in the chest wall progressed in December 2016, and PFS2 was 8.3 months. In the third-line treatment regimen, etoposide capsules combined with trastuzumab and lapatinib were applied for 10 cycles (3 weeks per cycle), and trastuzumab and lapatinib maintenance therapy was continued. In August 2017, PET/CT showed metastatic tumors in the right chest wall, metastasis in the left breast and increased pleural effusion on the right side. Also in August 2017, the patient was first admitted to Department of Medical Oncology, National Cancer Center/National Clinical Research Center for Cancer/Cancer Hospital & Shenzhen Hospital, Chinese Academy of Medical Sciences and Peking Union Medical College (Shenzhen, China) due to tightness in their chest. Chest CT indicated left breast metastasis, metastasis in the right chest wall and right pleural effusion (Fig. 1). For fourth-line treatment, the patient received vinorelbine capsules combined with trastuzumab and lapatinib for five cycles (3 weeks per cycle). However, vinorelbine capsules and lapatinib were stopped for economic reasons, and trastuzumab therapy was continued. The patient gradually developed multi-site metastasis in November 2018, including pleural, chest wall, lung lymphangitis carcinomatosa, left breast, pancreas, adrenal and thyroid metastases (Fig. 1). In the present case, there were no standard treatment plans in the guidelines for patients with such a short PFS time and after multiline therapy.

To summarize, since the first recurrence and metastasis, the patient was treated with various chemotherapy drugs, including gemcitabine, capecitabine, vinorelbine, etoposide, Herceptin and lapatinib, over a period of 2 years and 6 months. Unfortunately, despite receiving multi-line chemotherapy and targeted Herceptin-based therapy, their condition continued to worsen. In December 2018, a mass developed in their left thyroid, and a thyroid gland ultrasound revealed diffuse lesions with dense microcalcification, raising concern for malignancy. Fine needle biopsy was recommended for further evaluation (Fig. 2A). A neck CT also showed enlargement of the thyroid gland and multiple low-density nodules in both lobes (Fig. 2B). In January 2019, a core needle biopsy on the thyroid was performed and cytological examination of the mass in the left thyroid implied poorly differentiated cancer cells, which were consistent with the history of breast cancer metastasis (Fig. 2C). The serum thyroglobulin antibody level was found to be 576.2 IU/ml.

Figure 1. CT images. Chest CT indicated left breast metastasis (indicated with red arrows), metastasis in the right chest wall (indicated with yellow arrows) and right pleural effusion (indicated with blue arrows). CT, computed tomography.

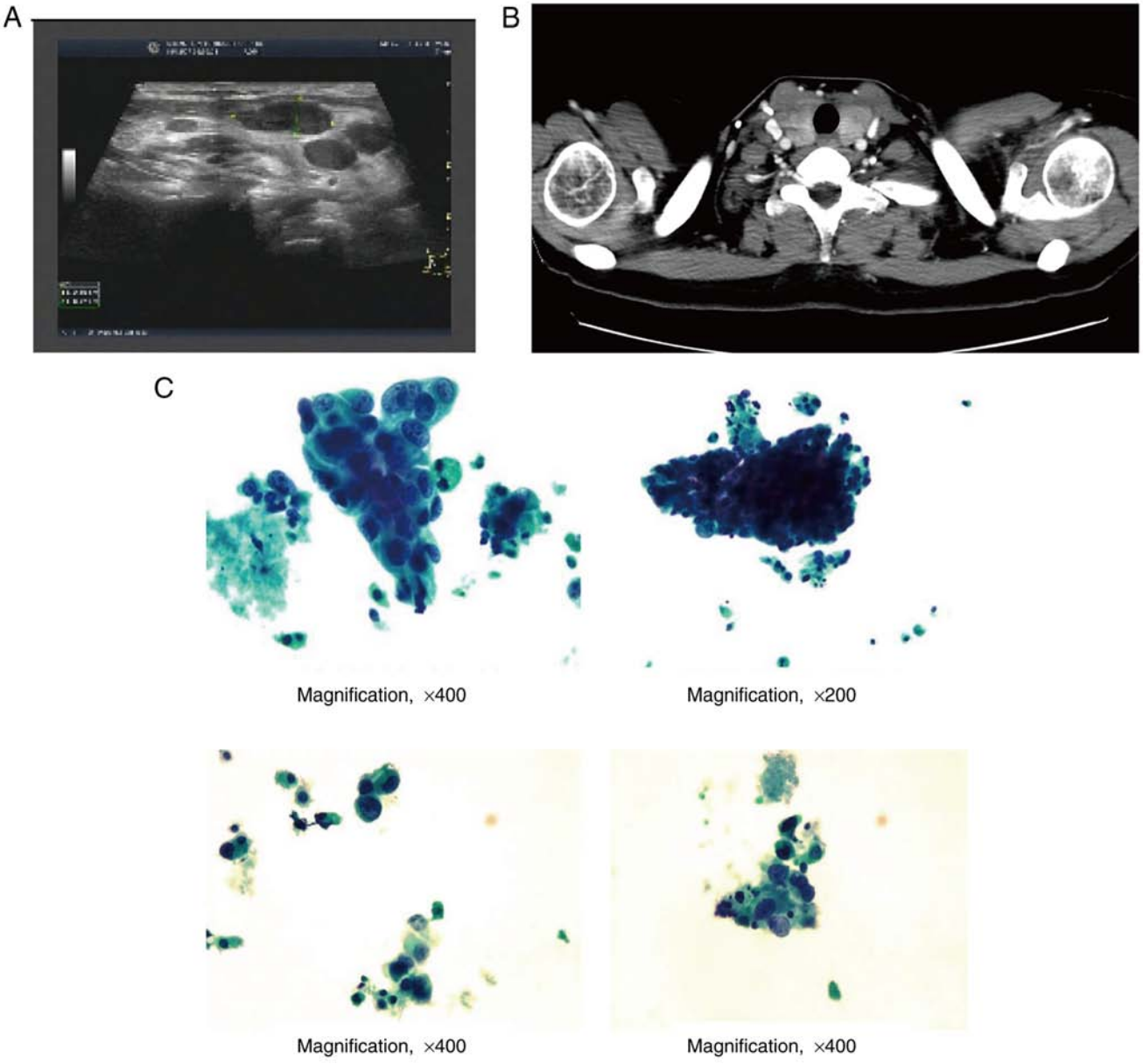

Figure 2. Thyroid ultrasound and neck computed tomography images, and cytological examination of the mass in the left thyroid. (A) Thyroid ultrasound images detected diffuse lesions, dense microcalcification. (B) CT imaging suggested that the thyroid gland was enlarged and multiple low-density nodules were seen in both lobes. (C) Cytological examination of the mass in the left thyroid implied poorly differentiated cancer cells, which were consistent with the history of breast cancer metastasis.

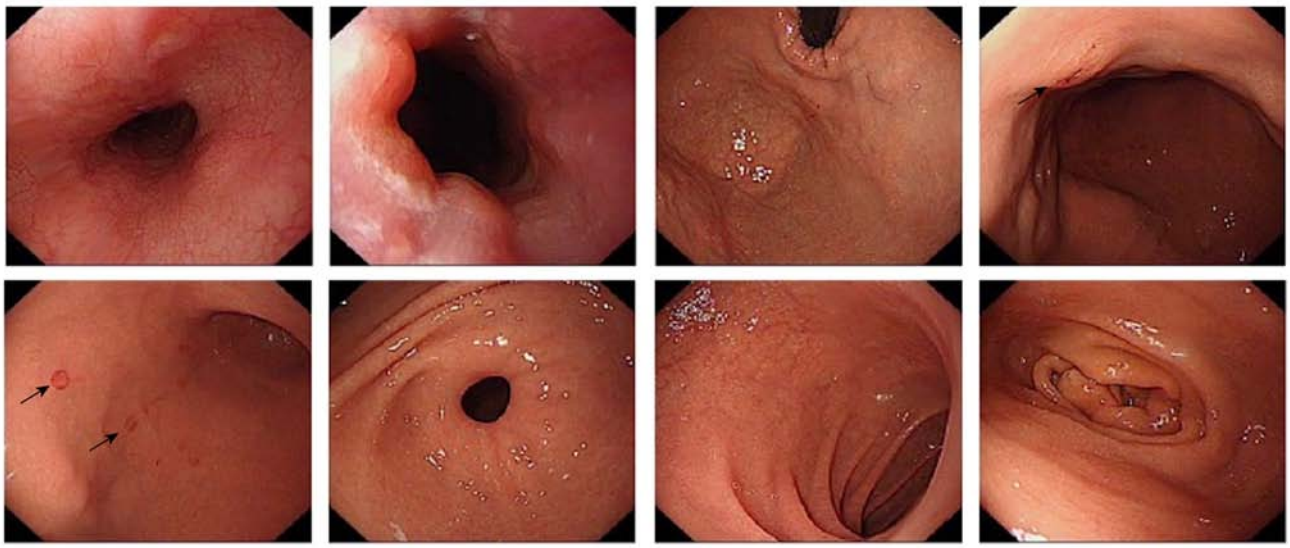

Figure 3. Gastroscopy images. There was no obvious abnormality in the esophagus, and the boundary between the esophagus and stomach was ~39 cm from the incisor. No obvious abnormality was observed at the cardia. Scattered erosion could be seen in the gastric body and fundus (indicated with black arrows). The gastric antrum mucosa was congested, edematous and rough, and the pylorus was congested and edematous. There was no obvious abnormality in the duodenum. Endoscopic diagnosis was of chronic gastritis with erosion.

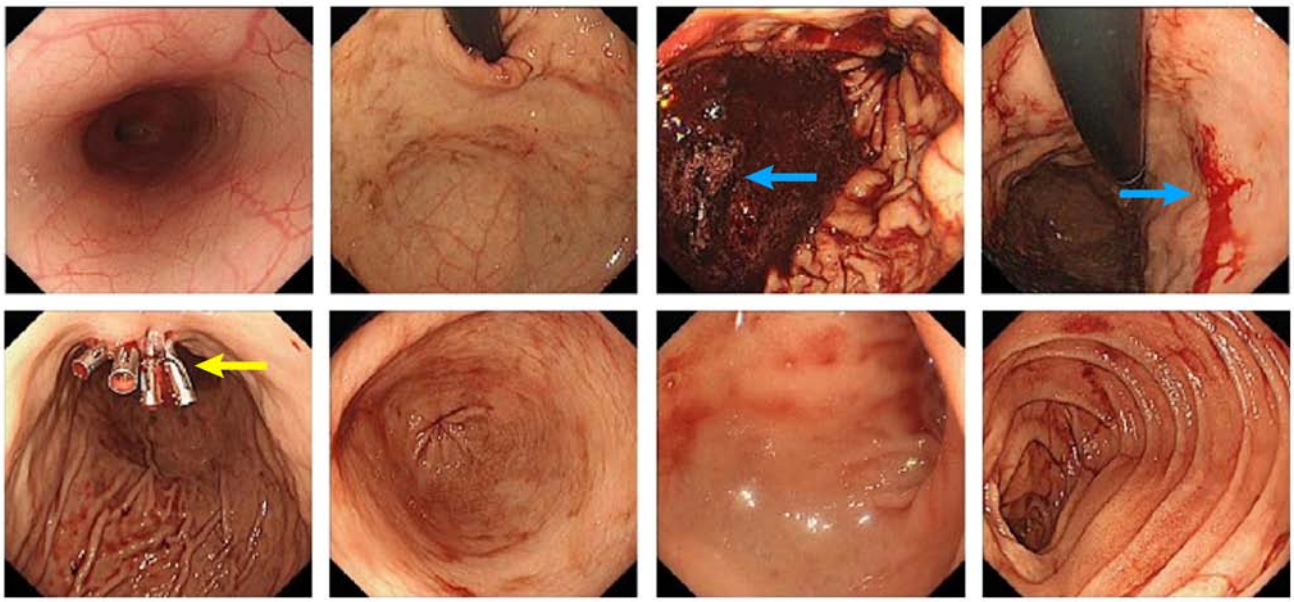

Figure 4. Emergency gastroscopy images. Lots of blood and blood clots (indicated with blue arrows) could be seen in the stomach cavity, and a bleeding spot was detected in the lesser curvature, which was closed with a disposable hemostatic clip (indicated with yellow arrows). There was no apparent bleeding foci in the rest of the gastric body, fundus of the stomach and duodenum. Endoscopic diagnosis was of chronic gastritis with erosion and bleeding.

Apatinib, a medication that was recently authorized by the National Medical Products Administration, may have antiangiogenic and antitumor effects by inhibiting the intracellular ATP-binding site of VEGFR-2 (13). Since October 2014, apatinib has been authorized in China as a third-line therapy for people with advanced gastric cancer. Recent research has demonstrated the anticancer activity of apatinib in several solid malignancies, including non-small cell lung and breast cancer. Since the previous second-line treatment regimen resulted in the longest duration of PFS, gemcitabine, trastuzumab plus apatinib was chosen for patient treatment from October 2018, and was administered for six cycles (3 weeks per cycle). The best efficacy observed was stable disease however, the patient eventually developed nausea and appetite loss, and upper endoscopy showed gastric mucosal tissue indicative of chronic gastritis with erosion (Fig. 3). A parallel gastric mucosa biopsy was taken in February 2019. After 7 days, the patient developed hematemesis and hematochezia. Due to the adverse effect of apatinib, the patient stopped taking apatinib, but no improvement was observed in gastric bleeding. Emergency gastroscopy showed active bleeding in the lesser curvature of the stomach and gastric mucosa clamping was performed to stop the bleeding (Fig. 4). Pathological examination of the gastric mucosa showed lamina propria visible in a variety

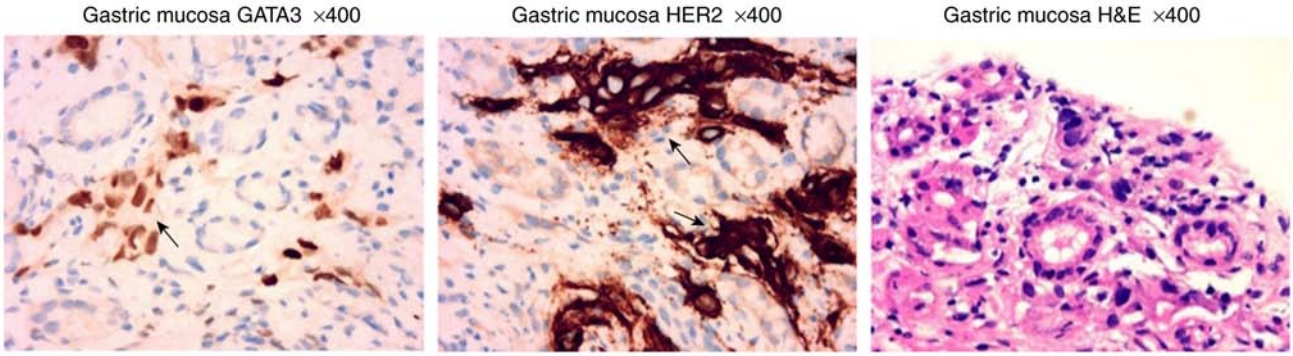

Figure 5. Pathological examination of the gastric mucosa. In the mucosa, lamina propria was visible in a variety of scattered nuclear layer cells and degeneration was detected. When combined with the immunohistochemical findings and the medical history of the patient, breast cancer metastasis was considered. Immunohistochemical results showed: GATA3 (++), HER2 (+++) (GATA3- and HER2-positive expression was indicated with black arrows). HER2, human epidermal growth factor receptor 2; H&E, hematoxylin and eosin.

of scattered nuclear layer cells and degeneration, which, in combination with immunohistochemical findings and medical history, suggested the presence of breast cancer metastasis (14) (Fig. 5). Immunohistochemical results showed: GATA3 (++), AE1/AE3 (+++), HER2 (+++). Gene testing of the primary tumor performed in March 2019 revealed that the breast tissue was negative for BRCA1/2 and had an ERBB2 (HER2) amplification mutation.

As the patient's disease progressed, palliative chemotherapy and targeted therapy were continued. However, few drugs were available for the patient, and they succumbed to heart failure in December 2019.

Discussion

The present study describes a rare case of breast cancer that spread to the stomach and thyroid gland following surgery and systemic treatment. Gastric metastases of breast cancer are infrequent and are difficult to distinguish from primary gastric tumors. In the largest study to date, Taal *et al* (15) reported that 51 cases of metastatic breast cancer were diagnosed by stomach endoscopy, including 36 ILC cases and 10 IDC cases, and the remaining five with particular types. Another single-center retrospective study found that in 97% (34/35) of patients, gastric metastases were derived from lobular carcinoma, suggesting that ILC or luminal-type breast cancer (ER-positive) are more likely to metastasize to the stomach than IDC (4). The present report describes a young patient with HER2-positive IDC with an extensive intraductal component who developed gastric metastases 5 years after surgery, illustrating the possibility of gastric metastases from breast IDC.

When diagnosing stomach metastasis of breast cancer, imaging and endoscopic data are insufficient to distinguish between primary and secondary GI tumors (16). Therefore, the diagnosis requires a biopsy, pathology and endoscopy, and the histological result must be compared to the initial breast cancer (17). Immunohistochemistry has a higher accuracy in differentiating these entities than other methods, such as imaging. With a 100% positivity rate for breast lobular carcinoma and a 96% positivity rate for breast ductal carcinoma, GATA3 has been widely classified as a marker of breast malignancies (18). By contrast, GATA3 has been reported to be stained positively in only 5% of malignant gastric cancer cases (15). Therefore, GATA3 serves as a hormonal marker similar to the function of ER and PR in identifying metastatic cells of mammary origin. Theoretically, *Helicobacter pylori*, inflammatory cells and chemokines may create a favorable environment to attract tumor cells, offering a promising diagnostic approach for gastric metastasis of breast cancer (19). However, some researchers do not agree that chemokines and inflammatory events are involved in the metastatic process of breast cancer (19). Treatment options for GI breast cancer metastases are still subject to debate. Systemic therapy is given high priority, and surgical treatment is taken into account in cases of obstruction or bleeding. In the present case, the patient received targeted therapy combined with chemotherapy for treatment without any further surgical intervention, and survival lasted 10 months, which is similar to the median survival of gastric metastases (20).

Metastasis of breast cancer to the thyroid gland is an uncommon occurrence in clinical practice. Despite the abundance of blood vessels in the thyroid gland, metastatic disease at this site remains rare; however, there have been reported cases of metastatic disease affecting the thyroid gland (21). The most common initial tumor locations for thyroid metastasis in a large series from the Mayo Clinic (97 patients) were the kidney (22%), lung (22%), and head and neck (12%) (22). To the best of our knowledge, Egaña *et al* (23) reported the first case of a patient with thyroid metastasis from breast cancer. In the present case, a patient with thyroid metastasis from breast cancer had no significant symptoms apart from diffuse lesions and elevated thyroglobulin antibodies indicating autoimmune thyroid inflammation. The expression of chemokine receptors could determine the type of tumor that has metastasized, whereas the expression of chemokine ligand can determine the spread site (24). Some chemokine receptors (such as CXCR4) are overexpressed in some tumors and are involved in directing tumor metastasis. Additional studies are required to accurately determine the role of chemokine receptors in the process of metastasis.

Although ILC metastasizes more often to the GI tract, pelvic organs, peritoneum/retroperitoneum and urinary tract than IDC, opportunities still exist for IDC to metastasize to the GI tract. Therefore, it is necessary to consider the possibility

of gastric metastasis. An endoscopic examination should be considered for patients with GI bleeding or other symptoms. Sometimes, it is difficult to detect and diagnose gastric metastasis early due to the absence of typical indicators of primary breast cancer coupled with nonspecific GI symptoms.

In patients with a history of breast cancer, it is essential to consider breast cancer metastasis if they have any discomfort or physical abnormalities. Immunohistochemistry is pivotal to the final diagnosis. For patients whose breast cancer was well-treated and had no associated relapse or distant metastasis, thyroidectomy can be an option for disease-free survival for primary thyroid tumors. However, for most cases of thyroid metastasis, it can respond well to chemotherapy; thus, no thyroidectomy is required. Since metastatic thyroid illness reflects the aggressiveness and advanced stage of the initial disease, the prognosis is often poor (23).

Valuable experience has been gained from this case, which highlights the significance of using a trastuzumab combined chemotherapy treatment approach for advanced HER2-positive breast cancer. However, there is no standardized treatment plan for advanced HER2-positive breast cancer following multiline therapy. Antiangiogenic drugs are targeted medications that inhibit the supply of nutrients to tumor cells, thereby hindering their growth. Apatinib is a small-molecule antiangiogenic drug that may be regarded as a therapeutic choice based on its mechanism of action, although its effectiveness requires further confirmation through clinical trials (13) In the present case, the inefficacy of posterior-line apatinib treatment may be attributed to the poor prognosis of breast cancer metastasis in the thyroid and stomach, and the patient's poor resilience following multiline treatment.

In conclusion, this case report presents a patient diagnosed with IDC with multiple metastases to the lung, pleura, chest wall, various lymph nodes, thyroid, stomach and left adrenal gland. The use of targeted therapy in combination with chemotherapy is an important mode of treatment for patients with advanced breast cancer, including those with gastric and thyroid metastases. Further research should aim to elucidate the mechanism underlying gastric and thyroid metastasis in HER2-positive breast cancer. The prognosis of metastatic breast cancer in the stomach and thyroid glands of young patients is relatively poor (17,22), making systemic treatment more critical than local surgery. Although ER positivity is uncommon in primary gastric cancer, gastric tumors that are GATA3-positive or ER-positive were previously thought to represent metastatic breast cancer (22). Although simultaneous thyroid and stomach metastases from breast cancer are uncommon, they cannot be ignored while assessing sites of metastasis, as overlooking them could impede the diagnosis and treatment of advanced breast cancer and adversely impact patient outcomes. Therefore, it is important to distinguish between the primary tumor and metastatic tumors, which can affect the treatment and prognosis of patients. In the case of breast cancer metastasis to other organs, it can be treated according to the treatment strategy for advanced breast cancer. In the case of primary thyroid or stomach cancer, therapeutic strategies should be selected according to the guidelines for thyroid cancer and stomach cancer, and multidisciplinary consultation should be considered as necessary.

Acknowledgments

Not applicable.

Funding

The National Natural Science Foundation of China (grant no. 81671750, 2016), the National Natural Science Foundation of Guangdong Province (grant no. 2016A030312008) and the Shenzhen Basic Research Program (grant no. JCYJ20180306171227129, 2018) all provided funding in support of this study.

Availability of data and materials

The datasets used and/or analyzed during the current study are available from the corresponding author on reasonable request.

Authors' contributions

XB, CBF and CWD designed the study and wrote the manuscript. XB, BLL, JYH, XLC and XFX confirmed the authenticity of all the raw data. SNH, WCD, ZZL and QYZ gathered medical pictures and examined patient information. BLL, JYH, XLC, XFX, MDL, JYL, JFG, LS, XFL and LPC contributed to the study's conceptualization, general design and quality assurance. All authors have read and approved the final version of the manuscript.

Ethics approval and consent to participate

Not applicable.

Patient consent for publication

Since the patient died, their husband provided written informed consent for the publication of this case report and any related images.

Competing interests

The authors declare that they have no competing interests.

References

1. Li CI, Uribe DJ and Daling JR: Clinical characteristics of different histologic types of breast cancer. Br J Cancer 93: 1046-1052, 2005.
2. Mukaiyama T: Analysis of metastatic and causes of death in 100 autopsied patients with breast cancer. Nyugan Rinsho 4: 121-126, 1989.
3. Ferri LE, Onerheim R and Emond C: Linitis plastica as the first indication of metastatic lobular carcinoma of the breast: Case report and literature review. Can J Surg 42: 466-469, 1999.
4. Almubarak MM, Lae M, Cacheux W, de Cremoux P, Pierga JY, Reyal F, Bennett SP, Falcou MC, Salmon RJ, Baranger B and Mariani P: Gastric metastasis of breast cancer: A single centre retrospective study. Dig Liver Dis 43: 823-827, 2011.
5. Hong J, Kim Y, Cho J, Lim SW, Park SE, Kim HK, Lee H, Cho SY, Kim JY, Ahn JS, *et al*: Clinical features and prognosis of breast cancer with gastric metastasis. Oncol Lett 17: 1833-1841, 2019.
6. Pectasides D, Psyrri A, Pliarchopoulou K, Floros T, Papaxoinis G, Skondra M, Papatsibas G, Macheras A, Athanasas G, Arapantoni-Datioti P and Economopoulos T: Gastric metastases originating from breast cancer: Report of 8 cases and review of the literature. Anticancer Res 29: 4759-4763, 2009.

7. Mazzaferri EL and Sipos J: Should all patients with subcentimeter thyroid nodules undergo fine-needle aspiration biopsy and preoperative neck ultrasonography to define the extent of tumor invasion? Thyroid 18: 597-602, 2008.
8. Thompson L: Neoplasms metastatic to the thyroid gland. Ear Nose Throat J 85: 480, 483, 2006.
9. Kim DH, Son SM and Choi YJ: Gastric metastasis from invasive lobular breast cancer, mimicking primary gastric cancer: A case report. Medicine (Baltimore) 97: e0258, 2018.
10. Chung AY, Tran TB, Brumund KT, Weisman RA and Bouvet M: Metastases to the thyroid: A review of the literature from the last decade. Thyroid 22: 258-268, 2012.
11. Riley DS, Barber MS, Kienle GS, Aronson JK, von Schoen-Angerer T, Tugwell P, Kiene H, Helfand M, Altman DG, Sox H, *et al*: CARE guidelines for case reports: Explanation and elaboration document. J Clin Epidemiol 89: 218-235, 2017.
12. Cserni G, Chmielik E, Cserni B and Tot T: The new TNM-based staging of breast cancer. Virchows Arch 472: 697-703, 2018.
13. Xia H, Zhou C, Luo Z, Zhang P, Zhu L and Gong Z: Apatinib-Induced Hand-foot skin reaction in chinese patients with liver cancer. Front Oncol 11: 624369, 2021.
14. Hui Y, Wang Y, Nam G, Fanion J, Sturtevant A, Lombardo KA and Resnick MB: Differentiating breast carcinoma with signet ring features from gastrointestinal signet ring carcinoma: Assessment of immunohistochemical markers. Hum Pathol 77: 11-19, 2018.
15. Taal BG, Peterse H and Boot H: Clinical presentation, endoscopic features, and treatment of gastric metastases from breast carcinoma. Cancer 89: 2214-2221, 2000.
16. Ciulla A, Castronovo G, Tomasello G, Maiorana AM, Russo L, Daniele E and Genova G: Gastric metastases originating from occult breast lobular carcinoma: diagnostic and therapeutic problems. World J Surg Oncol 6: 78, 2008.
17. Jones GE, Strauss DC, Forshaw MJ, Deere H, Mahedeva U and Mason RC: Breast cancer metastasis to the stomach may mimic primary gastric cancer: Report of two cases and review of literature. World J Surg Oncol 5: 75, 2007.
18. Liu H, Shi J, Wilkerson ML and Lin F: Immunohistochemical evaluation of GATA3 expression in tumors and normal tissues: A useful immunomarker for breast and urothelial carcinomas. Am J Clin Pathol 138: 57-64, 2012.
19. Villa Guzman JC, Espinosa J, Cervera R, Delgado M, Paton R and Cordero Garcia JM: Gastric and colon metastasis from breast cancer: Case report, review of the literature, and possible underlying mechanisms. Breast Cancer (Dove Med Press) 9: 1-7, 2017.
20. Xu L, Liang S, Yan N, Zhang L, Gu H, Fei X, Xu Y and Zhang F: Metastatic gastric cancer from breast carcinoma: A report of 78 cases. Oncol Lett 14: 4069-4077, 2017.
21. Magers MJ, Dueber JC, Lew M, Pang JC and Davenport RD: Metastatic ductal carcinoma of the breast to the thyroid gland diagnosed with fine needle aspiration: A case report with emphasis on morphologic and immunophenotypic features. Diagn Cytopathol 44: 530-534, 2016.
22. Hegerova L, Griebeler ML, Reynolds JP, Henry MR and Gharib H: Metastasis to the thyroid gland: Report of a large series from the Mayo Clinic. Am J Clin Oncol 38: 338-342, 2015.
23. Egaña N, Socias C, Matteucci T, Bilbao I and Alvarez-Coca M: Thyroid metastasis of lobular breast carcinoma. Endocrinol Nutr 59: 219-220, 2012 (In Spanish).
24. DiNatale A, Castelli MS, Nash B, Meucci O and Fatatis A: Regulation of tumor and metastasis initiation by chemokine receptors. J Cancer 13: 3160-3176, 2022.