SPANDIDOS PUBLICATIONS

ONCOLOGY LETTERS 26: 405, 2023

Synchronous primary colorectal mucinous adenocarcinoma and pancreatic ductal adenocarcinoma: A case report

XUDONG QIU[1*], BO NI[1*], YANYING SHEN[2*], YEQIAN ZHANG[1], XIANG XIA[1], HUI CAO[1], ZIZHEN ZHANG[1] and CHUNCHAO ZHU[1]

Departments of [1]Gastrointestinal Surgery and [2]Pathology, Ren Ji Hospital, School of Medicine, Shanghai Jiao Tong University, Shanghai 200127, P.R. China

Received February 22, 2023; Accepted July 11, 2023

DOI: 10.3892/ol.2023.13991

Abstract. The present study reports a rare case of synchronous colorectal mucinous adenocarcinoma (CMAC) and pancreatic ductal adenocarcinoma (PDAC). A 61-year-old man complained of hematochezia for half a month. Colonoscopy and biopsy in a local hospital revealed mucinous adenocarcinoma in the sigmoid colon, and a subsequent abdominal computed tomography examination in Ren Ji Hospital (Shanghai, China) identified an unexpectedly hypovascular lesion in the body and tail of the pancreas, in addition to a mass in the colon. The patient then underwent combined surgery consisting of a distal pancreaticosplenectomy and a sigmoidectomy, and the postoperative pathological tests confirmed the co-occurrence of CMAC and PDAC. Next-generation sequencing demonstrated no deleterious germline mutations, but did find some critical somatic mutations concerning both tumors. The patient received 12 cycles of a combination of 5-fluorouracil, leucovorin, irinotecan and oxaliplatin (modified FOLFIRINOX regimen) as adjuvant chemotherapy thereafter. Complete remission was achieved at 1 year after the surgery. To the best of our knowledge, this is the first documented case of such synchronous malignances (CMAC and PDAC) in the literature, and its publication therefore improves our overall understanding in this field.

Correspondence to: Dr Zizhen Zhang or Dr Chunchao Zhu, Department of Gastrointestinal Surgery, Ren Ji Hospital, School of Medicine, Shanghai Jiao Tong University, 160 Pu Jian Road, Shanghai 200127, P.R. China
E-mail: zhangzizhen@renji.com
E-mail: zhuchunchao@renji.com

[*]Contributed equally

Key words: multiple primary neoplasms, colorectal mucinous adenocarcinoma, pancreatic ductal adenocarcinoma, adjuvant chemotherapy, next-generation sequencing

Introduction

Colorectal cancer (CRC) and pancreatic cancer (PC) are both among the leading causes of cancer-associated deaths in the United States (US) (1,2). CRC is the second most common cancer diagnosed in women and the third most common cancer in men, with population-based annual incidence rates of ~37.7 cases per 100,000 individuals in the US (1). PC is a relatively uncommon cancer, with ~13.3 diagnoses per 100,000 individuals in the US each year (2,3); however, it is predicted to be the second leading cause of cancer-related mortality in the US by 2030, owing to its advanced stage at diagnosis and resistance to chemotherapy (4).

Multiple primary neoplasms (MPNs), defined as the presence of two or more histologically distinct neoplasms that are not due to recurrence or metastasis in the same individual, are grouped into two large categories, namely synchronous neoplasms (the second primary neoplasm is diagnosed within 6 months after the diagnosis of the first neoplasm) and metachronous neoplasms (the second primary neoplasm is diagnosed >6 months after the diagnosis of the first neoplasm) (5,6). Over the past decades, MPNs have been reported quite frequently but have rarely involved both CRC and PC (7,8). Dayer *et al* (8) reported a case of a synchronous CRC and pancreatic neuroendocrine tumor, a less common neoplasm arising from the pancreas with a distinct molecular profile and natural history from PDAC. Li Destri *et al* (9) reported only two confirmed PC cases (one synchronous and the other metachronous) out of 842 CRC cases (0.24%). There are no established guidelines for the management of MPNs, therefore making clinical decisions difficult. The present study reports the case of a 61-year-old man presenting with synchronous CMAC and PDAC. The study aims to report this experience in order to shed light on potential clues regarding the etiology of MPNs.

Case report

A 61-year-old man presented to the local hospital with hematochezia for half a month. The patient did not have bowel habit changes, nausea, emesis or body weight loss during this episode. The patient had been drinking and smoking for 20 years, and had been taking medication for primary

hypertension for 1 year. There was no history of malignancy in the family. The patient underwent a colonoscopy and was found to have an ulcerative mass of 2 cm in diameter in the sigmoid colon (Fig. 1A). Histological examination (hematoxylin and eosin staining) of the biopsy specimens showed abundant mucous in the extracellular space, which indicated mucinous adenocarcinoma (Fig. 1B). The patient was then transferred to Ren Ji Hospital (Shanghai, China) for further diagnosis and treatment. A physical examination revealed no specific signs of illness. Laboratory examinations showed that tumor biomarker levels, including those for carcinoembryonic antigen and carbohydrate antigen 19-9, were all within the normal ranges. Consistent with the findings of the colonoscopy, abdominal contrast-enhanced computed tomography (CT) showed that the thickened sigmoid colon wall was unevenly strengthened with a rough surface (Fig. 1C). Unexpectedly, a hypovascular lesion was also discovered in the body and tail of the pancreas, which highly suggested the occurrence of pancreatic cancer (Fig. 1D).

A multidisciplinary team of internists, surgeons, oncologists, radiologists and pathologists diagnosed the patient with synchronous CRC and PC after a comprehensive analysis of the clinical findings, and proposed combined surgery for the two tumors. Thereafter, a distal pancreaticosplenectomy and a radical sigmoidectomy with end-to-end colorectal anastomosis were performed. Grossly, there was an ulcerative and hard bulging mass of 2 cm in diameter invading the serosal layer of the sigmoid colon. In addition, there was another gray and hard mass of 4 cm in diameter in the body and tail of the pancreas, with surrounding vessels dilated and congested. Microscopically, the sections of the colon specimens showed poorly differentiated adenocarcinoma with lymph node metastasis (3/14 lymph nodes), most of which (>50%) consisted of a mucinous component (Fig. 2A). Angiolymphatic and perineural invasion were both positive. The pancreatic specimen was determined to be moderately differentiated ductal adenocarcinoma with lymph node metastasis (1/16 lymph nodes) and angiolymphatic and perineural invasion (Fig. 2B). Immunohistochemically, the CRC cells were negative for CK7 (Fig. 2C), while the PC cells were positive for CK7 (Fig. 2D), implicating a histologically distinct origin. Additionally, in terms of the expression level of TP53, the CRC cells exhibited a strongly positive pattern (Fig. 2E), whereas the PC cells demonstrated a weakly positive pattern (Fig. 2F). The mismatch repair status was stable in both tumors according to the findings of immunohistochemical (IHC) staining, with retained expression of DNA mismatch repair protein Mlh1 (MLH1), DNA mismatch repair protein Msh2 (MSH2), MSH6 and mismatch repair endonuclease PMS2 (PMS2) proteins (Fig. S1). To uncover the underlying genetic alterations, a comprehensive molecular analysis by next-generation sequencing (NGS) (a panel of 520 gene hotspot mutations closely associated with tumorigenesis and targeted therapy) was conducted. NGS revealed a missense mutation of KRAS in PC. With respect to CRC, a nonsense mutation of APC was discovered, and a missense mutation of TP53 was observed, partially explaining its high expression level as shown by IHC stain. There were no deleterious germline mutations in the two tumors. The protocols of hematoxylin and eosin staining, IHC staining and NGS are reported in Data S1.

At 6 weeks after surgery, the patient started to receive a combination of 5-fluorouracil (2,400 mg/m^2 of body surface area), leucovorin (400 mg/m^2), irinotecan (150 mg/m^2) and oxaliplatin (85 mg/m^2) (modified FOLFIRINOX regimen) every 2 weeks and completed 12 cycles, without serious adverse events documented. The patient was followed up every third month after surgery and had recovered well and was free of cancer recurrence at the 1-year follow-up.

Discussion

Emerging evidence suggests that the increasing occurrence of MPNs is affected by a myriad of factors, including the late effects of cancer therapy, genetic predisposition, behavioral and lifestyle factors, environmental determinants (such as viral infection and occupation), host effects (such as age, sex, immune function and hormones) and combinations of these factors (such as gene-environment interactions) (10). On the basis of the major etiological factors, Travis *et al* (11) categorized MPNs into three distinct groups, including treatment-associated MPNs, syndromic MPNs and those with shared etiology.

Despite the fact that great advances in cancer therapy, such as chemotherapy, immunotherapy and targeted therapy, have markedly improved the overall survival time of patients with cancer, they have significantly increased the risk of MPNs for cancer survivors, partially due to acquired somatic gene mutations and chromosomal abnormalities (12). For instance, the use of alkylating agents and DNA-topoisomerase inhibitors has increased the risk of secondary leukemia (13). However, in the present case, the patient had not previously undergone anticancer therapy, therefore excluding the possibility of treatment-associated MPNs.

Individuals with germline mutations in cancer predisposition genes are prone to various benign or malignant tumors; therefore, they may be eligible for high-risk screening and prevention strategies. To date, >100 of these genes have been identified, such as TP53, APC, BRCA1, BRCA2 and PMS2 (14,15). Heterozygous germline mutations occur in most cases (16). The most common cancer syndrome identified in patients with CRC is hereditary nonpolyposis CRC, also termed Lynch syndrome, which is characterized by a germline mutation of a mismatch repair gene, including MLH1, MSH2, PMS2 and MSH6, or a germline deletion of EpCAM (17). In this study, as shown by the results of IHC, tumor cells in both CMAC and PDAC stably expressed MLH1, MSH2, PMS2 and MSH6, therefore excluding the possibility of Lynch syndrome. Additionally, no pathogenic germline mutations were detected by NGS, indicating that the two tumors may arise from a sporadic occurrence.

It is acknowledged that progressive accumulation of somatic gene mutations resulting from replication errors or DNA damage throughout life could result in sporadic cancer (18). In the present case, somatic mutations of oncogenes were observed in both cancer types. A somatic mutation of KRAS, an essential gene controlling MAPK signaling, is the most common oncogenic alteration in PDAC, occurring in ~90% of cases (19), including the present case. This mutation facilitates PDAC cell survival by protecting against inflammation-associated senescence and promoting autophagy,

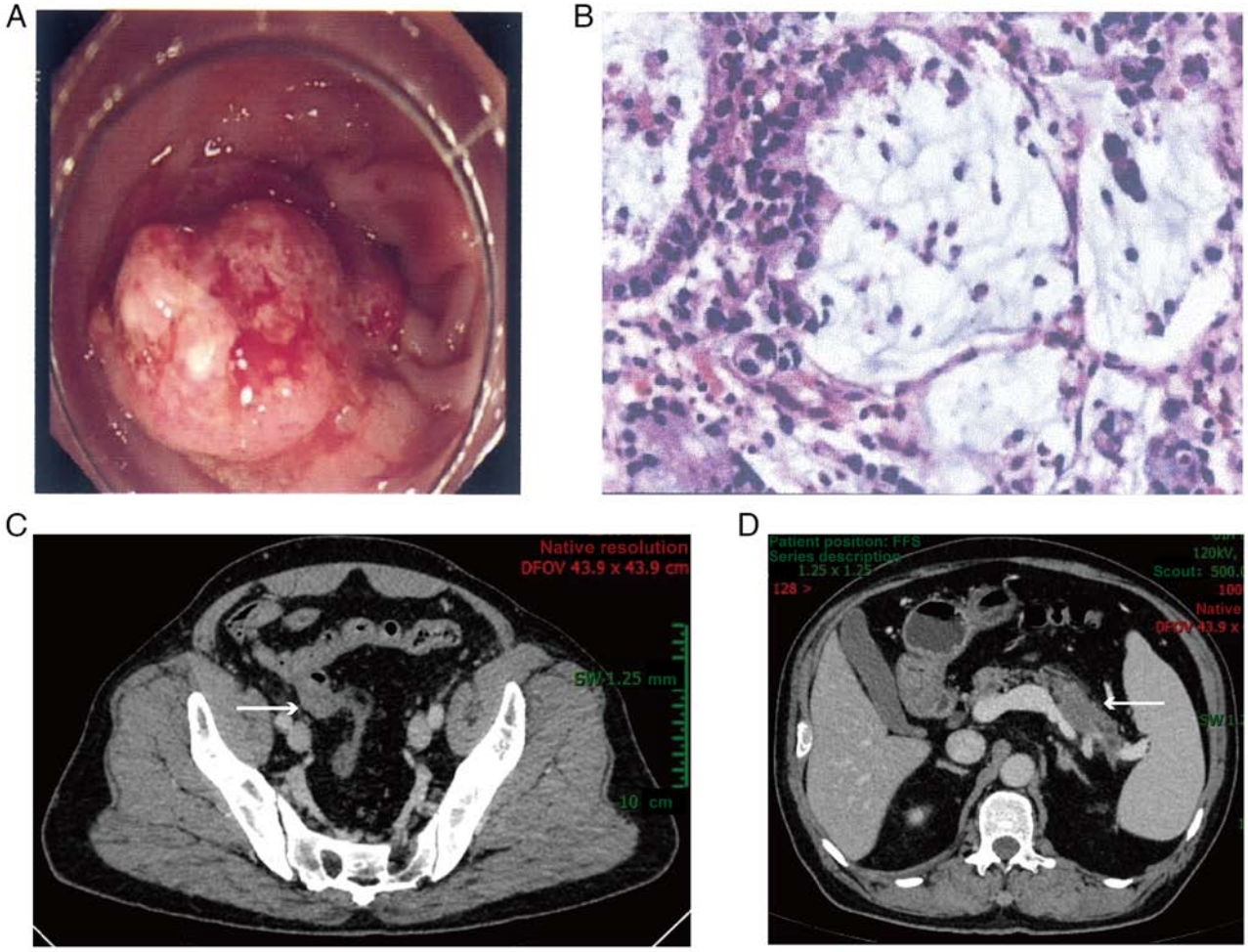

Figure 1. (A) Colonoscopy showing an ulcerative mass in the sigmoid colon. (B) Histological specimen showing colorectal mucinous adenocarcinoma (hematoxylin and eosin stain; x400 magnification). Abdominal contrast-enhanced computed tomography showing (C) a thickened sigmoid colon wall that is unevenly strengthened (arrow) and (D) a hypovascular lesion in the body and tail of the pancreas (arrow).

micropinocytosis and stress granule formation (20). KRAS mutation is also frequently observed in CRC and non-small cell lung cancer (NSCLC), and serves as a promising target for cancer therapy (21-24). TP53 is an essential tumor suppressor gene that can sense DNA damage and then arrest the cell cycle, acting as the so-called 'guardian of the genome'. A somatic mutation of TP53 can be found in various cancer types, including CRC, PDAC, gastric cancer (GC), NSCLC, lymphoma and leukemia (25-27). This mutation is closely associated with colorectal adenoma-carcinoma transition and confers a poor prognosis (28). Compared with mutations in the aforementioned two genes, the somatic mutation of APC predominantly occurs in CRC (1). Through the regulation of β-catenin levels and localization, APC functions as a tumor suppressor, and inactivation attributable to somatic mutation occurs in 70-80% of sporadic CRC cases (29).

Previous reports of MPNs involving CRC or PDAC highlight genetic alteration as a potential factor fostering cancer initiation and progression (30-34). Hirata *et al* (32) reported a case of Lynch syndrome. The patient, who had a history of rectal and urinary bladder cancer, developed a liposarcoma in the left thigh. Genetic tests of a blood sample revealed a pathogenic germline mutation of MSH2 (32). In another case, an 86-year-old man was diagnosed with synchronous CRC and B-cell chronic lymphocytic leukemia. Somatic mutations of KRAS and BRAF were determined in the CRC specimen (34). In another patient with metachronous CRC and breast cancer, genetic tests demonstrated constitutional hypermethylation of the MLH1 promoter in both of the cancer specimens, while no germline or somatic mutations were found, suggesting an essential role of epigenetic mutation in tumorigenesis (31). Consistent with the present case, a somatic mutation of KRAS was discovered in a previous case involving PDAC (33). Furthermore, in a 56-year-old man with metachronous PDAC and hereditary diffuse GC, a germline mutation of CDH1 was identified in the GC. In terms of PDAC, somatic mutations of KRAS and TP53 were determined, but no CDH1 mutation was found, indicating a histologically distinct origin of the two tumors (33).

The role of lifestyle factors, such as tobacco use, excessive alcohol intake and obesity, emerges as an area of great interest with regard to MPNs. Tobacco products lead to millions of cancer-associated deaths per year worldwide and are one of the major causes of MPNs. Tobacco delivers a plethora of carcinogens, such as polycyclic aromatic hydrocarbons and volatile organic compounds, which are responsible for the somatic mutations observed in cancer predisposition genes (35). Alcohol intake is another acknowledged risk factor for cancer.

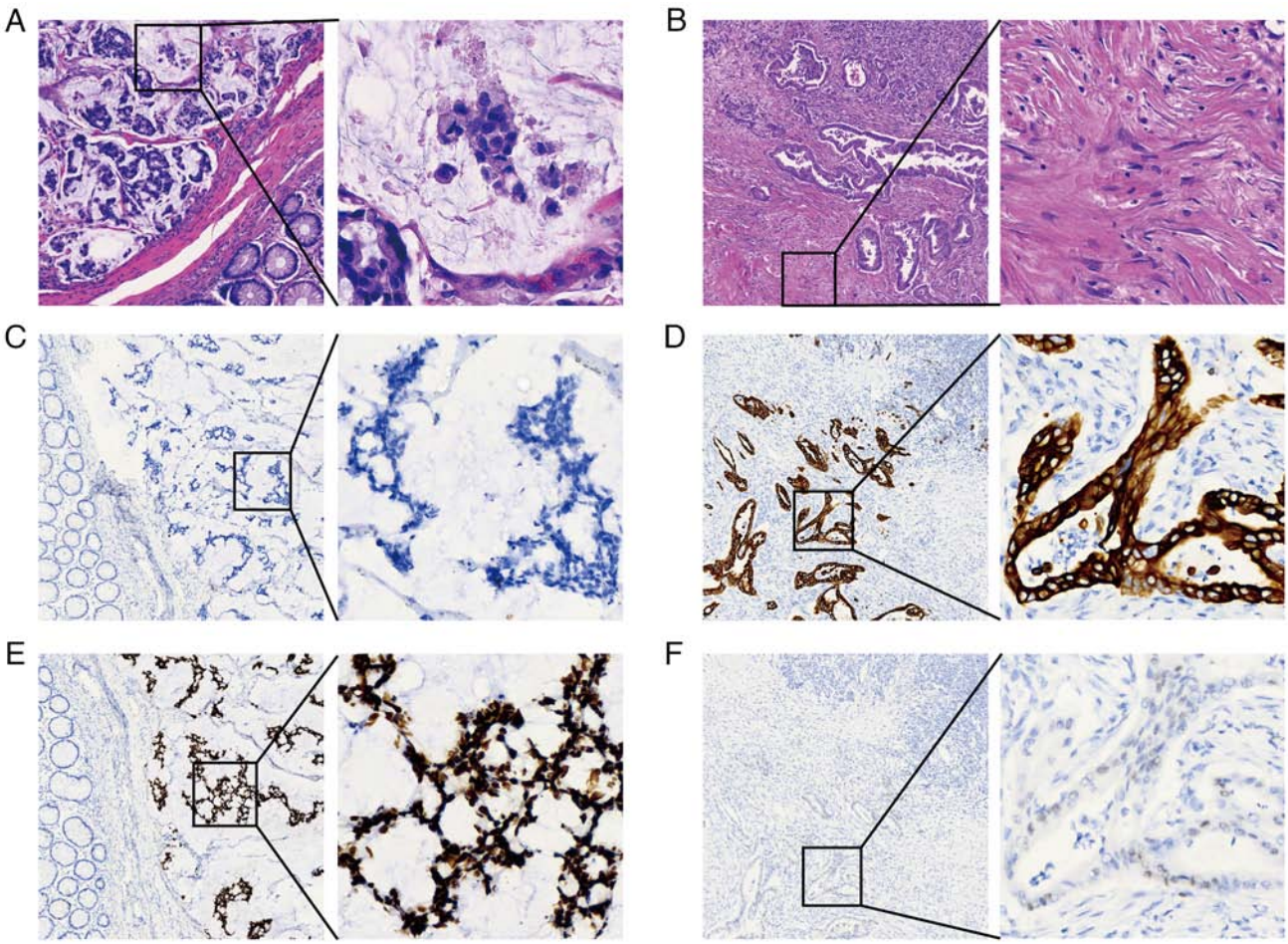

Figure 2. Microscopic examination showing (A) colorectal mucinous adenocarcinoma (HE stain) and (B) pancreatic ductal adenocarcinoma (HE stain). Colorectal cancer cells were negative for (C) CK7 (IHC stain) and strongly positive for (E) TP53 (IHC stain), whereas pancreatic cancer cells were (D) positive for CK7 (IHC stain) and (F) weakly positive for TP53 (IHC stain) (all images: Left, x40 magnification; inset right, x200 magnification). HE, hematoxylin and eosin; IHC, immunohistochemical.

Multiple mechanisms are responsible for its oncogenic effect, including the genotoxic effect of acetaldehyde (the primary metabolite of alcohol), increased estrogen levels, the production of reactive oxygen species and nitrogen species, and changes in folate metabolism (36). Notably, Prabhu *et al* (37) discovered a positive synergistic effect of alcohol and tobacco use on the risk of esophageal squamous cell carcinoma. In the present case, the patient had a 20-year history of drinking and smoking, therefore placing himself at an elevated risk of various tumors. There is therefore a pressing need to improve people's lifestyles, for example, encouraging them to control weight and alcohol consumption, and quit smoking, which may contribute to the prevention of MPNs.

Adenocarcinoma is the most common form of CRC, occurring in ~85% of patients with CRC, whereas only 10-15% of patients with CRC are diagnosed with mucinous adenocarcinoma, which is characterized by abundant extracellular mucin comprising at least 50% of the tumor volume (38). Compared with the non-mucinous subtype, mucinous colorectal adenocarcinoma is more frequently diagnosed at an advanced stage (39). In addition, it has an aberrant metastatic pattern and it often metastasizes to more than one site, especially to extrahepatic regions, such as distant lymph nodes and the peritoneum, which predicts a poor prognosis (38). In the present case, no distant metastases were found, with only regional lymph node metastases, suggesting localized advanced disease.

Due to the lack of specific symptoms at an early stage, ~90% of patients with PC are diagnosed at an advanced stage, with systematic metastasis observed in >50% of cases, therefore leading to a high mortality rate (40). Regarding the diagnostic modalities, abdominal CT angiography exhibits a sensitivity ranging from 76 to 96% in the detection of PC, which is helpful in the assessment of vascular anatomy and stage of disease (41). Endoscopic ultrasound-guided fine-needle aspiration (EUS-FNA) is recognized as an adjunctive tool for tissue acquisition to confirm the histologic diagnosis and facilitate molecular analysis (2). In the present case, it would have been more rational to have conducted EUS-FNA before the surgery; however, the patient declined due to the potential complications, such as infection, hemorrhage and pancreatitis.

In the present case, the patient complained of hematochezia for half a month, which is a common sign of CRC. The subsequent colonoscopy and hematoxylin and eosin staining of the biopsy specimens revealed the diagnosis of mucinous adenocarcinoma in the sigmoid colon. The findings of the abdominal contrast-enhanced CT showed an unevenly strengthened mass in the sigmoid colon, further validating the diagnosis of

CMAC, the origin of which was unknown. Another hypodense lesion in the pancreas was also identified in the CT scan. It has been established that primary PC typically appears as hypodense relative to the pancreatic parenchyma owing to high interstitial pressures within the tumor tissue (42), which is in line with the present case. However, metastatic pancreatic lesions arising from CRC appeared hyperdense in a previous case, indicating that the possibility of metastatic PC was relatively low (43). The most likely method of cancer metastasis from the pancreas to the sigmoid colon is through the blood vessels. However, the vein of the pancreas leads to the liver via the portal vein. Hence, the possibility of solitary colonic metastasis without liver metastasis is extremely low. Based on the aforementioned facts, in the present study, it was assumed that the patient had synchronous colonic and pancreatic cancer, and the postoperative pathological tests corroborated this hypothesis.

As there are no established guidelines for MPNs involving both CMAC and PDAC, treatment protocols should be tailored to the specific condition of the patient, including functional status, tumor stage, gene mutation and economic status. In the present study, after a comprehensive analysis of the preoperative CT scan, the tumors were both determined to be resectable and a combined surgical resection was performed followed by adjuvant chemotherapy with curative intent. According to results of the multicenter PRODIGE-24 trial, the modified FOLFIRINOX regimen is recommended as the first-line adjuvant chemotherapy for patients with resected PDAC who exhibit excellent performance status (Eastern Cooperative Oncology Group Score, 0-1) (44,45). Fluoropyrimidine and oxaliplatin are the cornerstones of adjuvant chemotherapy for patients with CRC in stage III and a subset of those in stage II. The therapeutic role of irinotecan in metastatic CRC has been widely acknowledged (1). Therefore, in the present study, the modified FOLFIRINOX regimen was chosen as the adjuvant chemotherapy, due to it ability to exert cytotoxic effects on both cancer cell types. CMAC has been reported with impaired responses to current chemotherapies, as the surrounding mucous may function as a physical barrier to the drugs (39). Nevertheless, the current patient responded well and has not shown any sign of recurrence or metastasis up to the time of this report.

In conclusion, the present study reports a rare case of synchronous CMAC and PDAC in a 61-year-old man without a family history of malignancy. Radical surgery was undertaken to remove the two tumors concurrently, followed by adjuvant chemotherapy, which proved to be effective. As demonstrated by the NGS results, no deleterious germline mutations were found, whereas critical somatic mutations were discovered in both tumors. In addition, unhealthy lifestyle factors were identified in the patient, suggesting that the disease may be a result of a complex interaction between genes and the environment. Overall, it is of great importance to identify additional primary malignancies in clinical practice, as they could largely influence the planned therapeutic schedule, and thereby the long-term outcomes of patients.

Acknowledgements

Not applicable.

Funding

This study was funded by The Natural Science Foundation of Shanghai (grant no. 22ZR1438800).

Availability of data and materials

The datasets used and/or analyzed during the present study are available from the corresponding author on reasonable request. Data sequences from NGS are not available due to the use of proprietary computational algorithms and to protect patient anonymity.

Authors' contributions

XQ, ZZ and CZ conceived and designed the study. BN, YS, YZ, XX and HC acquired and interpreted the clinical data. XQ, BN and YS drafted and revised the manuscript. ZZ and CZ confirm the authenticity of all the raw data. All authors have read and approved the final manuscript.

Ethics approval and consent to participate

Not applicable.

Patient consent for publication

Written informed consent was obtained from the patient for publication of the case report and accompanying images.

Competing interests

The authors declare that they have no competing interests.

References

1. Dekker E, Tanis PJ, Vleugels JLA, Kasi PM and Wallace MB: Colorectal cancer. Lancet 394: 1467-1480, 2019.
2. Wood LD, Canto MI, Jaffee EM and Simeone DM: Pancreatic cancer: Pathogenesis, screening, diagnosis, and treatment. Gastroenterology 163: 386-402.e1, 2022.
3. Park W, Chawla A and O'Reilly EM: Pancreatic cancer: A review. JAMA 326: 851-862, 2021.
4. Rahib L, Smith BD, Aizenberg R, Rosenzweig AB, Fleshman JM and Matrisian LM: Projecting cancer incidence and deaths to 2030: The unexpected burden of thyroid, liver, and pancreas cancers in the United States. Cancer Res 74: 2913-2921, 2014.
5. Zhai C, Cai Y, Lou F, Liu Z, Xie J, Zhou X, Wang Z, Fang Y, Pan H and Han W: Multiple primary malignant tumors-a clinical analysis of 15,321 patients with malignancies at a single center in China. J Cancer 9: 2795-2801, 2018.
6. Warren S: Multiple primary malignant tumors. A survey of the literature and a statistical study. Am J Cancer 16: 1358-1414, 1932.
7. Sakellakis M, Peroukides S, Iconomou G, Boumpoucheropoulos S and Kalofonos H: Multiple primary malignancies: A report of two cases. Chin J Cancer Res 26: 215-218, 2014.
8. Dayer N, Fasquelle F, Salati E and Dietrich G: Multiple primary malignancies: Synchronous lymphoma, pancreatic neuroendocrine tumour and colorectal cancer. BMJ Case Rep 14: e241938, 2021.
9. Li Destri G, Giarrizzo A, Bellavia N, Milazzotto R, Frattalone ME, Scilletta B and Di Cataldo A: Synchronous double cancers of the colon and the pancreas: A case report. Eur Rev Med Pharmacol Sci 18: 28-31, 2014.
10. Travis LB, Demark Wahnefried W, Allan JM, Wood ME and Ng AK: Aetiology, genetics and prevention of secondary neoplasms in adult cancer survivors. Nat Rev Clin Oncol 10: 289-301, 2013.

11. Travis LB, Rabkin CS, Brown LM, Allan JM, Alter BP, Ambrosone CB, Begg CB, Caporaso N, Chanock S, DeMichele A, *et al*: Cancer survivorship-genetic susceptibility and second primary cancers: Research strategies and recommendations. J Natl Cancer Inst 98: 15-25, 2006.
12. Wood ME, Vogel V, Ng A, Foxhall L, Goodwin P and Travis LB: Second malignant neoplasms: Assessment and strategies for risk reduction. J Clin Oncol 30: 3734-3745, 2012.
13. Leone G, Pagano L, Ben-Yehuda D and Voso MT: Therapy-related leukemia and myelodysplasia: Susceptibility and incidence. Haematologica 92: 1389-1398, 2007.
14. Zhang J, Walsh MF, Wu G, Edmonson MN, Gruber TA, Easton J, Hedges D, Ma X, Zhou X, Yergeau DA, *et al*: Germline mutations in predisposition genes in pediatric cancer. N Engl J Med 373: 2336-2346, 2015.
15. Rahman N: Realizing the promise of cancer predisposition genes. Nature 505: 302-308, 2014.
16. Carbone M, Arron ST, Beutler B, Bononi A, Cavenee W, Cleaver JE, Croce CM, D'Andrea A, Foulkes WD, Gaudino G, *et al*: Tumour predisposition and cancer syndromes as models to study gene-environment interactions. Nat Rev Cancer 20: 533-549, 2020.
17. Sinicrope FA: Lynch syndrome-associated colorectal cancer. N Engl J Med 379: 764-773, 2018.
18. Martincorena I and Campbell PJ: Somatic mutation in cancer and normal cells. Science 349: 1483-1489, 2015.
19. Cancer Genome Atlas Research Network. Electronic address: andrew_aguirre@dfci.harvard.edu; Cancer Genome Atlas Research Network: Integrated genomic characterization of pancreatic ductal adenocarcinoma. Cancer Cell 32: 185-203.e13, 2017.
20. Hayashi A, Hong J and Iacobuzio-Donahue CA: The pancreatic cancer genome revisited. Nat Rev Gastroenterol Hepatol 18: 469-481, 2021.
21. JCO Flashback: Predictive value of KRAS mutations on the outcomes of panitumumab monotherapy in colorectal cancer. J Clin Oncol 41: 3277, 2023.
22. Dy GK, Govindan R, Velcheti V, Falchook GS, Italiano A, Wolf J, Sacher AG, Takahashi T, Ramalingam SS, Dooms C, *et al*: Long-term outcomes and molecular correlates of sotorasib efficacy in patients with pretreated KRAS G12C-mutated non-small-cell lung cancer: 2-year analysis of CodeBreaK 100. J Clin Oncol 41: 3311-3317, 2023.
23. van de Haar J, Ma X, Ooft SN, van der Helm PW, Hoes LR, Mainardi S, Pinato DJ, Sun K, Salvatore L, Tortora G, *et al*: Codon-specific KRAS mutations predict survival benefit of trifluridine/tipiracil in metastatic colorectal cancer. Nat Med 29: 605-614, 2023.
24. Mullard A: The KRAS crowd targets its next cancer mutations. Nat Rev Drug Discov 22: 167-171, 2023.
25. Karlsson K, Przybilla MJ, Kotler E, Khan A, Xu H, Karagyozova K, Sockell A, Wong WH, Liu K, Mah A, *et al*: Deterministic evolution and stringent selection during preneoplasia. Nature 618: 383-393, 2023.
26. Frankell AM, Dietzen M, Al Bakir M, Lim EL, Karasaki T, Ward S, Veeriah S, Colliver E, Huebner A, Bunkum A, *et al*: The evolution of lung cancer and impact of subclonal selection in TRACERx. Nature 616: 525-533, 2023.
27. Shen R, Fu D, Dong L, Zhang MC, Shi Q, Shi ZY, Cheng S, Wang L, Xu PP and Zhao WL: Simplified algorithm for genetic subtyping in diffuse large B-cell lymphoma. Signal Transduct Target Ther 8: 145, 2023.
28. Iacopetta B: TP53 mutation in colorectal cancer. Hum Mutat 21: 271-276, 2003.
29. Fearon ER: Molecular genetics of colorectal cancer. Ann Rev Pathol 6: 479-507, 2011.
30. Aaquist T, Dembic M, Thomassen M, de Stricker K, Bertelsen M, Christensen LG, Mortensen MB and Detlefsen S: Synchronous detection of pancreatic adenocarcinoma and paraganglioma in a Whipple resection specimen. Pathology Res Pract 226: 153590, 2021.
31. Brandler J, Wu TT and Sweetser S: Young onset breast and colon cancer. Gastroenterology 152: e12-e13, 2017.
32. Hirata K, Kanemitsu S, Nakayama Y, Nagata N, Itoh H, Ohnishi H, Ishikawa H and Furukawa Y: A novel germline mutation of MSH2 in a hereditary nonpolyposis colorectal cancer patient with liposarcoma. Am J Gastroenterol 101: 193-196, 2006.
33. Ottenhof NA, de Wilde RF, Morsink FH, de Leng WW, Ausems MG, Morreau H, van Hillegersberg R, Offerhaus GJ and Milne AN: Pancreatic ductal adenocarcinoma in hereditary diffuse gastric cancer. A case report. Hum Pathol 43: 457-461, 2012.
34. Silvestris N, Zito FA, Fiore MG, Simone G, Tommasi S, Izzi G, Guarini A and Colucci G: Synchronous presentation of B-cell chronic lymphocytic leukemia/small-cell lymphoma and colon adenocarcinoma within the same mesenteric lymph nodes and a single liver metastasis. J Clin Oncol 29: e11-e13, 2011.
35. Hecht SS and Hatsukami DK: Smokeless tobacco and cigarette smoking: Chemical mechanisms and cancer prevention. Nat Rev Cancer 22: 143-155, 2022.
36. Boffetta P and Hashibe M: Alcohol and cancer. Lancet Oncol 7: 149-156, 2006.
37. Prabhu A, Obi KO and Rubenstein JH: The synergistic effects of alcohol and tobacco consumption on the risk of esophageal squamous cell carcinoma: A meta-analysis. Am J Gastroenterol 109: 822-827, 2014.
38. Hugen N, Brown G, Glynne-Jones R, de Wilt JH and Nagtegaal ID: Advances in the care of patients with mucinous colorectal cancer. Nat Rev Clin Oncol 13: 361-369, 2016.
39. Luo C, Cen S, Ding G and Wu W: Mucinous colorectal adenocarcinoma: Clinical pathology and treatment options. Cancer Commun (Lond) 39: 13, 2019.
40. Siegel RL, Miller KD, Fuchs HE and Jemal A: Cancer statistics, 2021. CA Cancer J Clin 71: 7-33, 2021.
41. Chu LC, Goggins MG and Fishman EK: Diagnosis and detection of pancreatic cancer. Cancer J 23: 333-342, 2017.
42. Mizrahi JD, Surana R, Valle JW and Shroff RT: Pancreatic cancer. Lancet 395: 2008-2020, 2020.
43. Su L and Wernberg J: Synchronous distal pancreatic metastatic lesion arising from colonic adenocarcinoma: Case report and literature review. Clin Med Res 12: 166-170, 2014.
44. Conroy T, Castan F, Lopez A, Turpin A, Ben Abdelghani M, Wei AC, Mitry E, Biagi JJ, Evesque L, Artru P, *et al*: Five-year outcomes of FOLFIRINOX vs. gemcitabine as adjuvant therapy for pancreatic cancer: A randomized clinical trial. JAMA Oncol 8: 1571-1578, 2022.
45. Conroy T, Hammel P, Hebbar M, Ben Abdelghani M, Wei AC, Raoul JL, Choné L, Francois E, Artru P, Biagi JJ, *et al*: FOLFIRINOX or gemcitabine as adjuvant therapy for pancreatic cancer. N Engl J Med 379: 2395-2406, 2018.