SPANDIDOS PUBLICATIONS

ONCOLOGY LETTERS 26: 429, 2023

Mixed medullary-follicular thyroid carcinoma: A case report and literature review

YONGHUI WANG[1], DANDAN YIN[2], GUIFANG REN[3], ZHENGJIANG WANG[2] and FANHUA KONG[2]

Departments of [1]Thyroid and Breast Surgery, [2]Pathology and [3]Hospital Office, Weifang People's Hospital, Weifang, Shandong 261041, P.R. China

Received March 14, 2023; Accepted July 27, 2023

DOI: 10.3892/ol.2023.14015

Abstract. Papillary thyroid cancer (PTC) and medullary thyroid cancer (MTC) originate from follicular and neuroendocrine parafollicular C cells, respectively. PTC and MTC simultaneously exist in tumors containing both MTC and PTC features in a rare condition known as mixed medullary-follicular thyroid carcinoma (MMFTC). In the present study, a 60-year-old female presented with a small mass on the left side of the neck. Ultrasonography indicated a hyperechoic nodule measuring ~11.9x9.7 mm^2 in the left lobe of the thyroid gland. The preoperative calcitonin serum value was elevated and total thyroidectomy and bilateral central compartment lymph node dissection was performed. Histological and immunohistochemical analysis of the tumor demonstrated MMFTC. No metastasis was observed in lymph nodes isolated from the bilateral central compartment. Given the rarity of MMFTC, enhancing understanding and management of such tumors is crucial.

Introduction

Thyroid cancer is the most common endocrine malignancy and the fastest increasing cancer worldwide (1). Despite this, the mortality rate has increased only slightly and has ranged from 0.4 to 0.5 per 100,000 people per year since 1980 (1). Thyroid cancer is classified based on their cellular origin. Those that originate from follicular cells comprise follicular thyroid cancer, papillary thyroid cancer (PTC) and anaplastic thyroid cancer (1). Medullary thyroid cancer (MTC) develops from neuroendocrine parafollicular C cells (1). PTC accounts for ~85% of the total number of thyroid cancer cases (1). MTC is a rare type of cancer that accounts for ~4% of all thyroid cancer. MTC and PTC can coexist in thyroid tissues (2,3). Concomitant medullary and papillary thyroid carcinoma is divided into two forms. The first form includes ≥2 lesions in the same or different thyroid lobes, which indicates coexistence of MTC and PTC (2,3). However, PTC and MTC can also simultaneously exist in a mixed tumor containing features of both types of cancer named mixed medullary-follicular thyroid carcinoma (MMFTC) (4). To the best of our knowledge, MMFTC has rarely been reported.The present study reports a rare case of MMFTC and a literature review of MTC and PTC and MMFTC.

Case report

A 60-year-old female was referred to Weifang People's Hospital (Weifang, China) with a small mass on the left side of her neck in September 2020. The mass was discovered during a routine health examination 2 days prior. The patient had no history of radiation exposure or family history of any endocrine disease. Physical examination revealed a 2 cm, well-defined, non-tender nodule in the left thyroid lobe, which was moved with deglutition. The patient underwent Doppler ultrasound (US) and computed tomography (CT) examination. Ultrasonic examination was performed using a GE Logiq E9 color Doppler US system (GE Healthcare) equipped with a GE 3.5C convex array transducer probe with a frequency of 6-9 MHz. The patient was placed in a supine position with the neck fully exposed. The thyroid gland was scanned for transverse, longitudinal and oblique views. When a nodule was found, its size, morphology, parenchymal echo pattern and internal echo were analyzed. US examination of the neck indicated the presence of a hyperechoic nodule measuring ~11.9x9.7 mm^2 in the left lobe of the thyroid gland (Fig. 1A).

CT scanning was performed using the SOMATOM Definition Flash (Siemens Healthcare) with the patient in a supine position. The mandibular and shoulder positions were required to avoid the influence of clavicle artifacts. The patient was instructed to hold their breath and avoid swallowing to avoid breathing and swallowing artifacts. The scanning parameters were as follows: A tube voltage, 100 kV; reference current, 186 mAs; B tube voltage, Sn140 kV; reference current, 125 mAs; fusion coefficient, 0.5; pitch, 0.65; open CARE Dose 4D, Q30 (SAFIRE strength 3) and slice thickness/interval, 1.5/1.5 mm. Scanning was performed from the skull base to the thoracic entrance. CT images

Correspondence to: Dr Fanhua Kong, Department of Pathology, Weifang People's Hospital, 151 Guangwen Street, Weifang, Shandong 261042, P.R. China
E-mail: kongfanhua0708@126.com

Key words: medullary, follicular, papillary, thyroid cancer, case report

demonstrated a solid nodule ~10.5x7.7 mm^2 in size in the left thyroid lobe (Fig. 1B). US and CT examination indicated no abnormalities in the right thyroid lobe and isthmus.. The levels of serum calcitonin were elevated [143.20 pg/ml; normal levels (NL), 0.0-6.4 pg/ml], while carcinoembryonic antigen (CEA; <0.5 ng/ml; NL, 0-4.99 pg/ml), thyroid stimulating hormone (1.57 μg/ml; NL, 038-4.34 pg/ml), free thyroxine (19.45 pmol/l; NL, 10-22 pmol/l) and anti-thyroglobulin autoantibody serum levels (2.23 IU/ml; NL, <75 IU/ml) were in the expected ranges.

The case was discussed at the regional thyroid multidisciplinary team meeting and surgery was proposed. The patient underwent total thyroidectomy and bilateral central compartment lymph node dissection in October 2020. During gross examination, a poorly demarcated yellowish mass measuring 15.2x12.1 mm^2 was observed in the left lobe of the thyroid gland (Fig. 2A). Tissue specimens were fixed with 4% formalin at room temperature for 12 h, embedded in paraffin at 60˚C for 15 min, cut into 4-μm sections, stained for 5 min at room temperature with hematoxylin and eosin and observed under a light microscope (Nikon Corporation). Light microscopy images demonstrated a large tumor ~18.2 mm composed of two distinct parts that were joined (Fig. 2B). The cells in one component exhibited PTC pathology with nuclear clearing, grooving and occasional pseudoinclusion (Fig. 2B). The other component exhibited features consistent with MTC (2,3), such as irregular and solid nests of pleomorphic cells surrounded by a fibrovascular stroma with an abundance of acidophilic homogenous material, large and polygonal cells, prominent nucleoli and finely granular cytoplasm (Fig. 2B).

Immunohistochemical analysis of the tissue was performed. Tumor tissue was fixed with 4% neutral formalin at room temperature for 12 h, embedded in paraffin at 60˚C for 15 min, cut into 4-μm sections and sealed with 3% hydrogen peroxide at room temperature for 10 min. Antigen retrieval was performed with EDTA at 100˚C for 2.5 min followed by washing with PBS. Primary antibody incubation was performed at 37˚C for 60 min and secondary antibody incubation at 37˚C for 20 min. Anti-CEA was bought from Santa Cruz Biotechnology. The other primary antibodies were purchased from Beyotime Institute of Biotechnology. The following primary antibodies were used: Calcitonin (cat. no. AG8159; 1:100), CEA (sc-48364; 1:100), thyroid transcription factor 1 (TTF-1; cat. no. AG8751; 1:100) and thyroglobulin (TG; cat. no. AG3385; 1:100). Biotinylated Goat anti-Mouse and Rabbit secondary antibodies were obtained from OriGene Technologies, Inc. (cat. no. PV-6000; 1:500). Finally, tissue sections were stained with 3,3'-diaminobenzidine at room temperature for 5 min, counterstained with hematoxylin at room temperature for 5 min and imaged using a light microscope (Nikon Corporation). MTC cells were positive for calcitonin (Fig. 3A), CEA (Fig. 3B) and TTF-1 (Fig. 3C) but negative for TG (Fig. 3D). The PTC cells were negative for calcitonin (Fig. 3E) and CEA (Fig. 3F) but positive for TTF-1 (Fig. 3G) and TG (Fig. 3H). A final pathology diagnosis identified MMFTC in the thyroid gland.

No lymph node metastasis was detected in the 15 lymph node samples harvested from the bilateral central compartment lymph node.

Immediately following surgery, serum calcitonin levels decreased to 5.3 pg/ml. After 2 years of follow-up, the patient remained healthy with no symptoms of discomfort.

Literature review

MTC-PTC and MMFTC are rare thyroid tumor, and the reported incidence rate is <0.1/100,000 individuals/year (2,3), the data pertaining to this type of thyroid cancer are mainly acquired from case reports (2-6). The present review summarizes advances in the epidemiology, histology, molecular techniques, presentation and therapeutic strategies of MTC-PTC and MMFTC.

Epidemiology. The morbidity of thyroid cancer worldwide has increased by 300% over the past 30 years (1). PTC, which originates from follicular cells, accounts for ~85% of the total number of thyroid cancer cases (1). MTC, which develops from neuroendocrine parafollicular C cells, is a rare type of cancer that accounts for ~4% of all thyroid cancer (1). Concomitant medullary and papillary thyroid carcinoma is a rare phenomenon, which accounts for 2.7-12.3% of all medullary thyroid cancer and is divided into two forms. The first form includes ≥2 lesions in the same or different thyroid lobes, which indicates coexistence of MTC and PTC (2,3). The other form comprises a tumor with dual differentiation, known as MMFTC (4). The incidence of the two forms vary and over the past two decades the incidence of MTC-PTC has increased from 2.7% of all MTCs to 12.3% (2). This figure is consistent with that of a previous study that indicated that 19% of MTC cases displayed concurrent PTC (5). However, no case of MMFTC was reported in the aforementioned study (5). The increased incidence of simultaneous MTC-PTC may be due to enhanced resolution of medical imaging and its widespread application, in addition to careful pathological examinations diagnosing more thyroid abnormalities (2). Most patients with MTC-PTC are aged >45 years (median age 53.5±6.5 y), which is older than patients with MTC (median age 44.5±12.6 y) but younger than patients with PTC (median age 57.3±9.8 y) (1-3). MTC-PTC is more common in female patients, with previous studies reporting a ~2:1 female-to-male ratio (2,3,5). The risk factors for development of MTC-PTC have not been fully elucidated but may be similar to those of MTC or PTC, which include ionizing radiation exposure, sex, alcohol and tobacco use, obesity and previous family history (1,6).

Clinical presentation. The clinical presentation of MTC-PTC exhibits no additional symptoms compared with traditional MTC or PTC. Usually, a thyroid nodule or neck mass is the initial sign (6). Flushing or diarrhea accompanied by high levels of calcitonin may be present (6). However, if opportunistic screening is combined with high-resolution US, thyroid cancer can be observed in patients with a thyroid nodule, either as a single or multinodular goiter without other specific symptoms (1).

Ultrasonography is currently the most common method for detecting thyroid cancer and can detect ≥1 hyperechoic nodules with or without capsular invasion and microcalcification (7). Neither CT nor magnetic resonance imaging (MRI) can characterize thyroid nodules accurately, as these technologies cannot depict the fine architectural features that distinguish benign

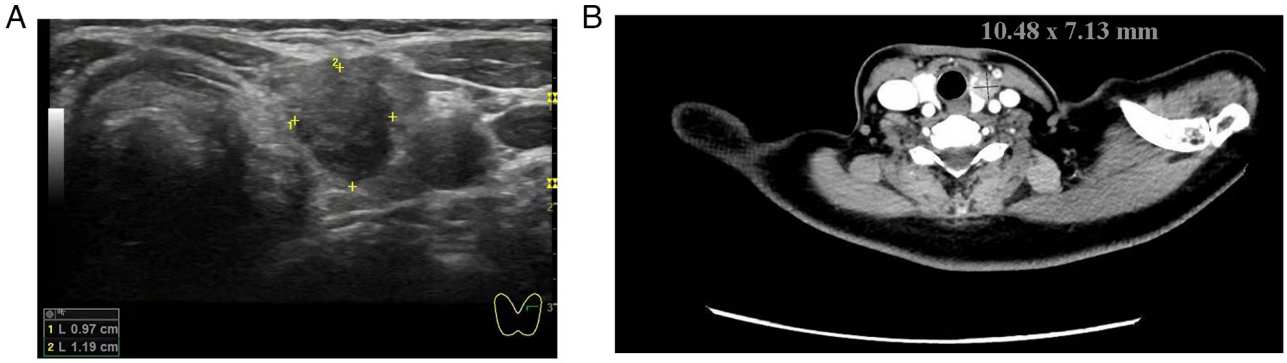

Figure 1. Ultrasonography and CT images of the thyroid nodule. (A) Ultrasonography revealed a hyperechoic nodule in the left lobe of the thyroid gland. (B) CT images demonstrated a solid nodule in the left lobe of the thyroid gland. CT, computed tomography.

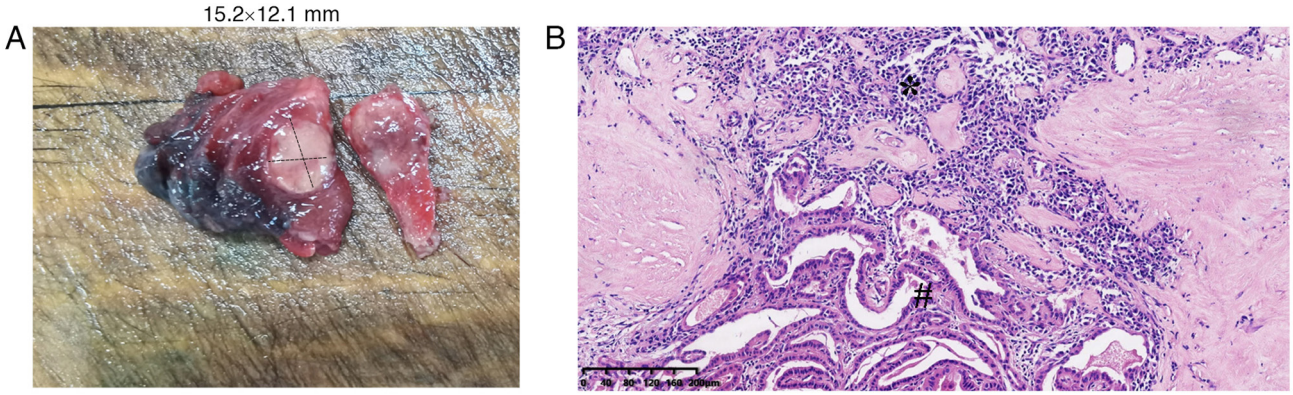

Figure 2. Gross and microscopic presentation of the lesion. (A) Tumor located in the left lobe of the thyroid gland was 15.2x12.1 mm. (B) Hematoxylin and eosin staining of the tumor demonstrated two types of cancer which were joined. Medullary thyroid cancer (*) was immediately adjacent to the papillary thyroid cancer (#). Magnification, x100.

and malignant nodules (8). However, CT and MRI can illustrate the association between thyroid tumors and surrounding tissues pertaining to organs, such as the trachea and esophagus (8).

Diagnosis. Owing to the two different types of cancer cells in MTC-PTC, the diagnosis of MTC-PTC or MMPTC should occur when tumors exhibit characteristics of both MTC and PTC. MTC-PTC in different lesions may be observed in surgery treatment for MTC or PTC (9). In this condition, MTC and PTC should be diagnosed (9). In addition, 8.3% of cases of MTC-PTC are reported to be familial MTC (10). Therefore, familial and sporadic MTC should be distinguished based on germline mutation of the RET protooncogene.

A cytological smear of MTC is characterized by isolated, oval or round, large polygonal or spindled cells. Although the MTC cytological pattern is generally typical, diagnosis of a high percentage of cases of MTC remains difficult (11). In ambiguous cases, elevated basal levels of serum calcitonin enable the diagnosis of MTC, especially at levels >100 pg/ml (11). For patients with calcitonin levels in the expected range, a diagnosis can be ascertained through the measurement of calcitonin in the washout fluid of the needle puncture derived from a suspected thyroid nodule (11,12). Serum CEA is an additional reliable MTC tumor marker and high CEA levels predict distant metastases (12). In a previous study using immunohistochemistry of calcitonin, CEA, synaptophysin and chromogranin A levels, positive results were obtained for TTF-1 and paired box 8 (PAX8), whereas those for TG were negative (13).

The cytological PTC specimen consists of cells arranged in papillae and/or monolayer sheets with a syncytial appearance (14). They exhibit intranuclear cytoplasmic pseudoinclusions, nuclear crowding, intranuclear grooves and pale nuclei with powdery chromatin (14). Immunohistochemistry of these sample types are positive for TTF-1, PAX8 and TG and negative for calcitonin, synaptophysin and chromogranin A (13).

For diagnosis of MMFC, MTC and PTC cells should be present in the same lesion (4). To the best of our knowledge, familial MTC has not yet been reported in this type of cancer. In previous microscopic analysis (15-17), the investigated tumor was composed of two different parts that were joined. Immunohistochemistry revealed that the PTC cells were positive for TG, whereas the MTC cells were positive for calcitonin (15-17).

Therapy. Given the presence of both MTC and PTC components, treatment strategy should consist of treatment methods for both types of cancer.

Surgical management. Owing to poor prognosis of MTC, surgery should be performed to manage this condition (2,3,5). Total or near total thyroidectomy is considered a standard

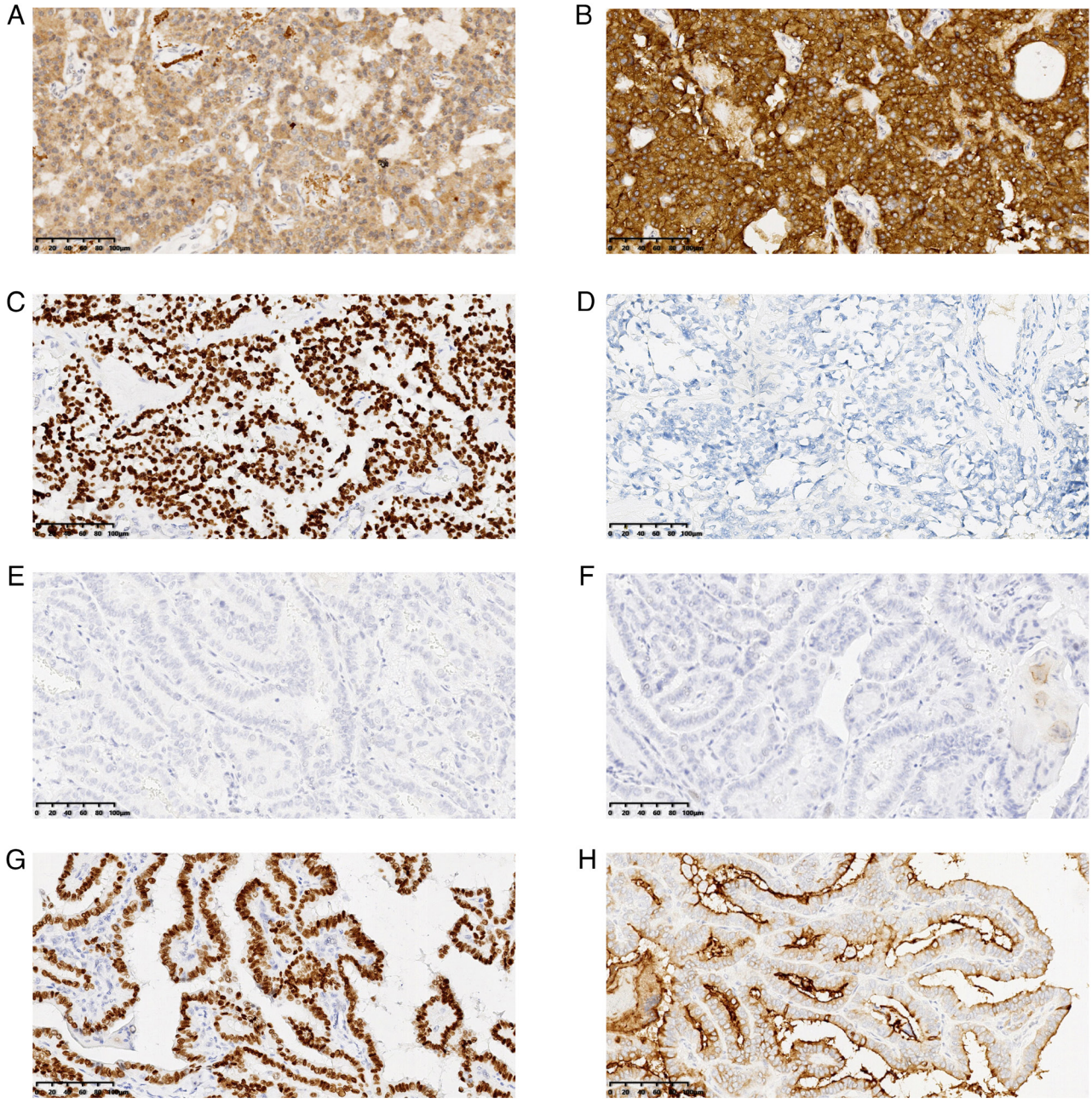

Figure 3. Immunohistochemical staining of the tumor. Immunohistochemical staining of MTC component of the tumor for (A) calcitonin, (B) CEA, (C) TTF-1 and (D) thyroglobulin. Immunohistochemical staining of PTC component of the tumor for (E) calcitonin, (F) CEA, (G) TTF-1 and (H) thyroglobulin. Magnification, x200. MTC, medullary thyroid cancer; PTC, papillary thyroid cancer; CEA, carcinoembryonic antigen; TFF-1, thyroid transcription factor 1.

treatment for MTC or PTC (2,3,5). The extent of lymph node dissection depends on levels of preoperative calcitonin. If the levels are <20 pg/ml, prophylactic central compartment lymph node dissection is inappropriate (2,3,5). Calcitonin values >20, 50, 200 and 500 pg/ml are associated with the presence of lymph node metastases in the ipsilateral central and lateral neck, contralateral central neck, contralateral lateral neck and upper mediastinum, respectively (18-20). Therefore, the corresponding range of lymph nodes should be dissected.

Radioactive iodine (RAI) therapy. RAI therapy is dependent on the sodium iodide symporter (NIS) principle of differentiating thyroid cancer cells that trap RAI, which facilitates remnant ablation, adjuvant therapy and treatment of known residual or recurrent disease (10).

Patients with PTC who have high-risk factors including tumor invading the normal tissue, are recommended to undergo RAI therapy (10). However, 10% of patients with PTC develop advanced disease, which can become resistant to RAI therapy (10). For reversal of the sensitivity of RAI therapy, several drugs, such as lithium carbonate and retinoic acid, have been utilized (10). Furthermore, various oncogenes, including RAS, BRAF and RET, enhance activation of the MAP kinase signaling pathway and subsequently inhibit expression of NIS (21). Therefore, the use of the MEK1 and MEK2 inhibitor selumetinib enhances RAI uptake and achieves therapeutic effects (22).

Hormone therapy. It has previously been recommended that hormone therapy using L-thyroxine should commence immediately following thyroidectomy (23). Given the enhancement of thyrotropin in the metastasis and proliferation of PTC, hormone suppressive therapy is conducted as per the PTC risk stratification (23).

Prognosis and follow-up. Previous studies have reported that the size of MTC-PTC tumors is significantly smaller compared with MTC tumors (2,3). The 10-year disease-free survival rate of MTC-PTC is 87%, which is notably higher than that of MTC which is ~50% (2). All deaths pertaining to MTC-PTC are reported to be due to MTC metastasis (24). Rigorous surveillance is required to detect early metastasis. For patients who undergo surgery, serum levels of TG, TG antibodies, calcitonin and CEA should be monitored 3 months after surgery (24). If basal TG, TG antibodies and calcitonin levels are undetectable, the patient can be considered in clinical remission with low risk of recurrence (10%) (24). The recurrence rate decreases to 3% if calcium stimulation test for calcitonin remains negative (25). Subsequently, patients can be followed up with neck US, TG serum, TG antibody, calcitonin and CEA testing and physical examination every 6 months (24,25). If calcitonin or TG is detectable, further tests should be based on levels of circulating calcitonin or TG (24,25). In the case of undetectable TG or calcitonin <150 pg/ml, residual cervical disease is the most likely hypothesis and cervical US should be performed. Furthermore, the TG serum (>10 pg/ml) or calcitonin (>150 pg/ml) levels indicate the presence of extra cervical metastases if total thyroidectomy has been performed (24,25). Therefore, other auxiliary examination methods, such as chest CT, liver MRI and bone scintigraphy should be performed (26).

Advanced disease treatment. If recurrent disease is limited to the neck, revision surgery is the most appropriate method of disease treatment and a biochemical cure is often attainable (27). However, in cases of extensive disease or distant metastasis, the disease may be incurable and systemic therapy must be administered. Biopsy should be performed, and MTC or PTC metastasis should be distinguished when feasible (28). For patients with locoregional disease, which is invasive of visceral structures, postoperative radiation therapy may be an effective treatment (28). Traditional cytotoxic drugs are reported to have no significant effect on either MTC or PTC. Regardless, targeted therapy has been used for advanced MTC and PTC in recent decades (28). The Food and Drug Administration (FDA) of the United States has approved multitargeted kinase inhibitors for advanced MTC (cabozantinib) and PTC (sorafenib and lenvatinib) (18). In addition, the FDA has approved two RET-specific inhibitors (selpercatinib and pralsetinib) for treatment of RET-mutant MTC (28).

Origin of MTC-PTC. The origin of MTC-PTC has not been well-demonstrated. The leading theories include the collision effect, stem cell and hostage theory. The hostage theory hypothesizes that carcinoma is attributable to adenomatous areas becoming sequestered by a different type of tumor (29). The stem cell theory hypothesizes that the tumor originates from the same stem cell and differentiates into two distinct types of carcinoma cells (30). The collision theory postulates that the tumor originates from different polyclonal neoplasms that manifest simultaneously (31). Notably, collision theory exhibits the highest rational robustness. In combination with the development of molecular diagnosis, Ciampi *et al* (32) reported that medullary tumors and PTC occurring simultaneously in the same gland show different oncogene mutations, including RET, BRAF and RAS. In addition, two population-level analyses reported that MTC-PTC likely represents a primary tumor with an incidental pathological finding of a second malignancy (2,5).

In conclusion, knowledge of this rare type of thyroid cancer and immunohistochemical markers are key to make a correct diagnosis., Owing to the coexistence of MTC and PTC, MTC-PTC or MMPTC should be treated based on its respective stage and currently available treatment guidelines. Owing to low morbidity of MTC-PTC or MMPTC and the availability of only retrospective data from case reports, extensive research is needed on the condition. First, the molecular mechanism underlying MTC-PTC or MMPTC development needs to be studied to identify novel signaling pathways. Novel target therapies may lead to high clinical effectiveness. To develop the most effective treatment strategy, prospective, randomized and double-blinded studies may be performed.

Acknowledgements

Not applicable.

Funding

No funding was received.

Availability of data and materials

The datasets used and/or analyzed during the current study are available from the corresponding author on reasonable request.

Authors' contributions

YW and FK conceived the study and confirm the authenticity of all the raw data. YW performed the surgery. DY, GR, ZW and FK collected and analyzed the data. YW and GR wrote the manuscript. GR and ZW revised the manuscript. All authors have read and approved the final manuscript.

Ethics approval and consent to participate

The present study was approved by the Ethics Committee of Weifang People's Hospital (Weifang, China; approval no. WF2023011302). The patient provided written consent to participate in the study.

Patient consent for publication

Written informed consent was given by the patient for publication of data and associated images.

Competing interests

The authors declare that they have no competing interests.

References

1. Fagin JA and Wells SA Jr: Biologic and clinical perspectives on thyroid cancer. N Engl J Med 375: 1054-1067, 2016.
2. Appetecchia M, Lauretta R, Barnabei A, Pieruzzi L, Terrenato I, Cavedon E, Mian C, Castagna MG, Elisei R and SIE (Italian Society of Endocrinology) Working Group: Epidemiology of simultaneous medullary and papillary thyroid carcinomas (MTC/PTC): An Italian multicenter study. Cancers (Basel) 11: 1516, 2019.
3. Wong RL, Kazaure HS, Roman SA and Sosa JA: Simultaneous medullary and differentiated thyroid cancer: A population-level analysis of an increasingly common entity. Ann Surg Oncol 19: 2635-2642, 2012.
4. Hales M, Rosenau W, Okerlund MD and Galante M: Carcinoma of the thyroid with a mixed medullary and follicular pattern: morphologic, immunohistochemical, and clinical laboratory studies. Cancer 50: 1352-1359, 1982.
5. Kim WG, Gong G, Kim EY, Kim TY, Hong SJ, Kim WB and Shong YK: Concurrent occurrence of medullary thyroid carcinoma and papillary thyroid carcinoma in the same thyroid should be considered as coincidental. Clin Endocrinol (Oxf) 72: 256-263, 2010.
6. Seib CD and Sosa JA: Evolving understanding of the epidemiology of thyroid cancer. Endocrinol Metab Clin North Am 48: 23-35, 2019.
7. Sharbidre KG, Lockhart ME and Tessler FN: Incidental thyroid nodules on imaging: Relevance and management. Radiol Clin North Am 59: 525-533, 2021.
8. Shetty SK, Maher MM, Hahn PF, Halpern EF and Aquino SL: Significance of incidental thyroid lesions detected on CT: Correlation among CT, sonography, and pathology. AJR Am J Roentgenol 187: 1349-1356, 2006.
9. Poller DN and Glaysher S: Molecular pathology and thyroid FNA. Cytopathology 28: 475-481, 2017.
10. Biscolla RP, Ugolini C, Sculli M, Bottici V, Castagna MG, Romei C, Cosci B, Molinaro E, Faviana P, Basolo F, *et al*: Medullary and papillary tumors are frequently associated in the same thyroid gland without evidence of reciprocal influence in their biologic behavior. Thyroid 14: 946-952, 2004.
11. Costante G and Filetti S: Early diagnosis of medullary thyroid carcinoma: Is systematic calcitonin screening appropriate in patients with nodular thyroid disease? Oncologist 16: 49-52, 2011.
12. Wells SA Jr, Asa SL, Dralle H, Elisei R, Evans DB, Gagel RF, Lee N, Machens A, Moley JF, Pacini F, *et al*: Revised American thyroid association guidelines for the management of medullary thyroid carcinoma. Thyroid 25: 567-610, 2015.
13. Filetti S, Durante C, Hartl D, Leboulleux S, Locati LD, Newbold K, Papotti MG, Berruti A and ESMO Guidelines Committee. Electronic address: Clinicalguidelines@esmo.org: Thyroid cancer: ESMO clinical practice guidelines for diagnosis, treatment and follow-up†. Ann Oncol 30: 1856-1883, 2019.
14. Vance J and Gilani SM: Thyroid cytopathology: updates and molecular testing. Pathologica 111: 51-57, 2019.
15. Gurkan E, Gurbuz Y, Tarkun I, Canturk Z and Cetinarslan B: Mixed medullary-papillary carcinoma of the thyroid: report of two cases and review of the literature. Indian J Pathol Microbiol 57: 598-602, 2014.
16. Jain M, Verma D, Thomas S and Chauhan R: Mixed medullary-papillary carcinoma thyroid: An uncommon variant of thyroid carcinoma. J Lab Physicians 6: 133-135, 2014.
17. Nangue C, Bron L, Portmann L, Volante M, Ris HB, Monnier P and Andrejevic-Blant S: Mixed medullary-papillary carcinoma of the thyroid: Report of a case and review of the literature. Head Neck 31: 968-974, 2009.
18. Araque KA, Gubbi S and Klubo-Gwiezdzinska J: Updates on the management of thyroid cancer. Horm Metab Res 52: 562-577, 2020.
19. Kim M and Kim BH: Current guidelines for management of medullary thyroid carcinoma. Endocrinol Metab (Seoul) 36: 514-524, 2021.
20. Viola D and Elisei R: Management of medullary thyroid cancer. Endocrinol Metab Clin North Am 48: 285-301, 2019.
21. Durante C, Puxeddu E, Ferretti E, Morisi R, Moretti S, Bruno R, Barbi F, Avenia N, Scipioni A, Verrienti A, *et al*: BRAF mutations in papillary thyroid carcinomas inhibit genes involved in iodine metabolism. J Clin Endocrinol Metab 92: 2840-2843, 2007.
22. Liu D, Hu S, Hou P, Jiang D, Condouris S and Xing M: Suppression of BRAF/MEK/MAP kinase pathway restores expression of iodide-metabolizing genes in thyroid cells expressing the V600E BRAF mutant. Clin Cancer Res 13: 1341-1349, 2007.
23. Stramazzo I, Capriello S, Antonelli A, Fallahi P, Centanni M and Virili C: Seeking optimization of LT4 treatment in patients with differentiated thyroid cancer. Hormones (Athens) 21: 537-543, 2022.
24. Pellegriti G, Leboulleux S, Baudin E, Bellon N, Scollo C, Travagli JP and Schlumberger M: Long-term outcome of medullary thyroid carcinoma in patients with normal postoperative medical imaging. Br J Cancer 88: 1537-1542, 2003.
25. Franc S, Niccoli-Sire P, Cohen R, Bardet S, Maes B, Murat A, Krivitzky A, Modigliani E and French Medullary Study Group (GETC): Complete surgical lymph node resection does not prevent authentic recurrences of medullary thyroid carcinoma. Clin Endocrinol (Oxf) 55: 403-409, 2001.
26. Giraudet AL, Vanel D, Leboulleux S, Aupérin A, Dromain C, Chami L, Ny Tovo N, Lumbroso J, Lassau N, Bonniaud G, *et al*: Imaging medullary thyroid carcinoma with persistent elevated calcitonin levels. J Clin Endocrinol Metab 92: 4185-4190, 2007.
27. Machens A, Lorenz K and Dralle H: Prediction of biochemical cure in patients with medullary thyroid cancer. Br J Surg 107: 695-704, 2020.
28. Walgama E, Busaidy N and Zafereo M: Novel therapeutics and treatment strategies for medullary thyroid cancer. Endocrinol Metab Clin North Am 51: 379-389, 2022.
29. Bangaraiahgari R, Panchangam RB, Puthenveetil P, Mayilvaganan S, Bangaraiahgari R, Banala RR, Karunakaran P and Md R: Is there adenoma-carcinoma sequence between benign adenoma and papillary cancer of thyroid: A genomic linkage study. Ann Med Surg (Lond) 60: 695-700, 2020.
30. Yoo MH and Hatfield DL: The cancer stem cell theory: Is it correct? Mol Cells 26: 514-516, 2008.
31. Pishdad R, Cespedes L, Boutin R, Jaloudi M and Raghuwanshi M: Coexistence of two different thyroid malignancies: A collision phenomenon. Cureus 12: e7539, 2020.
32. Ciampi R, Romei C, Pieruzzi L, Tacito A, Molinaro E, Agate L, Bottici V, Casella F, Ugolini C, Materazzi G, *et al*: Classical point mutations of RET, BRAF and RAS oncogenes are not shared in papillary and medullary thyroid cancer occurring simultaneously in the same gland. J Endocrinol Invest 40: 55-62, 2017.