SPANDIDOS PUBLICATIONS

ONCOLOGY LETTERS 26: 536, 2023

Recurrence of scalp angiosarcoma after multiple surgeries: A case report and literature review

DONGJIAN LI[1,2], ZHIGUO SUN[3], LING MA[2] and SHAOHUA LIU[4,5]

[1]Department of Clinical Medicine, Cheeloo College of Medicine, Shandong University; [2]Department of Plastic and Burn Surgery, Qilu Hospital of Shandong University, Jinan, Shandong 250012; [3]Department of Clinical Medicine, Yanggu County Central Hospital, Liaocheng, Shandong 252300; [4]Department of Oral and Maxillofacial Surgery, Qilu Hospital of Shandong University; [5]Institute of Stomatology, Shandong University, Jinan, Shandong 250012, P.R. China

Received June 29, 2023; Accepted September 21, 2023

DOI: 10.3892/ol.2023.14122

Abstract. Scalp angiosarcoma (SA) is rare, accounting for <1% of soft tissue sarcomas, with a high degree of malignancy, a high recurrence rate and a poor prognosis. The best treatment strategy is uncertain. Therefore, it is essential to continuously refine treatment strategies and improve the prognosis of patients. Curative-intent surgery increases overall survival in patients with primary cutaneous angiosarcoma of the scalp and face, and radiation therapy combined with chemotherapy is now recommended for the curative treatment of patients who both can or cannot undergo surgery. The present case report is of an 87-year-old man hospitalised for the fifth time with SA. He had experienced four recurrences and previously underwent curative-intent surgery four times. However, the patient did not undergo radiotherapy or chemotherapy after any of the surgeries. A detailed report of the management of this case is presented along with a review of the relevant literature. It is hypothesised that patients with SA should receive a combination of radiotherapy and chemotherapy after surgery whenever possible, which may improve patient prognosis.

Introduction

Angiosarcomas usually occur on the scalp and upper forehead (1), with scalp angiosarcoma (SA) accounting for ~50% of all angiosarcoma cases (2). A history of radiation and chronic lymphoedema are established risk factors for the disease, while being immunocompromised, and the presence of arteriovenous fistulae and xeroderma pigmentosum are potential risk factors for the disease (3). Angiosarcomas that occur on the scalp and face are more likely to recur, and treatment of angiosarcomas in these areas is difficult (4). The prognosis for angiosarcoma of the head and neck is poor, with a reported 5-year survival rate of 11-53% (5). Treatment options for angiosarcoma include curative-intent surgery, radiotherapy and chemotherapy (6). Curative-intent surgery has been reported to contribute to overall survival in patients with primary angiosarcomas of the scalp and face (5). For angiosarcoma with distant metastases, cytotoxic chemotherapy is the mainstay of treatment (6). However, the best treatment strategy remains uncertain.

The present study reports the case of a patient with multiple postoperative SA recurrences. On each occasion, the patient was treated using curative-intent surgery alone; however, the prognosis was poor.

Case report

Patient. The present study reports the case of an 87-year-old man hospitalized for the fifth time with SA. The patient had suffered multiple lacunar infarctions and gout for >3 and >5 years, respectively. The patient had experienced four previous recurrences of SA and underwent curative-intent surgery four times (Table I). Each time angiosarcoma recurred, the patient underwent curative-intent surgery with negative pathological margins. No radiotherapy or chemotherapy was administered after the surgeries. The fifth recurrence was in September 2022, when a dark red mass measuring ~1.5x1.0 cm appeared on the scalp, which gradually increased in size and became more numerous; ulcers also developed. The lesion was painful which was relieved with oral painkillers. On physical examination, an irregularly shaped mass measuring ~14.0x7.0 cm was identified, with most of the surface of the mass broken and bleeding (Fig. 1A). Cranial computed tomography demonstrated an irregular soft tissue mass with uneven density in the frontal region; no invasive damage to the skull was demonstrated (Fig. 1B). The postoperative pathological diagnosis of the fourth recurrence was angiosarcoma (Fig. 2A). Immunohistochemically, the tumour cells were positive for CD31, CD34 and D2-40, with a Ki-67 focal positivity

Correspondence to: Dr Ling Ma, Department of Plastic and Burn Surgery, Qilu Hospital of Shandong University, 107 West Wenhua Road, Jinan, Shandong 250012, P.R. China
E-mail: 18560085376@163.com

Dr Shaohua Liu, Department of Oral and Maxillofacial Surgery, Qilu Hospital of Shandong University, 107 West Wenhua Road, Jinan, Shandong 250012, P.R. China
E-mail: lshabccba@126.com

Key words: angiosarcoma, tumour recurrence, surgical treatment, prognosis, radiotherapy, chemotherapy

rate of ~30%. The patient was diagnosed with recurrent SA. Considering the patient's poor condition, curative-intent surgery was performed in a single stage (Fig. 1C), followed by postoperative flap grafting and skin grafting twice, 7 days (Fig. 1D) and 14 days later. The wound had healed well 7 days after the second postoperative flap and skin grafting was performed (Fig. 1E). Postoperative recovery was fair, and the patient was discharged. The post-operative pathological diagnosis was angiosarcoma (Fig. 2B).

The cells were positive for CD31 (Fig. 3A), CD34 (Fig. 3B), D2-40, Vimentin (Fig. 3C) and ETS-related gene (ERG) (Fig. 3D), with a Ki-67 (Fig. 3E) focal positivity rate of ~50%, as observed by light microscopy. Hematoxylin and eosin staining was also performed.

At 20 days after surgery, some of the tissue at the edges of the surgical area became necrotic (Fig. 1F) and the necrotic area progressively increased. At 4 months subsequent to this, the patient died of multiple organ failure.

Tissue analysis. Immunohistochemical staining was performed by the Department of Pathology using formalin-fixed (0.4% neutral formalin for 12 h), paraffin-embedded tissues at a 3- to 4-μm thickness. Antigen retrieval was performed using a stainless steel pan at ~110˚C. PBS was used as the washing reagent. Rehydration was performed in a descending alcohol series diluted with double-distilled water. Hydrogen peroxide (3%) was used to block endogenous peroxidase/phosphatase activity. Incubation for was performed with the following primary antibodies: CD31 (cat. no. ZM-0044; OriGene Technologies, Inc.; 37˚C; 60 min), CD34 (cat. no. ZM-0046; OriGene Technologies, Inc.; 37˚C; 60 min), ERG (cat. no. ZM-0103; OriGene Technologies, Inc.; 37˚C; 60 min), D2-40 (cat. no. MAB-0567; Fuzhou Maixin Biotech. Co., Ltd.; room temperature; 60 min), Ki-67 (cat. no. 05278384001; Roche Diagnostics; 37˚C; 16 min) and vimentin (cat. no. 05278139001; Roche Diagnostics; 37˚C; 16 min) (all ready-to-use). Secondary antibody incubation was performed using the contents of the PV-8000D (OriGene Technologies, Inc.) and 05269806001 (Roche Diagnostics) kits at room temperature for 20 and 10 min, respectively. Hematoxylin staining solution was applied for 30 sec at room temperature for counterstaining.

HE staining was performed by the Department of Pathology using formalin-fixed (0.4% neutral formalin for 12 h), paraffin-embedded tissues at a 3- to 4-μm thickness. Samples were heated to 80˚C for 10 min. The waxes were dissolved by placing the paraffin sections in a deparaffinising agent (xylene for 3 min, three times). An appropriate dewatering solution (in a descending alcohol series diluted with double-distilled water) was used for deparaffinisation. Hematoxylin staining was performed for 5 min. The sections were acid-washed in acidic alcohol to remove excess hematoxylin dye (1% hydrochloric alcohol for 13 sec and 95% ethanol CH_3CH_2OH for 30 sec). Eosin staining was performed for 1 min.

Discussion

SA is rare, accounting for <1% of soft tissue sarcomas (7) and its prognosis is poor. The prognostic factors for SA are related to tumour diameter, infiltration depth, margin status, recurrence and metastasis (8).

The most reliable treatment strategy for SA is surgery (9-13) and patients can undergo surgical excision which can improve their survival (7). Curative-intent surgery is associated with increased overall survival in patients with primary cutaneous angiosarcomas of the scalp and face (5). Reports in the literature state that the 1- and 5-year survival rates for patients who did not undergo definitive surgery were 68.0 and 18.0%, respectively, compared with 78.2 and 34.1% for those who underwent surgery; however, there remains a risk of local tumour recurrence after surgical resection (11,14-16). The combination of radiotherapy and chemotherapy can deliver better results than any single regimen (17).

In addition to surgery, radiotherapy and chemotherapy can improve a patient's condition. Radiotherapy serves a significant role in controlling tumour growth, reducing exudation, and preventing rupture. Radiotherapy can also improve the efficacy of treatment for patients with SA (18). Two patients have been reported to have been cured by radiotherapy alone (19,20). Patel and Speer (19) reported that a patient received radiotherapy as a single modality treatment that resulted in complete remission of an angiosarcoma of the face. Gkalpakiotis *et al* (20) reported that an elderly patient was cured of angiosarcoma by undergoing radiotherapy and had no recurrence in the long term. Sorrentino *et al* (21) reported that postoperative radiotherapy improved the prognosis of patients with SA. Ohguri *et al* (22) reported that radiotherapy combined with recombinant interleukin 2 is a highly effective and efficient method for treating SA. However, recurrence and distant metastases may still occur after radiotherapy (23). Cheng *et al* (24) reported the case of a 77-year-old patient who developed recurrence and distant metastases after receiving postoperative adjuvant radiotherapy. The patient later received intravenous paclitaxel, which markedly improved their condition (24). Chemotherapy has been recommended for patients who are ineligible for surgical tumour removal or those who experience recurrence or distant metastases after treatment (11,25). Paclitaxel, an effective agent for angiosarcoma treatment, may prolong survival by reducing the rate of distant failure after radiotherapy (26). Penel *et al* (27) and Fujisawa *et al* (28) performed a phase II clinical trial and retrospective study, respectively, and reported that the prognosis of paclitaxel combined with radiotherapy was better than that of conventional surgery combined with radiotherapy, and paclitaxel combined with radiotherapy was better than radiotherapy alone. Therefore, radiation therapy combined with chemotherapy is now recommended for the curative treatment of patients who can or cannot undergo surgery (29). However, postoperative patients should be monitored for bone marrow suppression as one of the possible side effects of chemotherapy (30). Moreover, appropriate indications for adjuvant chemotherapy should be further elucidated to reduce potential toxicity issues and issues with tolerance to taxane-based regimens (6).

In addition to radiotherapy and chemotherapy, targeted therapy can also be used to treat angiosarcoma. Ji *et al* (6) reported the case of advanced angiosarcoma successfully treated with apatinib, an oral tyrosine kinase inhibitor targeting the intracellular domain of vascular endothelial growth factor

Table I. Times of tumour discovery and treatment.

	Disease occurrence				
Action	1st	2nd	3rd	4th	5th
Discovery of tumour	November 2019	July 2020	January 2021	April 2021	September 2022
Treatment	December 2019	September 2020	February 2021	August 2021	November 2022

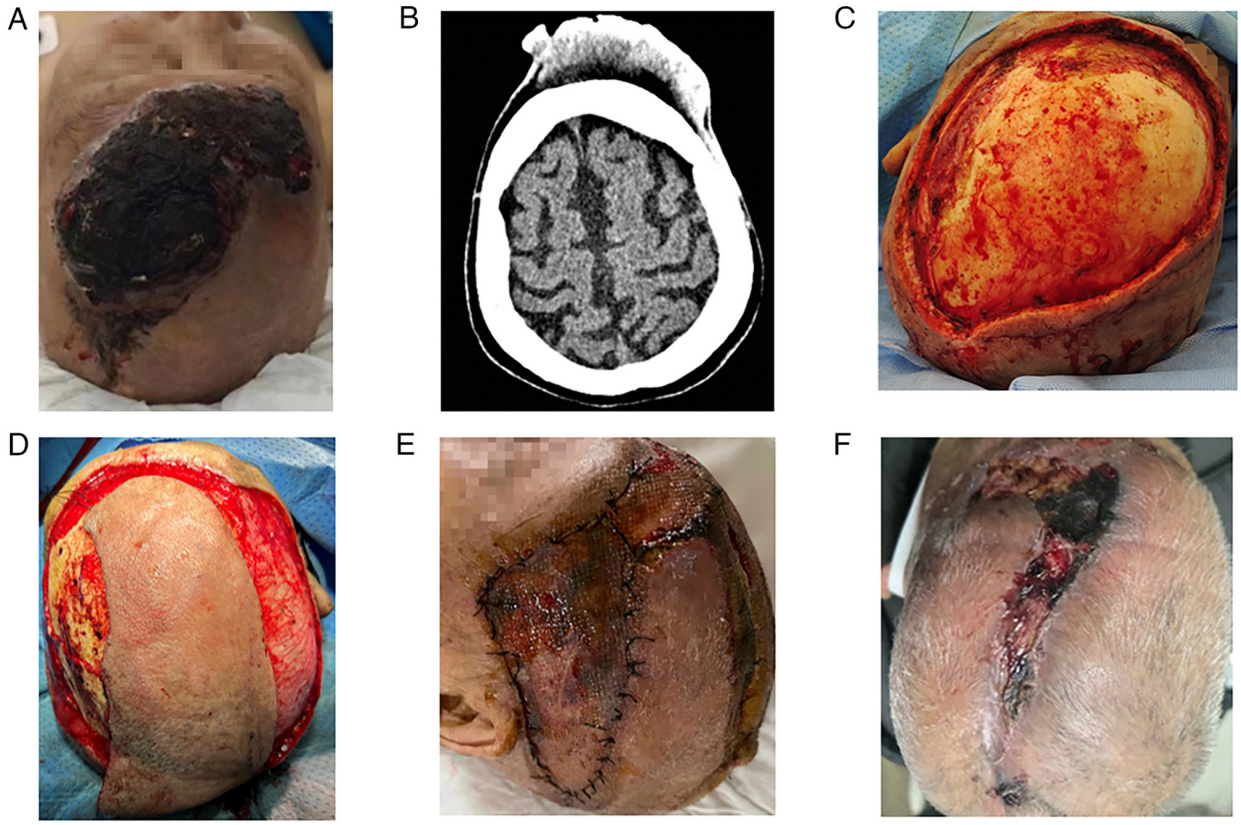

Figure 1. Clinical information of the patient. (A) On physical examination an irregularly shaped mass measuring ~14.0x7.0 cm was identified, most of the surface of the mass was broken and bleeding. (B) Cranial computed tomography demonstrated an irregular soft tissue mass of uneven density in the frontal region. (C) Following curative-intent surgery. (D) Intraoperative image of the first postoperative flap grafting and skin grafting. (E) Seven days after the second postoperative flap grafting and skin grafting. (F) Twenty days after surgery, some of the tissue at the edges of the surgical area had become necrotic.

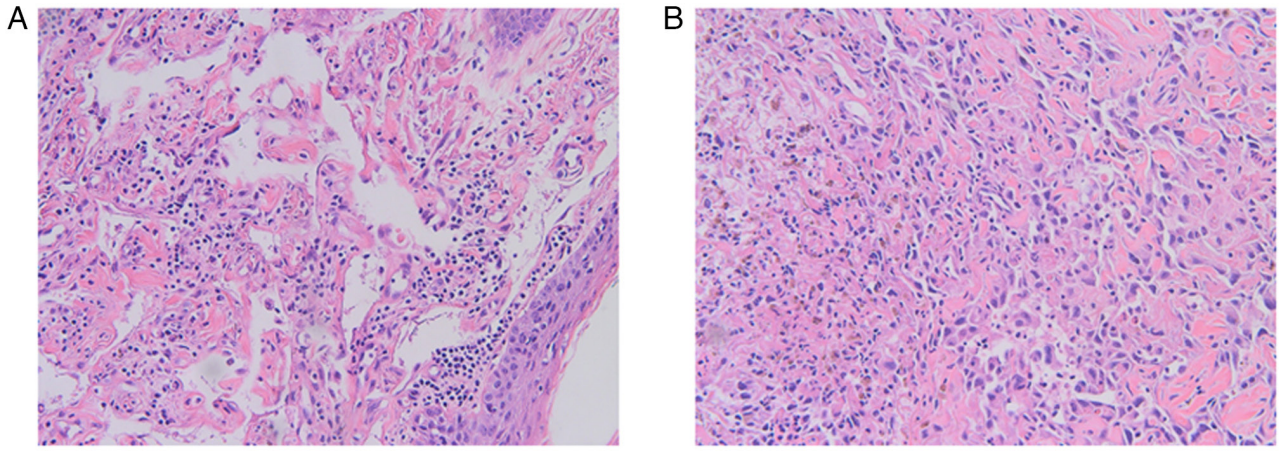

Figure 2. Pathological diagnosis of angiosarcoma. The cells stained with haematoxylin and eosin were heterogeneous and showed infiltrative growth consistent with angiosarcoma (magnification, x200). (A) Postoperative pathology following the fourth recurrence. (B) Postoperative pathology following the fifth recurrence.

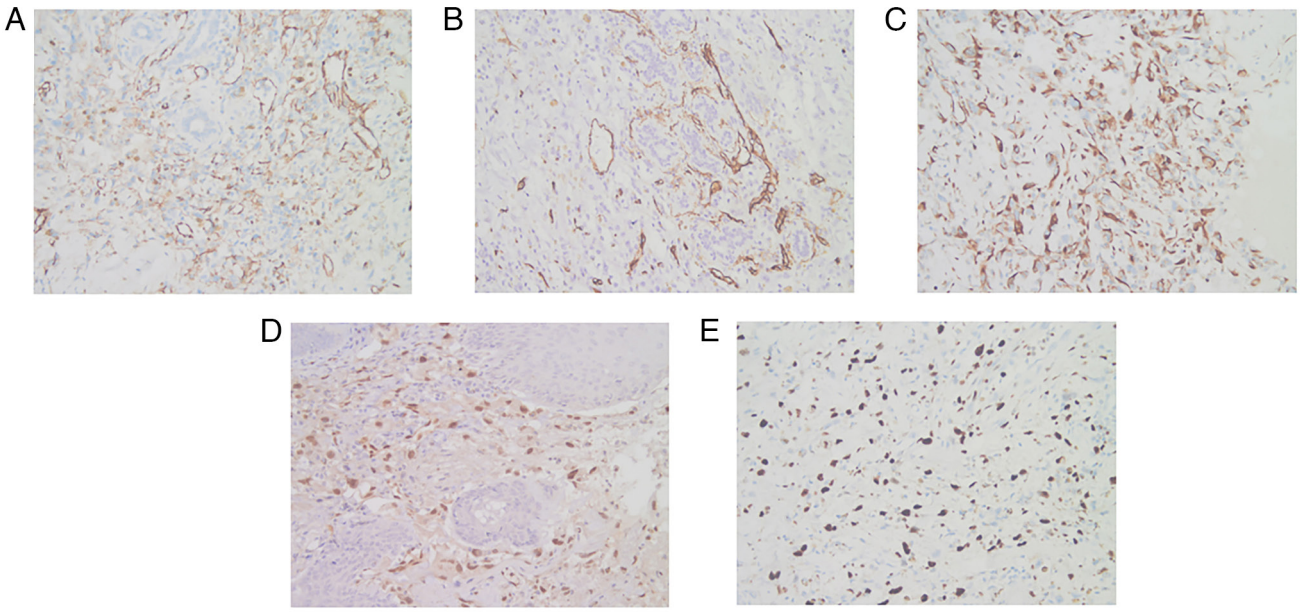

Figure 3. Immunohistochemical staining. (A) CD31, (B) CD34, (C) vimentin, (D) ETS-related gene and (E) Ki-67 staining (magnification, x200).

receptor-2. This suggested that apatinib had fewer toxic effects than traditional cytotoxic chemotherapy, making it a potential alternative for angiosarcoma treatment, particularly in elderly patients (6).

In the present case, given the patient's age and poor condition, radiotherapy or chemotherapy was not performed after each surgery. It was hypothesised however, that such patients should receive a combination of radiotherapy and chemotherapy after surgery whenever possible, which may improve their prognosis. However, this view has certain limitations and should be assessed by further studies with larger sample sizes which consider the risks that radiotherapy may pose to patients.

Acknowledgements

Not applicable.

Funding

No funding was received.

Availability of data and materials

All data generated or analyzed during this study are included in this published article.

Author's contributions

LM and SL researched the literature, studied the clinical cases and revised the manuscript. DL researched the clinical case, participated in the treatment of the patient and wrote the first draft of the manuscript. ZS researched the clinical case and participated in the treatment of the patient. All authors reviewed and edited the manuscript, and read approved the final manuscript. LM and ZS confirm the authenticity of all the raw data.

Ethics approval and consent to participate

Not applicable.

Patient consent for publication

Consent for publication was obtained from the patient's legal guardians as the patient had passed away at the time of writing.

Competing interests

The authors declare that they have no competing interests.

References

1. Nakamura Y, Nakamura Y, Hori E, Furuta J, Kawachi Y and Otsuka F: Complete long-term response of angiosarcoma of the scalp with cervical lymph node metastases treated with a combination of weekly and monthly docetaxel. Br J Dermatol 163: 1357-1358, 2010.
2. Almogy G, Lieberman S, Gips M, Pappo O, Edden Y, Jurim O, Simon Slasky B, Uzieli B and Eid A: Clinical outcomes of surgical resections for primary liver sarcoma in adults: Results from a single centre. Eur J Surg Oncol 30: 421-427, 2004.
3. Sturm EC, Marasco IS and Katz SC: Multidisciplinary management of Angiosarcoma-A review. J Surg Res 257: 213-220, 2021.
4. Maddox JC and Evans HL: Angiosarcoma of skin and soft tissue: A study of forty-four cases. Cancer 48: 1907-1921, 1981.
5. Oashi K, Namikawa K, Tsutsumida A, Takahashi A, Itami J, Igaki H, Inaba K and Yamazaki N: Surgery with curative intent is associated with prolonged survival in patients with cutaneous angiosarcoma of the scalp and face-a retrospective study of 38 untreated cases in the Japanese population. Eur J Surg Oncol 44: 823-829, 2018.
6. Ji G, Hong L and Yang P: Successful treatment of angiosarcoma of the scalp with apatinib: A case report. Onco Targets Ther 9: 4989-4992, 2016.
7. Cassidy RJ, Switchenko JM, Yushak ML, Madden N, Khan MK, Monson DK, Beitler JJ, Landry JC, Godette KD, Gillespie TW and Patel KR: The importance of surgery in scalp angiosarcomas. Surg Oncol 27: A3-A8, 2018.
8. Morgan MB, Swann M, Somach S, Eng W and Smoller B: Cutaneous angiosarcoma: A case series with prognostic correlation. J Am Acad Dermatol 50: 867-874, 2004.

9. Young RJ, Brown NJ, Reed MW, Hughes D and Woll PJ: Angiosarcoma. Lancet Oncol 11: 983-991, 2010.
10. Mendenhall WM, Mendenhall CM, Werning JW, Reith JD and Mendenhall NP: Cutaneous angiosarcoma. Am J Clin Oncol 29: 524-528, 2006.
11. Patel SH, Hayden RE, Hinni ML, Wong WW, Foote RL, Milani S, Wu Q, Ko SJ and Halyard MY: Angiosarcoma of the scalp and face: The Mayo Clinic experience. JAMA Otolaryngol Head Neck Surg 141: 335-340, 2015.
12. Pawlik TM, Paulino AF, McGinn CJ, Baker LH, Cohen DS, Morris JS, Rees R and Sondak VK: Cutaneous angiosarcoma of the scalp: A multidisciplinary approach. Cancer 98: 1716-1726, 2003.
13. NCCN Clinical Practice Guidelines in Oncology. Soft tissue sarcoma version 2. 2017. https://www.nccn.org/professionals/physician_gls/PDF/sarcoma.pdf. Accessed in December 5, 2017.
14. Köhler HF, Neves RI, Brechtbühl ER, Mattos Granja NV, Ikeda MK and Kowalski LP: Cutaneous angiosarcoma of the head and neck: Report of 23 cases from a single institution. Otolaryngol Head Neck Surg 139: 519-524, 2008.
15. Buschmann A, Lehnhardt M, Toman N, Preiler P, Salakdeh MS and Muehlberger T: Surgical treatment of angiosarcoma of the scalp: Less is more. Ann Plast Surg 61: 399-403, 2008.
16. Guadagnolo BA, Zagars GK, Araujo D, Ravi V, Shellenberger TD and Sturgis EM: Outcomes after definitive treatment for cutaneous angiosarcoma of the face and scalp. Head Neck 33: 661-667, 2011.
17. Hwang K, Kim MY and Lee SH: Recommendations for therapeutic decisions of angiosarcoma of the scalp and face. J Craniofac Surg 26: e253-e256, 2015.
18. Hata M: Radiation Therapy for angiosarcoma of the scalp: Total scalp irradiation and local irradiation. Anticancer Res 38: 1247-1253, 2018.
19. Patel VB and Speer TW: Successful treatment of an angiosarcoma of the nose with radiation therapy. Case Rep Oncol 5: 570-575, 2012.
20. Gkalpakiotis S, Arenberger P, Vohradnikova O and Arenbergerova M: Successful radiotherapy of facial angiosarcoma. Int J Dermatol 47: 1190-1192, 2008.
21. Sorrentino R, Vitiello R and Castelli ML: Angiosarcoma of the larynx. Case report and review of the literature. Acta Otorhinolaryngol Ital 23: 191-193, 2003
22. Ohguri T, Imada H, Nomoto S, Yahara K, Hisaoka M, Hashimoto H, Tokura Y, Nakamura K, Shioyama Y, Honda H, *et al*: Angiosarcoma of the scalp treated with curative radiotherapy plus recombinant interleukin-2 immunotherapy. Int J Radiat Oncol Biol Phys 61: 1446-1453, 2005.
23. Mendenhall WM, Mendenhall CM, Werning JW, Reith JD and Mendenhall NP: Cutaneous angiosarcoma. Cancer 44: 524-528, 2006.
24. Cheng YS, Chen TM, Tsai WC and Huang TW: Pulmonary metastatic angiosarcoma from scalp with fatal complication: A case report. Int J Surg Case Rep 34: 36-39, 2017.
25. Bhatti Z, Bhatti R, Brangman S, Whiting K and Dhamoon A: Extensive cutaneous scalp angiosarcoma. Case Rep Dermatol Med 2018: 8409820, 2018.
26. Donghi D, Dummer R and Cozzio A: Complete remission in a patient with multifocal metastatic cutaneous angiosarcoma with a combination of paclitaxel and sorafenib. Br J Dermatol 162: 697-699, 2010.
27. Penel N, Bui BN, Bay JO, Cupissol D, Ray-Coquard I, Piperno-Neumann S, Kerbrat P, Fournier C, Taieb S, Jimenez M, *et al*: Phase II trial of weekly paclitaxel for unresectable angiosarcoma: The ANGIOTAX Study. J Clin Oncol 26:5269-5274, 2008.
28. Fujisawa Y, Ito M, Mori K, Okada S, Nakamura Y, Kawachi Y and Otsuka F: Intra-arterial mitoxantrone/paclitaxel in angiosarcoma of the lower limb associated with chronic lymphedema (Stewart-Treves syndrome) in a patient with cervical cancer. Eur J Dermatol 21: 119-120, 2011.
29. Lee KT, Moon J, Jeong HS, Lim HS and Lim SY: Benefits of the multidisciplinary approach after curative surgery for the treatment of scalp angiosarcoma. Ann Plast Surg 86: 39-45, 2021.
30. Yang P, Zhu Q and Jiang F: Combination therapy for scalp angiosarcoma using bevacizumab and chemotherapy: A case report and review of literature. Chin J Cancer Res 25: 358-361, 2013.