SPANDIDOS PUBLICATIONS

ONCOLOGY LETTERS 27: 9, 2024

# Clinicopathological and molecular pathological characteristics in tamoxifen-related endometrial cancer

HARUMI SAEKI[1,2], YOSHIYA HORIMOTO[1,3], MAY THINZAR HLAING[3], YUAN MEN[2], LU RONG[2], YUMIKO ISHIZUKA[3], TOSHITAKA UOMORI[3], EMIKO YOSHIDA[4], YASUHISA TERAO[4], ATSUSHI ARAKAWA[1], TSUYOSHI SAITO[1,2] and TAKASHI YAO[1,2]

[1]Department of Human Pathology, Juntendo University Faculty of Medicine; [2]Department of Human Pathology, Juntendo University Graduate School of Medicine; Departments of [3]Breast Oncology, and [4]Obstetrics and Gynecology, Juntendo University Faculty of Medicine, Tokyo 113-0033, Japan

Received July 8, 2023; Accepted September 21, 2023

DOI: 10.3892/ol.2023.14142

**Abstract.** Tamoxifen (TAM), a selective estrogen receptor modulator, is often used for long-term adjuvant endocrine therapy in patients with hormone receptor-positive breast cancer. TAM is known to increase the risk of endometrial cancer (EC); however, the mechanism has not yet been fully elucidated. Therefore, molecular genetic analysis of EC following TAM administration (TAM-related EC) was conducted. A total of 10 samples of TAM-related EC and 20 sporadic EC samples (as controls) were analyzed. Copy number variation analysis was conducted, microsatellite instability (MSI) status was assessed, and mismatch repair (MMR) protein expression was examined immunohistochemically. Copy number variation analysis revealed that *KDR*, *NOTCH1*, *NTRK1*, *NTRK3* and *PDGFRB* were more frequently amplified in TAM-related EC (P=0.039, P<0.001, P=0.011, P=0.006 and P=0.035, respectively). In MSI analysis, 4 cases were classified as MSI-high (40%), which is a higher frequency compared with that among patients with sporadic EC (~10% in Japanese women). Loss of MMR proteins was confirmed in all MSI-high cases. In 1 MSI-high case, a benign lesion of hyperplasia prior to EC development was also MSI-high with loss of some MMR protein expression. Several genes were specifically amplified in TAM-related ECs. Furthermore, TAM-related ECs were frequently MSI-high. Further studies are required to be conclusive; however, the present findings may lead to a reduction of unnecessary gynaecological testing in clinical practice and also encourage the testing for MSI status for optimal individualized treatment.

*Correspondence to:* Dr Yoshiya Horimoto, Department of Breast Oncology, Juntendo University Faculty of Medicine, 2-1-1 Hongo, Bunkyo-ku, Tokyo 113-0033, Japan
E-mail: horimoto@juntendo.ac.jp

*Key words:* endometrial cancer, breast cancer, tamoxifen, microsatellite instability, copy number variation, receptor protein-tyrosine kinases

## Introduction

Recently, based on the results of genomic analysis, endometrial cancer (EC) has been classified into four groups molecular-pathologically: polymerase epsilon (*POLE*)-ultra-mutated, microsatellite instability (MSI)-hypermutated, copy-number-low (CN-L), and copy-number-high (CN-H) groups. *POLE*-ultra-mutated tumors have the best outcome, while CN-H tumors have the poorest outcome (1). Endometrioid carcinoma has been categorized into the CN-L group, and serous carcinoma and high-grade EC with *TP53* mutation are frequently included in CN-H group (1). The MSI-hypermutated tumors appear associated with methylation of the MLH1 promoter, and the prognosis of this type of tumor is moderate, between *POLE*-ultra-mutated tumors and CN-H tumors (1). We recently reported that the rate of MSI-H in sporadic EC was approximately 10% in Japanese women, apparently lower than that in Western countries (2). Nevertheless, this classification has not been applied in clinical practice, as, to date, there is no immunohistochemistry (IHC) which can substitute for molecular testing.

Patients with hormone receptor (HR)-positive early breast cancer, which accounts for nearly 80% of all breast cancer cases, are recommended to receive adjuvant endocrine therapy after curative surgery (3). Tamoxifen (TAM), a selective ER modulator, is one of the major endocrine therapies along with aromatase inhibitors, but known to sometimes be a cause of EC (TAM-related EC), although infrequently (4-6). The partial agonist action of TAM promotes epithelial proliferation via the ER and might be involved in EC development (7). However, the detailed mechanism has not been fully elucidated, despite this disease having been recognized for a considerable time and numerous studies having been conducted. A study employing the Surveillance Epidemiology and End Results (SEER) data indicated that TAM was not associated with poor-prognosis disease (8), but patients taking TAM have to frequently visit gynecologists for screening and are forced to undergo invasive examinations periodically, such as cytology of the endometrium. Furthermore, based on the results of large clinical trials, the recommended duration of TAM has been extended from five years to 10 years (9). Moreover, recent

advances in chemo-regimens have reduced the recurrence rate of breast cancer, thus the number of patients who complete adjuvant TAM treatment has been increasing. It is likely that the number of patients who will develop TAM-related EC will increase, and the establishment of preventative methods will be necessary.

A number of basic investigations have attempted to elucidate the characteristics of TAM-related EC. Employing ChIP-seq, Droog *et al* (10) identified that cross-talk between forkhead box A1 (*FOXA1*) and ERα might contribute to the development of TAM-related EC. Several oncogenes, such as *PTEN* and *K-Ras*, were also investigated (11), however, due to the relatively low occurrence rate, the nature of TAM-related EC is far from fully understood. Therefore, we conducted copy number variation (CNV) analysis by nCounter and investigated MSI status in TAM-related EC and sporadic EC biopsies to assess the molecular genetic characteristics of TAM-related EC.

## Materials and methods

*Patients*. Among patients with HR-positive invasive breast cancer who received TAM as adjuvant endocrine therapy after curative surgery at our institute between 2013 and 2020, 10 patients developed EC after TAM administration (TAM-related EC). We also analyzed 20 sporadic EC samples randomly selected from 98 patients, whom we investigated in our previous study (2), surgically treated during the same period. The average age of TAM-related EC was 49.6 years, and those with sporadic EC was 60.9 years. None of these patients had been clinically diagnosed as having Lynch Syndrome (LS).

*Pathological assessment and immunohistochemistry*. Pathological assessment for EC and breast cancer was carried out at Juntendo University Hospital by two experienced pathologists (HS and AA) based on the WHO Classification. The histological subtype of all ECs was endometrioid carcinoma. Tissue sections of 4 $\mu$m were prepared from formalin-fixed paraffin-embedded blocks of EC surgical specimens and IHC was performed. IHC staining for mismatch repair (MMR) proteins was performed using primary monoclonal antibodies against MLH1 (clone ES05; Dako, Carpinteria, CA), MSH2 (clone FE11; Dako), PMS2 (clone EP51; Dako) and MSH6 (clone EP49; Dako). The staining procedures were previously described in detail (12). All MMR proteins (MLH1, MSH2, PMS2 and MSH6) were assessed for positive staining in the nuclei of cells. IHC for MMR proteins was also performed for breast cancer and endometrial hyperplasia specimens as precursor lesions for EC where available. Protein expression for the products of genes identified as amplified by CNV analysis were also assessed by IHC using the following antibodies: vascular endothelial growth factor receptor 2 (VEGFR2; clone 55B11; Cell Signaling Technology, Danvers, MA), tropomyosin receptor kinase (Trk) C (clone C44H5; Cell Signaling Technology), platelet-derived growth factor receptor β (PDGFRB; clone 28E1; Cell Signaling Technology), Notch1 (polyclonal, Santa Cruz Biotechnology, Dallas TX) and TrkA (clone 12G8; Cell Signaling Technology). Antigen retrieval was performed by heating in tris-ethylenediamine tetraacetic acid buffer (pH 9.0) for VEGFR2 and PDGFRB and in citrate buffer (pH 6.0) for TrkA, TrkC and Notch1.

*Nucleic acid extraction*. Genomic DNA was extracted from TAM-related EC surgical specimens as follows: 10 $\mu$m tissue sections were cut and DNA was extracted using a QIAamp DNA Formalin-Fixed Paraffin-Embedded Tissue kit (Qiagen Inc., Hilden, Germany). EC lesions and non-neoplastic endometrium or simultaneously resected ovary was separately dissected under a microscope for each case. Nontumorous tissue from each patient was used as a control. As nontumorous tissue, ovary and non-neoplastic endometrium were employed for TAM-related EC and sporadic EC cases, respectively.

*Copy number variation and microsatellite instability assessment*. A total of 30 samples, including 10 TAM-related ECs and 20 sporadic ECs, underwent CNV analysis using the NanoString nCounter gene expression system (NanoString Technologies, Seattle, WA). A customized panel including 28 genes encoding receptor tyrosine kinases which we previously established (13) was employed. The copy number for these genes for each EC lesion compared to the nonneoplastic lesion were determined in nSolver according to the manufacturer's instructions. Each copy number ratio was calculated with the score of nonneoplastic lesion being 2. MSI status was assessed in all 10 TAM-related EC, including 10 surgical and one endometrial curettage specimens. MSI testing was outsourced to the Takara Bio Inc. (Shiga, Japan) and the Fasmac Co. Ltd. (Kanagawa, Japan) as previously described (14). Using a Promega MSI Multiplex System, five loci from the DNA sequence for microsatellite markers (BAT-25, BAT-26, NR-21, NR-24, and MONO-27) were amplified. MSI-high (MSI-H) was determined if instability was detected at two or more markers, as recommended by the revised Bethesda Guidelines (15). Tumors with one or no unstable marker were classified as low levels of microsatellite instability (MSI-L) or microsatellite stable (MSS), respectively.

*Methylation assay*. Promoter-region methylation status of *MLH1* was analyzed in two cases in which MLH1 protein expression was lost by IHC. The detailed procedure has been described (16). The primers for methylated and unmethylated alleles were designed as done by House *et al* (17).

*Ethical approval and informed consent*. This study was carried out with approval from the Ethics Committee of Juntendo University (No. 2020281) and complies with the 1964 Helsinki Declaration and its later amendments or comparable ethical standards. All participants were informed that the research policy was available on the homepage of the hospital and that they had the opportunity to opt-out of the study at any time later on, which was approved by the Ethics Committee. The Ethics Committee approved of the opt-out method for the use of specimens and clinical data under the condition that all data were anonymized. Authors had access to information that could identify individual participants during or after data collection. Only those participants who had not opted-out from the study were included in the data analysis.

Table I. Clinicopathological data of patients with TAM-related and sporadic EC.

| Characteristics | TAM-related EC (n=10) | Sporadic EC (n=20) | P-value |
|---|---|---|---|
| Mean age, years (SD) | 49.5 (7.2) | 61.5 (10.0) | 0.004[a] |
| Stage, n | | | |
| I | 8 | 17 | >0.999[b] |
| II | 2 | 1 | |
| III | 0 | 1 | |
| IV | 0 | 1 | |
| Histology, n | | | |
| Endometrioid carcinoma, G1 | 9 | 11 | 0.101[b] |
| Endometrioid carcinoma, G2 | 1 | 7 | |
| Endometrioid carcinoma, G3 | 0 | 2 | |

[a]Unpaired t-test. [b]Fisher's exact test [compared between FIGO stage I (early cancer) and stage II-IV (advanced cancer), and between G1 and G2-G3]. TAM, tamoxifen; EC, endometrial cancer.

*Statistical analysis*. Mann-Whitney *U* tests and unpaired t tests were performed to analyze CNV data between TAM-related ECs and sporadic ECs. In addition, the Fisher's exact test and unpaired t-test was performed to compare clinicopathological data between TAM-related ECs and sporadic ECs, and between the MSI-H and MSI-L/MSS groups in TAM-related ECs. These data were evaluated using a two-tailed test and P<0.05 was considered to indicate a statistically significant difference.

## Results

*Clinicopathological findings*. Table I shows the clinicopathological characteristics of TAM-related ECs and sporadic ECs. Age was significantly younger in patients with TAM-related EC than those with sporadic EC (P=0.004). There was no significant difference in pathological stage based on the FIGO 2008 classification.

*Copy number variation and immunohistochemistry between tamoxifen-related endometrial cancer and sporadic endometrial cancer*. A summary of the results of CNV analysis is shown in Fig. 1. In total, five genes, *KDR*, *NTRK3*, *PDGFRB*, *NOTCH1* and *NTRK1*, appeared as frequently amplified genes in TAM-related EC, compared with sporadic EC (*KDR*, P=0.039; *NTRK3*, P=0.006; *PDGFRB*, P=0.035; *NOTCH1*, P<0.001; *NTRK1*, P=0.011) by either Mann-Whitney U test or unpaired t-test.

Next, IHC for the five proteins encoded by these genes was performed (Table SI). Representative images are shown in Fig. S1. One TAM-related EC case was diffusely and strongly positive for VEGFR2 and weakly positive for PDGFRB. Two sporadic EC cases were focally and weakly positive for TrkC and one sporadic EC case was focally and weakly positive for PDGFRB. Notch1 was positive for all cases and various intensity was seen from 1+ (weakly positive) to 3+ (strongly positive). Overall, intensity of IHC did not correlate with the ratio of copy number.

Table II. Clinicohistological data of patients with TAM-related endometrial cancer.

| Characteristics | MSI-H (n=4) | MSS (n=6) | P-value |
|---|---|---|---|
| Mean age, years (SD) | 48.5 (10.0) | 54.0 (3.7) | 0.244[a] |
| Stage, n | | | |
| I | 3 | 5 | >0.999[b] |
| II | 1 | 1 | |
| III | 0 | 0 | |
| IV | 0 | 0 | |
| Histology, n | | | |
| Endometrioid carcinoma, G1 | 4 | 5 | >0.999[c] |
| Endometrioid carcinoma, G2 | 0 | 1 | |
| Mean time after TAM administration, months (SD) | 42.0 (11.0) | 46.2 (7.6) | 0.397[a] |

[a]Unpaired t-test. [b]Fisher's exact test [compared between FIGO stage I (early cancer) and stage II-IV (advanced cancer)]. [c]Fisher's exact test. TAM, tamoxifen; MSI-H, microsatellite instability-high; MSS, microsatellite stable.

*Microsatellite instability status in tamoxifen-related endometrial cancers*. Next, we investigated MSI status in all 10 TAM-related ECs. Of the 10 TAM-related EC cases, four were MSI-H (40%) and six cases were MSS (60%). The clinicopathological findings according to MSI status are shown in Table II. There were no differences in age, pathological stage, EC tumor grade, or the length of time after initiating TAM administration, according to MSI status.

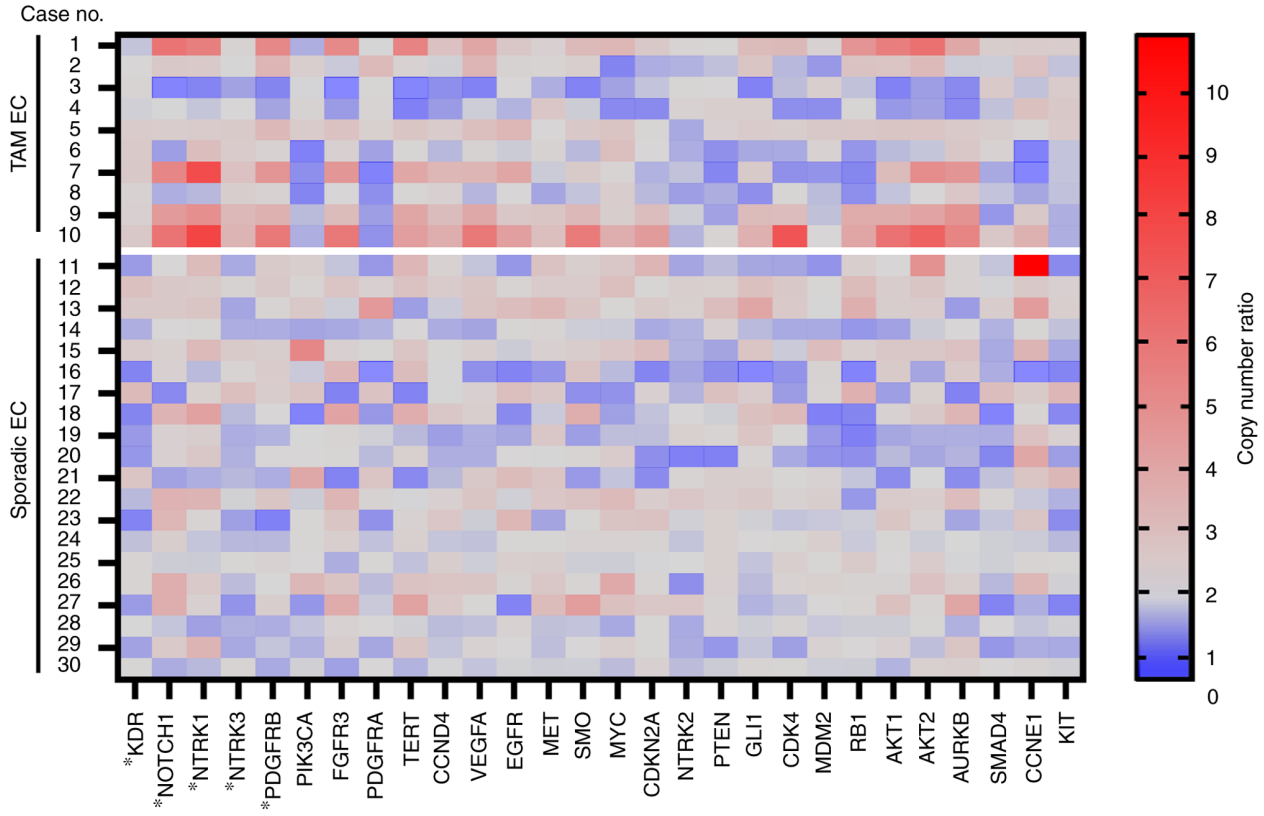


Figure 1. Results of CNV analysis for TAM-related EC (n=10) and sporadic EC (n=20). Each copy number ratio was calculated with the score of nonneoplastic lesion being 2. The heatmap of CNV analysis results is shown. *Indicates genes that showed a significant difference between TAM-related EC and sporadic EC (P<0.05). CNV, copy number variation; EC, endometrial cancer; TAM, tamoxifen.

*Immunohistochemistry for mismatch repair proteins*. Since we observed some MSI-H cases in TAM-related EC, we next conducted IHC for MMR proteins. As shown in Table III, four cases lost some MMR proteins and these corresponded to the MSI-H cases. All of MSI-H cases were endometrioid carcinoma, Grade 1 and one case was classified as FIGO Stage II due to an invasion to cervical stroma. Representative images of one case (Case #1) are shown in Fig. 2. Among the 10 patients with TAM-related EC, surgical specimens of primary breast cancer were available for IHC in six cases. All six breast cancer specimens retained MMR protein expression, including one MSH-H tumor (Case #2).

*Microsatellite instability status and mismatch repair protein expressions in previous benign biopsy specimens*. Among MSI-H cases of TAM-related ECs, Case #2 patient underwent histological examinations of the endometrium several times before developing EC and was diagnosed with endometrial hyperplasia without atypia. Hence, we also examined MSI status and MMR protein expressions in this biopsy specimen of hyperplasia. The benign lesion was MSI-H, and MLH1 and PMS2 expressions were deficient, similar to the surgical specimen of subsequent EC.

*Methylation assay for MLH1 promoter region in MLH1 protein-deficient tumors*. For two cases in which MLH1 protein was lost by IHC, we further conducted *MLH1* methylation-specific polymerase chain reaction. Methylation of the *MLH1* promoter region was detected in both cases (Fig. 3).

## Discussion

Our CNV analysis revealed that the amplification of five receptor tyrosine kinase genes, *KDR*, *NOTCH1*, *NTRK1*, *NTRK3* and *PDGFRB*, were more frequently detected in TAM-related EC, compared with sporadic EC. Meanwhile, the expression of corresponding proteins for these genes, assessed by IHC, did not reflect the results of the CNV analysis. This discrepancy might be caused by some deficiency or modification in the process of transcription. Yet, the biological significance of these genes for TAM-related EC cannot be ruled out and may merit further investigation.

According to the cBioPortal for Cancer Genomics across TCGA pan cancer atlas (18), the frequency of amplification for each gene in endometrioid carcinoma or mixed carcinoma of EC is low (*KDR none*, *NOTCH1* 1.04-4.76%, *NTRK1* 1.83-19.05%, *NTRK3* 0.26% and *PDGFRB none*). Our cases might show the characteristics of TAM-related EC different from sporadic EC. The frequency of MSI-H in TAM-related EC was 40%, higher than what we previously reported in sporadic EC in Japanese patients (2). There have been a few reports on MSI status in TAM-related EC and their results differed to the current study, as the frequency of MSI-H in TAM-related EC was not different from (19) or, rather, was lower than that in sporadic EC (11). However, these studies employed relatively older methods (e.g., with less microsatellite markers) while we followed the revised Bethesda Guidelines. It is unclear whether TAM promotes MSI or not. In the current study, we were unable to perform a functional

Table III. MSI status and MMR protein expression based on immunohistochemistry in tamoxifen-related endometrial cancer.

| | EC | | | | | | BC | | |
|---|---|---|---|---|---|---|---|---|---|
| Case no. | Age, years | MSI status | Loss of MMR proteins | Tumor grade | Vessel invasion (Ly/V) | Lymph node metastasis | Loss of MMR proteins | Past history | Family history |
| 1 | 49 | MSI-H | MSH2, MSH6 | G1 | - | - | N.E. | None | BC (mother) |
| 2 | 47 | MSI-H | MLH1, PMS2 | G1 | +/+ | - | - | BLC | None |
| 3 | 50 | MSI-H | MSH6 | G1 | +/- | - | N.E. | None | CC (mother), BLC and LC (father) |
| 4 | 45 | MSI-H | MLH1, PMS2 | G1 | -/- | N.E. | N.E. | None | None |
| 5 | 54 | MSS | - | G1 | -/- | N.E. | - | None | None |
| 6 | 54 | MSS | - | G2 | -/- | - | N.E. | None | CC (mother) |
| 7 | 36 | MSS | - | G1 | -/- | - | - | None | BC (grandmother, aunt) |
| 8 | 43 | MSS | - | G1 | -/- | N.E. | - | None | BC (sister), CC and PC (uncle) |
| 9 | 54 | MSS | - | G1 | -/- | N.E. | - | None | None |
| 10 | 64 | MSS | – | G1 | -/- | N.E. | - | None | GC (mother) |

EC, endometrial cancer; BC, breast cancer; MSI, microsatellite instability; MMR, mismatch repair; MSI-H, microsatellite instability-high; MSS, microsatellite stable; MSH2, mutS homolog 2; MSH6, mutS homolog 6; MLH1, mutL homolog 1; PMS2, PMS1 homolog 2, mismatch repair system component; N.E., not evaluated; BLC, bladder cancer; CC, colon cancer; LC, liver cancer; PC, pancreatic cancer; GC, gastric cancer; Ly, lymphatic vessel invasion; V, venous invasion.

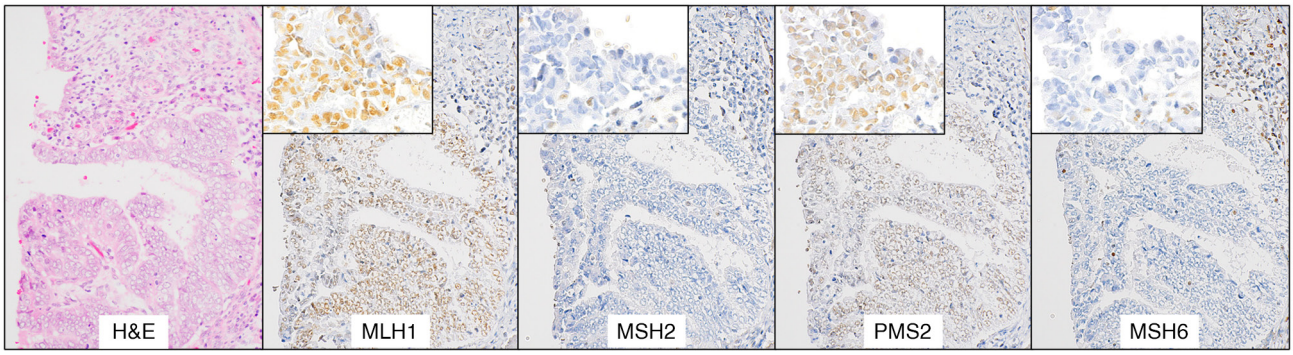


Figure 2. Representative images of immunohistochemistry for MMR proteins in a MSI-high case. Images of MMR proteins of Case #1 (MSI-high) are shown. MSH2 and MSH6 protein expression was lost in this case. Magnification, x200; inset magnification, x400. MLH1, mutL homolog 1; MMR, mismatch repair; MSH2, mutS homolog 2; MSH6, mutS homolog 6; MSI, microsatellite instability; PMS2, PMS1 homolog 2, mismatch repair system component.

analysis. Further investigations employing cell lines to assess changes in MSI status with TAM treatment and analysis of endometrial tissue over time before developing TAM-related EC are also warranted.

The high frequency of MSI-H in TAM-related ECs indicates that the prognosis of these tumors may be better than that of sporadic ECs. However, one report suggests a worse prognosis among LS patients with EC occurring in the group taking TAM (20). Considering the recent trend of extension of TAM duration after breast cancer surgery, we believe that it is necessary to continue to investigate the characteristics of this tumor in more detail.

In our study, patients in the TAM-related EC group were significantly younger than those in the sporadic EC group, while the risk of EC due to TAM is known to be higher in older patients (4,21). The main reason for the lower age in our cohort is possibly due to the low frequency of TAM administration in postmenopausal women. Compared to a few

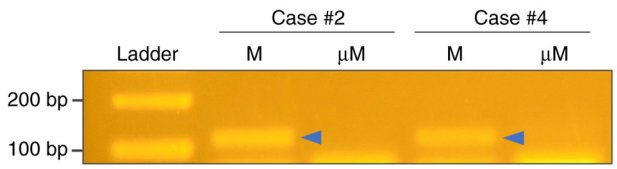


Figure 3. Methylation assay for the MLH1 promoter region in Cases #2 and #4. Methylation assays for the MLH1 promoter region were conducted for Case #2 and Case #4, whose MLH1 and PMS1 homolog 2, mismatch repair system component protein expression was lost. M, reaction for methylated DNA; MLH1, mutL homolog 1; uM, reaction for unmethylated DNA.

decades ago, aromatase inhibitors rather than TAM are now given to most postmenopausal patients as adjuvant endocrine therapy for breast cancer in Japan. Thus, the number of postmenopausal breast cancer patients taking TAM has decreased. Unfortunately, we were unable to collect detailed data on the type and duration of endocrine therapy for all of the patients who underwent curative surgery for breast cancer. Therefore, it was not possible to assess the exact frequency of TAM-related EC development.

We could not completely exclude the possibility that patients with TAM-related EC had a background of LS. For instance, Case #2 developed urinary tract cancer after breast cancer and EC but had no relevant family history. Case #3 had a family history as her mother suffered colon cancer and father experienced urinary tract and liver cancers. Only one primary breast cancer sample was available among the MSI-H cases, and the expression of MMR proteins were retained. However, some reports indicate that breast cancer in patients with LS is not necessarily MSI-H (22,23), hence LS cannot be determined by MMR protein expressions in breast cancer. Nevertheless, no patients in our cohort had undergone genetic testing for LS diagnosis.

Our data indicate that TAM-related ECs are frequently MSI-high. If further study confirms our finding, gynecological routine screening during TAM medication may be less critical than expected because MSI-high EC is known to have a relatively favorable prognosis (1). As such, unnecessary testing may be reduced in the future in clinical practice. Furthermore, for treatment of TAM-related EC, MSI status should be actively tested for to determine the optimal individualized postoperative treatment.

A major limitation of this study is, as with other studies, the small sample size. Another difficulty of analyzing this disease is that presumably not all TAM-related EC develop due to TAM. Considering the low occurrence rate of TAM-associated EC, there is even the possibility that it only arises from biologically altered-endometrium by TAM, but that TAM does not 'promote' the development of cancer *per se*. Given the timing of TAM administration, i.e., duration of the treatment and time after completion of treatment, we believe that it is also necessary to continue to accumulate more patients over a longer period.

In our study, we investigated the molecular characteristics of TAM-related ECs and revealed several genes with specific changes in TAM-related ECs. Furthermore, the frequency of MSI was higher in TAM-related EC. Our findings may lead to a reduction of unnecessary gynecologic testing in clinical practice, and also encourage the testing of MSI status for optimal individualized treatment. We believe that researchers need to continue to analyze TAM-related ECs from a variety of perspectives.

**Acknowledgements**

The authors would like to thank Ms. Tomomi Ikeda and Ms. Takako Ikegami (Laboratory of Molecular and Biochemical Research, Biomedical Research Core Facilities, Juntendo University Graduate School of Medicine, Tokyo, Japan) for the technical assistance with microsatellite instability analysis, and Dr Hidetaka Eguchi (Intractable Disease Research Center, Juntendo University Graduate School of Medicine, Tokyo, Japan) for technical assistance with the NanoString nCounter gene expression system for copy number variation analysis.

**Funding**

The present study was supported through grants from the Grant-in-Aid of the Japan Society for the Promotion of Science KAKENHI (grant nos. 20K17594 and 21K15409) and a grant from the Institute for Environmental & Gender-specific Medicine, Juntendo University (grant no. E2011).

**Availability of data and materials**

All data generated or analyzed during this study are included in this published article.

**Authors' contributions**

HS, YH and TS designed the study. HS, YH, MTH, YM, LR, YI, TU, EY and YT conducted data acquisition. YH, YI, TU, EY and YT treated patients. HS, YH, AA and TY performed pathological assessment and histological analysis. HS, YH, YM and TS conducted data analysis and statistical analysis. HS and YH drafted the original manuscript and TS and TY substantially revised it. HS and YH confirm the authenticity of all the raw data. All authors have read and approved the final manuscript.

**Ethics approval and consent to participate**

All procedures performed in studies involving human participants were in accordance with the ethical standards of the Ethics Committee of Juntendo University (approval no. 2020281; Tokyo, Japan) and with the 1964 Helsinki declaration and its later amendments or comparable ethical standards. The requirement for informed consent was waived by the Ethics Committee of Juntendo University.

**Patient consent for publication**

Not applicable.

**Competing interests**

The authors declare that they have no competing interests.

## References


1. Cancer Genome Atlas Research Network; Kandoth C, Schultz N, Cherniack AD, Akbani R, Liu Y, Shen H, Robertson AG, Pashtan I, Shen R, *et al*: Integrated genomic characterization of endometrial carcinoma. Nature 497: 67-73, 2013.
2. Saeki H, Hlaing MT, Horimoto Y, Kajino K, Ohtsuji N, Fujino K, Terao Y and Hino O: Usefulness of immunohistochemistry for mismatch repair protein and microsatellite instability examination in adenocarcinoma and background endometrium of sporadic endometrial cancer cases. J Obstet Gynaecol Res 45: 2037-2042, 2019.
3. DeSantis CE, Ma J, Gaudet MM, Newman LA, Miller KD, Goding Sauer A, Jemal A and Siegel RL: Breast cancer statistics, 2019. CA Cancer J Clin 69: 438-451, 2019.
4. Early Breast Cancer Trialists' Collaborative Group (EBCTCG); Davies C, Godwin J, Gray R, Clarke M, Cutter D, Darby S, McGale P, Pan HC, Taylor C, *et al*: Relevance of breast cancer hormone receptors and other factors to the efficacy of adjuvant tamoxifen: Patient-level meta-analysis of randomised trials. Lancet 378: 771-784, 2011.
5. Fisher B, Costantino JP, Redmond CK, Fisher ER, Wickerham DL and Cronin WM: Endometrial cancer in tamoxifen-treated breast cancer patients: Findings from the national surgical adjuvant breast and bowel project (NSABP) B-14. J Natl Cancer Inst 86: 527-537, 1994.
6. Braithwaite RS, Chlebowski RT, Lau J, George S, Hess R and Col NF: Meta-analysis of vascular and neoplastic events associated with tamoxifen. J Gen Intern Med 18: 937-947, 2003.
7. Shang Y and Brown M: Molecular determinants for the tissue specificity of SERMs. Science 295: 2465-2468, 2002.
8. Jordan VC and Assikis VJ: Endometrial carcinoma and tamoxifen: Clearing up a controversy. Clin Cancer Res 1: 467-472, 1995.
9. Davies C, Pan H, Godwin J, Gray R, Arriagada R, Raina V, Abraham M, Medeiros Alencar VH, Badran A, Bonfill X, *et al*: Long-term effects of continuing adjuvant tamoxifen to 10 years versus stopping at 5 years after diagnosis of oestrogen receptor-positive breast cancer: ATLAS, a randomised trial. Lancet 381: 805-816, 2013.
10. Droog M, Nevedomskaya E, Kim Y, Severson T, Flach KD, Opdam M, Schuurman K, Gradowska P, Hauptmann M, Dackus G, *et al*: Comparative cistromics reveals genomic cross-talk between FOXA1 and ERα in tamoxifen-associated endometrial carcinomas. Cancer Res 76: 3773-3784, 2016.
11. Turbiner J, Moreno-Bueno G, Dahiya S, Sánchez-Estevez C, Hardisson D, Prat J, Oliva E and Palacios J: Clinicopathological and molecular analysis of endometrial carcinoma associated with tamoxifen. Mod Pathol 21: 925-936, 2008.
12. Suzuki O, Eguchi H, Chika N, Sakimoto T, Ishibashi K, Kumamoto K, Tamaru JI, Tachikawa T, Akagi K, Arai T, *et al*: Prevalence and clinicopathologic/molecular characteristics of mismatch repair-deficient colorectal cancer in the under-50-year-old Japanese population. Surg Today 47: 1135-1146, 2017.
13. Sasa K, Saito T, Kurihara T, Hasegawa N, Sano K, Kubota D, Akaike K, Okubo T, Hayashi T, Takagi T, *et al*: Establishment of rapid and accurate screening system for molecular target therapy of osteosarcoma. Technol Cancer Res Treat 21: 15330338221138217, 2022.
14. Horimoto Y, Thinzar Hlaing M, Saeki H, Kitano S, Nakai K, Sasaki R, Kurisaki-Arakawa A, Arakawa A, Otsuji N, Matsuoka S, *et al*: Microsatellite instability and mismatch repair protein expressions in lymphocyte-predominant breast cancer. Cancer Sci 111: 2647-2654, 2020.
15. Umar A, Boland CR, Terdiman JP, Syngal S, de la Chapelle A, Rüschoff J, Fishel R, Lindor NM, Burgart LJ, Hamelin R, *et al*: Revised Bethesda guidelines for hereditary nonpolyposis colorectal cancer (Lynch syndrome) and microsatellite instability. J Natl Cancer Inst 96: 261-268, 2004.
16. Suzuki Y, Fukumura Y, Asahina M, Fujimaki M, Ohba S, Matsumoto F, Kurahayashi I, Yao T and Ikeda K: EGFR protein expression relates with tumor histology, methylation status of EGFR and HPV16 E6 viral load in oropharyngeal carcinoma. Head Neck Pathol 15: 743-756, 2021.
17. House MG, Guo M, Iacobuzio-Donahue C and Herman JG: Molecular progression of promoter methylation in intraductal papillary mucinous neoplasms (IPMN) of the pancreas. Carcinogenesis 24: 193-198, 2003.
18. Cerami E, Gao J, Dogrusoz U, Gross BE, Sumer SO, Aksoy BA, Jacobsen A, Byrne CJ, Heuer ML, Larsson E, *et al*: The cBio cancer genomics portal: An open platform for exploring multidimensional cancer genomics data. Cancer Discov 2: 401-404, 2012.
19. Prasad M, Wang H, Douglas W, Barakat RR and Ellenson LH: Molecular genetic characterization of tamoxifen-associated endometrial cancer. Gynecol Oncol 96: 25-31, 2005.
20. Johnatty SE, Stewart CJR, Smith D, Buchanan D, Leung Y, Oehler MK, Brand A, Webb PM and Spurdle AB: Risk and prognostic factors for endometrial carcinoma after diagnosis of breast or Lynch-associated cancers-A population-based analysis. Cancer Med 7: 6411-6422, 2018.
21. Fisher B, Costantino JP, Wickerham DL, Cecchini RS, Cronin WM, Robidoux A, Bevers TB, Kavanah MT, Atkins JN, Margolese RG, *et al*: Tamoxifen for the prevention of breast cancer: Current status of the national surgical adjuvant breast and bowel project P-1 study. J Natl Cancer Inst 97: 1652-1662, 2005.
22. Latham A, Srinivasan P, Kemel Y, Shia J, Bandlamudi C, Mandelker D, Middha S, Hechtman J, Zehir A, Dubard-Gault M, *et al*: Microsatellite instability is associated with the presence of Lynch syndrome pan-cancer. J Clin Oncol 37: 286-295, 2019.
23. Kanaya N, Tanakaya K, Yamasaki R, Arata T, Shigeyasu K, Aoki H, Morito T, Sanaii H, Akagi K and Fujiwara T: Clinicopathological features of breast cancer in Japanese female patients with Lynch syndrome. Breast Cancer 26: 359-364, 2019.