SPANDIDOS PUBLICATIONS

ONCOLOGY LETTERS 27: 31, 2024

Update on clinical characteristics and molecular insights for uterine intravenous leiomyomatosis (Review)

XIAOTING ZHOU, XIAORONG QI, XIA ZHAO and FAN YANG

Department of Gynecology and Obstetrics, Development and Related Disease of Women and Children Key Laboratory of Sichuan Province, Key Laboratory of Birth Defects and Related Diseases of Women and Children, Ministry of Education, West China Second Hospital, Sichuan University, Chengdu, Sichuan 610041, P.R. China

Received June 29, 2023; Accepted November 9, 2023

DOI: 10.3892/ol.2023.14165

Abstract. Intravenous leiomyomatosis (IVL) is a rare benign disease, which typically develops along vascular vessels and extends to the inferior vena cava and right atrium of the heart. In the early stages of the disease, the clinical manifestations and the results of imaging examinations are not uniform among patients. Thus, a high rate of misdiagnosis and missed diagnosis is common. When the tumor extends along the venous system to the pelvic floor vein or through the inferior vena cava involving the right atrium of the heart or the pulmonary artery, severe symptoms occur, such as ascites, dyspnea, heart failure and even sudden mortality. Improving the understanding of IVL to identify and evaluate this disease in its early stages is important. Complete tumor resection remains the primary treatment option for IVL. The recurrence rate of the disease varies depending on multiple factors, such as type of surgical procedure performed. Therefore, long-term follow-up is necessary for patients with IVL. The review of recent findings on the molecular and clinicopathological characterization of IVL is important to understand the pathogenesis of IVL. In the present study, the clinical manifestations, pathogenesis, differential diagnosis, treatment and prognosis of IVL are summarized in order to provide a single source of insightful information on IVL.

Correspondence to: Dr Fan Yang, Department of Gynecology and Obstetrics, Development and Related Disease of Women and Children Key Laboratory of Sichuan Province, Key Laboratory of Birth Defects and Related Diseases of Women and Children, Ministry of Education, West China Second Hospital, Sichuan University, 20, Section 3, South Renmin Road, Chengdu, Sichuan 610041, P.R. China
E-mail: sharry48@163.com

Key words: intravenous leiomyomatosis, pathogenesis, diagnosis, treatment, prognosis

Contents

1. Introduction

Intravenous leiomyomatosis (IVL) is a rare benign smooth muscle tumor, which is characterized by its origin in the uterus and intrapelvic or extra-pelvic extension along the venous system (1). This growth pattern may present clinically as low-grade malignant potential. Since it was first reported in 1896 by Hirschfeld (2), ~700 cases have been reported worldwide (3). Typically, IVL is diagnosed in women of reproductive-age with a history of uterine leiomyomas, and it is considered to be one of the more unusual extrauterine leiomyomas. Other similar unique growth patterns are found in benign metastasizing leiomyoma (BML), leiomyomatosis peritonealis disseminata, parasitic leiomyoma and retroperitoneal growth (4). Due to the lack of obvious symptoms in the early stages and no effective diagnostic approach, it is usually challenging to make a diagnosis prior to surgery. When the tumor is confined within the pelvis (commonly found in the uterus and rarely found invading the pelvic veins and vena cava), abdominal or pelvic pain associated with a pelvic mass is the most common symptom, which is similar to that in patients with uterine leiomyomas (5). Severe symptoms such as shortness of breath, chest tightness, pulmonary embolism and even shock may occur in patients with IVL if the right side of the heart or the pulmonary arteries are involved (6). The main treatment option for IVL is a complete tumor resection. However, when the mass clearly invades the extrauterine venous system, patients are at risk of intraoperative hemorrhage or collateral damage and there is an increased mortality rate. Moreover, the overall recurrence rate of IVL has been

reported to be 10-31% (7,8). Recently, the molecular and clinicopathological characterization of IVL has been discussed in the literature. In the present review, the clinical manifestations, pathogenesis, pathological characteristics, treatment and prognosis of IVL are summarized. The present review aims to assist clinicians to delineate the clinical spectrum of this disease and provide a meaningful reference for its diagnosis and treatment.

2. Etiology

To explain the pathogenesis of IVL, two possible principal theories have been proposed. One theory considers that the smooth muscle cells in the vessel wall are the origin of IVL. Several cases have demonstrated that primary leiomyoma exists in large veins outside the uterine vein, such as the jugular vein, the popliteal vein, the common iliac vein and the subclavian vein (9-11). The number of cases of primary and male IVL is much lower compared with that of female patients with IVL and a history of uterine leiomyoma. The other theory proposes that the benign uterine leiomyoma invades the uterus or para-uterine veins. Both theories have supporting evidence, although most of the published literature currently supports the second hypothesis (11).

The majority of patients with IVL have a history of uterine leiomyoma or have undergone myomectomy or hysterectomy. Additionally, pathological and imaging examinations have shown a physical connection between the base of the tumor and the wall of the uterus (12). Furthermore, there is positive expression of progesterone receptor (PR) and estrogen receptor (ER) in IVL tumor cells, resembling the pathogenesis of uterine myoma. By contrast, there are low ER or PR expression levels in endothelial and subendothelial cells. This feature is consistent with the theory that IVL originates from uterine leiomyomas (13). In addition, several studies have reported the comparison of the gene expression between IVL and uterine leiomyomas (14-16). A study on the molecular cytogenetics of IVL revealed a similar chromosomal mechanism in IVL compared with that in typical uterine leiomyoma. Generally, structural chromosomal abnormalities were reported in ~50% of the cases of uterine leiomyomas, and spontaneous chromosome rearrangements accounted for ~20% of these abnormalities, which were mainly manifested as rearrangements of 12q14-15 (17). This chromosomal region targets the gene that encodes high-mobility group AT-hook 2 (18), which is considered to be associated with the self-renewal ability of stem cells. Additionally, this chromosomal rearrangement has been observed in IVL, underlying the association between the two entities. Another study demonstrated the genome-wide copy number alterations in a large series of 28 IVLs from 26 patients (2 of the cases were recurrences). Apart from der(14) t(12;14), chromosome alterations are reported in 1p, 22q, 2q, 1q, 13q, 3q and 10q, involving genes implicated in mesenchymal tumors (19). Furthermore, apart from sharing various molecular cytogenetic characteristics with uterine leiomyoma, IVL demonstrates similar expression profiles of leiomyosarcoma in hierarchical cluster analysis, which could be associated with the intermediate, quasi-malignant behavior of IVL (14).

A genome-wide investigation of 9 cases with IVL used oligonucleotide array comparative genomic hybridization. The result showed that all 9 cases of IVL harbored a wild-type mediator complex subunit 12 (MED12) gene at codon 44, while MED12 mutations were observed in up to 80% of uterine leiomyoma cases in another study (20,21). A similar result was reported in the study by Wang *et al* (22), which used Sanger sequencing to detect the mutation status of MED12 gene exon 2 in 9 cases of IVL (22). This revealed two novel MED12 mutations in IVL, which were different from that of uterine leiomyoma. No mutation at MED12 gene exon 2 was revealed in the remaining 7 cases of IVL. These results suggest that the MED12 gene may exhibit a different pathogenesis between IVL and uterine leiomyoma. Another previous study compared the molecular association between IVL and uterine myoma, and demonstrated similar dysregulated gene networks in the two diseases by identifying differentially expressed genes (DEGs) using RNA sequencing (RNA-seq) (15). Further results from Gene Ontology analysis in this study revealed that these DEGs were associated with cell adhesion, hormone stimulus and the extracellular matrix. However, elevated homeobox A13 (HOXA13) gene expression levels were shown in IVL, which could serve as a biomarker to differentiate uterine myoma from IVL (15). Another study identified DEGs between IVL and leiomyoma using RNA-seq analysis with reverse transcription-quantitative PCR validation. Upregulated anti-apoptosis-related genes BCL2A1 and CDKN2A, and the downregulated angiogenesis-related gene CXCL8 were found in IVL, partly demonstrating the possible molecular mechanism of the differences between IVL and uterine leiomyoma (16).

In addition to genomic and transcriptomic analysis, a recent study compared IVL and other smooth muscle tumors (uterine leiomyoma, soft tissue leiomyoma and BML) at the protein level using proteomic profiling analyses (23). A group of co-regulated splicing factors were found in IVL, which could be associated with the unique clinical behavior of the disease. One of these enriched clusters in IVL was shown to participate in the high expression of a number of important proteins, involving nascent protein (SRP-dependent cotranslational protein targeting to membrane), proteins involved in viral transcription and small GTPases mediating signal transduction (23). Furthermore, this study also found that IVL is more similar to BML at the proteomic level compared with uterine leiomyoma. This is consistent with a previous array comparative genomic hybridization analysis, which identified the recurrent copy number alterations in IVL overlap those found in BML (19).

Overall, these comparative gene expression studies demonstrate the difference and similarities between IVL and other smooth muscle tumors at multiple levels. Given the rarity of IVL, most studies have a limited number of cases; however, these data are required for an improved understanding of the pathogenesis of IVL. The similar cytogenetic and protein expression features support the theory that IVL originates from a pre-existing uterine leiomyoma. The unique alterations in IVL, including distinct MED12 mutations, downregulated expression levels of the angiogenesis-related gene CXCL8 and elevated expression levels of the HOXA13 gene and anti-apoptosis-related genes, are the focus for exploring the molecular mechanism of IVL progression. These studies have revealed that the unique molecular profile of IVL partially

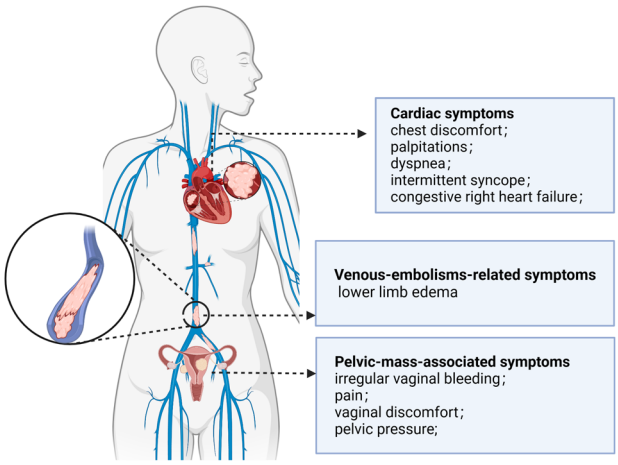

Figure 1. Clinical manifestations of IVL. In most cases, IVL is confined within the pelvis. Patients in this stage are usually asymptomatic or demonstrate some symptoms caused by pelvic masses, such as abdominal distention, unexplained pelvic pain and abnormal vaginal bleeding. As the tumor grows out of the pelvic cavity, reaching the renal vein and inferior vena cava, patients experience edema and heaviness of the lower extremities. When the tumor invades the right atrium or the pulmonary artery, patients may suffer from chest discomfort, palpitations, dyspnea, syncope, and in severe cases, develop congestive heart failure or pulmonary embolism, or even experience sudden death. IVL, intravenous leiomyomatosis.

overlaps with uterine leiomyoma and uterine leiomyosarcoma, similar to their intermediate clinical behavior (4,16,19,22,23). Future work investigating these DEGs will provide further insight into the possible pathogenesis of IVL.

3. Clinical manifestations

IVL occurs mainly in premenopausal women with a previous reproductive history and occasionally in postmenopausal women. The age at diagnosis ranges from 21-81 years, with a median age of 46 years (24). The clinical manifestations of IVL are usually variable and non-specific, which mainly depends on the tumor size and the organ involved (3). In most cases, IVL is confined within the pelvis, and patients in this stage are usually asymptomatic or demonstrate a number of symptoms caused by pelvic masses, such as abdominal distention, unexplained pelvic pain, abnormal vaginal bleeding, hypermenorrhea and menostaxis (25). Urinary tract obstruction could occur when the tumor compresses the ureter (26). All these common presenting complaints are similar to those of uterine leiomyomas. As the tumor grows out of the pelvic cavity, reaching the renal vein and inferior vena cava, patients experience edema and heaviness of the lower extremities (27). Acute Budd-Chiari syndrome, with shortness of breath, bilateral diffuse lower extremities, ascites, edema and hepatomegaly, has been reported in several patients as a result of tumor thrombosis (28). When the tumor invades the right atrium or the pulmonary artery, it is known as intravenous-cardiac leiomyomatosis (IVCL). IVCL accounts for 10-30% of IVL cases, and the patient may suffer from chest discomfort, palpitations, dyspnea, syncope, and in severe cases, develop congestive heart failure, pulmonary embolism or even sudden mortality (24). Two pathways have been reported for IVL extending into the inferior vena cava and right atrium. The first access is via the uterine veins to the internal iliac veins to the common iliac veins to the inferior vena cava to the right side of the heart (29). A case study reported that the right iliac vein was shorter and straighter compared with the left one before joining the inferior vena cava, suggesting that the lesion was prone to invade the inferior vena cava from the right iliac vein (30). The second access is via the left ovarian vein to the left renal vein to the inferior vena cava. Compared with the ovarian veins, the uterine vein is more commonly involved. The different routes of venous channels have an impact on the difficulty of surgical resection (31).

All these symptoms can be divided into three categories: i) Symptoms associated with a pelvic mass, such as irregular vaginal bleeding, pain, vaginal discomfort or pelvic pressure; ii) symptoms associated with venous embolisms, such as lower limb edema; and iii) cardiac symptoms, such as congestive right-sided heart failure, intermittent syncope and dyspnea (Figure 1).

4. Imaging manifestations

Ultrasonography is the most convenient and simple diagnostic method for IVL. Tubular or slit-like anechoic lesions can be observed in IVL masses (32). Color Doppler flow imaging can detect venous blood flow signals in slit-like anechoic lesions so that they can be distinguished from common uterine fibroids. Cardiac ultrasound can be used to evaluate intravascular and intracardiac lesions when performed by experienced operators, which requires specialized training (33). In particular, transthoracic echocardiography is indispensable for revealing the intracardiac lesion burden as well as the associated compromise (30,33). Contrast-enhanced ultrasonography (CEUS) can allow tracking of the origin and expansion of the lesion (30). The echocardiography of IVL cardiac extension manifests as solid or tubular masses in the right atrium of the heart, and is soft and highly mobile, with no stalk adhering to the wall of the heart (33). Different perfusion modes of CEUS are shown in different types of IVL. Solid-mass IVL exhibits earlier perfusion, and the intensity is the same as that of the myocardium. Cystic conduit IVL has delayed perfusion, with an intensity similar to that of the cardiac chambers. It is proposed that cystic tumors are venous leiomyomas, with no vascular function, which is responsible for the delay in blood supply in cystic tumors compared with that in solid tumors. The 'sieve hole sign' and the 'multi-track sign' are reported to be the specific signs of IVL in CEUS diagnosis (34).

Computed tomography (CT) imaging is an important examination technique to display the distinct features of IVL, and 3D post-processing, including multiplanar reconstruction, maximum intensity projection and CT angiography (CTA), is beneficial to directly demonstrate the full-scale path of the tumor extension. The chest/abdomen/pelvis combined scans are able to show the IVL extension pathway clearly (35). Usually, a tumor mass exhibits heterogeneous enhancement, and typical CT findings include a low-density intravascular mass with deficient filling (36). Tumors in the inferior vena cava are continuous, with a stadium shape (35). When tumors invade the right atrium of the heart, a snake's head- or walking stick head-shaped mass can be found (12,37). Moreover, CTA can also reveal the condition of other organs, including

Uterine leiomyoma		IVL	Leiomyosarcoma	
Differences	Similarities	Differences	Differences	Similarities
MED12 mutations	Rearrangements of 12q14-15; Positive expression of ER and PR; Similar dysregulated gene networks	Elevated HOXA13; Upregulated antiapoptosis-related genes: BCL2A1, CDKN2A; Downregulated angiogenesis-related gene: CXCL8; Increased expression of p16 and cyclin D1	CD44-positive mesenchymal tumor cells	Positive expression of cyclin E and Ki-67

Figure 2. Similarities and differences in cytogenetic and protein expression features between IVL and uterine leiomyoma/leiomyosarcoma. The unique molecular profile of IVL partially overlaps with that of uterine leiomyoma and leiomyosarcoma, similar to their intermediate clinical behavior. ER, estrogen receptor; PR, progesterone receptor; IV, intravenous leiomyomatosis; MED12, mediator complex subunit 12; HOXA13, homeobox A13; BCL2A1, BCL2-related protein A1; CDKN2A, cyclin-dependent kinase inhibitor 2A; CXCL8, C-X-C motif chemokine ligand 8.

hydronephrosis, abdominal ascites, pulmonary or hepatic metastasis, collateral circulation and pericardial effusion. This increased imaging information facilitates the diagnosis of IVL (12). Due to the detailed information regarding the tumor composition given by CT imaging, it serves as the primary imaging technique in preoperative assessment. A recent study reported that a contrast-enhanced CT-based radiomic nomogram could provide evidence for the differential diagnosis of IVL and uterine leiomyoma (38).

The excellent soft-tissue resolution of MRI makes this non-invasive diagnostic technique desirable in spite of shortcomings, such as its time-consuming nature, poor spatial resolution and lack of suitability for patients with cardiac pacemakers or intrauterine metal devices (12). It has been reported that the number of smooth muscle cells and vessels containing hyalinized fibrous tissue determines the signal intensity of the lesions on MRI. Multiple signals (low, equal or high), depending on the ratio of smooth muscle to fibrous tissue, and unevenly high signals may appear on T2 and T1 weighted images (37). However, these signal features are not specific for IVL. A luffa vegetable sponge and sieve pore-like appearance on MRI are demonstrated to be important features for differential diagnosis (6).

5. Pathological characteristics

On first examination, the morphology of IVL overlaps with that of other uterine mesenchymal tumors. Cord-like, worm-like or lobulated structures are characteristically visible macroscopically in the myometrial or parametrial layers and extend along the uterine and ovarian veins (39). These worm-like plugs are usually white to gray in color, with a convoluted irregular border (40).

On microscopic examination, IVL consists of smooth muscle cells, which grow in the vascular cavity. The spindle-shaped smooth muscle cells of the same size and shape are arranged in a whirlpool, scattered in the thick-walled small blood vessels, surrounded by banded glassy tissue. Moreover, the focal distribution of edema degeneration and glassy areas is easily found. Only a small number of nuclear division images, generally <2/10 high-power field and nuclear atypia are found in IVL (25).

Typically, positive expression of ER and PR is reported in most cases of IVL. There is also positive expression for smooth muscle actin, the peritumor vascular endothelial markers (CD31 and CD34) and factor VIII in the intravascular parts of the tumor (41), which could serve as biomarkers to identify IVL. One molecular pathological study identified a population of tumor stem-like cells in IVL, similar to uterine leiomyosarcoma. The CD44-positive mesenchymal tumor cells were hypothesized to be able to infiltrate into the vasculature, participating in tumor metastasis (8). CD44 has also been identified as the first integral receptor of hyaluronan. Hyaluronan is involved in tumor invasion/metastases and can enhance tumor growth by stimulating angiogenesis and malignant neovascularization (42). Elevated expression levels of hyaluronan and CD44 are demonstrated in IVL, while in uterine leiomyomas, hyaluronan is reported to be notably lower, suggesting a difference in the pathogenesis. The grape-like appearance with a large amount of fluid accumulation in the IVL tumor could be associated with hyaluronan secretion, producing tissue hydration (43). High positive expression levels of cyclin E and Ki-67 are factors associated with a poor prognosis in uterine leiomyosarcoma. However, in contrast to the high expression levels of cyclin E and Ki-67 frequently observed in uterine leiomyosarcoma, cyclin E and Ki-67-expressing cells are rarely found in IVL, which is in line with the low malignancy of IVL (44). The retinoblastoma (Rb) pathway is known to serve a regulatory role in multiple steps of cancer progression, including angiogenesis, the epithelial-mesenchymal transition, invasion and migration (45). The findings from immunohistochemistry (IHC) experiments suggest cytoplasmic phosphorylated-Rb localization in IVL. The nuclear export of Rb may be the mechanism

for Rb inactivation, signifying the role of the Rb pathway in IVL pathogenesis (19). The p16/cyclin D1/Rb pathway serves a critical role in controlling the transition from the G_1 to the S phase, which is routinely used to diagnose various tumor types (46). Increased expression of p16 and Cyclin D1 can be detected in IVL using IHC (8,19).

6. Differential diagnosis

Leiomyosarcoma, intravenous thrombus, right atrial myxoma and malignant thrombosis with carcinoma (such as renal cell carcinoma, hepatocellular carcinoma and adrenocortical carcinoma) have similar clinical manifestations or similar characteristics on CT or MRI with IVL, and they need to be differentially diagnosed from IVL (34,47).

Firstly, these diseases are not usually accompanied by a history of uterine leiomyoma. No vessels grow inside the intravenous thrombus and thus no enhancement arises inside the intravenous thrombosis on contrast CT (35). It can be challenging to differentiate IVL from primary leiomyosarcoma at an early stage due to similar clinical and radiological manifestations. Leiomyosarcoma is known to grow from the wall of the inferior vena cava, which tends to involve the vascular walls and adjacent tissues (48). IVL, by contrast, has a clear boundary with no adhesion to the vascular walls. Men account for a large proportion of the patients with leiomyosarcoma, especially primary vascular leiomyosarcoma in the extremities (34,48). Right atrial myxoma only occurs in the heart chamber with a stalk and may attach to the walls of the cardiac chambers and not affect the inferior vena cava, while IVL, typically originating from the uterus, has a serpentine appearance, with iliac or ovarian vein extension into the inferior vena cava and right atrium. Renal cell carcinoma is the most common tumor that can invade the inferior vena cava and right atrium of the heart, and should be distinguished from IVL by postoperative pathological examination (49).

7. Treatment and prognosis

The age of the patient, fertility status and extent of the lesion involvement must be considered in the treatment of IVL. Tumor removal and prevention of recurrence are the main aims of IVL treatment. Surgical treatment and antiestrogen therapy are the most common treatment choices for patients with IVL (50,51).

Surgery. Although there is no current consensus on clinical guidelines established for the treatment of IVL, a complete tumor resection is the recommended course for most patients with IVL, and resection of IVL tumors has been performed in almost all types of organ, including intra-pelvic and extra-pelvic organs (52).

A preoperative staging system has been proposed by Ma *et al* (53), which reflects intravascular tumor progression before surgery and facilitates the option of different surgical strategies in patients with IVL. Stage I is defined by tumors that penetrate the uterine venous wall, but are confined to the pelvic cavity; stage II reflects tumors that extend into the abdominal cavity, but have not grown into the renal vein; stage III refers to tumors that reach the renal vein, inferior vena cava and even further into the right atrium, but have not yet extended into the pulmonary arteries; and stage IV refers to tumors that grow into the pulmonary arteries and/or those with lung metastases. Based on these four stages, different surgical strategies have been provided. Total tumor resection, hysterectomy and bilateral salpingo-oophorectomy (BSO) are suggested for patients in stage I. Complete tumor resection, abdominal hysterectomy and BSO are also recommended for patients graded as stage II or above. These surgeries require the cooperation of gynecologists and vascular surgeons. For patients in stages III or IV, cardiopulmonary bypass (CPB) is necessary to prevent massive hemorrhage during tumor resection. Two surgical procedures are recommended for patients with lesions involving the cardiovascular system, especially those with severe hemodynamic dysfunction or with large tumors strongly adhered to surrounding tissue (54,55); in general, patients first receive the resection of the intracardiac component, followed by resection of the remaining intra-abdominal tumor. The interval between the first and second operations ranges from 7 days to 2 years (51,56). Due to the current understanding of IVL and improved technical abilities, a one-stage resection of intracardiac leiomyomatosis using a single laparotomy is also feasible; this is cost-effective and could avoid tumor embolism and progression during the interval between the two surgical stages (24,57,58).

Further classification of IVCL has been proposed for individualized surgical treatment of IVCL cases (59). Types A, B, C, D or E were classified depending on the tumor size and extension of IVCL. Type A IVCL refers to tumors in which the maximal diameters of both the intracardiac and intracaval sections of the tumor are smaller than the minimum diameter of the inferior vena cava. A single laparotomy is suggested for patients with type A IVCL. Type B refers to tumors in which the maximal diameter of the intracardiac section of the IVCL is greater than the minimum diameter of the inferior vena cava. For patients with this type of IVCL, right atriotomy with CPB and deep hypothermic arrest to remove the tumor, as well as an abdominal procedure that includes removal of the pedicle of the tumor in the internal iliac or ovarian vein, adnexectomy or hysterectomy is suggested. Type C refers to tumors in which the maximal diameter of the intracaval section of the IVCL is greater than the minimum diameter of the inferior vena cava, and is the most common type of IVCL. Sternolaparotomy and CPB are required for these patients. Type D refers to tumors that are in two separate segments. One originates from the ovarian or iliac vein, and another from the retrohepatic inferior vena cava intima. Type E refers to tumors that belong to any of the aforementioned types accompanied by pulmonary embolism. Due to the rareness of types D and E, individualized treatment approaches are recommended (59).

Overall, complete resection of the tumor plus BSO is considered the optimal and most efficient treatment option, which is a crucial part of preventing recurrences. Strategies and approaches to surgery should be individualized according to the tumor diameter, degree of abdominal and pelvic adhesion, and degree of obstruction caused by the IVCL. When IVL involves the heart cavity, the surgical options include one-stage and two-stage surgery, both of which have advantages and disadvantages, and the best surgical method is still controversial.

Anti-estrogen hormone therapies. IHC results have identified positive expression of ER and PR in IVL (60,61). Due to this estrogen-dependent characteristic of IVL, estrogen deprivation therapy is suggested to be another choice for those patients who cannot undergo complete primary removal (62). Gonadotrophin-releasing hormone agonist (GnRHa) administration before surgery in a premenopausal case was reported to shrink the volume of myoma, raising the possibility of positive surgical intervention (63). The perioperative complications could also be efficiently reduced by applying estrogen deprivation therapies preoperatively, considering that the intraoperative blood loss is 7.5 times higher in patients with IVCL compared with that in patients with IVL and tumors are confined to the abdominal cavity (53). In addition, GnRHa has also been administered postoperatively to prevent recurrence after incomplete resections (5,62,64). In one case, a 30-year-old woman developed a pulmonary embolism and multiple nodules of the lungs after postoperatively receiving GnRHa for 6 months. No progression of the pulmonary nodules was found (65). However, the duration and benefits of this approach are still controversial (50). In a number of premenopausal women who received complete tumor resection, the administration of GnRHa postoperatively was found to have limited effects and even lead to a small amount of growth in the residual tumors of the patients (66). The side effects of long-term therapy with GnRHa, including reduced bone mineral density, vasomotor symptoms and altered lipid profile, deserve serious consideration (67). Other hormonal therapies include selective ER modulators (SERMs) and aromatase inhibitors. Tamoxifen and raloxifene, as typical SERMs, are used as both monotherapy and adjuvant treatments for IVL (68). However, an analysis of 194 cases of IVL demonstrated that postoperative tamoxifen treatment did not help to prevent recurrence (49). Therefore, the effectiveness of GnRHa and other hormonal therapies in the adjuvant treatment of IVL still requires investigation and large samples of clinical cases. Further research is still required for using hormone therapy in patients with IVL.

8. Follow-up and prognosis

The recurrence rate of the IVL varies among different studies. Yu *et al* (69) reported a recurrence rate of 31.0% in 58 patients. In a comprehensive analysis of 194 cases of IVL, no recurrence or postoperative mortality was reported in patients who undewent complete tumor removal. However, for those who underwent an incomplete removal, the recurrence rate was 33.3%, and 4 patients died during the follow-up period (49). Incomplete surgical tumor resection and large vein involvement are the critical risk factors for recurrence. In a recent retrospective single-center study, compared with patients diagnosed non-incidentally and undergoing a complete tumor resection, those patients diagnosed incidentally were reported to have a higher risk of recurrence. A total of 5 (12.8%) cases in the incidental group were reported to have recurrence, while no recurrence was found among the 24 patients who are non-incidentally diagnosed (7). There are several reasons that may explain this result. Firstly, the incidentally diagnosed patients may have an inadequate evaluation without further imaging examination, such as echocardiography. Secondly, the surgery of these patients could also be insufficient, which would result in residual tumors and recurrence. For patients diagnosed non-incidentally, further evaluation could be conducted to identify the details of the IVL before the operation, including use of CT, MRI and transesophageal echocardiography (7,53). Furthermore, a multidisciplinary team usually participates in the surgery of patients diagnosed non-incidentally but not in the surgery being performed by gynecologists only (39). Overall, this medical evidence highlights the importance of extra-pelvic imaging and multidisciplinary surgical treatment.

Long-term follow-up is necessary for patients with IVL, especially those who have an incomplete tumor resection and preservation of the uterus and ovaries. Although there is no standard recommendation for the time and imaging modalities of follow-up, indications are for a follow-up every 3-6 months for the first 2 years after surgery and then every 12 months after that (32). A CT scan of the chest, abdomen and pelvis is necessary. When the CT scan is not available, an ultrasound of the peritoneal cavity, retroperitoneal space and pelvic cavity, including transvaginal and transanal examinations, is recommended (3). Furthermore, if any symptoms associated with thromboembolic events occur, a Doppler ultrasound assessment of the corresponding vein, such as the inferior vena cava, iliac vessels and veins of the lower limbs, is vital to identify the progress of the disease (52).

9. Conclusions

In summary, IVL is a rare and unique benign smooth muscle tumor with the potential to be malignant. Due to the non-specific clinical manifestations, it is challenging for clinicians to diagnose IVL before surgery. However, intracardiac IVL must be considered in fertile women with a history of uterine leiomyomatosis when the patient has a mobile mass in the right atrium and inferior vena cava without attachment to the endothelium or the endocardium. Imaging modalities, such as ultrasonography, CT and MRI, are useful in displaying the precise location and full-scale extension path of the tumor before surgery. The primary treatment approach remains as surgery with a complete tumor resection, which is the key to avoiding recurrence. The final diagnosis also depends on the histopathological analysis after surgery. The surgical procedure should be considered carefully depending on the general condition of the patient, the tumor diameter, the degree of abdominal and pelvic adhesion, and the degree of obstruction. A thorough preoperative assessment and intraoperative collaboration in a multi-disciplinary setting are important for good patient outcomes. The application of hormone therapies is still controversial and needs the support of further large-scale clinical data. The unique molecular profile of IVL has been investigated at different levels and further analysis is required for an improved understanding of the pathogenesis of IVL (Figure 2). The DEGs and tumor stem-like cells in IVL could provide insights for the development of new therapeutic and diagnostic approaches. Furthermore, long-term follow-up is necessary for patients with IVL.

Acknowledgements

Not applicable.

Funding

No funding was received.

Availability of data and materials

Not applicable.

Authors' contributions

XTZ and FY designed and organized this manuscript. XTZ contributed to the first draft of the manuscript, tables and figures. XRQ and XZ revised the manuscript. All authors have read and approved the manuscript. Data authentication is not applicable.

Ethics approval and consent to participate

Not applicable.

Patient consent for publication

Not applicable.

Competing interests

The authors declare that they have no competing interests.

References

1. Ahmed M, Zangos S, Bechstein WO and Vogl TJ: Intravenous leiomyomatosis. Eur Radiol 14: 1316-1317, 2004.
2. Birch-Hirschfeld FV: Textbook of pathological anatomy. FCW Vogel, Leipzig, p226, 1896 (In German).
3. Lim WH, Lamaro VP and Sivagnanam V: Manifestation and management of intravenous leiomyomatosis: A systematic review of the literature. Surg Oncol 45: 101879, 2022.
4. Findakly D and Wang J: Molecular profiling of benign metastasizing leiomyoma of the uterus revealing unique novel therapeutic targets. Cureus 12: e7701, 2020.
5. Low HY, Zhao Y, Huang KS, Shen HP, Wu PJ and Tseng CJ: Intravenous leiomyomatosis of the uterus: A clinicopathological analysis of nine cases and literature review. Taiwan J Obstet Gynecol 56: 362-365, 2017.
6. Kang LQ, Zhang B, Liu BG and Liu FH: Diagnosis of intravenous leiomyomatosis extending to heart with emphasis on magnetic resonance imaging. Chin Med J (Engl) 125: 33-37, 2012.
7. Shi P, Xiao H, Li H, Tang W, Ren A, Ma L, Tu R, Yin S and Zhang J: Management and prognosis comparison between incidental and nonincidental intravenous leiomyomatosis: A retrospective single-center real-life experience. Ann Transl Med 10: 503, 2022.
8. Hayashi T, Yaegashi N and Konishi I: Molecular pathological approach of uterine intravenous leiomyomatosis. Ann Transl Med 10: 724, 2022.
9. Grimer RJ and Armstrong GR: Intra-vascular leiomyoma of the popliteal vein. Postgrad Med J 64: 247-248, 1988.
10. Hansson B, Bogers J, Colpaert C, De Roeck J, De Backer A, Ceulemans P, De Maeseneer M and Hubens G: Leiomyoma of the right common iliac vein presenting as a duodenal tumour. Eur J Surg Oncol 26: 717-719, 2000.
11. Fang H, You Y, Cai F, Yang Y, Yang C and Lv P: Intravenous leiomyomatosis of the subclavian vein. J Vasc Surg Venous Lymphat Disord 5: 254-256, 2017.
12. Gui T, Qian Q, Cao D, Yang J, Peng P and Shen K: Computerized tomography angiography in preoperative assessment of intravenous leiomyomatosis extending to inferior vena cava and heart. BMC Cancer 16: 73, 2016.
13. Miro A, Bottazzi EC, Vanella S, Palma T, Noviello A, Apicella I, Lombardi G, Fiorani B and Crafa F: Intravascular leiomyomatosis with intracardiac extension: A toraco-abdominal approach. J Surg Case Rep 202: rjab249, 2021.
14. Ordulu Z, Nucci MR, Cin PD, Hollowell ML, Otis CN, Hornick JL, Park PJ, Kim TM, Quade BJ and Morton CC: Intravenous leiomyomatosis: An unusual intermediate between benign and malignant uterine smooth muscle tumors. Mod Pathol 29: 500-510, 2016.
15. Zhang X, Wu L, Xu R, Zhu C, Ma G, Zhang C, Liu X, Zhao H and Miao Q: Identification of the molecular relationship between intravenous leiomyomatosis and uterine myoma using RNA sequencing. Sci Rep 9: 1442, 2019.
16. Wang W, Wang Y, Chen F, Zhang M, Jia R, Liu X, Zhang C, Shao J, Cheng N, Ma G, *et al*: Intravenous leiomyomatosis is inclined to a solid entity different from uterine leiomyoma based on RNA-seq analysis with RT-qPCR validation. Cancer Med 9: 4581-4592, 2020.
17. Rein MS, Friedman AJ, Barbieri RL, Pavelka K, Fletcher JA and Morton CC: Cytogenetic abnormalities in uterine leiomyomata. Obstet Gynecol 77: 923-926, 1991.
18. Schoenmakers EF, Wanschura S, Mols R, Bullerdiek J, Van den Berghe H and Van de Ven WJ: Recurrent rearrangements in the high mobility group protein gene, HMGI-C, in benign mesenchymal tumours. Nat Genet 10: 436-444, 1995.
19. Ordulu Z, Chai H, Peng G, McDonald AG, De Nictolis M, Garcia-Fernandez E, Hardisson D, Prat J, Li P, Hui P, *et al*: Molecular and clinicopathologic characterization of intravenous leiomyomatosis. Mod Pathol 33: 1844-1860, 2020.
20. Buza N, Xu F, Wu W, Carr RJ, Li P and Hui P: Recurrent chromosomal aberrations in intravenous leiomyomatosis of the uterus: High-resolution array comparative genomic hybridization study. Hum Pathol 45: 1885-1892, 2014.
21. Matsubara A, Sekine S, Yoshida M, Yoshida A, Taniguchi H, Kushima R, Tsuda H and Kanai Y: Prevalence of MED12 mutations in uterine and extrauterine smooth muscle tumours. Histopathology 62: 657-661, 2013.
22. Wang L, Hu S, Xin F, Zhao H, Li G, Ran W, Xing X and Wang J: MED12 exon 2 mutation is uncommon in intravenous leiomyomatosis: Clinicopathologic features and molecular study. Hum Pathol 99: 36-42, 2020.
23. Krasny L, Wilding CP, Perkins E, Arthur A, Guljar N, Jenks AD, Fisher C, Judson I, Thway K, Jones RL and Huang PH: Proteomic profiling identifies co-regulated expression of splicing factors as a characteristic feature of intravenous leiomyomatosis. Cancers (Basel) 14: 2907, 2022.
24. Cassol DF, Junior FJRT, Dias do Couto Netto S, Rengel LC, Ragazzo L, Gaiotto FA and Utiyama EM: Symptomatic uterine leiomyomatosis with intracaval and intracardiac invasion: Video case report. Gynecol Oncol Rep 45: 101127, 2023.
25. Lan S, Wang X, Li Y and Zhai M: Intravenous leiomyomatosis: A case study and literature review. Radiol Case Rep 17: 4203-4208, 2022.
26. Peng J, Zhong F, Zhu Y, Zhang M, Zhang M, Lu C, Wang Y, Qi X, Wang C and Li G: Clinical analysis of uterine intravenous leiomyomatosis: A retrospective study of 260 cases. J Obstet Gynaecol Res 47: 4357-4364, 2021.
27. Jin X, Li F, Lu Z and Cheng W: IV Leiomyomatosis on FDG PET/CT. Clin Nucl Med 41: 580-582, 2016.
28. Barksdale J, Abolhoda A and Saremi F: Intravenous leiomyomatosis presenting as acute Budd-Chiari syndrome. J Vasc Surg 54: 860-863, 2011.
29. Deng Y and Song B: Three case reports of intravenous leiomyomatosis with intracardiac extensions. Thorac Cardiovasc Surg Rep 9: e40-e43, 2020.
30. Luo X, Li R and Li Z: Combined transthoracic echocardiography and contrast-enhanced ultrasonography to trace intravenous leiomyomatosis with intracardiac extension. Echocardiography 36: 1573-1576, 2019.
31. Lam PM, Lo KW, Yu MY, Wong WS, Lau JY, Arifi AA and Cheung TH: Intravenous leiomyomatosis: Two cases with different routes of tumor extension. J Vasc Surg 39: 465-469, 2004.
32. Zhang G, Yu X, Shi H, Fan Q, Lang J and Liu B: Clinical characteristics and prognostic features of intravenous leiomyomatosis with inferior vena cava or intracardiac extension. J Vasc Surg Venous Lymphat Disord 5: 485-492, 2017.
33. Ma H, Niu Y, Yang Z and Zheng M: Echocardiographic characteristics and contrast-enhanced imaging of intravenous leiomyomatosis with intracardiac extension. J Ultrasound Med 41: 1101-1108, 2022.
34. Ge Z, Wang Y, Wang Y, Fang S, Wang H and Li J: Diagnostic value of contrast-enhanced ultrasound in intravenous leiomyomatosis: A single-center experiences. Front Oncol 12: 963675, 2022.

35. Wang H, Nie P, Chen B, Hou F, Dong C, He F and Xu W: Contrast-enhanced CT findings of intravenous leiomyomatosis. Clin Radiol 73: 503 e1-503 e6, 2018.
36. Peng HJ, Zhao B, Yao QW, Qi HT, Xu ZD and Liu C: Intravenous leiomyomatosis: CT findings. Abdom Imaging 37: 628-631, 2012.
37. Zeng H, Xu Z, Zhang L, Luo YI, Chen H, Zhu H, Peng L and Yu J: Intravenous leiomyomatosis with intracardiac extension depicted on computed tomography and magnetic resonance imaging scans: A report of two cases and a review of the literature. Oncol Lett 11: 4255-4263, 2016.
38. Shao J, Wang C, Shu K, Zhou Y, Cheng N, Lai Z, Li K, Xu L, Chen J, Du F, *et al*: A contrast-enhanced CT-based radiomic nomogram for the differential diagnosis of intravenous leiomyomatosis and uterine leiomyoma. Front Oncol 13: 1239124, 2023.
39. Yu X, Fu J, Cao T, Huang L, Qie M and Ouyang Y: Clinicopathologic features and clinical outcomes of intravenous leiomyomatosis of the uterus: A case series. Medicine (Baltimore) 100: e24228, 2021.
40. Wei JL, Ji X, Zhang P, Chen WJ, Zhao YN and Liu M: Complete intravenous leiomyomatosis: A case report and literature review. Ann Palliat Med 10: 12039-12045, 2021.
41. Du J, Zhao X, Guo D, Li H and Sun B: Intravenous leiomyomatosis of the uterus: A clinicopathologic study of 18 cases, with emphasis on early diagnosis and appropriate treatment strategies. Hum Pathol 42: 1240-1246, 2011.
42. Bartolazzi A, Peach R, Aruffo A and Stamenkovic I: Interaction between CD44 and hyaluronate is directly implicated in the regulation of tumor development. J Exp Med 180: 53-66, 1994.
43. Chen MJ, Peng Y, Yang YS, Huang SC, Chow SN and Torng PL: Increased hyaluronan and CD44 expressions in intravenous leiomyomatosis. Acta Obstet Gynecol Scand 84: 322-328, 2005.
44. Tamura S, Hayashi T, Tokunaga H, Yaegashi N, Abiko K and Konishi I: Oncological properties of intravenous leiomyomatosis: Involvement of mesenchymal tumor stem-like cells. Curr Issues Mol Biol 43: 1188-1202, 2021.
45. Sherr CJ and McCormick F: The RB and p53 pathways in cancer. Cancer Cell 2: 103-112, 2002.
46. Peurala E, Koivunen P, Haapasaari KM, Bloigu R and Jukkola-Vuorinen A: The prognostic significance and value of cyclin D1, CDK4 and p16 in human breast cancer. Breast Cancer Res 15: R5, 2013.
47. Sungur EC, Selçuk İ, Özbek HM, Aytekin O, Köklü NO, Turhan N, Talay S, Sarıtaş A and Yalçın HR: Extrapelvic intravenous uterine leiomyomatosis mimicing cardiac myxoma and deep vein thrombosis. Turk Gogus Kalp Damar Cerrahisi Derg 30: 622-626, 2022.
48. Yokoyama Y, Goda T, Sato K, Suzuki M, Kanda T and Sato Y: Leiomyosarcoma arising from the ovarian vein as a gynecologic malignancy: Two case reports and a review of the literature. J Obstet Gynaecol Res 48: 2224-2230, 2022.
49. Li B, Chen X, Chu YD, Li RY, Li WD and Ni YM: Intracardiac leiomyomatosis: A comprehensive analysis of 194 cases. Interact Cardiovasc Thorac Surg 17: 132-138, 2013.
50. Liang J, Lei R, Xie M, Lin S, Xu J, Ling X and Xie Q: The role of estrogen deprivation therapy in premenopausal women with primary unresectable intracardiac leiomyomatosis: A systematic review and meta-analysis. Orphanet J Rare Dis 16: 453, 2021.
51. Li H, Xu J, Lin Q, Zhang Y, Zhao Y, Tong H, Tu R, Xu D, Wang C and Lu W: Surgical treatment strategies for extra-pelvic intravenous leiomyomatosis. Orphanet J Rare Dis 15: 153, 2020.
52. Stilidi I, Paianidi J, Bokhian V, Andreeva J, Shevchuk A and Ramirez PT: Intracardiac intravenous leiomyomatosis: Diagnosis and management. Int J Gynecol Cancer 30: 1243-1247, 2020.
53. Ma G, Miao Q, Liu X, Zhang C, Liu J, Zheng Y, Shao J, Cheng N, Du S, Hu Z, *et al*: Different surgical strategies of patients with intravenous leiomyomatosis. Medicine (Baltimore) 95: e4902, 2016.
54. Yang C, Fang H, Yang Y, Cai F, Zheng H, Jin B, Li Y, Liu Z and Zayed MA: Diagnosis and surgical management of inferior vena cava leiomyomatosis. J Vasc Surg Venous Lymphat Disord 6: 636-645, 2018.
55. Gissey LC, Mariano G, Musleh L, Lepiane P, Colasanti M, Meniconi RL, Ranocchi F, Musumeci F, Antonini M and Ettorre GM: Massive pelvic recurrence of uterine leiomyomatosis with intracaval-intracardiac extension: Video case report and literature review. BMC Surg 17: 118, 2017.
56. Luo G, Pan H, Bi J, Luo Y, Zhu J, Feng Z, Fan H, Zhang Y and Dai X: Surgical treatment of intravenous leiomyomatosis involving the right heart: A case series. J Int Med Res 47: 3465-3474, 2019.
57. Price JD, Anagnostopoulos C, Benvenisty A, Kothuru RK and Balaram SK: Intracardiac extension of intravenous leiomyomatosis. Ann Thorac Surg 103: e145-e147, 2017.
58. Wang C, Shao J, Ma X, Zhou Y, Ma G, Cheng N, Cao D, Lai Z, Song X, Li K and Liu B: One-stage resection of intravascular leiomyomatosis involving the right heart chamber through a single laparotomy. Front Cardiovasc Med 9: 976478, 2022.
59. Liu J, Liang M, Ma G, Liu X, Cheng N, Cao D, Yu C, Du S, Miao Q and Zhang C: Surgical treatment for intravenous-cardiac leiomyomatosis. Eur J Cardiothorac Surg 54: 483-490, 2018.
60. Kokawa K, Yamoto M, Yata C, Mabuchi Y and Umesaki N: Postmenopausal intravenous leiomyomatosis with high levels of estradiol and estrogen receptor. Obstet Gynecol 100: 1124-1126, 2002.
61. Akinseye OA, Nayyar M and Das P: Uterine intravenous leiomyomatosis with femoral vein, intracaval, intracardiac and pulmonary artery extension. Future Cardiol 16: 27-32, 2020.
62. Mitsuhashi A, Nagai Y, Sugita M, Nakajima N and Sekiya S: GnRH agonist for intravenous leiomyomatosis with cardiac extension. A case report. J Reprod Med 44: 883-886, 1999.
63. Khayata GM, Thwaini S and Aswad SG: Intravenous leiomyomatosis extending to the heart. Int J Gynaecol Obstet 80: 59-60, 2003.
64. Mizoguchi C, Matsumoto H, Nasu K, Arakane M, Kai K and Narahara H: Intravenous leiomyomatosis treated with radical hysterectomy and adjuvant aromatase inhibitor therapy. J Obstet Gynaecol Res 42: 1405-1408, 2016.
65. Bodner-Adler B, Bartl M and Wagner G:Intravenous leiomyomatosis of the uterus with pulmonary metastases or a case with benign metastasizing leiomyoma? Anticancer Res 29: 495-496, 2009.
66. Hameleers JA, Zeebregts CJ, Hamerlijnck RP, Elbers JR and Hameeteman TM: Combined surgical and medical approach to intravenous leiomyomatosis with cardiac extension. Acta Chir Belg 99: 92-94, 1999.
67. Doyle MP, Li A, Villanueva CI, Peeceeyen SC, Cooper MG, Hanel KC, Fermanis GG and Robertson G: Treatment of intravenous leiomyomatosis with cardiac extension following incomplete resection. Int J Vasc Med 2015: 756141, 2015.
68. Lo KW and Lau TK: Intracardiac leiomyomatosis. Case report and literature review. Arch Gynecol Obstet 264: 209-210, 2001.
69. Yu X, Zhang G, Lang J, Liu B and Zhao D: Factors associated with recurrence after surgical resection in women with intravenous leiomyomatosis. Obstet Gynecol 128: 1018-1024, 2016.