SPANDIDOS PUBLICATIONS

ONCOLOGY LETTERS 27: 39, 2024

Breast carcinoma arising in a fibroadenoma: A case series of 16 patients and review of the literature

LIANG XU[1*], SHUYA LUO[2*], QIXIN MAO[3], YUFENG GAO[1], LIHUA LUO[1], WEI QU[4] and YALI CAO[1]

[1]Prevention and Cure Center of Breast Disease; [2]Outpatient Department, The Third Hospital of Nanchang City, Nanchang, Jiangxi 330009; [3]Department of Breast Disease, Henan Breast Cancer Center, The Affiliated Cancer Hospital of Zhengzhou University & Henan Cancer Hospital, Zhengzhou, Henan 450002; [4]Department of Pathology, The Third Hospital of Nanchang City, Nanchang, Jiangxi 330009, P.R. China

Received February 18, 2023; Accepted September 25, 2023

DOI: 10.3892/ol.2023.14172

Abstract. Breast carcinoma arising from a fibroadenoma is an uncommon entity and is frequently detected incidentally during pathological examination or excisional biopsy of a benign breast tumor. Due to only sporadic cases being reported, evidence-based guidelines are not well-established to date. The present report describes 16 patients diagnosed with breast carcinoma arising within a fibroadenoma in the Third Hospital of Nanchang (Nanchang, China) between January 2019 and December 2021 and discusses the clinicopathological characteristics, imaging findings and treatment. The age of patients at diagnosis ranged between 19 and 58 years and a well-defined asymptomatic mass was the most common clinical presentation. Carcinoma occurring in fibroadenoma generally mimics a benign tumor and potential carcinomatous changes may not be detected. Pathologically, carcinoma *in situ* was the predominant subtype in the present study. Additionally, ductal carcinoma *in situ* was more common compared with lobular carcinoma *in situ* in the present case series. Regarding the molecular phenotypes, the majority of cases were categorized as luminal subtype, although other subtypes such as triple-negative and HER2 positive breast cancer were also identified. In the present study, seven patients were treated with breast-conserving surgery and nine patients were treated with mastectomy. Sentinel lymph node biopsy was performed in all patients and none exhibited axillary node metastasis. Additionally, six patients underwent radiotherapy and two received chemotherapy. During the follow-up, all patients were alive and no evidence of disease relapse was observed. In summary, clinicians should be aware of the possibility of carcinoma within a fibroadenoma, which could alter the therapeutical course. Adequate biopsy or excision should be performed in patients with indicators of malignant transformation in a presumed benign breast tumor.

Correspondence to: Professor Wei Qu, Department of Pathology, The Third Hospital of Nanchang City, 2 South Xiangshan Road, Xihu, Nanchang, Jiangxi 330009, P.R. China
E-mail: quwei6616917@163.com

Professor Yali Cao, Prevention and Cure Center of Breast Disease, The Third Hospital of Nanchang City, 2 South Xiangshan Road, Xihu, Nanchang, Jiangxi 330009, P.R. China
E-mail: 84985540@qq.com

[*]Contributed equally

Key words: carcinoma *in situ*, breast cancer, fibroadenoma, benign fibroepithelial tumor, immunohistochemistry, surgery

Introduction

Fibroadenoma is the most common benign tumor diagnosed in the breast, with a peak incidence in the female in their 20s and 30s worldwide (1,2). In principle, an asymptomatic fibroadenoma can be managed conservatively with regular breast imaging follow-up; however, in clinical practice, it may not be an optimal choice if the mass is enlarged or other atypical symptoms are present (3). Carcinoma arising in a fibroadenoma of the breast can be diagnosed by incidental biopsy or excision although it is present in only 0.1-0.3% of all cases (4).

To the best of our knowledge, only sporadic case reports and case series with a small sample size describing breast carcinoma occurring within a fibroadenoma have been published (3,5). Breast carcinoma arising within a fibroadenoma includes lobular carcinoma *in situ* (LCIS), ductal carcinoma *in situ* (DCIS) and, rarely, invasive carcinoma (6). Non-invasive breast carcinomas are more commonly found than invasive breast carcinomas (7). An epithelial malignancy within a fibroadenoma often mimics the features of a fibroadenoma clinically and radiologically; therefore, early detection remains clinically challenging. Although radiological examinations such as ultrasonography and mammography are valuable in diagnosing fibroadenoma, malignancy within a fibroadenoma may be indistinguishable from benign fibroadenoma on imaging (5). Moreover, few reports have documented the transition from fibroadenoma to breast cancer and little is known about its clinicopathological features and prognosis (5,8). To the best of our knowledge, no evidence-based guidelines for diagnosis and treatment of breast carcinoma arising within a fibroadenoma exist due to its low incidence rate. The present study reviews the literature and discusses

the clinicopathological features and treatments of patients with breast carcinoma arising from a fibroadenoma diagnosed at The Third Hospital of Nanchang City (Nanchang, China) between January 2019 and December 2021.

Materials and methods

Patients. Between January 2019 and December 2021, 6,558 of breast carcinoma were admitted to The Third Hospital of Nanchang City (Nanchang, China). Of them, 6,550 cases were female. All cases diagnosed as breast carcinoma *in situ* or invasive carcinoma arising within fibroadenoma were included. All histopathological slides were reviewed by two pathologists independently to confirm the diagnosis. Data such as age, sex, menopausal status, primary complaint and treatment were also collected.

Pathological examination. All available hematoxylin and eosin (H&E)-stained breast carcinoma arising within a fibroadenoma sections were reviewed by two independent pathologists. Tumor morphology was assessed using recently described criteria (9), including nuclear grade, mitotic rate, presence and extent of associated carcinoma *in situ* and invasive carcinoma. Immunohistochemistry was performed on paraffin-embedded 4 μm tissue slides as described previously and fixed in 10% formalin for 6 h at room temperature (10). First incubate the slides at 65˚C for 2 h, and then deparaffinize twice for 5 min. Antigen retrieval solution (10 mmol/l tris; 1 mmol/LEDTA; pH9.0) was 100˚C for 5 min and blocked with 2% sheep serum (Biyangtian Biotechnology Research Institute) at room temperature. The slides were then incubated with primary antibodies overnight at 4˚C and with horseradish peroxidase-labeled secondary antibodies and DAB for 1 h at 37˚C. Tumor immunoreactivity was assessed independently by two pathologists. In addition, human epidermal growth factor receptor 2 (HER2) was detected by immunohistochemistry (IHC) and fluorescence *in situ* hybridization (FISH) according to the latest HER2 testing recommendations from the American Society of Clinical Oncology and the College of American Pathologists. Status is determined. Breast Cancer 2018 (11). FISH analysis was performed as previously reported (12).

Follow-up. All patients are followed up regularly every 3-6 months at the Breast Disease Prevention and Treatment Center of Nanchang Third Hospital Routine physical and radiological examinations were performed to monitor recurrence and metastasis. The last date of follow-up was September 30, 2022.

Table I. Clinicopathological characteristics of breast carcinoma arising in a fibroadenoma.

Characteristic	Value
Age at diagnosis, years (%)	
<35	5 (31.3)
35-50	10 (62.5)
>50	1 (6.3)
Median age (range), years	45.0 (19.0-58.0)
Sex (%)	
Male	0 (0.0)
Female	16 (100.0)
Clinical presentation (%)	
Mass	14 (87.5)
Nipple discharge	1 (6.3)
Laterality (%)	
Left	8 (50.0)
Right	8 (50.0)
Bilateral	0 (0.0)
Fibroadenoma diameter, cm (%)	
≤2	6 (37.5)
2-3	8 (50.0)
>3	2 (12.5)
Mean fibroadenoma diameter (range), cm	2.2 (1.0-3.7)
Malignant component subtype (%)	
DCIS	10 (62.5)
LCIS	2 (12.5)
IDC	3 (18.8)
ILC	1 (6.3)
T stage (%)	
Tis	12 (75.0)
T1	4 (25.0)
T2	0 (0.0)
T3	0 (0.0)
T4	0 (0.0)
Axillary lymph node involvement (%)	
Yes	0 (0.0)
No	16 (100.0)

T stage was classified according to the greatest dimension of malignant components within the fibroadenoma. DCIS, ductal carcinoma *in situ*; LCIS, lobular carcinoma *in situ*; IDC, invasive ductal carcinoma; ILC, invasive lobular carcinoma; T, tumor; Tis, tumor *in situ*.

Results

Clinical and pathological findings. Between January 2019 and December 2021, 16 patients were diagnosed with carcinoma arising in a fibroadenoma at The Third Hospital of Nanchang City. The age at diagnosis ranged between 19 and 58 years (median, 45 years). All patients were female and most were premenopausal (87.5%). The most common initial clinical presentation was an asymptomatic palpable mass (87.5%), followed by nipple discharge (6.3%). Notably, two patients (12.5%) presented because of abnormal imaging changes of fibroadenoma during follow-up (Table I).

Consistent with a previous study (13), a small malignant tumor arising in a relatively large fibroadenoma was observed in 14 cases (87.5%). The mean tumor size (diameter of fibroadenoma containing the malignant component) ranged between 1.0 and 3.7 cm (mean, 2.2 cm). However, the malignant component in 12 of cases was non-invasive (75%). Thus, the majority of cases in the present study were tumor *in situ* (Tis) according to the latest TNM staging system (75%; Table I) (14).

Table II. Immunohistochemical analysis.

Immunohistochemical marker	n (%)
ER status	
Positive	15 (93.8)
Negative	1 (6.3)
PR status	
Positive	14 (87.5)
Negative	2 (12.5)
HER2 status	
-	3 (18.8)
1+	3 (18.8)
2+	8 (50.0)
3+	2 (12.5)
Ki67, %	
≤14	12 (75.0)
>14	4 (25.0)
Molecular subtype	
Luminal A	10 (62.5)
Luminal B	5 (31.3)
HER2 overexpression	0 (0.0)
TNBC	1 (6.3)

A total of two cases positive for HER2 were classified as Luminal B subtype because they were HR-positive. ER, estrogen receptor; PR, progesterone receptor; HER2, human epidermal growth factor receptor 2; TNBC, triple-negative breast cancer.

Table III. Treatment of breast carcinoma arising in a fibroadenoma.

Treatment	n (%)
Surgery	
BCS or lumpectomy	7 (43.8)
Mastectomy	9 (56.3)
Surgery of axillary lymph nodes	
SLNB	16 (100)
ALND	0 (0.0)
Chemotherapy	
Yes	2 (12.5)
No	14 (87.5)
Radiotherapy	
Yes	6 (37.5)
No	10 (62.5)
Endocrine therapy	
Yes	15 (93.8)
No	1 (6.3)
HER2-targeted therapy	
Yes	1 (6.3)
No	15 (93.8)

BCS, breast conserving surgery; SLNB, sentinel lymph node biopsy; ALND, axillary lymph node dissection; HER2, human epidermal growth factor receptor-2.

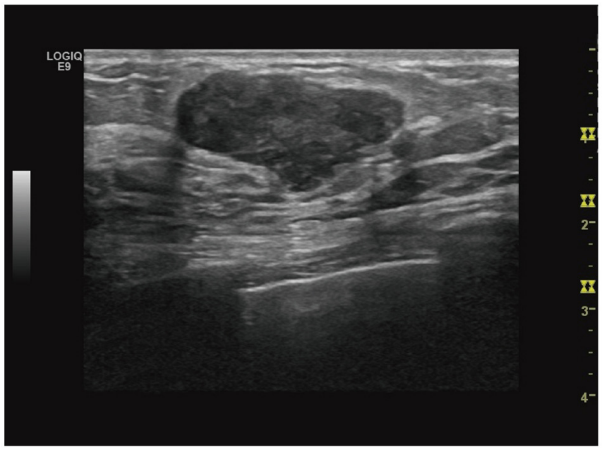

Figure 1. Ultrasonography of breast carcinoma arising within a fibroadenoma. A 26 mm large tumor in a 47-year-old female. Ultrasound examination revealing a regular and well-circumscribed hypoechoic mass.

Fibroadenoma harboring a carcinoma mimics benign fibroepithelial tumor radiologically. Ultrasonography revealed a circumscribed, homogenous, isoechoic or hypoechoic mass (Fig. 1). A total of 5 cases (31.3%) were categorized as breast imaging-reporting and data system (15) (BI-RADS) 4 on ultrasonography in the present study which indicated suspicious malignancy. Mammography findings were similar to those of benign tumors and revealed a lobulated well-defined mass. However, several indicators of malignant transformation, including indistinct borders and microcalcifications, were observed in three cases (18.8%) (16).

Diagnosis, treatment and survival. In the present study, all cases received core needle or vacuum-assisted biopsy or excision to make a diagnosis. Pathologically, carcinoma *in situ* was more common than invasive carcinoma, with 12 non-invasive cases (75%) and four invasive cases (25%; Fig. 2A and B). Furthermore, DCIS was more common than LCIS (Table II; Fig. 2C and D). Invasive ductal and lobular carcinoma were diagnosed in three (81.3%) and one case (93.8%), respectively (Fig. 2E and F). When breast carcinoma arising within a fibroadenoma is suspected, immunohistochemical analysis (such as CK5/6 and α-SMA) is performed to confirm the diagnosis (Fig. S1). In immunohistochemical analyses, the majority of cases were hormone receptor (HR)-positive (15 cases, 93.8%) and HER2-negative (14 cases, 87.5%; Fig. 3A-C). Regarding molecular subtypes, luminal A and B, HER2-positive and triple-negative subtypes accounted for 10 (62.5%), 5 (31.3%), 1 (6.3%) and 0 (0.0%) cases, respectively.

Once the tumor was confirmed to be malignant, breast-conserving surgery (BCS) as well as sentinel lymph node biopsy (SLNB) were advised. A total of seven patients (43.6%) received BCS and nine patients (56.3%) received mastectomy (Table III). SLNB was performed in all cases and no axillary lymph node involvement was observed. Of seven patients who received BCS, six underwent radiation

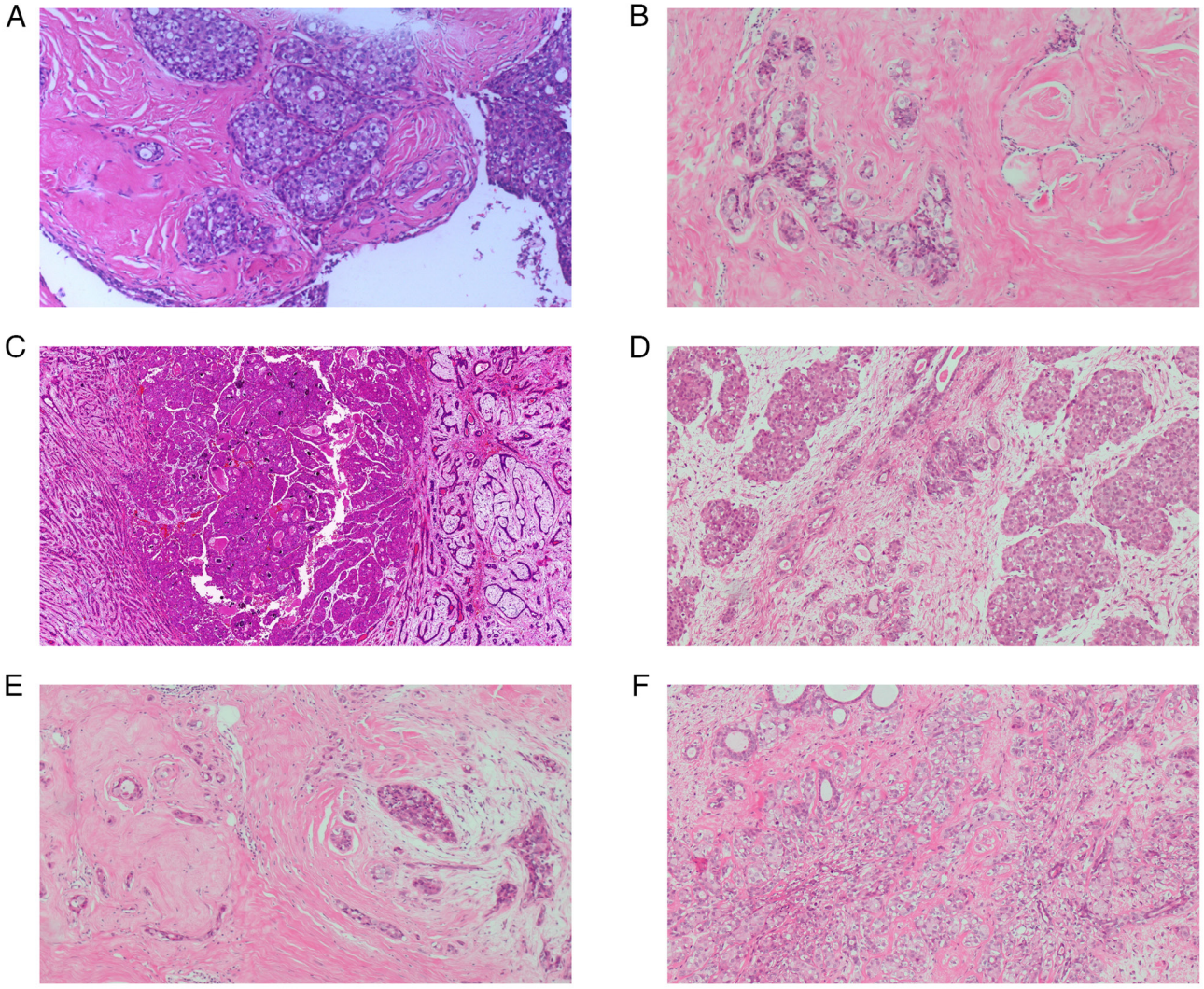

Figure 2. Subtypes of breast carcinoma arising in a fibroadenoma. (A) Carcinoma *in situ*, (B) invasive breast carcinoma, (C) ductal and (D) lobular carcinoma *in situ* and (E) invasive ductal and (F) lobular carcinoma arising within a fibroadenoma. Representative images were observed at a magnification of x100.

therapy; one 19-year-old female patient diagnosed with DCIS arising within a fibroadenoma rejected radiotherapy because of personal reasons. Furthermore, chemotherapy was administered in two patients diagnosed with invasive carcinoma. Anti-HER2-targeted therapy was administered concurrently with chemotherapy in one of these patients, since the immunohistochemical staining revealed HER2-positive invasive carcinoma (Fig. 3D).

Follow-up data were available for all patients. In the follow-up period, no signs of recurrence or relapse were observed and all patients were in good health at the last follow-up.

Discussion

Carcinoma arising from a fibroadenoma is a poorly understood disease of the breast, with only a few reported cases (17,18). Unlike benign fibroadenoma, malignant transformation within a fibroadenoma is most reported in patients in their 40s (6,13), although it can occur at any age. Consistent with these reports, the age of patients at diagnosis in the present study ranged between 19 and 58 years, with a median age of 45 years. Notably, five of the 16 patients (31.3%) were <35 years old, with the proportion of young patients with breast cancer markedly higher than that in the whole breast cancer population (19). This indicated that malignant transformation within a fibroadenoma may be stimulated by high estrogen levels in young women. Notably, the youngest patient in the present study was a 19-year-old female patient who was diagnosed with low-grade DCIS arising with a fibroadenoma. To the best of our knowledge, this is the youngest case reported in the literature so far. Therefore, it is important for clinicians to be cognizant of potential malignant transformation within a fibroadenoma even if the patient is young.

Breast cancer arising in fibroadenomas is difficult to diagnose because its oncogenic components may be masked by fibroadenoma components and has a low incidence rate.. In the present study, the most common clinical presentation was a well-defined, movable, asymptomatic mass (87.5%), which was similar to a benign breast tumor. Furthermore, observations in the radiological examinations, including ultrasonography and mammography, are usually non-specific (20). Only five patients (31.3%) in the present study were categorized as BI-RADS 4 on ultrasonography. Additionally, malignant transformation

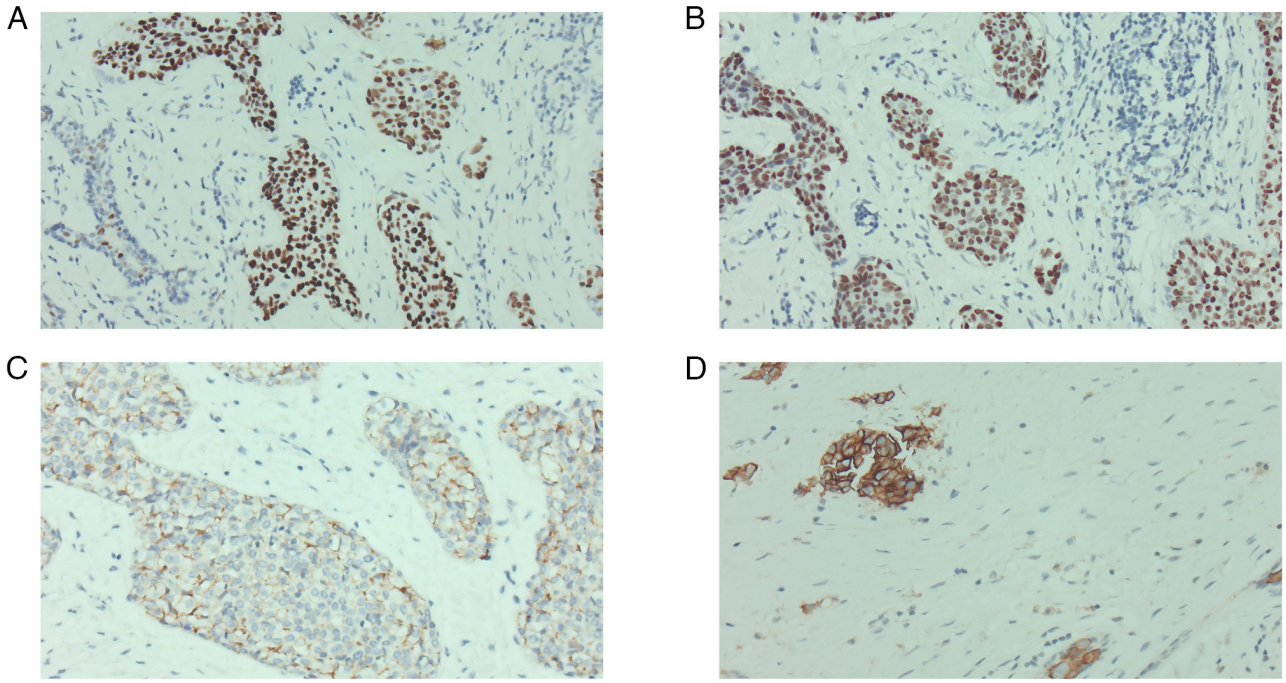

Figure 3. Immunohistochemical analysis of breast carcinoma arising in a fibroadenoma. (A) Estrogen and (B) Progesterone receptor. Human epidermal growth factor receptor (C) (1+) and (D) (3+). Representative images were observed at a magnification of x200.

indicators in mammography, such as microcalcifications and distortion of surrounding tissue, were only observed in three cases (18.8%) (21). As the carcinoma component may be hidden by other components in fibroadenoma, and thus, may not be detected by imaging examinations (16), it is difficult to differentiate benign fibroadenomas from their counterparts with malignant transformation within them. Therefore, tumor biopsy or excision should potentially be suggested to make a diagnosis in this situation. Notably, a recent study evaluated the role of dynamic contrast-enhanced MRI in diagnosing cancerous lesions developing within fibroadenomas (21) and revealed that relatively low diffusion of the apparent diffusion coefficient value suggested a malignant transformation within a fibroadenoma. Novel potential imaging methods with high accuracy and efficiency are clinically warranted.

Here, non-invasive carcinoma was the predominant type of malignancy within a fibroadenoma (75%). Theoretically, the occurrence of a breast carcinoma within a fibroadenoma has two potential etiologies: The breast carcinoma may arise from epithelial components of the fibroadenoma or tumors may coexist separately (22). Previous studies have produced inconsistent results: Several studies found that LCIS is more common compared with DCIS since fibroadenoma is of lobular origin (23,24), while other reports demonstrated that LCIS and DCIS present with approximately equal frequency within a fibroadenoma because they both originate from the terminal duct-lobular units of the breast (25,26). However, in the present study, DCIS was more frequent than LCIS. These inconsistent results indicate that the exact cell origin of the carcinoma within a fibroadenoma remains unclear.

Since few case reports have been published to date (27,28), the immunohistochemical characteristics as well as molecular subtype distribution of breast carcinoma arising within a fibroadenoma remain to be determined. A retrospective study reported that most cases are HR-positive (25). However, the study was reported in the 'pre-adjuvant anti-HER2 therapy era' and HR status was determined few cases, which introduced possible elements of bias. In the present immunohistochemical examination, the majority of cases were positive for HR (93.8%) and negative for HER2 (87.5%). The luminal A and B, HER2-positive and triple-negative molecular subtypes accounted for 10 (62.5%), five (31.3%), 0 (0.0%) and 0 (0.0%) and one (6.3%) cases, respectively. To the best of our knowledge, this is the first case series reporting molecular subtype distribution in detail. Since DCIS cases have diverse clinical and prognostic features for different molecular subtypes, accurate diagnosis, including determination of molecular subtype, is required for prompt treatment and prognosis.

Following diagnosis of carcinoma, BCS was performed in seven patients and mastectomy was performed in nine patients based on the personal preference of the patient. Although the majority of cases were non-invasive on core needle biopsy, SLNB was performed in all cases in case of tumor upstaging on final pathology. A previous study (29) reported the rate of upstaging to invasive breast cancer in patients with DCIS identified on core needle biopsy; 36% of patients with DCIS were ultimately diagnosed with invasive carcinoma (29). Additionally, in the present study, no axillary node involvement was observed. The present results indicated that SLNB may be unnecessary in carcinoma arising within a fibroadenoma, particularly in non-invasive cases.

Although differences between breast carcinoma arising from fibroadenoma and breast cancer remain unknown, a tumor bed boost after postoperative whole breast irradiation in patients with DCIS following conservative surgery can be recommended, as evidenced by the BIG 3-07/TROG 07.01 trial (30). Regarding radiotherapy following BCS, six out of seven patients completed the treatment as planned; one 19-year-old female with DCIS refused post-operative

radiotherapy for personal reasons. Adjuvant chemotherapy was administered to one HER2-positive invasive breast cancer case. Upregulation of HER2 in DCIS is associated with adverse clinicopathological parameters, including higher grade, comedo necrosis, as well as worse clinical outcome (31). To the best of our knowledge, however, the therapeutic role of anti-HER2-targeted therapy in HER2-positive DCIS has not been established. Therefore, another patient diagnosed with HER2-positive DCIS arising within a fibroadenoma was treated with post-operative radiotherapy only.

At the end of follow-up, all 16 patients included in the present study were alive and no progression was observed. A limitation of the present study is the follow-up period was relatively short; further follow-up and prognosis should be assessed in future. A second limitation of the study is the genetic analysis of breast carcinoma arising within a fibroadenoma is not routinely performed in daily clinical practice, therefore genetic information of these cases was not collected. Previous studies have demonstrated that carcinoma arising within a fibroadenoma is associated with a favorable prognosis with adequate local therapy (3,32), regardless of whether it is biologically *in situ* or not. However, clinicians should be alert to potentially enclosed cancerous lesions in a fibroadenoma since they can radically alter both prognosis and treatment outcome.

In conclusion, carcinoma arising within a fibroadenoma is a rare malignancy of the breast. In clinical practice, it is often encountered incidentally during pathological examination of a benign breast mass. Non-invasive carcinoma was the predominant type of malignancy within a fibroadenoma, although the cell origin of the carcinoma remains to be elucidated. Notably, the present report described the youngest case to date, although malignant changes within fibroadenomas are typically identified in older patients. Aggressive molecular phenotypes, including HER2-positive or triple-negative subtypes, were identified in the present case series. Surgical excision with or without postoperative radiotherapy should be recommended once the malignancy is diagnosed. Additionally, systemic treatment, such as chemotherapy and endocrine therapy, were also suggested, especially in the presence of invasive carcinoma with unfavorable tumor biology or axillary lymph node metastases.

Acknowledgements

The authors would like to thank Professor Jianhong Tu (Department of Pathology, The Third Hospital of Nanchang City, Nanchang, China) for technical assistance in preparing histology tissue sections.

Funding

The present study was supported by the National Natural Science Foundation of China (grant nos. 81860467, 82060482 and 81860546) and Key Science and Technology Support Project of Nanchang (grant no. 2019-258-13).

Availability of data and materials

The datasets used and/or analyzed during the current study are available from the corresponding author on reasonable request.

Authors' contributions

LX, WQ, SL and YC conceived and designed the study. LX and QM wrote the manuscript. LL collected data. QM, YG and LL analyzed the data. WQ performed the pathological examination and provided experimental technical support. SL and YC wrote and revised the manuscript. LX and YC confirm the authenticity of all the raw data. All authors have read and approved the final manuscript.

Ethics approval and consent to participate

The present study was approved by the Institutional Review Boards of The Third Hospital of Nanchang City (Nanchang, China; approval no. K-ky2023005). Written informed consent was obtained from all patients according to The Declaration of Helsinki.

Patient consent for publication

Not applicable.

Competing interests

The authors declare that they have no competing interests.

References

1. Basara Akin I and Balci P: Fibroadenomas: A multidisciplinary review of the variants. Clin Imaging 71: 83-100, 2021.
2. Lerwill MF, Lee AHS and Tan PH: Fibroepithelial tumours of the breast-a review. Virchows Arch 480: 45-63, 2022.
3. Feliciano YZ, Freire R, Net J and Yepes M: Ductal and lobular carcinoma in situ arising within an enlarging biopsy proven fibroadenoma. BMJ Case Rep 14: e237017, 2021.
4. Brock CM, Harper C and Tyler T: Fibroadenoma containing lobular carcinoma in situ, an unusual finding in a normally benign mass. J Surg Case Rep 2020: rjaa059, 2020.
5. Shojaku H, Hori R, Yoshida T, Matsui K, Shimada K, Takayanagi N and Noguchi K: Low-grade ductal carcinoma in situ (DCIS) arising in a fibroadenoma of the breast during 5 years follow-up: A case report. Medicine (Baltimore) 100: e24023, 2021.
6. Krishnamurthy K, Alghamdi S, Gyapong S, Kaplan S and Poppiti RJ: A clinicopathological study of fibroadenomas with epithelial proliferation including lobular carcinoma in-situ, atypical ductal hyperplasia, DCIS and invasive carcinoma. Breast Dis 38: 97-101, 2019.
7. Fukuda M, Nagao K, Nishimura R, Matsuda M, Baba K, Ueno Y, Morinaga H, Omachi H and Hamada T: Carcinoma arising in fibroadenoma of the breast-a case report and review of the literature. Jpn J Surg 19: 593-596, 1989.
8. Wu YT, Wu HK, Chen ST, Chen CJ, Chen DR and Lai HW: Fibroadenoma progress to ductal carcinoma in situ, infiltrating ductal carcinoma and lymph node metastasis? Report an unusual case. J Surg Case Rep 2017: rjx064, 2017.
9. Md Nasir ND, Koh VCY, Cree IA, Ruiz BII, Del Águila J, Armon S, Fox SB, Lakhani SR and Tan PH: Phyllodes tumour evidence gaps mapped from the 5th edition of the WHO classification of tumours of the breast. Histopathology 82: 704-712, 2023.
10. Yamamoto Y, Hayashi Y, Sakaki H and Murakami I: Downregulation of fascin induces collective cell migration in triple-negative breast cancer. Oncol Rep 50: 150, 2023.
11. Wolff AC, Hammond MEH, Allison KH, Harvey BE, Mangu PB, Bartlett JMS, Bilous M, Ellis IO, Fitzgibbons P, Hanna W, *et al*: Human epidermal growth factor receptor 2 testing in breast cancer: American society of clinical oncology/college of American pathologists clinical practice guideline focused update. J Clin Oncol 36: 2105-2122, 2018.

12. Jacobs TW, Gown AM, Yaziji H, Barnes MJ and Schnitt SJ: Comparison of fluorescence in situ hybridization and immunohistochemistry for the evaluation of HER-2/neu in Breast Cancer. J Clin Oncol 17: 1974-1982, 1999.
13. Wu YT, Chen ST, Chen CJ, Kuo YL, Tseng LM, Chen DR, Kuo SJ and Lai HW: Breast cancer arising within fibroadenoma: Collective analysis of case reports in the literature and hints on treatment policy. World J Surg Oncol 12: 335, 2014.
14. Giuliano AE, Connolly JL, Edge SB, Mittendorf EA, Rugo HS, Solin LJ, Weaver DL, Winchester DJ and Hortobagyi GN: Breast Cancer-Major changes in the American Joint Committee on Cancer eighth edition cancer staging manual. CA Cancer J Clin 67: 290-303, 2017.
15. Spak DA, Plaxco JS, Santiago L, Dryden MJ and Dogan BE: BI-RADS ® fifth edition: A summary of changes. Diagn Interv Imaging 98: 179-190, 2017.
16. Shiino S, Yoshida M, Tokura M, Watase C, Murata T, Jimbo K, Takayama S, Suto A, Satomi K, Miyagi Maeshima A, *et al*: Locally advanced triple negative breast cancer arising from fibroadenoma with complete response to neoadjuvant chemotherapy: A case report. Int J Surg Case Rep 68: 234-238, 2020.
17. Razakanaivo M, Rakotoarivo T, Andrianandrasana NO and Rafaramino F: Breast Carcinoma Arising in Fibroadenoma in a 15-Year-Old Girl; Diagnosis and Treatment Challenge. J Cancer Ther 13: 615-620, 2022.
18. Ni XH, An R, Shi QW and Wang CL: Low-Grade ductal carcinoma in situ within a fibroadenoma of the breast: A rare case report and review of the literature. Onco Targets Ther 16: 399-406, 2023.
19. Paluch-Shimon S, Cardoso F, Partridge AH, Abulkhair O, Azim HA, Bianchi-Micheli G, Cardoso MJ, Curigliano G, Gelmon KA, Gentilini O, *et al*: ESO-ESMO fifth International consensus guidelines for breast cancer in young women (BCY5). Ann Oncol 33: 1097-1118, 2022.
20. Ren Y, Li P and Yang Y: Imaging findings of ductal carcinoma in situ arising within fibroadenoma. Breast J 26: 1037-1038, 2020.
21. Tagliati C, Lanni G, Cerimele F, Di Martino A, Calamita V, Lucidi Pressanti G, Mingliang Y, Giuseppetti GM, Argalia G and Giovagnoni A: Low diffusion level within a fibroadenoma as the sole sign of ductal carcinoma in situ: A case report. Breast Dis 40: 283-286, 2021.
22. Saimura M, Koga K, Anan K, Mitsuyama S and Tamiya S: Diagnosis, characteristics, and treatment of breast carcinomas within benign fibroepithelial tumors. Breast Cancer 25: 470-478, 2018.
23. Hayes BD and Quinn CM: Microinvasive lobular carcinoma arising in a fibroadenoma. Int J Surg Pathol 21: 419-421, 2013.
24. Seow DYB, Tay TKY and Tan PH: Fibroepithelial lesions of the breast: A review of recurring diagnostic issues. Semin Diagn Pathol 39: 333-343, 2022.
25. Diaz NM, Palmer JO and McDivitt RW: Carcinoma arising within fibroadenomas of the breast. A clinicopathologic study of 105 patients. Am J Clin Pathol 95: 614-622, 1991.
26. Hammood ZD, Mohammed SH, Abdulla BA, Omar SS, Naqar S, Salih AM and Kakamad FH: Ductal carcinoma in situ arising from fibroadenoma; a rare case with review of literature. Ann Med Surg (Lond) 75: 103449, 2022.
27. Ma XL, Kang L, Li BJ, He CN and Zhao HF: Invasive ductal carcinoma displayed 'basal-like' feature arising within a breast fibroadenoma. Breast J 22: 695-696, 2016.
28. Fujimoto A, Matsuura K, Kawasaki T, Ichinose Y, Nukui A, Hiratsuka M, Asano A, Shimada H, Osaki A and Saeki T: Early HER2-positive breast cancer arising from a fibroadenoma: A case report. Oxf Med Case Reports 2021: omab083, 2021.
29. Miller-Ocuin JL, Howard-McNatt M, Levine EA and Chiba A: Is sentinel lymph node biopsy necessary for ductal carcinoma in situ patients undergoing mastectomy? Am Surg 86: 955-957, 2020.
30. Chua BH, Link EK, Kunkler IH, Whelan TJ, Westenberg AH, Gruber G, Bryant G, Ahern V, Purohit K, Graham PH, *et al*: Radiation doses and fractionation schedules in non-low-risk ductal carcinoma in situ in the breast (BIG 3-07/TROG 07.01): A randomised, factorial, multicentre, open-label, phase 3 study. Lancet 400: 431-440, 2022.
31. Yang L, Shen M, Qiu Y, Tang T and Bu H: Molecular subtyping reveals uniqueness of prognosis in breast ductal carcinoma in situ patients with lumpectomy. Breast 64: 1-6, 2022.
32. Wu J, Sun KW, Mo QP, Yang ZR, Chen Y and Zhong MC: Preoperational diagnosis and management of breast ductal carcinoma in situ arising within fibroadenoma: Two case reports. World J Clin Cases 10: 3496-3504, 2022.