SPANDIDOS PUBLICATIONS

ONCOLOGY LETTERS 27: 56, 2024

# Precision therapy for intrahepatic cholangiocarcinoma: A case report on adjuvant treatment in a recurrent patient after surgery and literature review

BAO YING, TAO TANG, LI-XING ZHANG, JIAN-WEI XIONG, KAI-FENG ZHAO, JIA-WEI LI and GUO WU

Department of Hepatobiliary Surgery, Affiliated Hospital of North Sichuan Medical College, Nanchong, Sichuan 637000, P.R. China

Received May 25, 2023; Accepted October 23, 2023

DOI: 10.3892/ol.2023.14189

**Abstract.** A 37-year-old female patient was diagnosed with intrahepatic cholangiocarcinoma (ICC), with the lesion located in the right lobe of the liver. Despite radical resection, postoperative adjuvant chemotherapy and a combination of adjuvant chemotherapy and immunotherapy, the patient continued to experience multiple instances of intrahepatic tumor metastases. Furthermore, the patient exhibited significant adverse reactions to systemic chemotherapy and had poor treatment tolerance. Guidance from paraffin section fluorescence *in situ* hybridization gene sequencing was used to select a combination of immunotherapy and targeted therapy treatments with programmed cell death 1 (PD-1)/PD-1 ligand 1 antibody durvalumab and the targeted drug pemigatinib. The patient tolerated the treatment and has continued to survive for 28 months. According to imaging evaluations, the lesions continued to decrease, with some disappearing completely. The tumor marker carbohydrate antigen 19-9 remained normal for >9 weeks during the treatment. This report described the patient's treatment process in detail and briefly reviewed relevant literature on the treatment progress of postoperative patients with ICC.

## Introduction

Intrahepatic cholangiocarcinoma (ICC) is a malignant tumor that originates in the epithelial cells of the intrahepatic bile ducts. It accounts for 10-15% of primary liver cancers and is second only to hepatocellular carcinoma (HCC) in incidence (1). Due to its insidious onset, ICC is often diagnosed at a late stage. It can easily invade organs, tissues and nerves surrounding the liver, leading to lymph node and distant extrahepatic metastases. Effective treatment options are currently lacking (2). So far, surgery is the only curative treatment for ICC. However, only ~35% of patients are eligible for surgery and ~35% of those who undergo radical resection relapse within two years (3). At present, there is no well-established treatment plan for patients with ICC after surgery. In addition, There are limited studies on the comprehensive treatment of patients with postoperative recurrence of ICC. Chemotherapy, immunotherapy and their combination have demonstrated potential clinical benefits, but it is still controversial (4). In addition, no relevant studies have been found regarding the effectiveness of combining immunotherapy with targeted therapy for patients who have experienced postoperative recurrence of ICC. The present report describes the treatment for a patient with postoperative recurrence of ICC.

## Methods

*Data collection*. For the section titled 'Medical History Prior to Treatment at the Affiliated Hospital of North Sichuan Medical College (Nanchong, China)', data were collected through direct patient interviews and from the patients' historical discharge documents from other hospitals. These documents included the discharge summary, surgical records and relevant diagnostic reports. As for the section 'Course of Treatment at the Affiliated Hospital of North Sichuan Medical College (Nanchong, China)', the data were meticulously extracted from the patients' medical records maintained at the Affiliated Hospital of North Sichuan Medical College (Nanchong, China).

*Data analysis*. The analysis included review of the patient's symptoms, signs, laboratory test results, radiological findings and the course of treatment.

*Literature review*. Utilizing a search strategy that integrates both subject words and free words, the following key words were employed: 'intrahepatic cholangiocarcinoma',

*Correspondence to:* Professor Guo Wu, Department of Hepatobiliary Surgery, Affiliated Hospital of North Sichuan Medical College, 1 Maoyuan South Road, Shunqing, Nanchong, Sichuan 637000, P.R. China
E-mail: cqxnyywg@163.com

*Key words:* intrahepatic cholangiocarcinoma, immunotherapy, targeted therapy, pemigatinib, durvalumab

'postoperative recurrence', 'postoperative adjuvant therapy', 'immunotherapy', 'targeted therapy', 'adjuvant chemotherapy', 'pemigatinib' and 'durvalumab'. These keywords were used to search for relevant studies on postoperative adjuvant treatment for patients with ICC in the PubMed, Embase, Web of Science and Cochrane Library databases. The search time frame spanned from the inception of each database up to April 2023. This search was supplemented by manual retrieval of references from pertinent articles. Finally, a comprehensive review was conducted on the recent advancements in postoperative adjuvant treatment for ICC derived from both clinical trials and experimental studies.

*Evaluation criteria*. Efficacy was evaluated according to the Response Evaluation Criteria In Solid Tumors version 1.1 (RECIST 1.1) (5) and adverse events were reported using the Common Terminology Criteria for Adverse Events version 5.0 (CTCAE 5.0; National Cancer Institute) (6).

*Histology, immunohistochemistry and fluorescence in situ hybridization (FISH).* FISH gene sequencing analysis on paraffin sections was outsourced to Wuhan HealthCare Medical Laboratory. Assays were performed according to standard protocols. Immunohistochemistry antibodies were as follows: DNA mismatch repair protein MSH2 (MSH2) monoclonal antibody (FE11) (cat. no. 33-7900; dilution, 3 $\mu$g/ml); MSH6 polyclonal antibody (cat. no. 18120-1-AP; dilution, 1:100); MLH1 polyclonal antibody (cat. no. 11697-1-AP; dilution, 1:100); PMS1 homolog 2, mismatch repair system component (PMS2) recombinant rabbit monoclonal antibody (SY08-09) (cat. no. MA5-32044; dilution, 1:100); and ErbB2 (HER-2) polyclonal antibody (cat. no. PA5-14635; dilution, 1:500; all from Invitrogen; Thermo Fisher Scientific, Inc.).

## Case report

*Medical history before treatment at the Affiliated Hospital of North Sichuan Medical College (Nanchong, China).* A 37-year-old female patient reported 'the presence of hepatic space-occupying lesions detected during a routine physical examination eight months previously' and was admitted to a local hospital. The following information was obtained from the medical records/the discharge certificate of the patient's local hospital. Abdominal enhanced CT showed space-occupying lesions in the lower segment of the right lobe and the upper segment of the right anterior lobe of the liver, suggesting the possibility of liver cancer with intrahepatic metastasis. The patient's medical records from the local hospital showed that the patient had no specific symptoms and no significant weight changes upon admission. The patient was diagnosed with chronic hepatitis B 22 years previously but reported having been cured and having a negative result. The patient had no history of smoking or drinking, no family history of similar illnesses and was divorced. Physical examination revealed a body height of 160.0 cm, body weight of 48.0 kg, Eastern Cooperative Oncology Group (ECOG) performance status of 0, no jaundice in the skin and sclera, and negative abdominal signs. Laboratory tests showed elevated aspartate aminotransferase (AST) (99.6 U/l; normal range, 8-40 U/l), alanine aminotransferase (ALT) (99.0 U/l; normal range, 5-35 U/l). ALT and AST exist in the cytoplasm of hepatocytes and when the hepatocyte membrane is damaged and ruptured, ALT and AST increase significantly and are released into the bloodstream, making them important indices for reflecting hepatocyte injury. Furthermore, the patient exhibited an increase in total bilirubin (TBil) (25.7 $\mu$mol/l; normal range, 3.0-20.0 $\mu$mol/l). TBil, also known as serum bilirubin, including indirect bilirubin and direct bilirubin (DBil), is helpful in detecting jaundice that cannot be observed by the naked eye, and it often reflects hepatocyte injury or cholestasis. The patient's hepatitis B virus (HBV) test results were as follows: HBV surface antigen (HBsAg) (-), HBs antibody (Ab) (+), HBc antibody (Ab) (+), HBe antibody (Ab) (-), HBe antigen (Ag) (-), and the patient's HBV-DNA was within the normal range (1-1.00x$10^2$). The five serum immune markers (HBsAg, HBsAb, HBcAb, HBeAb and HBeAg) of HBV, are commonly used in clinics to determine whether patients are infected. Quantitative detection of HBV-DNA reflects the level of HBV replication. These two tests are often employed to determine whether to treat the HBV and to evaluate the efficacy of antiviral therapy. The patient's test results for hepatitis C virus antigen were negative, and no additional testing was performed to detect other types of hepatitis viruses. Other biochemical indexes and tumor markers [including abnormal prothrombinase II, α-fetoprotein (AFP) and AFP isoform-3 percentage] were normal [however, carbohydrate antigen 19-9 (CA19-9) was not tested; serum CA19-9 can be used as an auxiliary diagnostic index for malignant tumors, such as pancreatic cancer and biliary tract cancer. The content of CA19-9 in the serum of patients with malignant tumors of the digestive tract, particularly pancreatic cancer and biliary tract cancer, is significantly increased, although its value in early diagnosis is limited. It is primarily used as an index to monitor the disease and to predict recurrence]. Furthermore, blood routine and coagulation function were normal. The Child-Pugh score was A. The patient underwent laparoscopic right hepatectomy + cholecystectomy + bile duct repair under general anesthesia. Intraoperative ultrasound showed no metastases in the left half of the liver and there was no ascites. Mild liver cirrhosis was present, but there were no metastases in the diaphragm, abdominal wall, peritoneum, greater omentum or pelvic cavity by naked eye observation. Intraoperative bleeding was ~600 ml and thus, 400 ml of autologous blood was transfused. Postoperatively, 2U suspended red blood cells and 700 ml fresh frozen plasma were infused. The patient was discharged 10 days after the operation. Pathological examination of the resected liver cancer (Fig. 1A) showed multiple cholangiocarcinomas (moderately differentiated), with the largest nodule measuring 10.0x6.5x3.5 cm. The tumor affected but did not penetrate the hepatic capsule. The tumor thrombus and nerve invasion were visible in the vessels. No residual cancer was found at the incisal liver margin. Immunohistochemical staining results were as follows: MSH2 (+), MSH6 (+), MLH1 (+), PMS2 (+) and human EGFR2 (-) (Fig. 1B). Chronic cholecystitis was present in the gallbladder, but no cancer was found. The level of tumor marker CA19-9 was 135 U/ml at 1 month post-surgery. Adjuvant chemotherapy with 'capecitabine + oxaliplatin' was started one month after surgery. The CA19-9 level was 442 U/ml when the fourth round of chemotherapy was scheduled 4 months after surgery. A plain scan of the upper abdomen

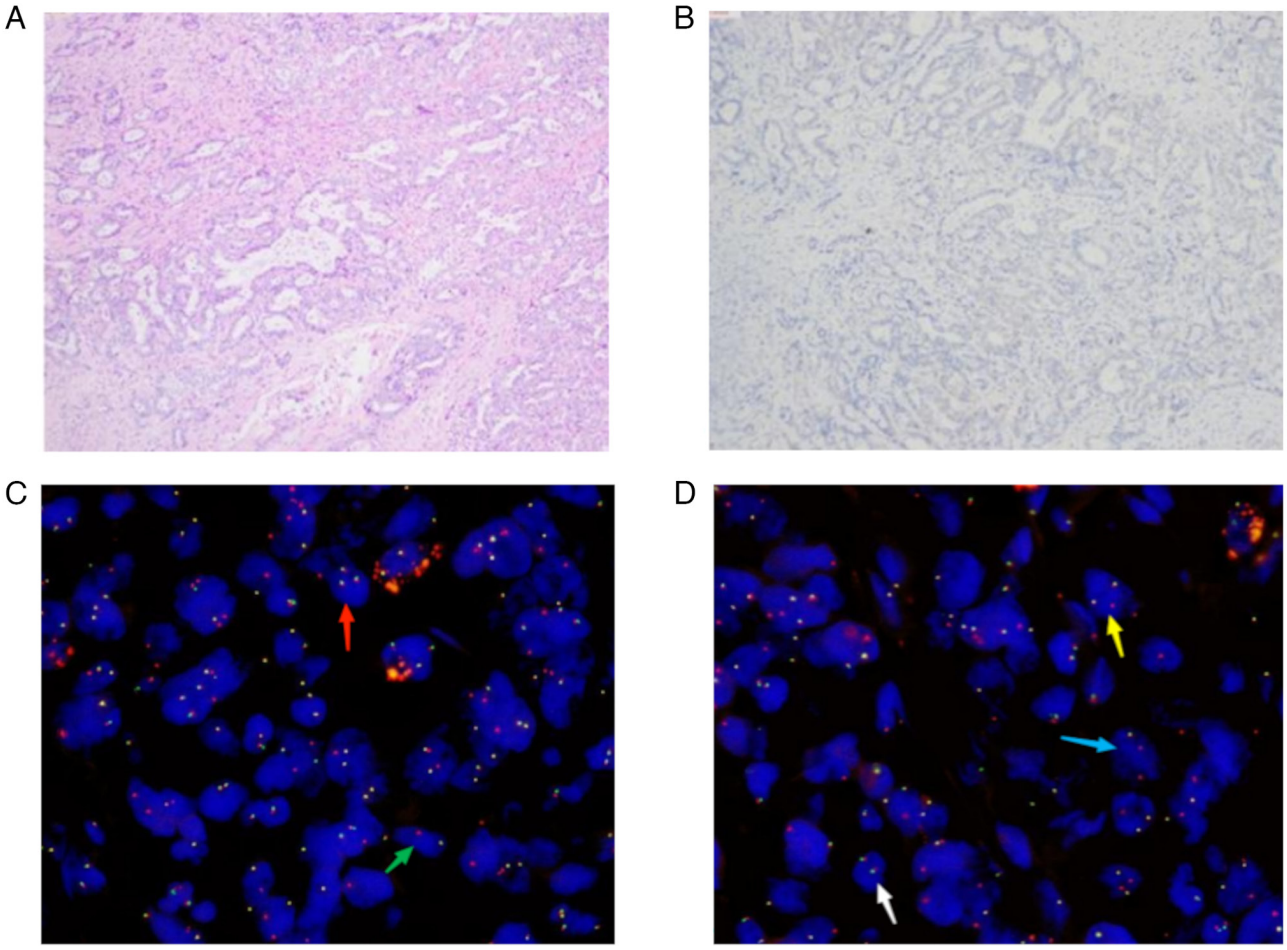


Figure 1. Immunohistochemical and gene sequencing using FISH on paraffin sections. (A and B) Histological smear of tumor tissue and immunohistochemistry. (A) A randomly chosen accompanying image of a histological smear of the tumor stained with hematoxylin-eosin. (B) A randomly chosen accompanying image of immunohistochemical staining [antigen: MSH2 monoclonal antibody (FE11)]. Immunohistochemical staining results were as follows: MSH2 (+), MSH6 (+), MLH1 (+), PMS2 (+) and human EGFR2 (-). (C and D) Gene sequencing using paraffin section FISH: A total of 100 cells were counted in the sample, which showed an abnormal FISH status of FGFR2 gene rearrangement. The red signal marks the 5' end and the green signal marks the 3' end of the FGFR2 gene. The normal signal pattern is 2F (F denotes a yellow signal resulting from red and green fusion), with 8% of the cells being 1F and 16% being 2F. The typical positive signal pattern is 1F1R1G, with ~76% of the cells exhibiting fusion signals accompanied by abnormal single red signals. (C) The green arrow represents 1F1R, with a cell proportion of 14%; the red arrow represents 3F2R, with a cell proportion of 6%. (D) The yellow arrow represents 1F2R, with a cell proportion of 14%; the blue arrow represents 2F1R, with a cell proportion of 18%; the white arrow represents 2F2R, with a cell proportion of 24% (magnification, x1,000). FISH, fluorescence *in situ* hybridization; MSH2, DNA mismatch repair protein MSH2; FGFR, fibroblast growth factor receptor.

plus enhanced magnetic resonance imaging (MRI) suggested multiple abnormal signals at the edge of the operative area and in the liver, indicating a high possibility of tumor recurrence and metastasis. Due to poor tolerance of chemotherapy side effects, the patient refused to undergo a fourth round of chemotherapy and was discharged from the local hospital. The patient subsequently sought treatment at Affiliated Hospital of North Sichuan Medical College (Nanchong, China).

*Course of treatment at the Affiliated Hospital of North Sichuan Medical College (Nanchong, China).* The patient presented with 'recurrence of ICC >4 months after surgery and >1 month after multiple adjuvant chemotherapy treatments'. Upon admission, the patient reported grade 2 fatigue with poor mental state (low mood, anxiety and agitation), grade 2 poor appetite and grade 2 occasional generalized pain. The grading of adverse events was conducted according to the CTCAE v5.0. Laboratory examination results were as follows: AST, 37 U/l; TBil, 34 $\mu$mol/l; DBil, 8.4 $\mu$mol/l (normal range, 1.7-8.0 $\mu$mol/l); CA19-9; 99.6 U/ml (normal range, 0-37.00 U/ml); white blood cells (WBC), 3.38x$10^9$/l (normal range, is 4-10x$10^9$/l). Upper abdominal MRI scans with contrast (Fig. 2) revealed the following: i) Multiple nodules of varying sizes were found in liver tissue after liver cancer surgery, indicating recurrence of multi-line liver cancer with larger and more numerous nodules; ii) the patient had liver cirrhosis, splenomegaly and a small amount of ascites. Compared to the postoperative period with no intrahepatic lesions, there was at least a 20% increase in the sum of diameters of target lesions, which resulted in a rating as progressive disease according to RECIST 1.1. The diagnosis was postoperative recurrence of ICC. As the side effects from capecitabine were significant and the patient had poor tolerance, the treatment group communicated with the patient to obtain consent for a change in treatment. The patient was subsequently administered 'gemcitabine + oxaliplatin' (gemcitabine 1,000 mg/$m^2$ plus oxaliplatin 85 mg/$m^2$ once every four weeks) adjuvant chemotherapy combined with durvalumab (1,500 mg intravenous drip once every three weeks) for immunotherapy.

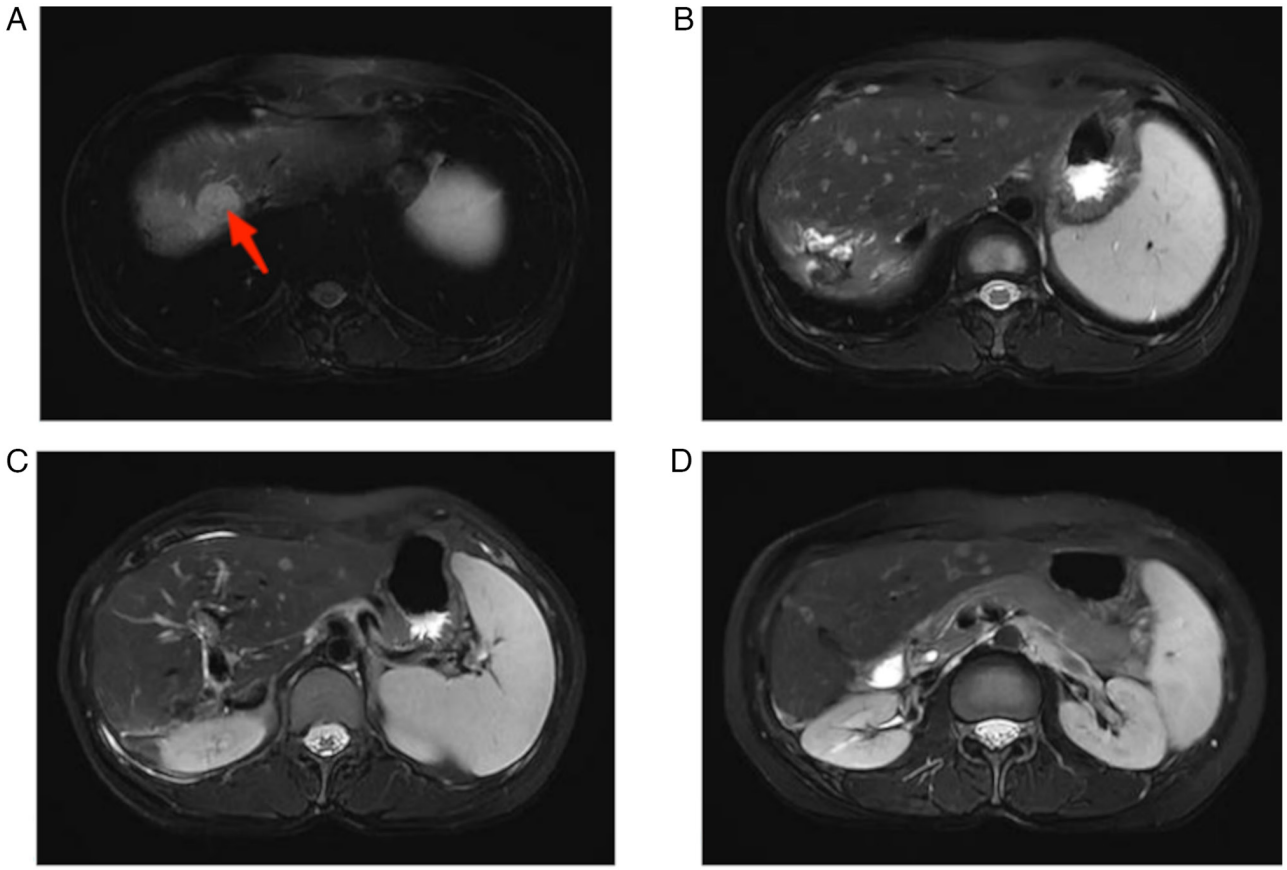


Figure 2. MRI T2-weighted imaging. Multiple metastases (high signal intensity) are visible in the hepatic parenchyma at the first presentation of the patient at the Affiliated Hospital of North Sichuan Medical College. (A) The largest one is located in the dome of the right hepatic lobe (red arrow) and measures ~2.0 cm in diameter. (B) Multiple punctate metastases are observed in liver segments SII, SVII and SVIII. (C) Micrometastases are detected at the junction of SII and SIII in the liver segment. (D) Scattered micrometastases can also be seen in segment SII of the liver.

After three courses of treatment, the patient suffered severe adverse reactions, including grade 2 fatigue, grade 2 nausea, grade 2 vomiting, grade 2 loss of appetite, grade 2 generalized pain and discomfort, grade 2 liver insufficiency, grade 1 hypoproteinemia, grade 2 severe myelosuppression and grade 3 severe thrombocytopenia leading to ecchymosis in multiple areas of the skin and conjunctival hemorrhage in the right eyeball. The grading of adverse events was conducted according to the CTCAE v5.0. The ECOG performance status was 3. Further laboratory examinations results were as follows: AST, 65 U/l; ALT, 46 U/l; TBil, 23.5 $\mu$mol/l; DBil, 7.9 $\mu$mol/l; ALB, 33.9 g/l; WBC, 1.86x$10^9$/l; red blood cells, 2.57x$10^{12}$/l (normal range, 3.5-5.0x$10^{12}$/l); hemoglobin, 78 g/l (normal range, 110-150 g/l); platelets, 42x$10^9$/l (normal range, 100-300x$10^9$/l); CA19-9, 151.7 U/ml. A subsequent plain MRI scan of the upper abdomen with contrast (Fig. 3) revealed the following: i) There were multiple nodules of varying sizes in the liver parenchyma after liver cancer surgery, with more enlarged nodules indicating recurrence of multi-line liver cancer, and a new tortuously dilated blood vessel in the right posterior liver lobe; ii) the patient still had liver cirrhosis, splenomegaly and a small amount of ascites. Compared to the baseline (Fig. 2), the diameter of intrahepatic lesions in the patient had increased by >20%, which resulted in a rating as progressive disease according to RECIST 1.1.

The patient discontinued adjuvant chemotherapy due to severe adverse reactions and declined further treatment. Combining adjuvant chemotherapy with immunotherapy did not yield any good results. Therefore, the treatment group decided to administer durvalumab (1,500 mg via intravenous drip once every three weeks) as a single immunotherapy. After discontinuing adjuvant chemotherapy, the patient's condition and mental state significantly improved and the patient's appetite and physical strength returned. However, the laboratory results showed a continuous increase in the tumor marker CA19-9, reaching 3,436.1 U/ml after three courses of immunotherapy. Due to the high cost of the MRI scan, the patient requested to switch to the more affordable CT scan for evaluating tumor response due to financial constraints. An epigastric enhanced CT (Fig. 4) showed the following: i) There were multiple nodules of different sizes in the liver parenchyma after postoperative immunotherapy for liver cancer and postoperative recurrence of multi-line liver cancer was considered; and ii) liver cirrhosis and splenomegaly. Compared to the baseline level (Fig. 2), the diameter of intrahepatic lesions in the patient increased by >20% and there was maintenance of the tumor marker CA19-9 level above the normal limits. As a result, the patient was assigned a progressive disease status according to the RECIST 1.1.

Given the comprehensive assessment of the patient's condition and despite undergoing curative surgery followed by adjuvant chemotherapy, combination of adjuvant chemotherapy and immunotherapy, and mono-immunotherapy, the

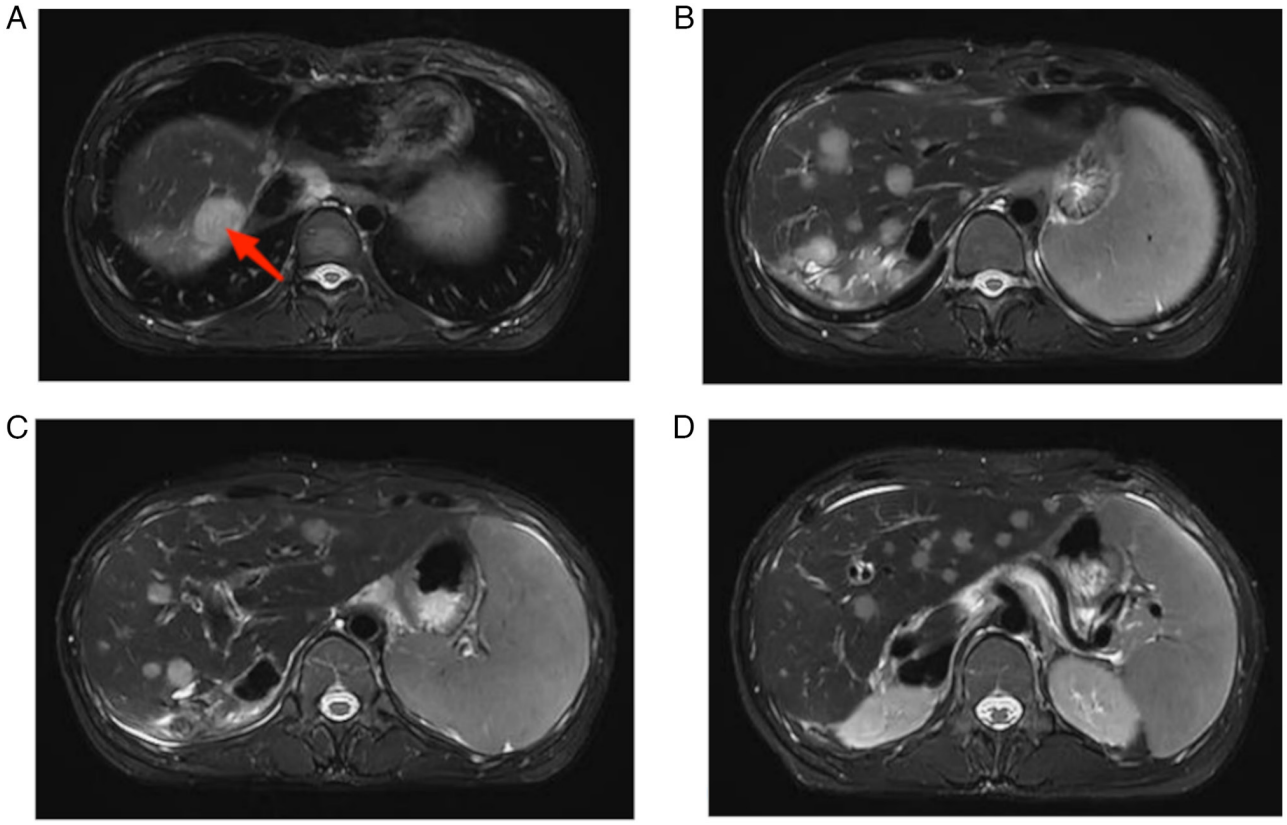


Figure 3. MRI T2-weighted imaging. Multiple metastases (high signal intensity) are visible in the hepatic parenchyma. The lesions significantly increased in number and size three months after the time-point of Fig. 1. (A) The largest one is located in the dome of the right hepatic lobe (red arrow) and measures ~2.8 cm in diameter. (B) There are numerous metastatic foci identified in liver segment SII, SVII, and SVIII. (C) Multiple metastatic foci are observed at the junction of SII and SIII, SV and SVI, as well as SVII and SVIII within the liver segment. (D) A significant number of metastatic foci are present in SII and SIV of the liver segment.

patient still experienced multiple intrahepatic metastases accompanied by persistently elevated tumor marker levels. In order to develop a more precise systemic treatment plan, fluorescence *in situ* hybridization (FISH) gene sequencing analysis on paraffin sections was outsourced to Wuhan HealthCare Medical Laboratory, which revealed an abnormal FISH status of fibroblast growth factor receptor (FGFR2) gene rearrangement in ~76% of cells with fusion signals accompanied by separate red signals (Fig. 1C and D). Through a literature analysis, pemigatinib was identified as one of the FGFR inhibitors currently approved for treating patients with ICC with FGFR2 fusion or translocation. In addition, durvalumab exhibited promising clinical activity in biliary tract cancer. Based on the clinical experience of patients with hepatocellular carcinoma benefiting from the combination of immunotargeted therapy, the treatment team decided to consult with the patient and opted for a combination treatment plan involving durvalumab (1,500 mg intravenous drip once every three weeks) immunotherapy combined with pemigatinib (9 mg/d for two weeks followed by one week of rest, with a three-week cycle) targeted therapy. The patient experienced several adverse drug reactions during the course of treatment, including grade 1 hair loss, grade 1 nail toxicity, grade 1 taste disorders, grade 2 stomatitis and grade 1 dry mouth. The grading of adverse events was conducted according to the CTCAE v5.0. However, no severe adverse reactions were observed. Three weeks after initiating systemic treatment, the patient's tumor marker CA19-9 decreased significantly to 82.1 U/ml. Subsequently, its level decreased to be within the normal range and remained so for >9 weeks. However, the patient's re-examination of tumor marker CA19-9 levels showed a rise to 330.4 U/ml after 8 months of systemic treatment (Fig. 5), prompting an adjustment in the pemigatinib dosage (13.5 mg/d for 2 weeks followed by 1 week of rest, with a 3-week cycle). During follow-up, imaging conducted every 2 months after systemic treatment, abdominal CT scans with contrast enhancement revealed that the intrahepatic metastases lesion nodules in the upper abdomen continuously shrank and even disappeared (Fig. 6; 6 months after systemic treatment). There was at least a 30% decrease in the sum of diameters of target lesions, taking as a reference the baseline sum diameters (Fig. 2), which resulted in a rating as partial response according to RECIST 1.1. During the course of treatment, the patient declined to undergo a whole-body positron emission tomography scan due to financial constraints and did not report any bone pain or discomfort in specific bones such as the clavicle, ribs, femur or spine. Routine chest CT scans were conducted every 2 months, revealing no signs of metastatic tumors. At the time of writing the manuscript, the patient's survival time was >28 months with an ECOG performance status of 1, and was continuing the regimen of immunotherapy (durvalumab, 1,500 mg intravenous drip once every three weeks) combined with targeted therapy (pemigatinib, 13.5 mg/d for 2 weeks followed by 1 week of rest, with a 3-week cycle).

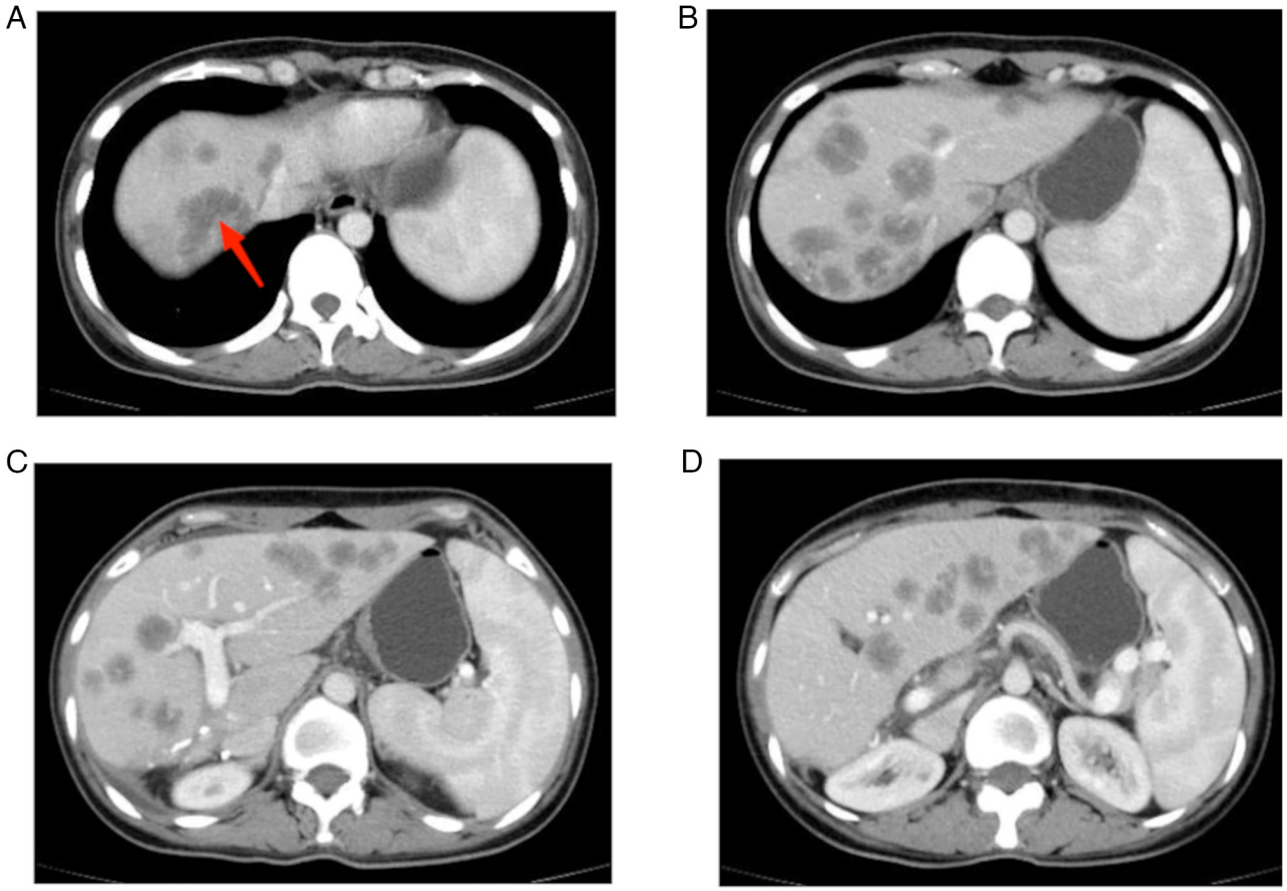


Figure 4. Portal venous phase of contrast-enhanced CT. Multiple metastases (low signal intensity) are visible in the hepatic parenchyma, indicating metastatic tumors. The lesions significantly increased in number and size two months after the time-point of Fig. 2. (A) The largest one is located in the dome of the right hepatic lobe (red arrow) and measures ~3.2 cm in diameter. (B) The liver segments SII, SVII and SVIII exhibit a multitude of identified metastatic foci. (C) Within the liver segment, metastatic foci are observed in multiple locations including the junctions of SII and SIII, SV and SVI, as well as SVII and SVIII. (D) SII and SIV of the liver segment display a significant number of present metastatic foci.

## Discussion

ICC lacks obvious clinical symptoms in the early stage and its high invasiveness makes the tumor prone to multifocality, lymph node metastasis and vascular invasion. Therefore, even if surgical resection is performed, relapse or distant metastasis may occur and long-term prognosis is far worse than that of HCC. Radical resection (R0 resection) is the main treatment for ICC. Most patients experience recurrence a short period of time after R0 resection. A study using an international database analyzed 563 patients with ICC who underwent radical resection and found that the recurrence rate was 71%, with a median follow-up period of 19 months (7). Therefore, further treatment of patients after ICC is crucial. Adjuvant therapy is currently recommended for postoperative ICC treatment, including adjuvant chemotherapy, radiotherapy, adjuvant chemotherapy combined with radiotherapy and transarterial chemoembolization (TACE). A meta-analysis of 10,181 postoperative ICC patients was conducted to study the effects of adjuvant therapy (8), including chemotherapy (n=832), TACE (n=309), radiotherapy (n=1,192) and adjuvant chemotherapy combined with radiotherapy (n=235). Random-effects model analysis showed that both overall survival (OS) and recurrence-free survival (RFS) were significantly better in the adjuvant therapy group compared to the non-adjuvant therapy group.

However, there is still an ongoing debate regarding the impact of adjuvant chemotherapy on inhibiting recurrence and prolonging survival in patients after surgery for ICC. Most retrospective studies indicate that adjuvant chemotherapy provides benefits to patients who undergo surgery for ICC, with the primary focus on gemcitabine-based chemotherapy. A meta-analysis of 11,458 patients (9), where 4,696 received postoperative adjuvant chemotherapy, has demonstrated that the OS time in patients with postoperative adjuvant chemotherapy was significantly higher than in those who were treated with surgery alone [hazard ratio (HR)=0.61; P<0.001]. Patients who received gemcitabine-based chemotherapy experienced significant benefits (HR=0.42; 95% confidence interval (CI): 0.33-0.55; P<0.001). There was no significant difference between studies based on 5-fluorouracil chemotherapy (HR=0.90; 95% CI: 0.56-1.44; P=0.66). A retrospective cohort study of 210 patients who underwent surgery for ICC has also shown that patients who received postoperative adjuvant chemotherapy based on gemcitabine had significantly better median OS and 1-, 3- and 5-year survival rates than those who did not receive postoperative adjuvant chemotherapy (10). A real-world study by Reames *et al* (11) has shown that the 5-year OS of patients with T stages T2, T3 and T4 and N1 lymph node metastasis who received adjuvant chemotherapy improved compared to those who did not receive adjuvant chemotherapy

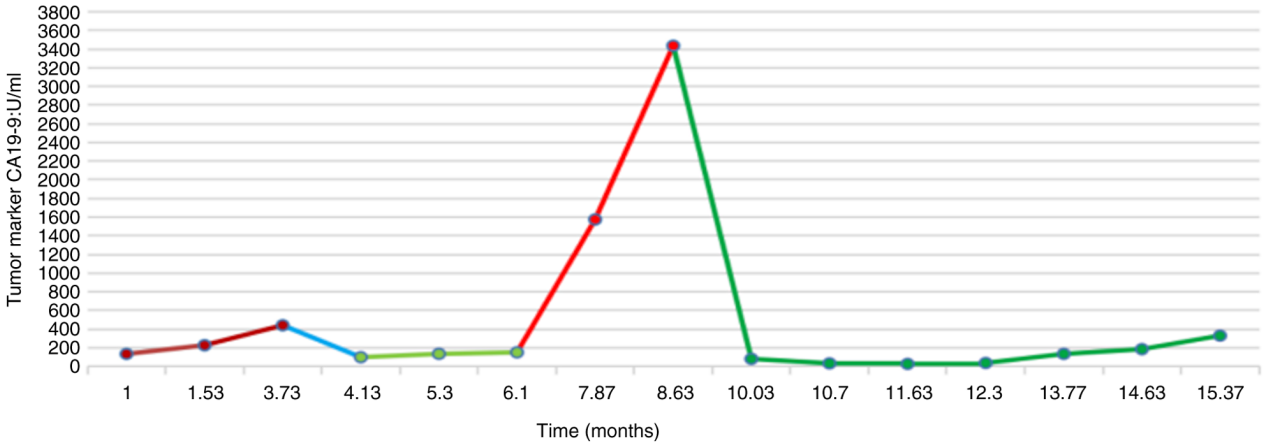


| Postoperative months | Treatment regimens |
|---|---|
| 1–3.73 (deep red) | Adjuvant chemotherapy with capecitabine+oxaliplatin |
| 3.73–4.13 (blue) | No anti-tumor treatment during this period; patient visited the Affiliated Hospital of North Sichuan Medical College in the > 4th postoperative month |
| 4.13–6.1 (light green) | Gemcitabine+oxaliplatin adjuvant chemotherapy combined with durvalumab |
| 6.1–8.63 (red) | Durvalumab as a single immunotherapy |
| 8.63 and ongoing (green) | Durvalumab immunotherapy combined with pemigatinib targeted therapy |

Figure 5. Tumor marker CA19-9 level change curve in response to different treatment regimens. Adjuvant chemotherapy with capecitabine + oxaliplatin is indicated in deep red, gemcitabine + oxaliplatin adjuvant chemotherapy combined with durvalumab for immunotherapy in light green, durvalumab as a single immunotherapy and durvalumab immunotherapy combined with pemigatinib targeted therapy in green. CA19-9, cancer antigen 19-9.

at the same stage. Other forms of adjuvant chemotherapy are currently being explored. The results of a multicenter open randomized phase III clinical trial by Nakachi *et al* (12) have shown that the 3-year OS rate and 3-year RFS rate of the S-1 adjuvant chemotherapy group were significantly better than those of the observation group treated with surgery alone. However, certain prospective studies have shown that adjuvant chemotherapy did not have a positive effect on reducing recurrence and prolonging survival in patients who underwent surgery for ICC. The results of a phase III clinical trial by Edeline *et al* (13) have shown that the gemcitabine plus oxaliplatin regimen was not beneficial for patients with recurrent ICC. In another multicenter randomized controlled phase III trial for capecitabine adjuvant chemotherapy in patients who underwent surgery for ICC, an intent-to-treat analysis (14) showed that the median survival time of the capecitabine and observation group was 51.1 and 36.4 months, respectively; however, the difference was not statistically significant (P<0.097), The main end-point of the study was also not reached. In the prespecified per-protocol analysis, the median survival time of the capecitabine and observation group was 53 and 36 months, respectively and the difference was statistically significant (P=0.028). This patient received adjuvant chemotherapy with the 'capecitabine + oxaliplatin' regimen during treatment at another hospital. The local hospital examination showed that the progression of tumor recurrence was not controlled and the patient showed poor tolerance and experienced significant side effects during the chemotherapy treatment.

Currently, clinical trials investigating immune cell regulation therapy for ICC are relatively limited. Existing clinical data are mainly restricted to small-scale individual studies and sub-analyses of basket trials. The unique aspect of the patient of the present study is that she received adjuvant chemotherapy combined with immunotherapy followed by single immunotherapy. An open single-center phase II clinical study has shown that the combination of gemcitabine and cisplatin with immunotherapy demonstrated good efficacy and acceptable

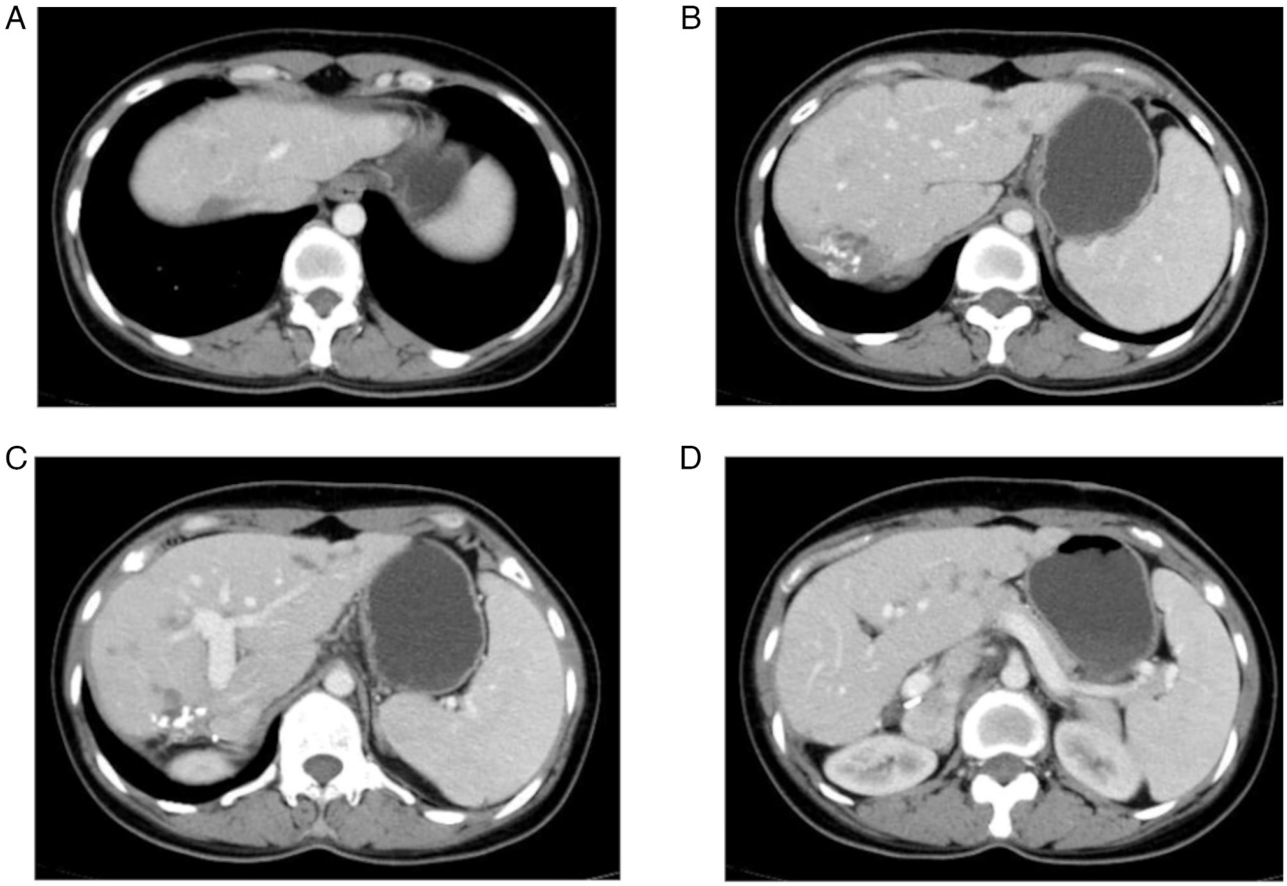


Figure 6. Portal venous phase of contrast-enhanced CT. A few metastases (low signal intensity) are visible in the hepatic parenchyma. The lesions significantly decreased in number and size six months after the time-point of Fig. 3. (A) The largest one is located in the dome of the right hepatic lobe (red arrow) and measures ~1.7 cm in diameter. (B) Hepatic segment SII showed the presence of multiple minimal metastases. (C) The imaging revealed the existence of minor metastases in hepatic segments SII, SV and SVIII. (D) Both hepatic segment SII and SIII exhibited the presence of small metastases.

safety in patients with unresectable or recurrent biliary tract cancer (BTC) (15). However, in the present case, the tumor progressed after three courses of adjuvant chemotherapy ('gemcitabine + oxaliplatin') combined with immunotherapy (durvalumab), which was accompanied by severe adverse reactions. Subsequently, the patient received single immunotherapy with durvalumab. The open multicenter phase I clinical basket study conducted by Doki *et al* (16) reported that durvalumab monotherapy showed acceptable safety and preliminary clinical activity in patients with BTC, including 42 patients with ICC. However, the patient of the present case study still failed to benefit from single immunotherapy and experienced unprecedented tumor progression.

Studies have found that most ICC cases present with abnormalities in FGFR2 fusion genes or functional mutations resulting from isocitrate dehydrogenase 1 or 2. Furthermore, FGFR2 fusion and rearrangement occur almost exclusively in ICC, affecting 10% of patients (17-19). The patient's gene sequencing results also confirmed an abnormal FGFR2 gene rearrangement status via FISH analysis of the sample. Pemigatinib, an FGFR1/2/3 selective inhibitor, has been approved for treating patients with ICC with FGFR2 gene fusion or rearrangement (20,21). In a multicenter open phase II clinical trial, patients with cholangiocarcinoma and FGFR2 fusion or rearrangement had an objective remission rate of 35.5%, median duration of response of 7.5 months, disease control rate of 82.2%, median progression-free survival of 6.9 months and median OS of 21.1 months (22). A similar phase II clinical trial conducted in Chinese patients has shown an encouraging tumor response and good safety profile, supporting the use of pemigatinib in previously treated patients with BTC with FGFR2 rearrangement (23). The patient of the present study also experienced significant tumor control and partial relief after receiving pemigatinib combined with durvalumab and did not experience any serious adverse reactions.

In conclusion, radical resection is currently the only curative treatment for patients with ICC. However, due to the tumor's high malignancy, recurrence rates are particularly high and prognosis is generally poor. Currently, postoperative adjuvant chemotherapy based on gemcitabine is the recommended first-line treatment for ICC. The efficacy of other adjunctive therapies, such as adjuvant chemotherapy combined with radiotherapy, radiotherapy alone and TACE, is controversial in current clinical studies and may cause serious adverse reactions (24-27). While PD-1/PD-L1 antibody-based immunotherapy is being investigated, there are no sufficient clinical data to support its use for postoperative patients with ICC, although research suggests that monotherapy with PD-1/PD-L1 antibodies or combined adjuvant chemotherapy may be effective for advanced ICC patients who cannot undergo surgical resection. Similarly, the combination of

targeted drugs and PD-1/PD-L1 antibody therapy is relatively mature in the field of HCC, but there are no relevant studies on the treatment of ICC. Most studies on pemigatinib have been conducted based on monotherapy but there are no reports on combination therapy with PD-1/PD-L1 antibody drugs. However, the efficacy observed in the patient of the present study warrants attention. In the future, immunotherapy combined with targeted therapy may provide certain benefits to patients with ICC, particularly those who have undergone radical surgery but experienced relapse and failed to respond to first-line adjuvant therapy.

**Acknowledgements**

Not applicable.

**Funding**

No funding was received.

**Availability of data and materials**

The datasets used and/or analyzed during the current study are available from the corresponding author on reasonable request.

**Authors' contributions**

GW and TT designed the research. BY analyzed the data and wrote the manuscript. LXZ, JWX, JWL and KFZ collected the patient's clinical data. GW, TT, BY, LXZ, JWX, JWL and KFZ contributed to the design and interpretation of the study, as well as drafting of the manuscript. GW and TT confirm the authenticity of all the raw data. All authors have read and agreed to the final version of the manuscript.

**Ethics approval and consent to participate**

Not applicable.

**Patient consent for publication**

Informed consent regarding the publication of data and images was obtained from the patient included in the study.

**Competing interests**

The authors declare that they have no competing interests.

**References**

1. Kelley RK, Bridgewater J, Gores GJ and Zhu AX: Systemic therapies for intrahepatic cholangiocarcinoma. J Hepatol 72: 353-363, 2020.
2. Esnaola NF, Meyer JE, Karachristos A, Maranki JL, Camp ER and Denlinger CS: Evaluation and management of intrahepatic and extrahepatic cholangiocarcinoma. Cancer 122: 1349-1369, 2016.
3. Yamamoto M, Takasaki K, Otsubo T, Katsuragawa H and Katagiri S: Recurrence after surgical resection of intrahepatic cholangiocarcinoma. J Hepatobiliary Pancreat Surg 8: 154-157, 2001.
4. Moris D, Palta M, Kim C, Allen PJ, Morse MA and Lidsky ME: Advances in the treatment of intrahepatic cholangiocarcinoma: An overview of the current and future therapeutic landscape for clinicians. CA Cancer J Clin 73: 198-222, 2023.
5. Eisenhauer EA, Therasse P, Bogaerts J, Schwartz LH, Sargent D, Ford R, Dancey J, Arbuck S, Gwyther S, Mooney M, *et al*: New response evaluation criteria in solid tumours: Revised RECIST guideline (version 1.1). Eur J Cancer 45: 228-247, 2009.
6. National Institutes of Health. Common Terminology Criteria for Adverse Events (CTCAE) version 5. Department of Health and Human Services, National Cancer Institute, Bethesda, ML, 2017
7. Spolverato G, Kim Y, Alexandrescu S, Marques HP, Lamelas J, Aldrighetti L, Clark Gamblin T, Maithel SK, Pulitano C, Bauer TW, *et al*: Management and outcomes of patients with recurrent intrahepatic cholangiocarcinoma following previous curative-intent surgical resection. Ann Surg Oncol 23: 235-243, 2016.
8. Ke Q, Lin N, Deng M, Wang L, Zeng Y and Liu J: The effect of adjuvant therapy for patients with intrahepatic cholangiocarcinoma after surgical resection: A systematic review and meta-analysis. PLoS One 15: e0229292, 2020.
9. Wang ML, Ke ZY, Yin S, Liu CH and Huang Q: The effect of adjuvant chemotherapy in resectable cholangiocarcinoma: A meta-analysis and systematic review. Hepatobiliary Pancreat Dis Int 18: 110-116, 2019.
10. Schweitzer N, Weber T, Kirstein MM, Fischer M, Kratzel AM, Reineke-Plaaß T, Lehner F, Manns MP and Vogel A: The effect of adjuvant chemotherapy in patients with intrahepatic cholangiocarcinoma: A matched pair analysis. J Cancer Res Clin Oncol 143: 1347-1355, 2017.
11. Reames BN, Bagante F, Ejaz A, Spolverato G, Ruzzenente A, Weiss M, Alexandrescu S, Marques HP, Aldrighetti L, Maithel SK, *et al*: Impact of adjuvant chemotherapy on survival in patients with intrahepatic cholangiocarcinoma: A multi-institutional analysis. HPB (Oxford) 19: 901-909, 2017.
12. Nakachi K, Ikeda M, Konishi M, Nomura S, Katayama H, Kataoka T, Todaka A, Yanagimoto H, Morinaga S, Kobayashi S, *et al*: Adjuvant S-1 compared with observation in resected biliary tract cancer (JCOG1202, ASCOT): A multicentre, open-label, randomised, controlled, phase 3 trial. Lancet 401: 195-203, 2023.
13. Edeline J, Benabdelghani M, Bertaut A, Watelet J, Hammel P, Joly JP, Boudjema K, Fartoux L, Bouhier-Leporrier K, Jouve JL, *et al*: Gemcitabine and oxaliplatin chemotherapy or surveillance in resected biliary tract cancer (PRODIGE 12-ACCORD 18-UNICANCER GI): A randomized phase III study. J Clin Oncol 37: 658-667, 2019.
14. Primrose JN, Fox RP, Palmer DH, Malik HZ, Prasad R, Mirza D, Anthony A, Corrie P, Falk S, Finch-Jones M, *et al*: Capecitabine compared with observation in resected biliary tract cancer (BILCAP): A randomised, controlled, multicentre, phase 3 study. Lancet 20: 663-673, 2019.
15. Oh DY, Lee KH, Lee DW, Yoon J, Kim TY, Bang JH, Nam AR, Oh KS, Kim JM, Lee Y, *et al*: Gemcitabine and cisplatin plus durvalumab with or without tremelimumab in chemotherapy-naive patients with advanced biliary tract cancer: An open-label, single-centre, phase 2 study. Lancet Gastroenterol Hepatol 7: 522-532, 2022.
16. Doki Y, Ueno M, Hsu CH, Oh DY, Park K, Yamamoto N, Ioka T, Hara H, Hayama M, Nii M, *et al*: Tolerability and efficacy of durvalumab, either as monotherapy or in combination with tremelimumab, in patients from Asia with advanced biliary tract, esophageal, or head-and-neck cancer. Cancer Med 11: 2550-2560, 2022.
17. Graham RP, Barr Fritcher EG, Pestova E, Schulz J, Sitailo LA, Vasmatzis G, Murphy SJ, McWilliams RR, Hart SN, Halling KC, *et al*: Fibroblast growth factor receptor 2 translocations in intrahepatic cholangiocarcinoma. Hum Pathol 45: 1630-1638, 2014.
18. Kipp BR, Voss JS, Kerr SE, Barr Fritcher EG, Graham RP, Zhang L, Highsmith WE, Zhang J, Roberts LR, Gores GJ and Halling KC: Isocitrate dehydrogenase 1 and 2 mutations in cholangiocarcinoma. Hum Pathol 43: 1552-1558, 2012.
19. Ross JS, Wang K, Gay L, Al-Rohil R, Rand JV, Jones DM, Lee HJ, Sheehan CE, Otto GA, Palmer G, *et al*: New routes to targeted therapy of intrahepatic cholangiocarcinomas revealed by next-generation sequencing. Oncologist 19: 235-242, 2014.
20. Zen Y: Intrahepatic cholangiocarcinoma: Typical features, uncommon variants, and controversial related entities. Hum Pathol 132: 197-207, 2023.
21. Wang XY, Zhu WW, Wang Z, Huang JB, Wang SH, Bai FM, Li TE, Zhu Y, Zhao J, Yang X, *et al*: Driver mutations of intrahepatic cholangiocarcinoma shape clinically relevant genomic clusters with distinct molecular features and therapeutic vulnerabilities. Theranostics 12: 260-276, 2022.

22. Abou-Alfa GK, Sahai V, Hollebecque A, Vaccaro G, Melisi D, Al-Rajabi R, Paulson AS, Borad MJ, Gallinson D, Murphy AG, *et al*: Pemigatinib for previously treated, locally advanced or metastatic cholangiocarcinoma: A multicentre, open-label, phase 2 study. Lancet Oncol 21: 671-684, 2020.
23. Shi GM, Huang XY, Wen TF, Song TQ, Kuang M, Mou HB, Bao LQ, Zhao HT, Zhao H, Feng XL, *et al*: Pemigatinib in previously treated Chinese patients with locally advanced or metastatic cholangiocarcinoma carrying FGFR2 fusions or rearrangements: A phase II study. Cancer Med 12: 4137-4146, 2023.
24. Kim YS, Oh SY, Go SI, Kang JH, Park I, Song HN, Ji JH, Hwang IG and Jang JS: The role of adjuvant therapy after R0 resection for patients with intrahepatic and perihilar cholangiocarcinomas. Cancer Chemother Pharmacol 79: 99-106, 2017.
25. Kim KS, Kim HY, Kim K, Yi NJ, Suh K and Chie EK: Postoperative chemoradiotherapy for R1 resected intrahepatic cholangiocarcinoma. J Liver Cancer 18: 115-120, 2018.
26. Li T, Qin LX, Zhou J, Sun HC, Qiu SJ, Ye QH, Wang L, Tang ZY and Fan J: Staging, prognostic factors and adjuvant therapy of intrahepatic cholangiocarcinoma after curative resection. Liver Int 34: 953-960, 2014.
27. Wu ZF, Zhang HB, Yang N, Zhao WC, Fu Y and Yang GS: Postoperative adjuvant transcatheter arterial chemoembolisation improves survival of intrahepatic cholangiocarcinoma patients with poor prognostic factors: Results of a large monocentric series. Eur J Surg Oncol 38: 602-610, 2012.