SPANDIDOS PUBLICATIONS

ONCOLOGY LETTERS 27: 168, 2024

Hepatocellular carcinoma in a transplanted donor liver and colon cancer developing in a patient with a complex background: A case report

SAYOKO SUMIYOSHI[1], TERUMI TAKAHARA[2], KAZUTO SHIBUYA[3], JOHJI IMURA[4], AKIRA NOGUCHI[1], KAZUTO TAJIRI[2], MASAMI MINEMURA[2], TSUTOMU FUJII[4] and KENICHI HIRABAYASHI[1]

[1]Department of Diagnostic Pathology; [2]Third Department of Medicine; [3]Department of Surgery and Sciences, Faculty of Medicine, Academic Assembly, University of Toyama, Toyama 930-0194; [4]Department of Diagnostic Pathology, Kumagaya General Hospital, Kumagaya, Saitama 360-8567, Japan

Received April 5, 2023; Accepted August 23, 2023

DOI: 10.3892/ol.2024.14301

Abstract. The development of tumors in livers transplanted from hepatitis B virus (HBV)-negative donors to patients with hepatitis B and cirrhosis is rare. The present study describes the case of a woman in her 60s who developed hepatocellular carcinoma (HCC) in her grafted liver, 19 years after transplantation, as well as a metachronous colorectal tumor. The pathological findings, including clinical, immunohistochemical and molecular results, are described in the present case report. The liver tumor was a conventional HCC and the colorectal tumor comprised a tubular adenocarcinoma. Immunohistochemistry of both tumors showed a loss of expression of mutL homolog 1 and postmeiotic segregation increased 2 in the tumor cells, confirming microsatellite instability-high (MSI-H) status. Furthermore, a molecular study detected the presence of genes located on the Y chromosome in the normal and tumor tissues of the liver, proving that the HCC occurred in the grafted liver. The present report also discusses that prolonged use of immunosuppressive drugs to prevent post-transplant rejection, poorly controlled diabetes mellitus and MSI-H may have contributed to the risk of tumor development.

Correspondence to: Dr Johji Imura, Department of Diagnostic Pathology, Kumagaya General Hospital, 4-5-1 Nakanishi, Kumagaya, Saitama 360-8567, Japan
E-mail: imura8600@gmail.com

Abbreviations: HCC, hepatocellular carcinoma; HBV, hepatitis B virus; HCV, hepatitis C virus; HBsAg, hepatitis B surface antigen; PCR, polymerase chain reaction; C-EF, capillary electrophoresis; MLH1, mutL homolog 1; PMS2, postmeiotic segregation increased 2; MSH, mutS homolog; MSI-H, microsatellite instability-high; IGF-1, insulin-like growth factor-1; MMR, mismatch repair

Key words: HCC, transplantation, colon cancer, HBV, immunosuppressant, diabetes mellitus, MSI

Introduction

It is not uncommon for hepatocellular carcinoma (HCC) to recur in HCC patients after liver transplantation (1). In contrast, reports of de novo HCC developing in a healthy donor liver, transplanted to a patient without a history of HCC, are extremely rare (2-16). A review of the case reports of HCC in transplanted livers reveals hepatitis B (5-7,10,15,17), C (2,8,10-13,18) and sclerosing cholangitis (18,19) as underlying diseases. Chronic viral hepatitis is an important factor in the development of HCC and, for both hepatitis B virus (HBV) and hepatitis C virus (HCV), there are many cases in which HCC develops after a long period of persistent infection. Especially for HBV, it is generally accepted that most individuals develop hepatitis in adulthood from a persistent infection following vertical transmission, progressing to liver cirrhosis and the development of HCC. In addition, the immunosuppressants used to prevent post-transplant rejection are among the factors contributing to the development of post-transplant HCC (20). Furthermore, it has been reported that patients with glucose intolerance, such as diabetes, have a high risk of developing malignancies. For example, patients with diabetes are more than twice as likely as non-diabetics to develop liver tumors (17,21-29). In addition, the involvement of microsatellite instability in the development of liver tumors is also important, and cases of comorbidity with cancers in other organs also have been reported (30-34).

This report describes the case of a poorly controlled diabetes mellitus patient who underwent living-donor liver transplantation, from an HBV-negative donor, for cirrhosis attributable to HBV infection. The recipient developed not only HCC but also colon cancer, both tumors having microsatellite instabilities, the status MSI-high.

Case report

The patient was a woman in her sixties who had been diagnosed with hepatitis B thirty years previously and given continuous medical treatment. At that time, she was also diagnosed with diabetes mellitus and started on insulin

administration. In August 1999, seven years after her first visit in April 1992 at Toyama, Japan, she underwent a living-donor liver transplantation from her husband at Matsumoto, Japan, who was HBV- and HCV-negative, to treat liver failure due to cirrhosis. Her resected liver showed non-neoplastic complete cirrhosis and was confirmed not to be included in the neoplastic lesions by the detailed histopathological examination. Specifically, the paraffin sections made from the samples of multiple sites from resected recipient liver, whenever possible, were examined by several pathologists subspecialized in liver pathology. After surgery, steroids (methylprednisolone, 3 mg/day for half a year, prednisolone, 1 mg/every other day for nine years, and Tacrolimus, a calcineurin inhibitor, from 1.2 mg to 0.4 mg/day gradually tapered down to maintain blood levels of 4-6 ng/ml to present were started as immunosuppressive drugs to suppress rejection. Lamivudine (100 mg/day from February 1999 to November 2015), Entecavir (0.5 mg/day from November 2015 to February 2020), and Tenofovir alafenamide fumarate (25 mg/day from February 2020 to present), an antiviral agent, and immunoglobulin (Hepatitis B immunoglobulin, every week) was started for HBV treatment. However, her diabetes was poorly controlled and she was in and out of hospital. In February 2018, nineteen years after liver transplantation, a mass lesion was noted in segment four of the transplanted liver (Fig. 1A and B), and a subsegmental liver resection was performed under the diagnosis of a liver tumor at Toyama, Japan. The following year, she underwent a colonoscopy for screening purposes; this revealed colon cancer in her cecum and she underwent an ileocecal resection in March 2019 at the same hospital. The following year, a mass lesion was found on the surface of the right liver lobe, segment 8 (Fig. 2A and B), and radiofrequency ablation was performed on suspicion of recurrence of the hepatocellular carcinoma, followed by additional resection in December 2020 at the same hospital. Four years after the final operation, no recurrence of the liver tumor or malignant tumors have been found, including in other organs. The amount of HBV DNA in the serum before transplantation was 3.8 logs IU/ml (TMA), after which hepatitis B surface antigen (HBsAg) and HBV DNA became negative. To date, HBsAg, anti-HBs, anti-HB core, anti-HB envelope, and HBV DNA by real-time PCR has been detected in serum.

The initial liver tumor showed circumscribed encapsulization but it had no extracapsular invasion and was diagnosed with moderately differentiated HCC, aligned in a trabecular pattern, based on the histopathologically cellular and structural atypia. Vascular invasion, exposure to the surgical stump, and intrahepatic metastasis were not observed (pT1NXM0) (Fig. 3A and B). The second hepatic tumor had a similar histological appearance, without vascular invasion (Fig. 4A and B). The colon cancer was mainly located in the cecum and comprised a well-differentiated tubular adenocarcinoma, invading the subserosal layer and accompanied by regional lymph node metastasis (pT3N1MX, pStage IIIb) (35) (Fig. 5A and B). The diagnosis of each of the above tumor tissues was made histopathologically by two pathologists (JI and AN) using the hematoxylin-eosin staining formalin-fixed paraffin sections of each sample. Monitoring for the recurrence of liver tumors and colon cancer was done every six months using abdominal enhanced-computed tomography.

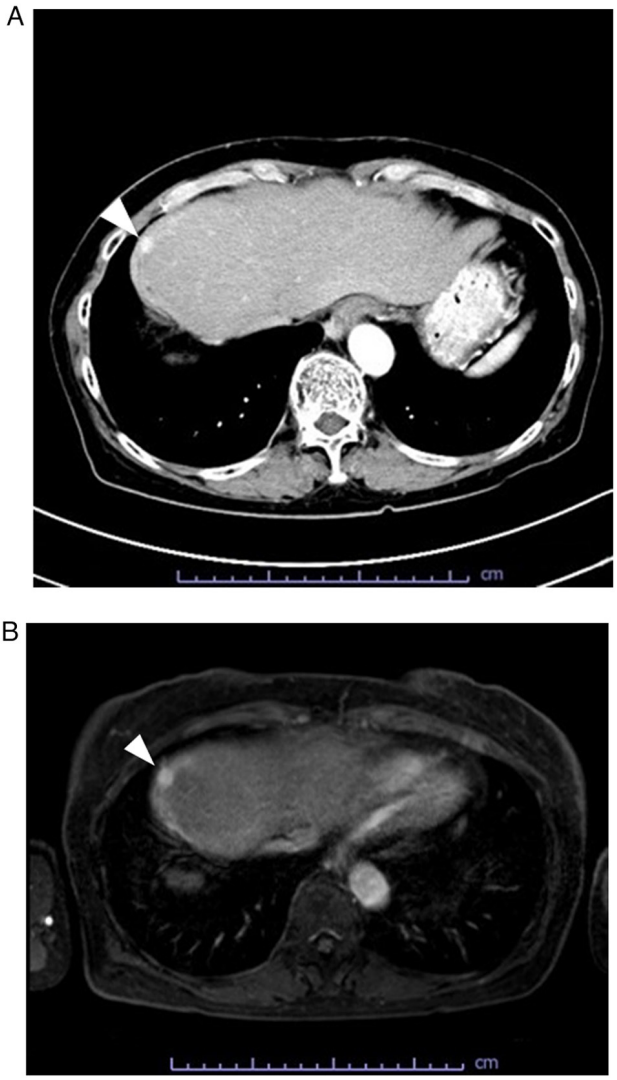

Figure 1. (A) Abdominal enhanced computed tomography and (B) T1-weighted magnetic resonance tomography before the first operation. The images show a nodule with early enhancement in the segment four area, in the arterial phase. Arrowheads indicate the tumor.

The total follow-up period is 30 years from the time of initial administration.

In order to determine whether the initial liver tumor was donor- or recipient-derived, genomic DNA was extracted from both liver tumors and non-tumor tissue and analyzed for the specific genes, *SRT*, *STS*, and *Amelogenin*, as genes located on the Y chromosome. Amplification was performed by polymerase chain reaction (PCR) and the products were confirmed by capillary electrophoresis (C-EF) (36,37). The presence of the *SRT-a-Y*, *AMEL-Y*, *SRY-b-Y*, and *STS-1-Y* genes on the Y chromosome in both liver tumors and non-liver tissues indicated that they originated from the liver donated by the husband, a male (Fig. 6). In addition, PCR was performed using a microsatellite marker (D17S938) to determine whether the primary and recurrent liver tumors were derived from the same clone (38). A peak, indicating expression in the normal liver tissue (Fig. 7, upper trace), was not detected in either tumor (Fig. 7, lower traces). Considering that the site of recurrence was near the initial lesion, recurrence due to intrahepatic metastasis was diagnosed. To

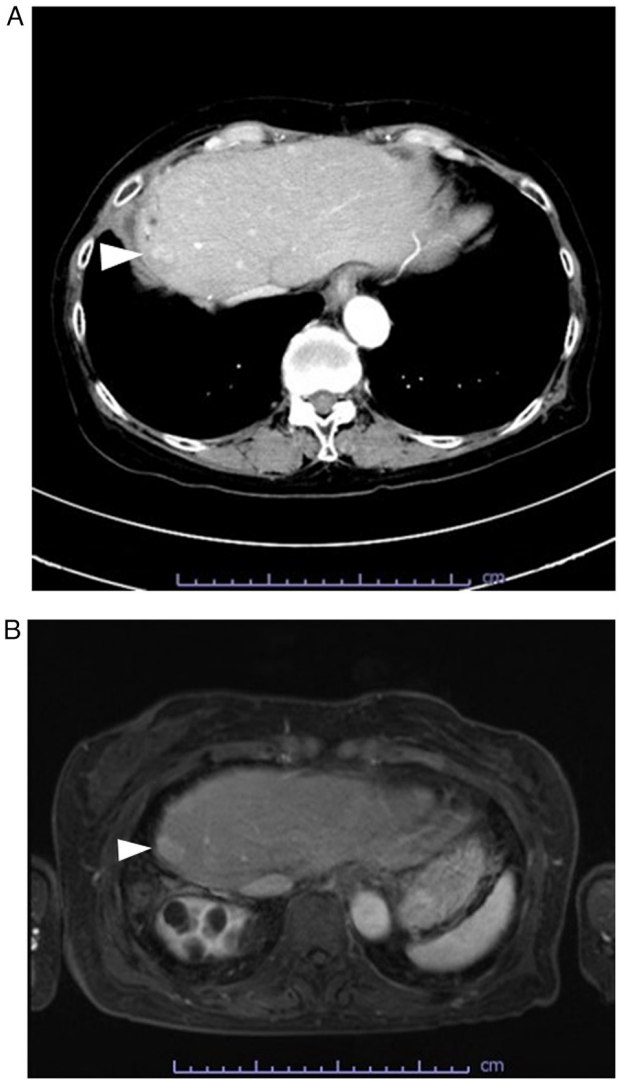

Figure 2. (A) Abdominal enhanced computed tomography and (B) T1-weighted magnetic resonance tomography of the recurrent tumor. The images show a nodule with early enhancement in the segment eight area, in the arterial phase. Arrowheads indicate the tumor.

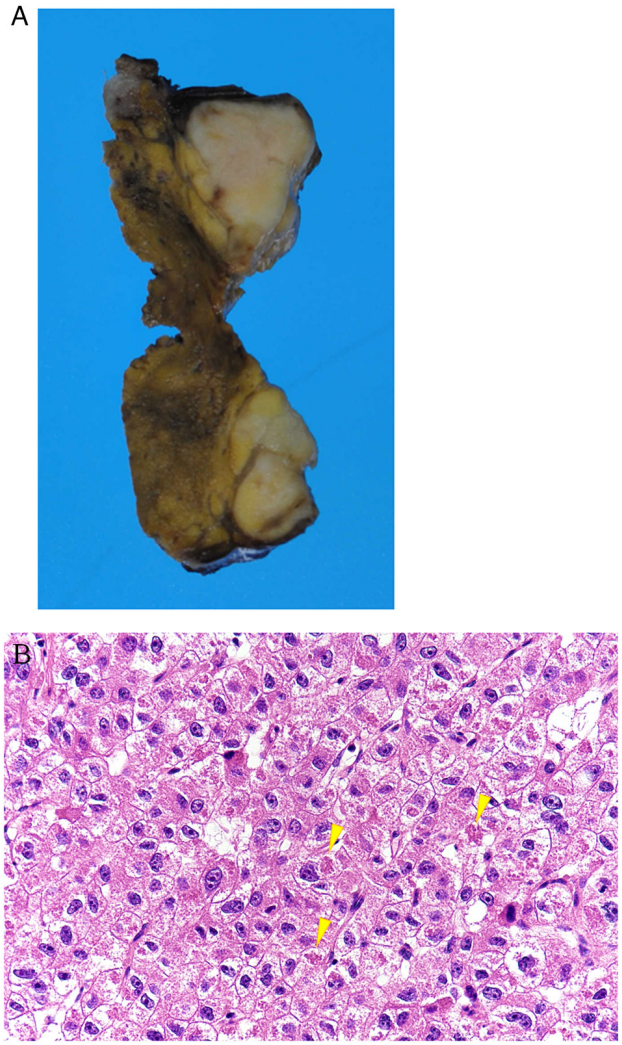

Figure 3. Macroscopic and histological findings of the primary tumor. (A) A relatively well-defined, bright yellowish nodule exposed on the cut surface. (B) The tumor, comprising a hepatocellular carcinoma with a trabecular pattern. The tumor cells having distinct Mallory-Denk bodies in their cytoplasm (arrowheads).

confirm that the serum was HBV DNA negative before transplantation and to determine whether the viral genome was present in the liver tumors and non-tumor liver tissues, PCR was performed using specific HBV DNA primers and confirmed by C-EF. The conditions for PCR amplification of HBV DNA and the used primer sequences were as followed. To obtain total HBV DNA, amplification was performed by PCR conditioning for 3 min at 94˚C and then 30 sec at 94˚C, 45 sec at 58˚C, and 30 sec at 72˚C to be repeated 40 cycles, using primers of HBV forward CAACCTCCAATCACT CACCAAC and HBV reverse ACGGGCAACATACCTTGG TAG (39). No amplified product was observed, confirming that no HBV DNA was present in any of the tissues. To investigate the causal relationship between the development of the three tumors of the liver and the colon and microsatellite instability, immunohistochemical studies were performed on four microsatellite regions in mutL homolog 1 (MLH1), postmeiotic segregation increased 2 (PMS2), mutS homolog 2 (MSH2) and MSH6 (40). Of these four factors, MLH1 and PMS2 confirmed the absence of nuclear expression in the liver and colorectal tumors, and MSH2 and MSH6 were retained in the nucleus, indicating that the three lesions were tumors with microsatellite instability-high (MSI-H) (Fig. 8A-C).

Discussion

Hepatocarcinogenesis appears to be a multistep process, involving disruption of genetic stability, and in which normal hepatocytes are transformed into liver cancer via chronic hepatitis, with persistent HBV or HCV infection, and subsequent cirrhotic conditions (32,33,41). It is generally accepted that the hepatitis viruses are strongly implicated in liver cancer development. However, the serological findings suggested the patient's HBV infection had not persisted after the antiviral treatment, possibly due to the remarkable efficacy of the antiviral drugs in this case. Although it cannot be shown that HBV has completely disappeared from the patient's body, at least it cannot be considered that HBV DNA remained detectable in the liver tissue. Therefore, although it cannot be completely ruled out that HBV was somehow involved in the development

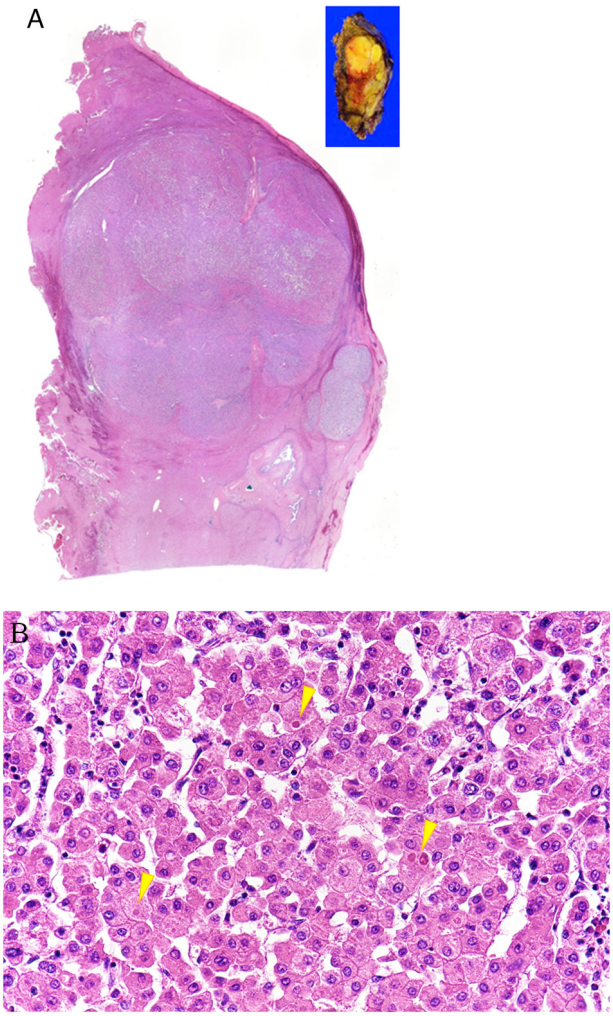

Figure 4. Macroscopic and histological findings of the second tumor. (A) Loupe figure of the pathological specimen. The tumor showing fused multinodular lesions (insert). Well-defined, yellowish multi-nodular tumor exposed on the cut surface. (B) The tumor showing similar histological findings to the primary liver tumor. The tumor cells having round to oval and deeply eosinophilic hyaline bodies in their cytoplasm (arrowheads).

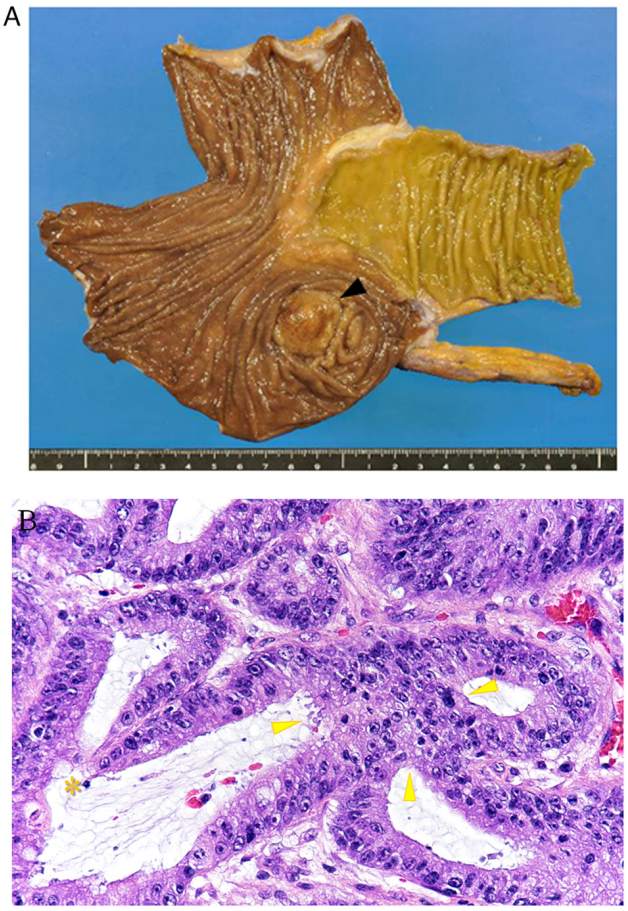

Figure 5. Macroscopic and histological findings of the cecal tumor. (A) A slightly elevated tumor, located in the cecum (arrowhead). (B) Histology, the tumor was moderately differentiated tubular adenocarcinoma. Tumor tissue revealing fused glands (arrowheads) and irregular branching (*).

of liver cancer in this case, there is a high possibility that other triggers were involved.

The involvement of immunosuppressants, administered to this patient for an extended period of time, also should be considered as a potential carcinogenesis-inducing factor. Many transplant patients have to take immunosuppressants for an extended period of time to prevent rejection. The most typical side effect of immunosuppressants is an increased susceptibility to infection, but they have also been reported to increase the risk of carcinogenesis, albeit in a small number of cases (20). Azathioprine is well-known as an immunosuppressant used after transplantation and there is a report confirming its oncogenicity to normal cells, as a result of long-term exposure in an *in vivo* experimental model. Tacrolimus, a calcineurin inhibitor administered to the patient in this case, is widely used worldwide as an immunosuppressant for transplant patients. The mechanism by which Tacrolimus promotes the onset and progression of cancer is not yet well understood. Reports suggest that inhibition of the immune system not only weakens the recipient's immune response but also impairs the ability of the tumor immune system to respond to early-stage tumor cells and their associated antigens (42). An indirect correlation between the ability to prevent rejection and the risk of developing tumors may support this notion. There is also evidence that Tacrolimus may directly promote the aggressiveness and invasiveness of tumor cells, including DNA damage induced by immunosuppressants and activation of cytokines such as TGF-β (43). The patient in the present case also has been administered immunosuppressive drugs for nearly 20 years. Although a definitive basis cannot be proved, the patient's immunosuppression may have been involved in her developing liver cancer. In the future, it may be worthwhile considering managing withdrawal from immunosuppressive drugs, reducing the dose, or switching to other medications.

It has been reported that diabetes is a risk factor for developing malignant tumors. The mechanism by which impaired glucose tolerance causes carcinogenesis remains a matter of speculation, but it has been suggested that diabetes is strongly involved in carcinogenesis in many organs (24,29,44,45). Especially in liver cancer, type 2 diabetes mellitus is an established independent risk factor for both nonalcoholic fatty liver disease and HCC. Independent of the coexistence of cirrhosis or another etiology, patients with type 2 diabetes have been reported to have a 2.5- to 4-fold increased risk of developing HCC (3,23,25,27). There also appears to be an increased risk

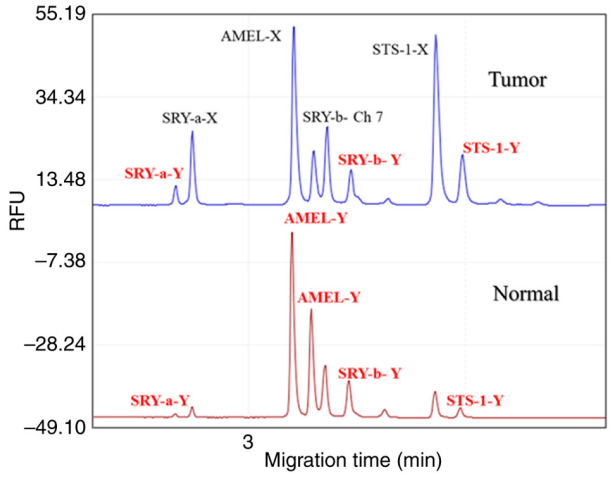

Figure 6. Capillary electrogram of the polymerase chain reaction products of genes located on the Y chromosome and amplified from primary and normal liver tissue. Both electrograms feature similar peaks, suggested SRY-a-Y, AMEL-Y, SRY-b-Y, and STS-Y gene products.

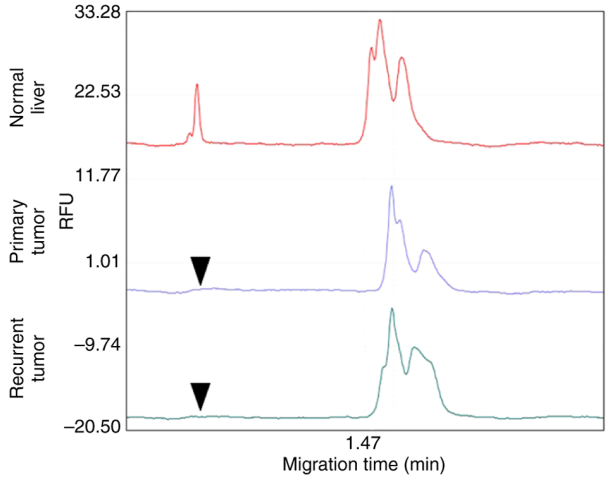

Figure 7. Capillary electrogram of polymerase chain reaction products for D17S938, as a microsatellite marker. The peak derived from normal liver tissue was not obtained from the primary and second liver tumors (arrowheads).

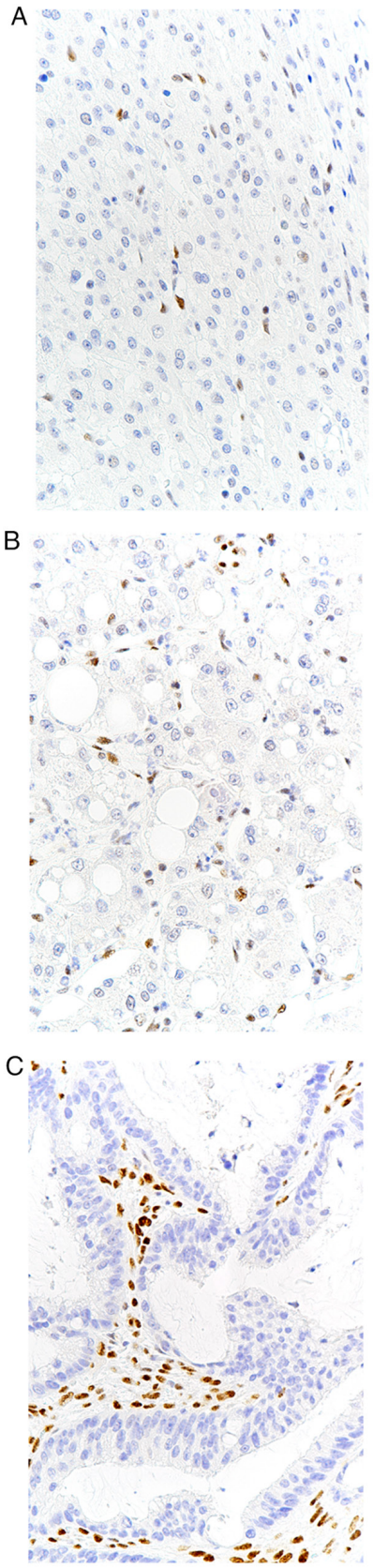

Figure 8. Immunohistochemistry for MLH1 in the liver and colon cancers. (A) Primary, (B) recurrent hepatocellular carcinoma and (C) colon carcinoma. Nuclear expression of MLH1 detected lymphocytes and vascular endothelial cells as internal controls but was not detected in the tumor cells.

of developing HCC in patients with long-standing uncontrolled diabetes mellitus (5,17). Furthermore, 10 to 15% of liver transplant recipients are said to have type 2 diabetes, and patients with underlying diabetes mellitus are considered at a higher risk of developing HCC (46). In these previous reports, because insulin produced in the islets of the pancreas is transported to the liver via the portal vein, the long-term exposure of hepatic cells to insulin secreted in a hyperglycemic state may increase the risk of developing liver cancer (21). In addition, hyperglycemia acts to promote tumor growth and there are many factors that promote carcinogenesis, such as hyperinsulinemia through effects on insulin and/or insulin-like growth factor-1 (IGF-1) receptors and inflammatory cytokines secreted from adipose tissue. Furthermore, insulin resistance and activation of the insulin receptor and IGF-1 have been implicated as one of the major determinants in the initiation and progression of the multistep carcinogenic process of colorectal cancer (22). Diabetes is also known to increase the risk of developing colorectal cancer (47). It is believed that hyperinsulinemia

in diabetes promotes the development and progression of colorectal cancer by delaying the intestinal transit time of feces and increasing the concentration of bile acids in the feces. This patient also had had diabetes mellitus since her hepatic failure and was receiving insulin therapy, but her diabetes was poorly controlled and she had persistent hyperglycemia, as shown by her high glycated hemoglobin (HbA1c) level (11.1%). It may not be a coincidence that HCC and colon cancer developed in such a state. In the future, potent diabetes treatment may be necessary, along with monitoring the immunosuppressive drugs.

Microsatellite instability is one of the factors that triggers carcinogenesis. It is common knowledge that MSI is closely involved in familial colon and endometrial cancer, typified by Lynch syndrome (48). Recent studies have revealed multiple genetic alterations in hepatocarcinogenesis, the most important of which involve mismatch repair (MMR) genes (30). It has been confirmed immunohistologically that microsatellite markers, such as MLH1 and PMS2, are lost from tumor cells in both primary and recurrent liver and colorectal cancer. Without a family history of Lynch syndrome in the patient's background, the development of MSI-positive cancer may be described as sporadic. However, MSI-positive liver cancer has been reported to occur, albeit less commonly than in colorectal cancer (34). Although immunohistochemical studies of MMR genes in HCC are scarce (31,40,49,50), this is an accurate method for identifying MMR defects, with sensitivity and specificity of 97 and 100%, respectively (51). Helal *et al* reported that the proportions of hMSH2 and hMLH1 protein downregulation in the HCC cases studied were 64 and 70%, respectively (40). On the other hand, in Japanese patients, hMSH2 and hMLH1 are implicated in around 20% (31,50) but, in the United States, no reduction or disappearance has been reported (49). The difference in the association between HCC and MSI in Japan/United States and Egypt may be due to racial differences or differences in the HBV genotypes, but the possibility that HCC development is affected by factors other than MSI cannot be ruled out. However, considering that the instability of the MSI gene is a somatic mutation, it is not unreasonable to speculate that MSI could have been caused in the donor's liver by some other trigger, such as the immunosuppressive drugs or abnormal glucose tolerance mentioned above.

Many case reports of the development of HCC after liver transplantation involve the use of fluorescent *in situ* hybridization to the Y chromosome to determine whether the tumor is derived from the original or grafted liver (2,18). Instead of that method, this report features a pathomolecular study, amplifying the *SRT-a-Y*, *AMEL-Y*, *SRY-b-Y*, and *STS-1-Y* genes located on the Y chromosome, an approach used in the field of forensic medicine (36,37). It was confirmed that these genes were present in the normal liver and its tumors and proved that the patient's liver tissue was derived from the donor. This method can be considered a highly sensitive and specific modality for analyzing even a very small sample. However, the disadvantage of this method is that the recipient and donor must be of opposite sexes. This report is of a case in which HCC developed in liver tissue derived from the donor, but if the gene located on the Y chromosome had not been detected, the tumor might have been derived from the recipient. The patient's liver had been resected entirely, so that no remnant liver was present. However, the possibility of liver cell renewal by hepatocytes derived from bone marrow stem cells cannot be completely ruled out.

In summary, the carcinogenic process of HCC in the grafted liver and colon cancer in the present case is related to immunosuppressants administered after transplantation, poor control of diabetes mellitus, MSI, and the interaction of these factors.

Acknowledgements

The authors would like to thank Mrs. Akiko Shimomura, Mr. Takeshi Nishida and Mr. Hideki Hatta (Department of Diagnostic Pathology, Faculty of Medicine, Academic Assembly, University of Toyama) for their advice and assistance in the pathological and molecular analysis throughout this case report.

Funding

No funding was received.

Availability of data and materials

All data generated and analyzed during this study are included in this published article.

Authors' contributions

SS and JI conceptualized this case report. TT, MM and KT carried out the internal medicine treatment and follow-up. KS and TF performed the surgery. SS, AN, KH and JI performed the histopathological and molecular examinations, and analyzed the data from the patient's cancer tissue. SS and JI wrote and prepared the original draft; TT, KS, AN, KT, MM, TF and KH reviewed the manuscript and confirm the authenticity of all the raw data. All authors read and approved the final manuscript.

Ethics approval and consent to participate

Not applicable.

Patient consent for publication

The patient provided written informed consent for the publication of any data and/or accompanying images.

Competing interests

The authors declare that they have no competing interests.

References

1. Hoffman D and Mehta N: Recurrence of hepatocellular carcinoma following liver transplantation. Expert Rev Gastroenterol Hepatol 15: 91-102, 2021.
2. Al-Joundi T, Gibson S, Brunt EM, Shakil O, Lee RS and Di Bisceglie AM: Delayed recurrence of hepatocellular carcinoma after liver transplantation: Detection of origin by chromosomal analysis. Liver Transpl 6: 374-375, 2000.

3. Allaire M and Nault JC. Type 2 diabetes-associated hepatocellular carcinoma: A molecular profile. Clin Liver Dis (Hoboken) 8: 53-58, 2016.
4. Croitoru A, Schiano TD, Schwartz M, Roayaie S, Xu R, Suriawinata A and Fiel MI: De novo hepatocellular carcinoma occurring in a transplanted liver: Case report and review of the literature. Dig Dis Sci 51: 1780-1782, 2006.
5. El-Domiaty N, Saliba F, Sebagh M, Salloum C, Vibert E, Azoulay D, Hamelin J, Cherqui D, Adam R and Samuel D: De novo hepatocellular carcinoma in a non-cirrhotic allograft 27 years after liver transplantation: A case report. Am J Transplant 21: 1953-1958, 2021.
6. Flemming P, Tillmann HL, Barg-Hock H, Kleeberger W, Manns MP, Klempnauer J and Kreipe HH: Donor origin of de novo hepatocellular carcinoma in hepatic allografts. Transplantation 76: 1625-1627, 2003.
7. Kita Y, Klintmalm G, Kobayashi S and Yanaga K: Retransplantation for de novo hepatocellular carcinoma in a liver allograft with recurrent hepatitis B cirrhosis 14 years after primary liver transplantation. Dig Dis Sci 52: 3392-3393, 2007.
8. Levitsky J, Faust TW, Cohen SM and Te HS: Group G streptococcal bacteremia and de novo hepatocellular carcinoma after liver transplantation. Liver Transpl 8: 572, 2002.
9. Morita K, Taketomi A, Soejima Y, Ikegami T, Fukuhara T, Iguchi T, Nagata S, Sugimachi K, Gion T, Shirabe K and Maehara Y: De novo hepatocellular carcinoma in a liver graft with sustained hepatitis C virus clearance after living donor liver transplantation. Liver Transpl 15: 1412-1416, 2009.
10. Navarro Burgos JB, Lee KW, Shin YC, Lee DS, Lee KB, Yi NJ and Suh KS: Inexplicable outcome of early appearance of hepatocellular carcinoma in the allograft after deceased donor liver transplantation: A case report. Transplant Proc 47: 3012-3015, 2015.
11. Ramadori G, Bosio P, Moriconi F and Malik IA: Case report: 8 years after liver transplantation: De novo hepatocellular carcinoma 8 months after HCV clearance through IFN-free antiviral therapy. BMC Cancer 18: 257, 2018.
12. Saab S, Zhou K, Chang EK and Busuttil RW: De novo Hepatocellular Carcinoma after Liver Transplantation. J Clin Transl Hepatol 3: 284-287, 2015.
13. Saxena R, Ye MQ, Emre S, Klion F, Nalesnik MA and Thung SN: De novo hepatocellular carcinoma in a hepatic allograft with recurrent hepatitis C cirrhosis. Liver Transpl Surg 5: 81-82, 1999.
14. Sotiropoulos GC, Frilling A, Molmenti EP, Brokalaki EI, Beckebaum S, Omar OS, Broelsch CE and Malagó M: De novo hepatocellular carcinoma in recurrent liver cirrhosis after liver transplantation for benign hepatic disease: Is a deceased donor re-transplantation justified? Transplantation 82: 1112, 2006.
15. Torbenson M, Grover D, Boitnott J, Klein A and Molmenti E: De novo hepatocellular carcinoma in a liver allograft associated with recurrent hepatitis B. Transplant Proc 37: 2205-2206, 2005.
16. Yu S, Guo H, Zhuang L, Yu J, Yan S, Zhang M, Wang W and Zheng S: A case report of de novo hepatocellular carcinoma after living donor liver transplantation. World J Surg Oncol 11: 176, 2013.
17. Yoo JJ, Cho EJ, Han K, Heo SS, Kim BY, Shin DW and Yu SJ: Glucose variability and risk of hepatocellular carcinoma in patients with diabetes: A nationwide population-based study. Cancer Epidemiol Biomarkers Prev 30: 974-981, 2021.
18. Tame M, Calvanese C, Cucchetti A, Gruppioni E, Colecchia A and Bazzoli F: The onset of de novo hepatocellular carcinoma after liver transplantation can be both of donor and recipient origin. A case report. J Gastrointestin Liver Dis 24: 387-389, 2015.
19. Allaire M, Seree O, Coilly A, Houssel-Debry P, Neau-Cransac M, Pageaux GP, Dumortier J and Altieri M: De novo primary liver cancer after liver transplantation: A French National Study on 15803 Patients. Exp Clin Transplant 16: 779-780, 2018.
20. Vajdic CM and van Leeuwen MT: Cancer incidence and risk factors after solid organ transplantation. Int J Cancer 125: 1747-1754, 2009.
21. Giovannucci E, Harlan DM, Archer MC, Bergenstal RM, Gapstur SM, Habel LA, Pollak M, Regensteiner JG and Yee D: Diabetes and cancer: A consensus report. Diabetes Care 33: 1674-1685, 2010.
22. Hung CH, Wang JH, Hu TH, Chen CH, Chang KC, Yen YH, Kuo YH, Tsai MC, Lu SN and Lee CM: Insulin resistance is associated with hepatocellular carcinoma in chronic hepatitis C infection. World J Gastroenterol 16: 2265-2271, 2010.
23. Inoue M, Iwasaki M, Otani T, Sasazuki S, Noda M and Tsugane S: Diabetes mellitus and the risk of cancer: Results from a large-scale population-based cohort study in Japan. Arch Intern Med 166: 1871-1877, 2006.
24. Lin CM, Huang HL, Chu FY, Fan HC, Chen HA, Chu DM, Wu LW, Wang CC, Chen WL, Lin SH and Ho SY: Association between gastroenterological malignancy and diabetes mellitus and anti-diabetic therapy: A nationwide, population-based cohort study. PLoS One 10: e0125421, 2015.
25. Mantovani A and Targher G: Type 2 diabetes mellitus and risk of hepatocellular carcinoma: Spotlight on nonalcoholic fatty liver disease. Ann Transl Med 5: 270, 2017.
26. van Kruijsdijk RC, van der Wall E and Visseren FL: Obesity and cancer: The role of dysfunctional adipose tissue. Cancer Epidemiol Biomarkers Prev 18: 2569-2578, 2009.
27. Wang C, Wang X, Gong G, Ben Q, Qiu W, Chen Y, Li G and Wang L: Increased risk of hepatocellular carcinoma in patients with diabetes mellitus: A systematic review and meta-analysis of cohort studies. Int J Cancer 130: 1639-1648, 2012.
28. Wojciechowska J, Krajewski W, Bolanowski M, Krecicki T and Zatonski T: Diabetes and Cancer: A Review of Current Knowledge. Exp Clin Endocrinol Diabetes 124: 263-275, 2016.
29. Zhang H, Pelzer AM, Kiang DT and Yee D: Down-regulation of type I insulin-like growth factor receptor increases sensitivity of breast cancer cells to insulin. Cancer Res 67: 391-397, 2007.
30. Macdonald GA, Greenson JK, Saito K, Cherian SP, Appelman HD and Boland CR: Microsatellite instability and loss of heterozygosity at DNA mismatch repair gene loci occurs during hepatic carcinogenesis. Hepatology 28: 90-97, 1998.
31. Matsukura S, Soejima H, Nakagawachi T, Yakushiji H, Ogawa A, Fukuhara M, Miyazaki K, Nakabeppu Y, Sekiguchi M and Mukai T: CpG methylation of MGMT and hMLH1 promoter in hepatocellular carcinoma associated with hepatitis viral infection. Br J Cancer 88: 521-529, 2003.
32. Suriawinata A and Xu R: An update on the molecular genetics of hepatocellular carcinoma. Semin Liver Dis 24: 77-88, 2004.
33. Thorgeirsson SS and Grisham JW: Molecular pathogenesis of human hepatocellular carcinoma. Nat Genet 31: 339-346, 2002.
34. Zhang SH, Cong WM, Xian ZH and Wu MC: Clinicopathological significance of loss of heterozygosity and microsatellite instability in hepatocellular carcinoma in China. World J Gastroenterol 11: 3034-3039, 2005.
35. Brierly JD, Gospodarowicz MK and Wittekind C (eds.): TNM Classification of Malignant Tumours. Eighth Edition, Whiley-Blackwell, Hoboken, N, USA, pp 73-76, 2017.
36. Morikawa T, Yamamoto Y and Miyaishi S: A new method for sex determination based on detection of SRY, STS and amelogenin gene regions with simultaneous amplification of their homologous sequences by a multiplex PCR. Acta Med Okayama 65: 113-122, 2011.
37. Wang LJ, Chen YM, George D, Smets F, Sokal EM, Bremer EG and Soriano HE: Engraftment assessment in human and mouse liver tissue after sex-mismatched liver cell transplantation by real-time quantitative PCR for Y chromosome sequences. Liver Transpl 8: 822-828, 2002.
38. Sakuraoka Y, Kubota K, Imura J, Yamagishi H, Aoki T, Matsumoto T, Arakawa T, Suzuki T, Tanaka G, Shimizu T, *et al*: Microsatellite analysis of recurrent lesions confirms merit of anatomical liver resection for hepatocellular carcinoma. Anticancer Res 39: 4315-4324, 2019.
39. Zhong Y, Han J, Zou Z, Liu S, Tang B, Ren X, Li X, Zhao Y, Liu Y, Zhou D, *et al*: Quantitation of HBV covalently closed circular DNA in micro formalin fixed paraffin-embedded liver tissue using rolling circle amplification in combination with real-time PCR. Clin Chim Acta 412: 1905-1911, 2011.
40. Helal TE, Khamis NS, El-Sharkawy TM, Nada OH and Radwan NA: Immunohistochemical expression of mismatch repair genes (hMSH2 and hMLH1) in hepatocellular carcinoma in Egypt. APMIS 118: 934-940, 2010.
41. Feitelson MA, Sun B, Satiroglu Tufan NL, Liu J, Pan J and Lian Z: Genetic mechanisms of hepatocarcinogenesis. Oncogene 21: 2593-2604, 2002.
42. Frey AB and Monu N: Signaling defects in anti-tumor T cells. Immunol Rev 222: 192-205, 2008.
43. Maluccio M, Sharma V, Lagman M, Vyas S, Yang H, Li B and Suthanthiran M: Tacrolimus enhances transforming growth factor-beta1 expression and promotes tumor progression. Transplantation 76: 597-602, 2003.
44. Giovannucci E: Insulin, insulin-like growth factors and colon cancer: A review of the evidence. J Nutr 131 (11 Suppl): 3109S-3120S, 2001.

45. Pollak M: Insulin and insulin-like growth factor signalling in neoplasia. Nat Rev Cancer 8: 915-928, 2008.
46. Azhie A, Sheth P, Hammad A, Woo M and Bhat M: Metabolic complications in liver transplantation recipients: How we can optimize long-term survival. Liver Transpl 27: 1468-1478, 2021.
47. Seow A, Yuan JM, Koh WP, Lee HP and Yu MC: Diabetes mellitus and risk of colorectal cancer in the Singapore Chinese Health Study. J Natl Cancer Inst 98: 135-138, 2006.
48. Roudko V, Cimen Bozkus C, Greenbaum B, Lucas A, Samstein R and Bhardwaj N: Lynch Syndrome and MSI-H Cancers: From mechanisms to 'Off-The-Shelf' cancer vaccines. Front Immunol 12: 757804, 2021.
49. Wang L, Bani-Hani A, Montoya DP, Roche PC, Thibodeau SN, Burgart LJ and Roberts LR: hMLH1 and hMSH2 expression in human hepatocellular carcinoma. Int J Oncol 19: 567-570, 2001.
50. Wani Y, Notohara K, Tsukayama C and Okada S: Reduced expression of hMLH1 and hMSH2 gene products in high-grade hepatocellular carcinoma. Acta Med Okayama 55: 65-71, 2001.
51. Marcus VA, Madlensky L, Gryfe R, Kim H, So K, Millar A, Temple LK, Hsieh E, Hiruki T, Narod S, *et al*: Immunohistochemistry for hMLH1 and hMSH2: A practical test for DNA mismatch repair-deficient tumors. Am J Surg Pathol 23: 1248-1255, 1999.