SPANDIDOS PUBLICATIONS

ONCOLOGY LETTERS 27: 254, 2024

Primary anastomosing hemangioma as a preoperative diagnostic mimicker of retroperitoneal cavernous hemangioma: A case report

HIROTAKA ISHIDO[1], HIDEHIRO TAJIMA[1], SOYA MEGURO[1], MUSASHI TAKADA[1], TEPPEI TATSUOKA[1], KEISHI KAWASAKI[1], YUKO ONO[2,3], SHINICHI BAN[4], TAKASHI OKUYAMA[1] and HIDEYUKI YOSHITOMI[1]

[1]Department of Surgery, Dokkyo Medical University Saitama Medical Center, Koshigaya, Saitama 343-8555; [2]Department of Nephrology and Hypertension, Saitama Medical Center, Saitama Medical University, Kawagoe, Saitama 350-8550; [3]Department of Diagnostic Pathology, Dokkyo Medical University, Mibu, Tochigi 321-0293; [4]Department of Pathology, Dokkyo Medical University Saitama Medical Center, Koshigaya, Saitama 343-8555, Japan

Received November 15, 2023; Accepted January 30, 2024

DOI: 10.3892/ol.2024.14386

Abstract. Anastomosing hemangioma (AH) is rare and a newly recognized variant of capillary hemangioma that is mostly found in the genitourinary tract. Additionally, AH is sometimes difficult to diagnose without pathological specimens. It is difficult to diagnose preoperatively due to the lack of specific clinical and radiologic appearance. The present report describes the imaging features from a radiological perspective and outlines the clinicopathologic features and treatment options. A 67-year-old woman was referred to Dokkyo Medical University Saitama Medical Center (Koshigaya, Japan) for a retroperitoneal tumor that was identified at a medical checkup 4 years prior. The patient had no symptoms, no abnormal physical signs and no past medical or specific family history. Routine blood tests were all within the normal ranges. A nonenhanced CT scan showed a circular, homogenous, well-circumscribed retroperitoneal tumor that was ~32x23 mm in size, between the abdominal aorta and the inferior vena cava, and just below the left renal vein. On a contrast-enhanced multidetector CT scan, the tumor showed heterogeneous septal enhancement in the arterial phase and persistent enhancement in the portal phase. The tumor was diagnosed as a benign neurogenic tumor or a retroperitoneal cavernous hemangioma at the time, and the patient was intended to be followed up at the outpatient clinic. However, it gradually increased to a maximum diameter of 35 mm over 4 years. Finally, it was completely resected by open laparotomy and pathologically diagnosed as AH. Retroperitoneal hemangioma is extremely rare in adulthood and has been confirmed in only 1-3% of all retroperitoneal tumors. To the best of our knowledge, only 6 cases of para-aortic AH have been reported. The incidence of this variant is very low. However, AH may be included in the differential diagnosis when a slowly progressing heterogeneous mass appears in the para-aortic region that exhibits a CT-enhanced pattern similar to a typical cavernous hemangioma.

Correspondence to: Dr Hidehiro Tajima, Department of Surgery, Dokkyo Medical University Saitama Medical Center, 2-1-50 Minamikoshigaya, Koshigaya, Saitama 343-8555, Japan
E-mail: h-tajima705@dokkyomed.ac.jp

Abbreviations: AH, anastomosing hemangioma; RA, robot-assisted

Key words: AH, retroperitoneal vascular tumors, CT, MRI, case report, pathology

Introduction

Retroperitoneal vascular lesions, such as hemangiomas, are very rare and are confirmed in only 1-3% of all retroperitoneal tumors, which comprise approximately 0.2-0.5% of all malignancies (1). It is sometimes difficult to diagnose them without pathological specimens (2). Of these, anastomosing hemangioma (AH) is extremely rare and a newly recognized variant of capillary hemangioma that is most found in the genitourinary tract (3-5). It is difficult to diagnose preoperatively due to the lack of specific clinical and radiologic appearance. Herein, we report the case of a 67-year-old woman who presented without any symptoms and was incidentally found to have a retroperitoneal hemangioma by imaging examination. Although we could confirm a retroperitoneal cavernous hemangioma preoperatively, the tumor was pathologically diagnosed as AH after surgical resection. We describe the imaging features from a radiological perspective and outline the clinicopathologic features and treatment options.

Case report

Case presentation. A 67-year-old woman was referred to our hospital for a retroperitoneal tumor that was identified by abdominal ultrasound at a medical checkup four years prior. She had no symptoms, no abnormal physical signs and no past medical or specific family history. Routine blood tests, biochemical function, coagulation panel, and tumor markers were all within the normal ranges. A nonenhanced axial CT scan showed a circular, homogenous, well-circumscribed retroperitoneal tumor that was approximately 32x23 mm in size, between the abdominal aorta and the inferior vena cava, and just

below the left renal vein. On contrast-enhanced multidetector CT scan, the tumor showed heterogeneous septal enhancement in the arterial phase and continuous enhancement in the portal phase (Fig. 1). To clarify the differential diagnosis, we also performed contrast-enhanced MRI. On the pre-contrast T1-weighted image (WI), the tumor showed a circular homogenous low-density area. On T2-weighted imaging, the tumor showed linear and curvilinear low-signal-intensity areas within the circular high-density area, and diffusion WI showed iso-intensity (Fig. 2). On postcontrast T1-weighted imaging, the tumor was heterogeneously contrasted and showed persistent enhancement peripherally and without centrally (Fig. 3). From those findings, we diagnosed it as a benign neurogenic tumor or a retroperitoneal cavernous hemangioma at the time, we planned to follow her at the outpatient clinic. Annual follow-up CT scan and MRI were performed, and the tumor was not compressed and had not invaded the duodenum, inferior vena cava, bilateral renal veins, or urinary tracts and did not involve retroperitoneal lymphadenopathy. However, it gradually increased to a maximum diameter of 35 mm over 4 years (Figs. 4 and 5). The patient was evaluated again, the image pattern was the same as before, and there were no findings suggesting malignancy. However, the definite nature of the lesion could not be established preoperatively, and we finally decided to perform laparotomy to prevent its spontaneous rupture and rule out malignancy.

Surgical treatment. At first, laparoscopic or robot-assisted surgical resection was considered because of the benefit of being less invasive to the patient. However, we finally performed open laparotomy because we evaluated the surgical difficulty and tried to avoid postoperative complications. A vertical midline incision and Kocher's maneuver were performed for the surgery. The tumor was located between the abdominal aorta and the inferior vena cava, just below the left renal vein, according to the preoperative radiological findings. It was elastic, hard and easy to mobilize around tissues. No metastatic lesions were found in the peritoneum, abdominal organs, or pelvic organs. The feeding arteries of the tumor were found to originate from retroperitoneal tissue, and each vessel was ligated before the tumor was removed. After these procedures, the size and elasticity of the tumor were obviously decreased. Based on these operative findings, we confirmed that the tumor could be a hemangioma. There was no evidence intraoperatively of invasion into the inferior vena cava, ureter, renal capsule, pancreas, duodenum, or other surrounding organs.

Radical resection of the tumor was completed in 3.5 h with an estimated blood loss of 75 ml. After the surgery, she had asymptomatic pancreatic hyperenzymemia that was characterized by temporary elevation of serum amylase above the upper normal limits in the absence of pancreatic symptoms. However, she was discharged on postoperative Day 10 without other surgical complications and was in good health without recurrence more than 15 months after the operation.

Pathological findings. In the macroscopic examination, the tumor was a brownish-colored solid mass and was 35x30x23 mm in diameter (Fig. 6). Microscopically, the tumor was edematous and covered by a fibrous capsule and was composed of an anastomosing proliferation of various-sized capillary vessels that were lined with hobnail endothelial cells (Fig. 7). On immunohistochemical examination, the cells that covered the capsule were positive for CD31 and CD34 and negative for D2-40 (Fig. 8). The walls of the capsule and stroma were positive for anti-alpha Smooth Muscle Actin, partially positive for desmin. S100, and human melanoma black-45 and Epithelial Membrane Antigen were negative (Fig. 9). Atypia and mitosis were not noted. The histopathologic appearance and immunophenotypic features of the tumor were indicative of a vascular tumor, and these characteristics were consistent with a diagnosis of AH.

Discussion

Hemangiomas are conventionally classified into two histological subtypes: cavernous and capillary. Most hemangiomas of the liver, kidney, ad ovary reported to date have been classified as benign hemangiomas of the cavernous type (6). Primary retroperitoneal tumors are relatively rare, accounting for only 0.1 to 0.2% of all malignant tumors in the body. However, 70 to 80% of these tumors are malignant in nature (1,2). Among these, retroperitoneal hemangiomas are extremely rare in adults, being identified in only 1 to 3% of all retroperitoneal tumors (7). The most common type of previously reported retroperitoneal hemangioma is the cavernous type (8), and it was described as a round shaped solid mass with minor or poor enhancement on enhanced CT scan (7).

On the other hand, AH was first described by Montgomery and Epstein in 2009 (3), and the tumor is a new variant of capillary renal hemangioma, a rare benign hemangioma that overlaps features of both sinusoidal and hobnail hemangiomas of the skin and soft tissues. According to the WHO Classification of tumors 5th edition for soft tissue and bone tumors, AH is classified as a soft tissue vascular tumor (4-6). Most cases of AH occur in the retroperitoneum, especially the genitourinary tract. AH has also been reported in the ovary, adrenal gland, liver, and gastrointestinal tract (3,4). However, some AH arises in unusual regions, such as the breast, skin, paravertebral region, and para-aorta. To the best of our knowledge, only 6 cases of para-aortic AHs have been reported (3,4)

AH is more common in middle-aged and slightly more common in males. (9). Generally, its diameter ranges from 0.1 to 6.0 cm (10). Zhang *et al* (11) reported a case of AH that progressed slowly over a four-year observation period. In the present case, the tumor also exhibited slow growth over a four-year period. AH has no special clinical symptoms or laboratory findings, and it is often found incidentally on imaging examination. However, the imaging findings of AH are not specific and are similar to most benign lesions. On noncontrast-enhanced CT, the AH showed lobular lesions with soft-tissue attenuation, and on contrast-enhanced CT showed heterogeneous solid lesions with persistent enhancement (10,12). On noncontrast-enhanced MRI, the AH presented as a round, well demarcated T1-hypointense and T2-hyperintense lesion, while on contrast-enhanced MRI, it presented with strong peripheral enhancement in the arterial phase, which persisted in the delayed phase without central enhancement (13). On the other hand, a previous report (14) also showed the different characteristics of their AH on MRI. In this report, the lesions showed uniform enhancement

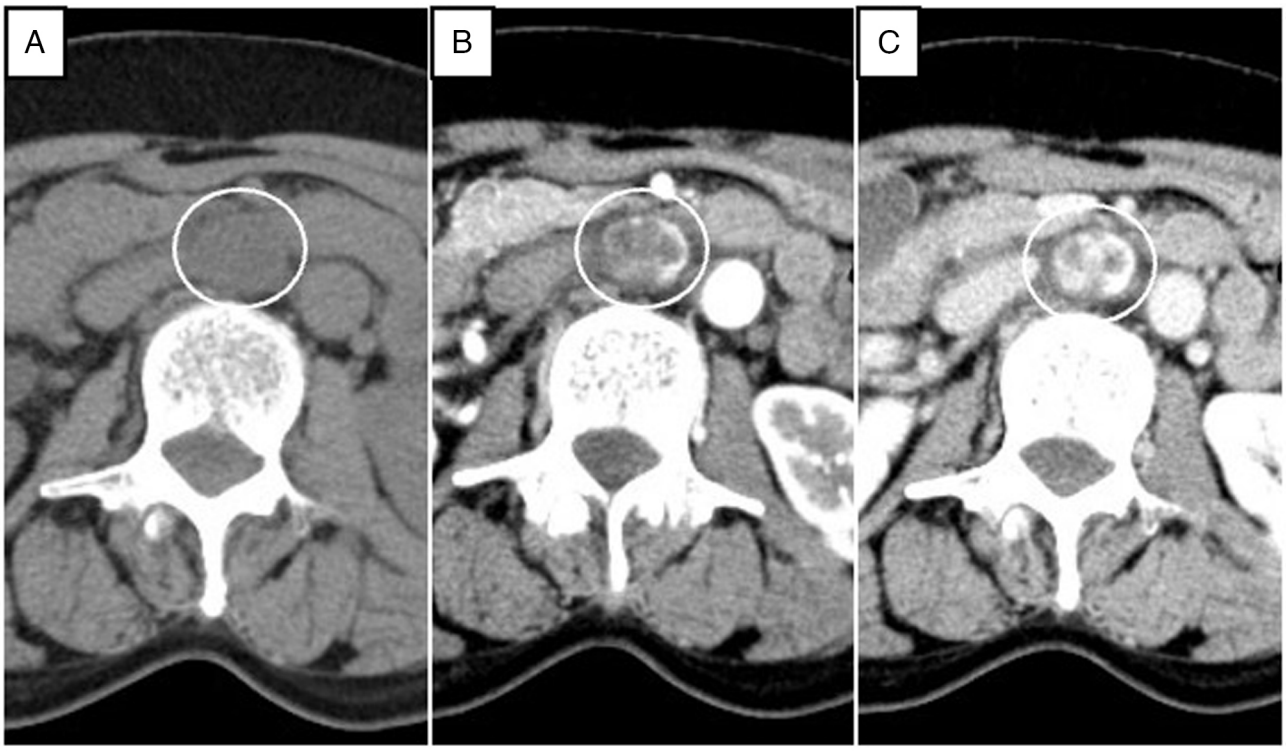

Figure 1. First abdominal CT scan. The white circle indicates the retroperitoneal tumor. (A) Non-contrast-enhanced CT scan. (B) Contrast-enhanced CT scan in the arterial phase. (C) Contrast-enhanced CT scan in the portal phase. The tumor showed lobulated and persistent enhancement. The size of the tumor was ~32 mm.

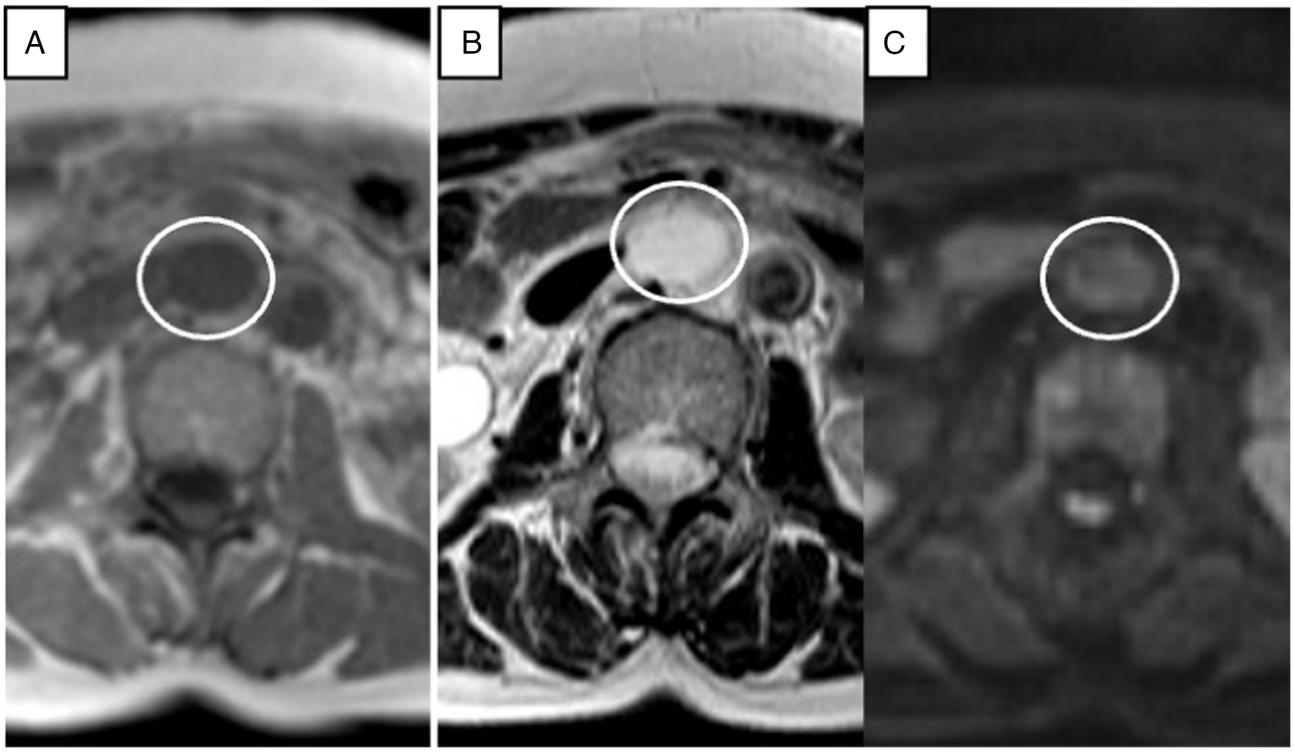

Figure 2. First pre-contrast-enhanced abdominal MRI scan. The white circle indicates the retroperitoneal tumor. (A) A circular homogenous low-density area on T1-weighted imaging. (B) Linear and curvilinear low-signal-intensity areas within the circular high-density area on T2-weighted imaging. (C) An iso-density area on diffusion-weighted imaging.

both peripherally and centrally in the arterial phase, which persisted in the delayed phase. Either way, the enhancement pattern of MRI was similar to that of CT, with clear heterogeneous enhancement in the arterial phase and persistent

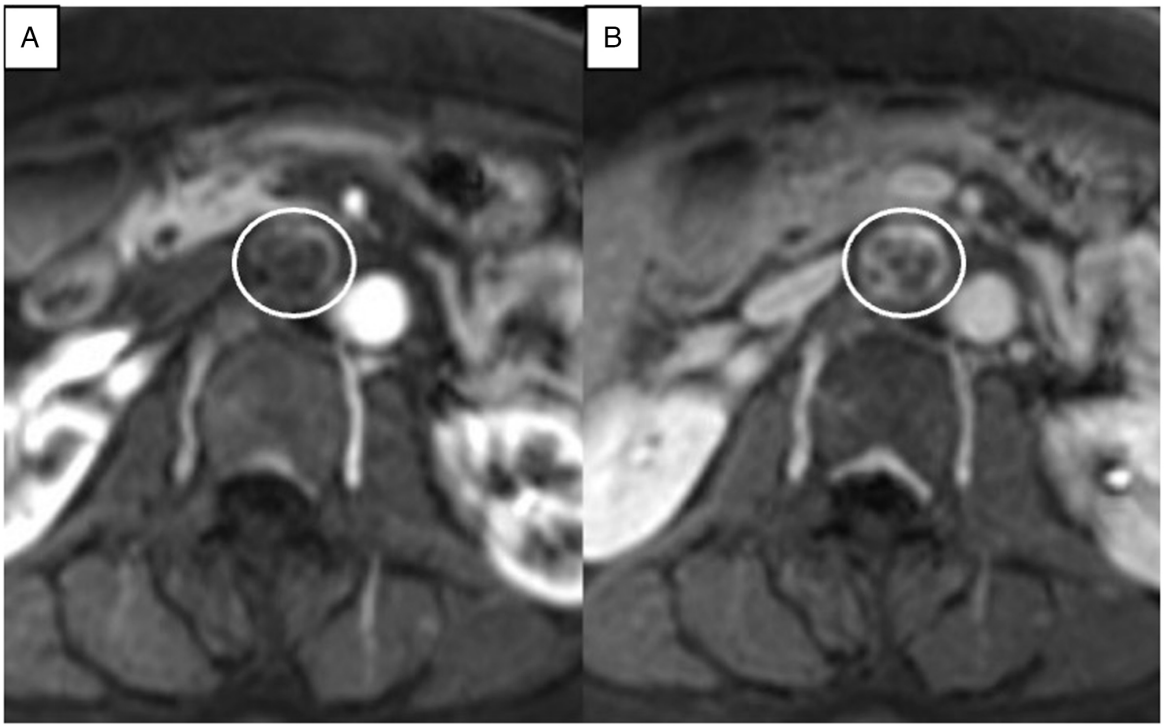

Figure 3. Postcontrast-enhanced abdominal MRI scan. The white circle indicates the retroperitoneal tumor. (A) Early phase of T1WI. (B) Delay phase of T1WI. The tumor presented with avid peripheral enhancement in the arterial phase, which persisted in the delayed phase without central enhancement. T1WI, T1-weighted imaging.

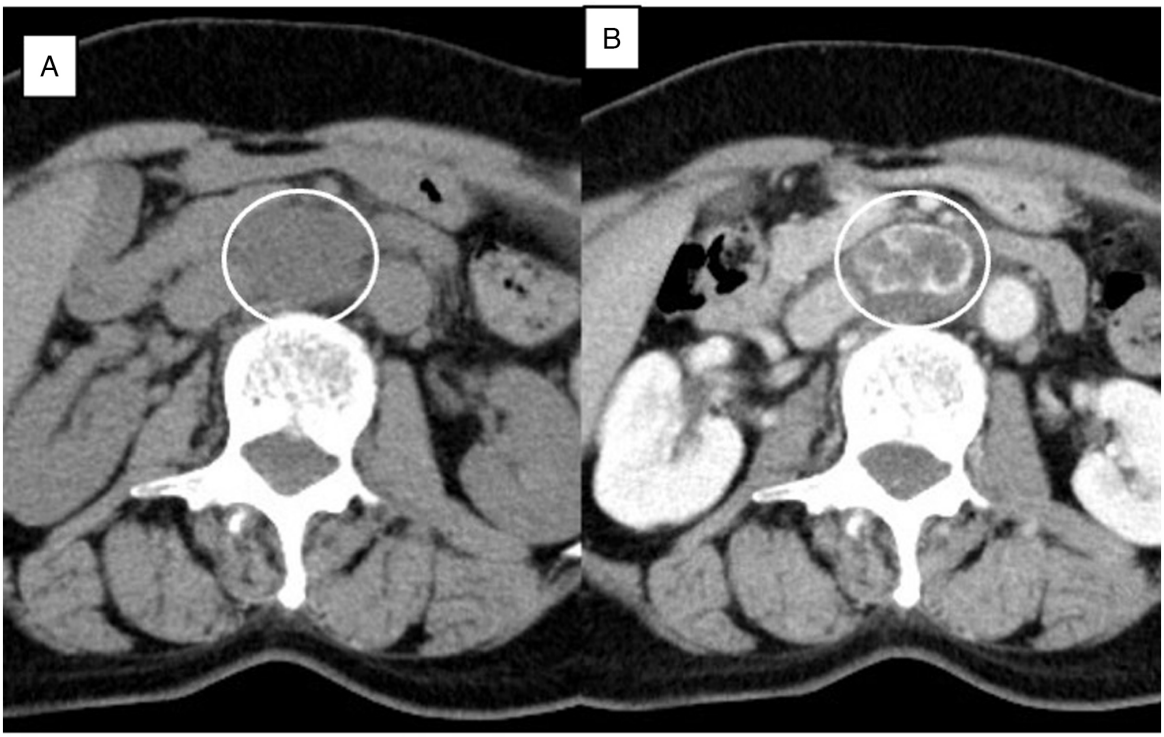

Figure 4. Abdominal CT scan after 4 years. The white circle indicates the retroperitoneal tumor. (A) Non-contrast-enhanced CT scan. (B) Contrast-enhanced CT scan in the portal phase. The tumor gradually increased to a maximum diameter of 35 mm.

hyperenhancement in the portal and delayed phases (12,14,15). In our case, the lesion showed heterogeneous septal enhancement in the arterial phase and persisted peripherally and centrally in the portal phase.

Most AHs are incidentally found and likely diagnosed after surgical resection because of the difficulty of differential diagnosis. To avoid surgery, biopsy was proposed (5). In our case, performing biopsy was difficult because the tumor

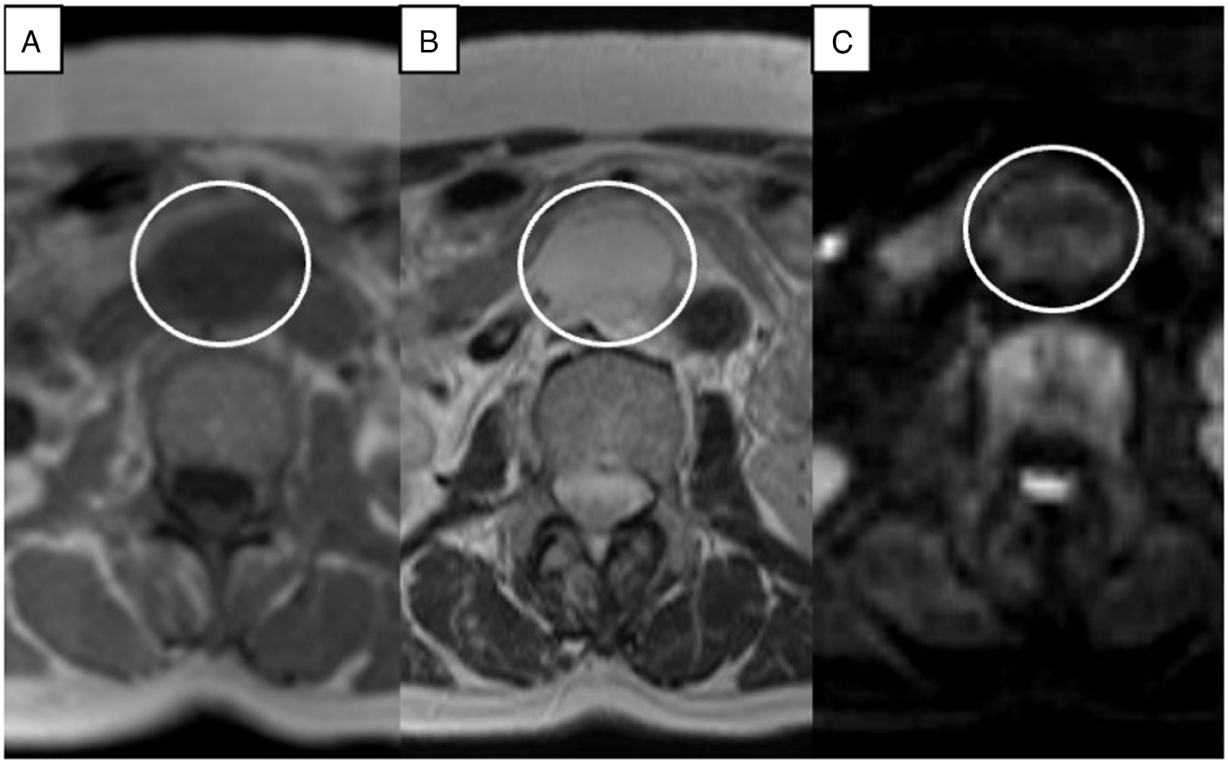

Figure 5. Abdominal MRI scan after 4 years. The white circle indicates the retroperitoneal tumor. Well-defined (A) T1-hypointense and (B) T2-hyperintense area. (C) Iso-density area on diffusion-weighted imaging.

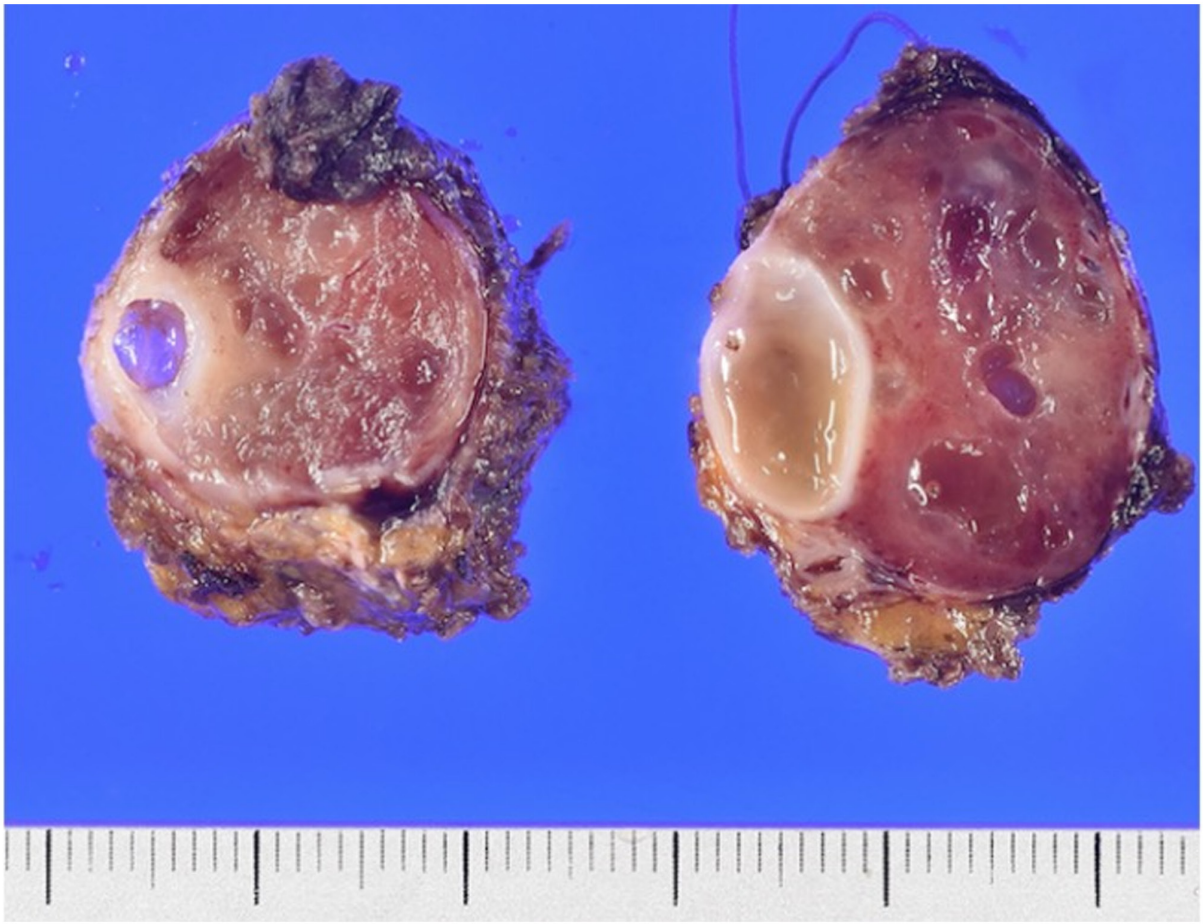

Figure 6. Macroscopic appearance. The cut surface of the lesion indicated well marginated, mahogany-colored, spongy appearance. The distance between lines on the ruler is 1 mm.

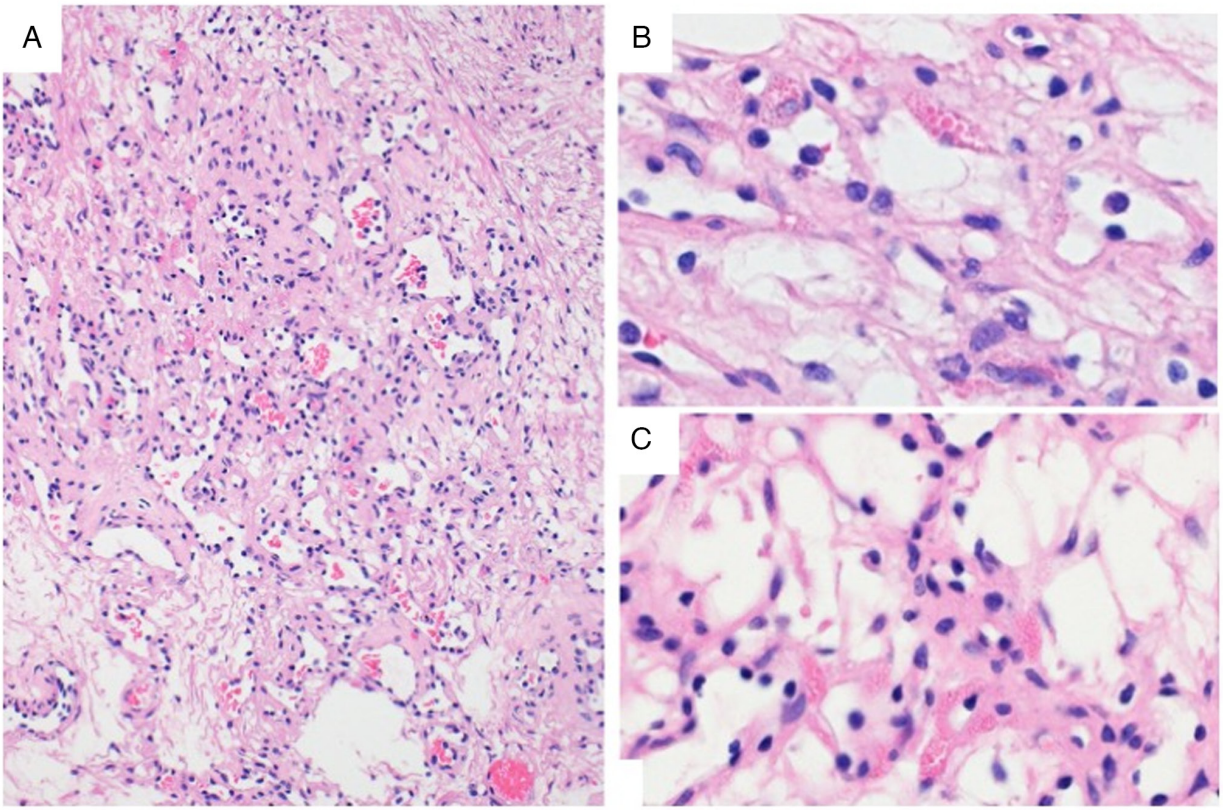

Figure 7. Microscopic observation of the tumor (hematoxylin and eosin stain). (A) Anastomosing, sinusoidal-like appearance with capillary-sized vessels (magnification, x200). (B) Neoplastic capillaries were lined by hobnail endothelial cells containing eosinophilic hyaline globules in the cytoplasm (magnification, x400). (C) Another area of neoplastic capillaries lined by hobnail endothelial cells containing eosinophilic hyaline globules in the cytoplasm (magnification, x400).

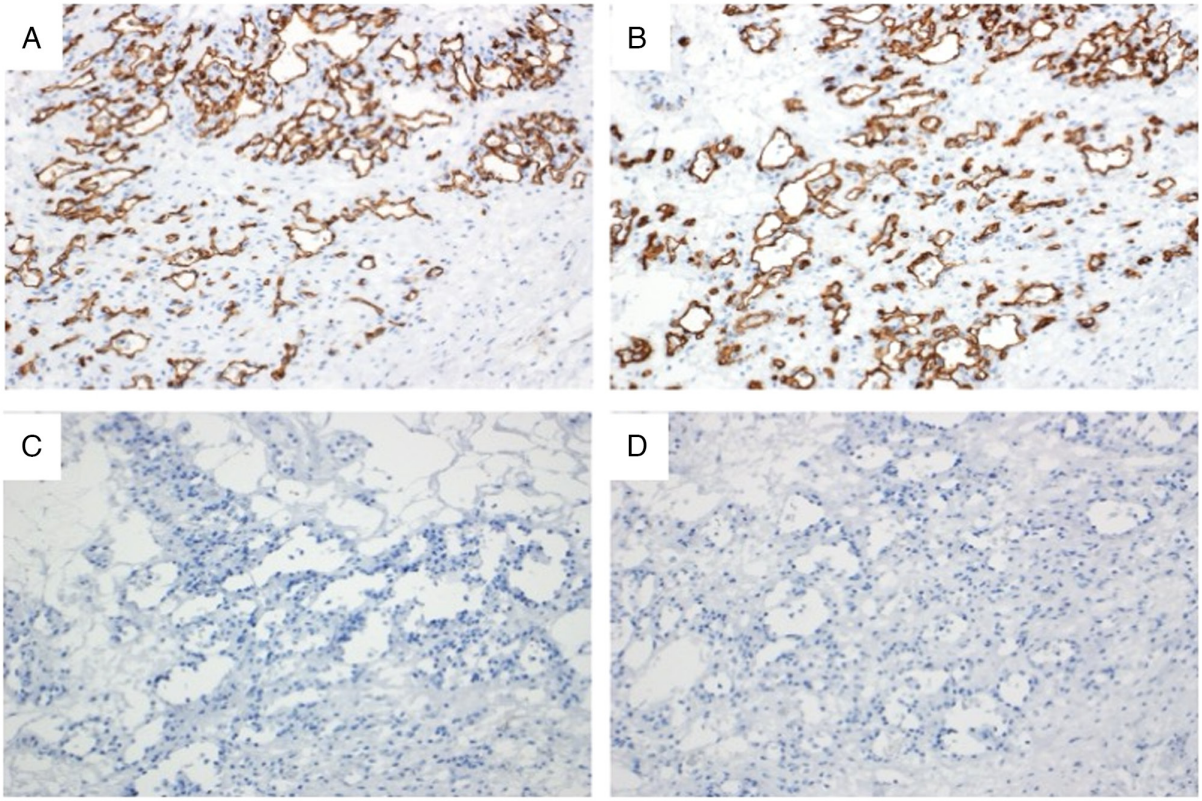

Figure 8. Immunohistochemical examination (magnification, x200). (A) Vasculature was highlighted with CD31 stain. (B) Vasculature was highlighted with CD34 stain. (C) Human melanoma black-45 was not detected in endothelial and interstitial cells. (D) D2-40 was not detected in endothelial and interstitial cells.

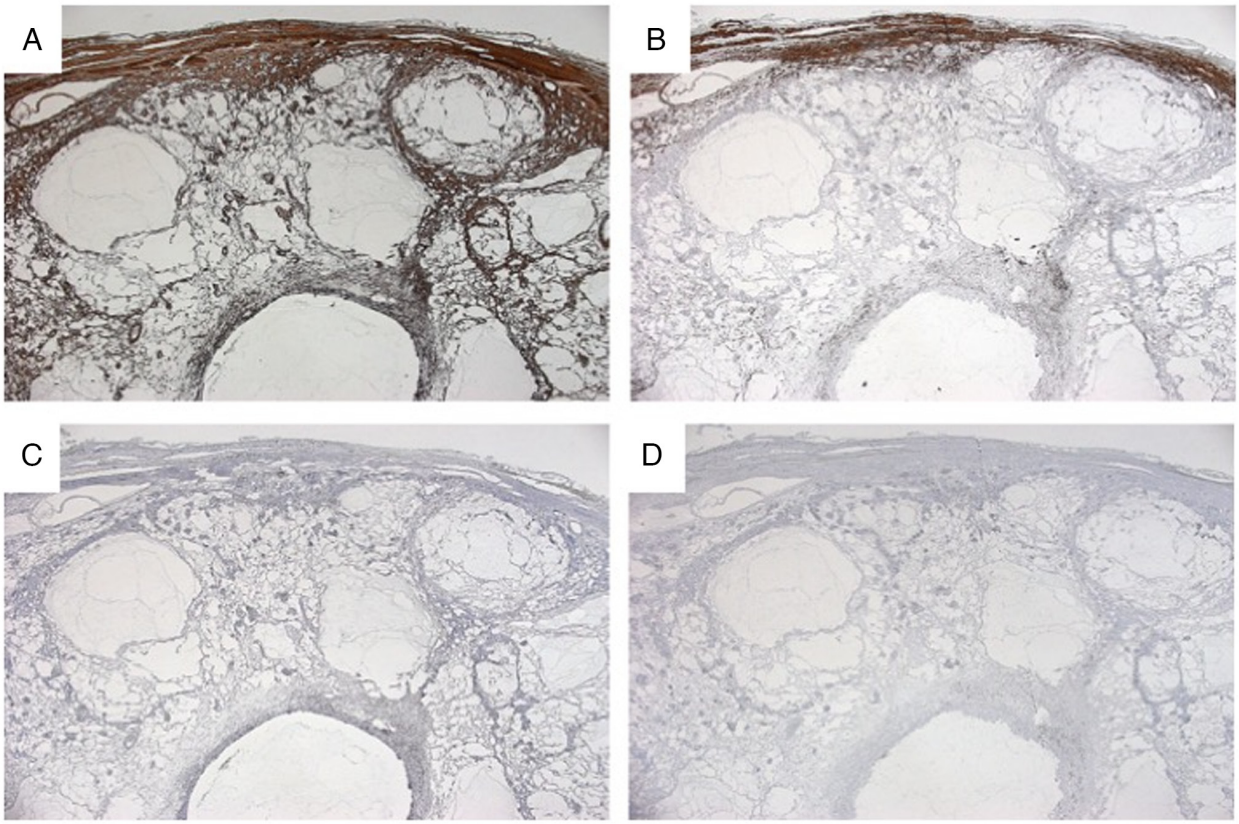

Figure 9. Immunohistochemical examination (magnification, x20). The walls of the capsule and stroma were positive for (A) α smooth muscle actin, and partially positive for (B) desmin. (C) S100 and (D) epithelial membrane antigen staining were negative.

was located on the para-aorta and in front of the vertebra. Therefore, we had no choice but to diagnose using images and to operate if we wanted to confirm the pathological features. The diagnosis of AH is basically based on histopathological examination. Macroscopically, AH usually shows a spongy neoplasm without capsule but with a clear boundary and a mahogany-brown color (10,11,16). Microscopically, AH is characterized by dense capillary vessels lined with hobnailed endothelial cells, which resembles the red pulp of the spleen in appearance, have extramedullary hematopoiesis, and lack endothelial atypia (10,17). Immunohistochemical staining was strongly and diffusely positive for CD31, CD34, and EGR (5,17). It is important to note that mitotic activity was absent, cellular atypia was no or only slight, and the Ki-67 index was low (5,9,10).

It is important to differentiate AH from angiosarcoma (18). Angiosarcoma is a rare, invasive, malignant tumor, and it cannot be differentiated from AH using radiological examinations. Histologically, it also presents with hobnailed endothelial cells and can mimic AH (9). However, angiosarcoma is characterized by high-grade cell atypia, multiple layers of endothelial cells, and obvious mitotic activity, none of which were present in our case. Therefore, the present case was diagnosed as AH from those characteristic histopathological findings. It is difficult to make a definitive diagnosis as AH from preoperative radiologic examinations, so it is controversial how to treat AH.

When biopsy results are obtained, different treatment modalities such as follow-up, embolization, or radiofrequency ablation may be used depending on the location of the lesion, size of the lesion, and presence of symptoms, and local or radical resection may be performed to avoid overtreatment. Previous studies have shown no tendency for disease recurrence (7,9). However, we must be concerned about the risk of bleeding and safety. Patients should not be disadvantaged by biopsies.

There are limited imaging data available for AH, and when available, it is typically described as having nonspecific features. In addition, imaging may vary according to the location and size of the tumor (6). However, we should rule it out in the differential diagnosis of retroperitoneal vascular tumors.

Robot-assisted (RA) surgery is becoming a popular and effective approach in the treatment of retroperitoneal tumors (19). In a previous report, conventional surgery had the shortest operation time but the greatest amount of blood loss. The median duration of postoperative drainage, morbidity rate, and postoperative length of stay were lower after RA approaches. The RA significantly reduces risks in cases when the tumor is in hard-to-reach small spaces and/or attached to the main vessels and when the size of the tumor is less than 10 cm. In the future, we will try RA approaches for resecting retroperitoneal tumors.

We describe a rare hemangioma variant in the para-aortic region that showed an anastomosing pattern of vascular channels on pathological examination. However, AH may be included in the differential diagnosis when a slowly progressing heterogeneous mass appears in the para-aortic region that exhibits a CT-enhanced pattern similar to a typical cavernous hemangioma.

Acknowledgements

The authors would like to thank Dr Taizen Urahashi (Saitama Medical Center, Kawagoe, Saitama, Japan) for their advice on this article.

Funding

No funding was received.

Availability of data and materials

The data generated in the present study may be requested from the corresponding author.

Authors' contributions

HI, HT, SM, MT, TT, KK, TO and HY participated in the conception, design and data acquisition of the study. TO and HY performed data analysis and interpretation. HI wrote the manuscript, and completed the follow-up. YO and SB performed the pathological assessment of the anastomosing hemangioma and wrote the manuscript. HT revised the manuscript. HT, TO and HY confirm the authenticity of all the raw data. All authors have read and approved the final manuscript.

Ethics approval and consent to participate

Written informed consent was obtained from this patient in accordance with the ethical principles of the 1964 Declaration of Helsinki and its subsequent amendments.

Patient consent for publication

Written informed consent was obtained from the patient for the publication of this report and its accompanying images.

Competing interests

The authors declare that they have no competing interests.

References

1. Xu YH, Guo KJ, Guo RX, Ge CL, Tian YL and He SG: Surgical management of 143 patients with adult primary retroperitoneal tumor. World J Gastroenterol 13: 2619-2621, 2007.
2. Nishino M, Hayakawa K, Minami M, Yamamoto A, Ueda H and Takasu K: Primary retroperitoneal neoplasms: CT and MR imaging findings with anatomic and pathologic diagnostic clues. Radiographics 23: 45-57, 2003.
3. Montgomery E and Epstein JI: Anastomosing hemangioma of the genitourinary tract: A lesion mimicking angiosarcoma. Am J Surg Pathol 33: 1364-1369, 2009.
4. John I and Folpe AL: Anastomosing hemangiomas arising in unusual locations: A clinicopathologic study of 17 soft tissue cases showing a predilection for the paraspinal region. Am J Surg Pathol 40: 1084-1089, 2016.
5. O'Neill AC, Craig JW, Silverman SG and Alencar RO: Anastomosing hemangiomas: Locations of occurrence, imaging features, and diagnosis with percutaneous biopsy. Abdom Radiol (NY) 41: 1325-1332, 2016.
6. Kryvenko ON, Gupta NS, Meier FA, Lee MW and Epstein JI: Anastomosing hemangioma of the genitourinary system: Eight cases in the kidney and ovary with immunohistochemical and ultrastructural analysis. Am J Clin Pathol 136: 450-457, 2011.
7. Hanaoka M, Hashimoto M, Sasaki K, Matsuda M, Fujii T, Ohashi K and Watanabe G: Retroperitoneal cavernous hemangioma resected by a pylorus preserving pancreaticoduodenectomy. World J Gastroenterol 19: 4624-4629, 2013.
8. Godar M, Yuan Q, Shakya R, Xia Y and Zhang P: Mixed capillary venous retroperitoneal hemangioma. Case Rep Radiol 2013: 258352, 2013.
9. Omiyale AO: Anastomosing hemangioma of the kidney: A literature review of a rare morphological variant of hemangioma. Ann Transl Med 3: 151, 2015.
10. Tao LL, Dai Y, Yin W and Chen J: A case report of a renal anastomosing hemangioma and a literature review: An unusual variant histologically mimicking angiosarcoma. Diagn Pathol 9: 159, 2014.
11. Zhang W, Wang Q, Liu YL, Yu WJ, Liu Y, Zhao H, Zhuang J, Jiang YX and Li YJ: Anastomosing hemangioma arising from the kidney: A case of slow progression in four years and review of literature. Int J Clin Exp Pathol 8: 2208-2213, 2015.
12. Silva MA, Fonseca EKUN, Yamauchi FI and Baroni RH: Anastomosing hemangioma simulating renal cell carcinoma. Int Braz J Urol 43: 987-989, 2017.
13. Peng X, Li J and Liang Z: Anastomosing haemangioma of liver: A case report. Mol Clin Oncol 7: 507-509, 2017.
14. Merritt B, Behr S, Umetsu SE, Roberts J and Kolli KP: Anastomosing hemangioma of liver. J Radiol Case Rep 13: 32-39, 2019.
15. Xue X, Song M, Xiao W, Chen F and Huang Q: Imaging findings of retroperitoneal anastomosing hemangioma: A case report and literature review. BMC Urol 22: 77-81, 2022.
16. Al-Maghrabi HA and Al Rashed AS: Challenging pitfalls and mimickers in diagnosing anastomosing capillary hemangioma of the kidney: Case report and literature review. Am J Case Rep 18: 255-262, 2017.
17. Cheon PM, Rebello R, Naqvi A, Popovic S, Bonert M and Kapoor A: Anastomosing hemangioma of the kidney: Radiologic and pathologic distinctions of a kidney cancer mimic. Curr Oncol 25: e220-e223, 2018.
18. Heidegger I, Pichler R, Schäfer G, Zelger B, Zelger B, Aigner F, Bektic J and Horninger W: Long-term follow up of renal anastomosing hemangioma mimicking renal angiosarcoma. Int J Urol 21: 836-838, 2014.
19. Berelavichus S, Kriger A, Kaldarov A, Panteleev V and Raevskaya M: Robotic surgery in treatment of retroperitoneal tumors. Comparative single center study. J Robot Surg 15: 363-367, 2021.