SPANDIDOS PUBLICATIONS

ONCOLOGY LETTERS 28: 314, 2024

Effective neoadjuvant immunotherapy and chemotherapy in stage IIIA adenosquamous carcinoma of the lung with a complete response and surgical success: A case report

CHEN SONG[1*], YUHUI NIE[1*], TIANZI LIU[1], XINTONG PENG[1], JING LIU[2], ZIWEN ZHOU[1] and YAN HUANG[2]

[1]Department of Clinical Medicine, Shandong Second Medical University, Weifang, Shandong 261053, P.R. China; [2]Department of Oncology, Affiliated Hospital of Shandong Second Medical University, Weifang, Shandong 261041, P.R. China

Received November 7, 2023; Accepted April 15, 2024

DOI: 10.3892/ol.2024.14448

Abstract. There has been rapid advancement in the development of neoadjuvant therapy for non-small cell lung cancer (NSCLC), which holds great promise as an effective treatment strategy. Some clinical trials have confirmed that immunotherapy in combination with chemotherapy can be a recommended first-line regimen for neoadjuvant treatment of NSCLC. The present study describes the case of a male patient aged 65 years who was diagnosed with stage IIIA (cT2N2M0) adenosquamous carcinoma of the lung. After the administration of two cycles of neoadjuvant immunotherapy (sintilimab) in combination with chemotherapy, stable disease was observed in the primary tumor, whereas partial remission was detected in the mediastinal lymph nodes based on imaging assessment. The patient underwent an immediate upper lobectomy of the left lung. Pathological analysis revealed a complete response in the primary lesion, with only minimal presence of tumor cells observed in the lymph nodes surrounding the mediastinum and bronchi. This indicated that the present neoadjuvant therapy could be used in the treatment of stage III adenosquamous lung carcinoma; however, to conclusively determine its efficacy, further studies targeting this specific cancer type are essential.

Introduction

At present, a variety of factors, including a significant rise in the incidence of cancer, an aging population worldwide and improvements in detection methods, are together leading to cancer being the second most common cause of death globally (1). However, the incidence of lung adenosquamous carcinoma (ASC) is relatively low globally, representing only 0.4-4% of all diagnosed cases of lung cancer (2). The rarity of this disease limits research into its diagnosis and prognosis, contributing to the significant challenges of a poor prognosis and limited treatment options faced by patients with lung ASC (3). The pathological characteristics of ASC include squamous cell carcinoma components and adenocarcinoma components (4), and ASC exhibits pathological heterogeneity, so is therefore widely regarded as a subtype of non-small cell lung cancer (NSCLC). Compared with classical lung adenocarcinoma and squamous cell carcinoma, it is known for its higher treatment difficulty (5,6). Immunotherapy for lung cancer has received increasing attention and several clinical studies have emerged. Specifically, the CheckMate 816 trial demonstrated that neoadjuvant immunotherapy, in combination with platinum-doublet chemotherapy, provided marked survival benefits for patients with resectable NSCLC, endorsing the use of nivolumab alongside platinum-doublet chemotherapy as the preferred neoadjuvant treatment approach for resectable NSCLC (7). This regimen not only aims to enhance surgical outcomes but also to minimize the risk of recurrence.

For the current case, when considering the patient's economic circumstances and the existing clinical trial support for sintilimab, a comprehensive evaluation led to the selection of a novel neoadjuvant treatment regimen, namely, sintilimab injection combined with pemetrexed and carboplatin. Sintilimab, a highly selective, recombinant humanized monoclonal antibody, inhibits the interaction between programmed cell death protein 1 (PD-1) and its ligands, proving effective in the treatment of squamous cell lung cancer by enhancing the antitumor response (8). Based on clinical research findings on neoadjuvant therapy for NSCLC (9), the goal of the present study was to explore a novel neoadjuvant treatment strategy for stage III lung adenocarcinoma by synergistically combining chemotherapy with sintilimab.

Case report

In July 2023, a 65-year-old male patient presented to Shandong Second Medical University (Weifang, China) for a detailed

Correspondence to: Professor Yan Huang, Department of Oncology, Affiliated Hospital of Shandong Second Medical University, 2428 Yuhe Road, Weifang, Shandong 261041, P.R. China
E-mail: 15866582815@163.com

[*]Contributed equally

Key words: adenosquamous carcinoma of the lung, neoadjuvant immunotherapy, programmed cell death protein 1, sintilimab, pathological complete response, case report

evaluation of the upper lobe of the left lung, following an incidental discovery during a health screening at Shouguang City People's Hospital (Shougang, China). A lesion with soft-tissue density, measuring ~4.9x4 cm at its widest point, was detected in the upper lobe of the left lung through a chest CT scan conducted in July 2023. Tiny nodules were also observed in both lungs, along with enlarged lymph nodes in the left pulmonary hilum and mediastinum (Fig. 1A and B). The patient had no systemic symptoms such as a cough, hemoptysis or chest pain. However, the patient had a 2-year history of hypertension and a 30-year history of smoking. To clarify the pathological features, a biopsy was immediately performed, which revealed the coexistence of adenocarcinoma and squamous carcinoma with a predominantly adenocarcinomatous component (Fig. 2A). Tissues were fixed in 10% neutral buffered formalin at room temperature for 24 h, sectioned to 5-μm thick and stained with hematoxylin and eosin (H&E) at room temperature (hematoxylin for 5 min and eosin for 3 min). Results were assessed using a light microscope. For immunohistochemical staining, paraffin-embedded tissues were fixed with 10% neutral buffered formalin at room temperature for 24 h and sectioned to a thickness of 5 μm. The sections were blocked with 5% normal goat serum at room temperature for 1 h, before incubating with the following primary antibodies overnight at 4°C: p40 antibody (cat. no. RMA-1006) and TTF-1 antibody (car. no. MAB-0266) (both diluted 1:200; Fuzhou Maixin Biotech Co., Ltd.). The secondary antibodies, including avidin and D-biotin, from the endogenous biotin blocking kit (both Fuzhou Maixin Biotech Co., Ltd.) were diluted at 1:500 and incubated with the sections at room temperature for 20 min. Immunohistochemical staining for p40 and TTF1 was positive (Fig. 2B and C) and the Ki-67 positivity rate was ~60% in adenocarcinoma (Fig. 2D) and ~5% in squamous carcinoma (Fig. 2E). Programmed death-ligand 1 expression had a positivity rate of 15% (Fig. 2F). Genetic testing identified mutations exclusively in KRAS G12A/V/R/C and G13C, whereas no distant metastasis was detected through other diagnostic examinations. Testing was performed internally using the PCR method: DNA was extracted from tissue samples. Taq DNA polymerase from Thermo Fisher Scientific was used for PCR amplification, with the following primer sequences: Forward, 5'-ACTTGTGGTAGTTGGAGCT-3' and reverse, 5'-CTGTATCAAAGAATGGTCCTGCACC-3'. PCR was conducted with the following conditions: Initial denaturation at 95°C for 3 min, followed by 35 cycles of denaturation at 95°C for 30 sec, annealing at 55°C for 30 sec and extension at 72°C for 1 min, with a final extension step at 72°C for 5 min. Agarose gel electrophoresis using a 1.5% gel and ethidium bromide staining under ultraviolet light were employed for visualization. Utilizing chest CT within the confines of available diagnostic modalities, and guided by the AJCC 8th edition Tumor-Node-Metastasis staging criteria (10), the patient's condition was ascertained to be cT2N2M0 (stage IIIA). This staging was predicated on the presence of N2 positive mediastinal lymph nodes (Fig. 1A and B).

During the initial comprehensive treatment evaluation, it was concluded that the tumor was located near the pulmonary artery (Fig. 1C), and that surgical resection presented significant challenges and risks. The enhanced inflammatory response and potential scar tissue formation around the tumor due to neoadjuvant therapy increased the difficulty and risks associated with the surgical procedure. Although synchrotron radiation therapy remains the primary treatment for advanced NSCLC (11), in order to perform surgery and preserve as much lung tissue as possible, an immunotherapy plus chemotherapy regimen was adopted as neoadjuvant therapy based on the CheckMate 816 trial (12). Before surgery in September 2023, the patient received two cycles of treatment, each lasting 21 days, including 200 mg sindilizumab on day 0, 1,000 mg pemetrexed on day 1 and 600 mg carboplatin on day 2. No significant adverse effects were observed in the patient throughout the course of neoadjuvant therapy. The imaging findings indicated a slight reduction of the primary tumor size (4.7x4.0 cm), indicating a stable response to treatment (Fig. 1D and E). In addition, the mediastinal lymph node size was also reduced compared with previous measurements. According to the Response Evaluation Criteria in Solid Tumors, the response of the patient to treatment was classified as stable disease (13). The patient underwent thoracoscopic surgery 2 weeks after the last neoadjuvant therapy, for effective removal of the left upper lung tumor and lymph node examination. Analysis of the pathological findings revealed a complete absence of residual cancer cells within the primary left lung tumor. Instead, it demonstrated a degenerative change characterized by a lack of active tumor cells, accompanied by extensive fibrous and lymphoid tissue proliferation, indicating a pathological complete response (Fig. 2G). However, metastatic malignant cells were detected in the lymph nodes in the mediastinal and parabronchial regions (Fig. 2H). The following tumor markers were evaluated in October 2023: Carcinoembryonic antigen, 4.29 ng/ml (normal, <5 ng/ml); neuron-specific enolase, 10.9 ng/ml (normal, <12.5 ng/ml); and cytokeratin 19 fragment antigen 21-1, 1.83 ng/ml (normal, <3.3 ng/ml). The patient did not experience any postoperative complications during hospitalization. Subsequently, between October and December, the patient received four cycles of adjuvant chemoimmunotherapy, with each cycle spanning 21 days. The regimen included administration of 200 mg sindilizumab on day 0, 1,000 mg pemetrexed on day 1 and 600 mg carboplatin on day 2. Since October 2023, the patient has been undergoing evaluations every 3 months, including chest CT scans and tumor biomarker assessments, all of which have shown no signs of recurrence. Currently, the patient remains on regular tumor surveillance to closely monitor for possible instances of recurrence. To comprehensively understand the treatment process and clinical response of the patient, a detailed timeline has been provided in Table I that outlines each critical stage from initial diagnosis to current monitoring.

Discussion

Lung cancer is a prevalent malignancy worldwide and a leading cause of cancer-related mortality (14). Compared with other types of lung cancer, lung ASC is a rare variant with an unfavorable prognosis. As adenosquamous lung cancer is a specific subtype of NSCLC, its management should be similar to that of NSCLC. At present, concurrent chemoradiotherapy is the primary approach for managing locally

Table I. Comprehensive treatment timeline of the patient.

Date	Event	Category
July 2023	Chest CT scan revealed a lesion in the upper lobe of the left lung, along with tiny nodules and enlarged lymph nodes in both the hilum and mediastinum.	Initial diagnosis
July 2023	Biopsy confirmed adenocarcinoma and squamous carcinoma. Immunohistochemical staining was positive for p40 and TTF-1. PD-L1 expression showed a positivity rate of 15%.	Diagnostic confirmation
September 2023	Initiation of two cycles of neoadjuvant therapy with sindilizumab combined with pemetrexed and carboplatin.	Treatment initiation
September 2023	Thoracoscopic surgery for the removal of the left upper lung tumor. The pathological report indicated a pCR, with no residual cancer cells found. Metastatic malignant cells were detected in the mediastinal and parabronchial lymph nodes.	Surgical intervention
October 2023	Tumor marker evaluation [CEA, 4.29 ng/ml (normal, <5 ng/ml); NSE, 10.9 ng/ml (normal, <12.5 ng/ml); and CYFRA21-1, 1.83 ng/ml (normal, <3.3 ng/ml)] indicated a response to treatment.	Treatment monitoring
October to December 2023	Administration of four cycles of adjuvant chemoimmunotherapy post-surgery.	Continued treatment
From October 2023 to the present	Every 3 months, routine follow-up assessments, including chest CT scans and evaluations of tumor biomarkers, have shown no signs of recurrence.	Long-term monitoring

CYFRA21-1, cytokeratin 19 fragment antigen 21-1; NSE, neuron-specific enolase; pCR, complete pathological response; PD-L1, programmed death-ligand 1; TTF-1, thyroid transcription factor 1.

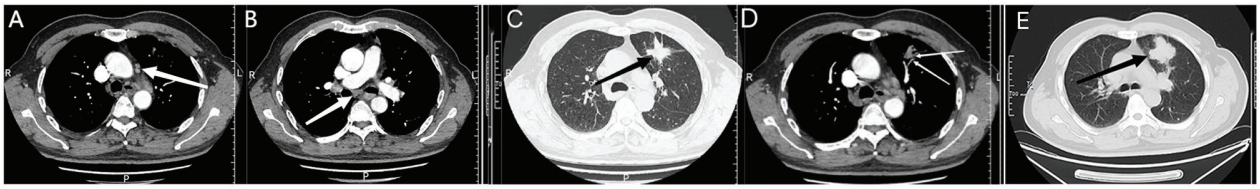

Figure 1. Assessment of observed outcomes from imaging. Chest CT scans indicated the clinical response to neoadjuvant chemotherapy and immunotherapy. (A, B and D) Chest CT images before adjuvant therapy in July 2023 showing (A) significantly enlarged lymph nodes in group 4 (arrow), (B) enlarged lymph nodes in group 7. (C) Chest CT before neoadjuvant therapy showing the tumor (top arrow) close to the pulmonary artery (bottom arrow). (D) the tumor lesion. (E) Chest CT image after two cycles of neoadjuvant therapy in August 2023 showing the tumor lesion (arrow).

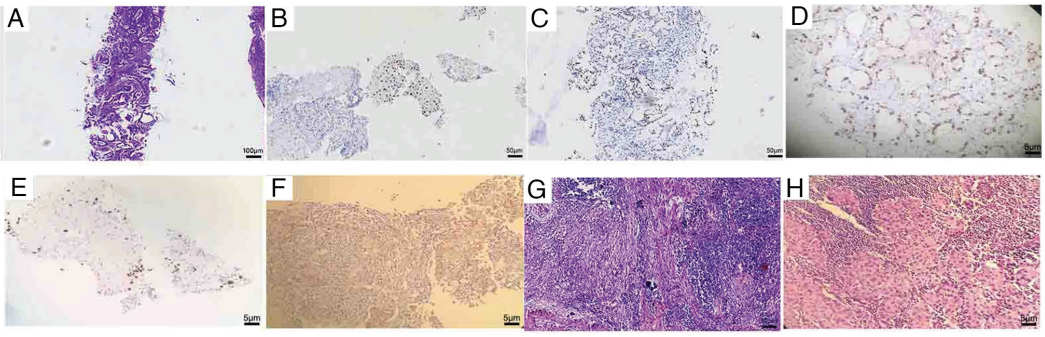

Figure 2. Pathological images. (A) H&E staining was used to detect surviving tumor cells before the administration of adjuvant therapy (magnification, x100). (B) Immunohistochemical staining of p40 (magnification, x200). (C) Immunohistochemical staining of TTF-1 (magnification, x200). (D) The Ki-67 positivity rate was ~60% in adenocarcinoma (magnification, x200). (E) The Ki-67 positivity rate was ~5% in squamous carcinoma (magnification, x200). (F) Programmed death-ligand 1 expression had a positivity rate of 15% (magnification, x200). (G) After adjuvant therapy, the primary tumor bed was stained with H&E, showing no surviving tumor cells (magnification, x200). (H) After adjuvant therapy, the 10th group of lymph nodes was immunohistochemically characterized as poorly differentiated adenocarcinoma (magnification, x200). H&E, hematoxylin and eosin; TTF-1, thyroid transcription factor 1.

advanced NSCLC (15); however, a significant proportion of patients cannot tolerate the treatment. Neoadjuvant therapy is currently in its nascent stages of development (16). The study by Kang *et al* (17) indicated that the utilization of neoadjuvant

anti-PD-1 immunotherapy exhibits promising long-term efficacy in individuals diagnosed with resectable stage I-IIIA NSCLC. A phase 1b clinical trial (ChiCTR-OIC-17013726) involving patients with stage IIIB NSCLC evaluated the safety and efficacy of neoadjuvant therapy using PD-1 inhibitors, specifically sintilimab (18). Patients received two cycles of sintilimab (200 mg; intravenous injection on day 22), followed by surgical intervention between days 29 and 43. The results showed that out of the 37 participants who underwent curative resection, 15 patients (40.5%) achieved a major pathological response, with complete tumor regression in 6 patients (16.2%) and lymph node regression in 3 patients (8.1%) (19). These findings highlight the significant benefits of sintilimab as a neoadjuvant therapy in the treatment of lung cancer.

Recent research findings have suggested the feasibility of combining neoadjuvant sintilimab with chemotherapy for stage III NSCLC (20). However, further clinical investigations are warranted to explore the potential of sintilimab as neoadjuvant immunotherapy for lung adenocarcinoma and squamous cell carcinoma. The present study demonstrated a favorable outcome of chemoimmunotherapy implemented as neoadjuvant therapy for lung adenocarcinoma, and the success of the treatment can be attributed to two potential factors: Firstly, the pathological examination revealed the coexistence of both adenocarcinoma and squamous cell carcinoma components in this tumor, which exhibit distinct immune microenvironments (21). Furthermore, the augmented presentation of surface antigens due to increased tumor volume can potentiate the response of the immune system to tumor eradication, thereby facilitating enhanced therapeutic outcomes (22). Currently, there is a lack of standardized guidelines for assessing the efficacy of adjuvant therapy in lung adenocarcinoma. However, several scholars have argued that pathological assessment can effectively reflect clinical efficacy (23). After two cycles of treatment, the patient's response was assessed as stable disease, while postoperative pathology results confirmed the success of complete resection (R0). However, in this case, it is noteworthy that the primary lesions of the patients showed a higher response rate than the lymph nodes, which was possibly attributable to differences in the molecular composition of the tumors (24). It is also possible that Ki-67 expression in primary tumors is higher than the expression in the lymph nodes (25). Enhanced blood supply in primary tumors improves the delivery and efficacy of chemotherapy and targeted therapy drugs, while poorer blood flow to the lymph nodes may restrict drug access, serving as another possible reason for this discrepancy (26).

In conclusion, the present case study highlights a promising approach for the neoadjuvant treatment of operable lung adenosquamous carcinoma. Preliminary evidence suggests the potential efficacy of neoadjuvant chemoimmunotherapy using sintilimab for treating lung adenosquamous carcinoma. A limitation of the present study was the absence of pre-treatment histopathological or positron emission tomography-CT confirmation of lymph node status, increasing the potential for false-positives from CT imaging alone. This methodology was chosen to minimize patient burden and costs before the planned surgical evaluation and lymphadenectomy. In comparison with a previous study utilizing dacomitinib alone, the neoadjuvant treatment regimen used in the present study resulted in a a pathological complete response, while the comparative case still presented with adenosquamous carcinoma (15). In terms of adverse reactions, the good tolerability of the present regimen contrasts with the comparative literature, where a grade 1 rash was reported (27). This highlights the advantages of the present treatment with regard to safety and reducing adverse effects. The present regimen had a notable impact by reducing tumor size and enhancing treatment safety, reinforcing the importance of further exploring and validating different neoadjuvant treatment approaches. The future direction in lung adenosquamous carcinoma research requires comprehensive clinical trials to be conducted that not only benchmark the efficacy of various neoadjuvant regimens against each other, but also rigorously assess the predictive utility of biomarkers such as programmed death-ligand 1 expression levels, tumor mutational burden and EGFR mutations. This approach aims to personalize therapy based on individual patient profiles. Essential to this research are longitudinal studies that track long-term outcomes, highlighting the importance of sustained patient welfare post-treatment. By adopting a multidisciplinary and patient-centric methodology, we are dedicated to refining treatment strategies that promise to significantly improve patient prognosis and elevate quality of life.

Acknowledgements

Not applicable.

Funding

No funding was received.

Availability of data and materials

The data generated in the present study may be requested from the corresponding author.

Authors' contributions

CS drafted the initial manuscript and was involved in the conception and design of the study. YN critically revised the manuscript for important intellectual content and contributed to the analysis and interpretation of data. TL, XP, JL and ZZ were involved in the preparation of images, contributing to the analysis and interpretation of data. YH contributed to the project's conception and design, and provided final approval for the version to be published. YN and YH confirm the authenticity of all the raw data. All authors have read and approved the final version of the manuscript.

Ethics approval and consent to participate

Not applicable.

Patient consent for publication

Written informed consent was obtained from family members of the patient to publish the present case report with the accompanying images.

Competing interests

The authors declare that they have no competing interests.

References

1. Huang C, Xu J and Li Z: Research Progress of Cancer-associated Fibroblasts in Lung Cancer]. Zhongguo Fei Ai Za Zhi 23: 267-273, 2020 (In Chinese).
2. Marx A, Chan JK, Coindre JM, Detterbeck F, Girard N, Harris NL, Jaffe ES, Kurrer MO, Marom EM, Moreira AL, *et al*: The 2015 World health organization classification of tumors of the thymus: Continuity and changes. J Thorac Oncol 10: 1383-1395, 2015.
3. Liu Y, Zhu Y, Bai L, Chen F, Wang J and Guo Y: Adenocarcinomatous-predominant subtype associated with a better prognosis in adenosquamous lung carcinoma. BMC Cancer 20: 520, 2020.
4. Travis WD, Brambilla E, Burke AP, Marx A and Nicholson AG: Introduction to The 2015 World health organization classification of tumors of the lung, pleura, thymus, and heart. J Thorac Oncol 10: 1240-1242, 2015.
5. Filosso PL, Ruffini E, Asioli S, Giobbe R, Macri L, Bruna MC, Sandri A and Oliaro A: Adenosquamous lung carcinomas: A histologic subtype with poor prognosis. Lung Cancer 74: 25-29, 2011.
6. Maeda H, Matsumura A, Kawabata T, Suito T, Kawashima O, Watanabe T, Okabayashi K and Kubota I; Japan National Hospital Organization Study Group for Lung Cancer: Adenosquamous carcinoma of the lung: Surgical results as compared with squamous cell and adenocarcinoma cases. Eur J Cardiothorac Surg 41: 357-361, 2012.
7. Forde PM, Spicer J, Lu S, Provencio M, Mitsudomi T, Awad MM, Felip E, Broderick SR, Brahmer JR, Swanson SJ, *et al*: Neoadjuvant nivolumab plus chemotherapy in resectable lung cancer. N Engl J Med 386: 1973-1985, 2022.
8. Zhang L, Mai W, Jiang W and Geng Q: Sintilimab: A Promising Anti-Tumor PD-1 Antibody. Front Oncol 10: 594558, 2020.
9. Jiang J, Wang Y, Gao Y, Sugimura H, Minervini F, Uchino J, Halmos B, Yendamuri S, Velotta JB and Li M: Neoadjuvant immunotherapy or chemoimmunotherapy in non-small cell lung cancer: A systematic review and meta-analysis. Transl Lung Cancer Res 11: 277-294, 2022.
10. Detterbeck FC, Boffa DJ, Kim AW and Tanoue LT: The Eighth Edition lung cancer stage classification. Chest 151: 193-203, 2017.
11. Huber RM, Kauffmann-Guerrero D, Hoffmann H and Flentje M: New developments in locally advanced nonsmall cell lung cancer. Eur Respir Rev 30: 200227, 2021.
12. Sun C, Liu Y, Zhang P, Wang X, Xu Y, Lin X, Ma X, Guo Y, Qiu S, Shao G, *et al*: Interim analysis of the efficiency and safety of neoadjuvant PD-1 inhibitor (sintilimab) combined with chemotherapy (nab-paclitaxel and carboplatin) in potentially resectable stage IIIA/IIIB non-small cell lung cancer: A single-arm, phase 2 trial. J Cancer Res Clin Oncol 149: 819-831, 2023.
13. Eisenhauer EA, Therasse P, Bogaerts J, Schwartz LH, Sargent D, Ford R, Dancey J, Arbuck S, Gwyther S, Mooney M, *et al*: New response evaluation criteria in solid tumours: Revised RECIST guideline (version 1.1). Eur J Cancer 45: 228-247, 2009.
14. Thai AA, Solomon BJ, Sequist LV, Gainor JF and Heist RS: Lung cancer. Lancet 398: 535-554, 2021.
15. Zhang N, Chen S, Guo L and Chen X: A case report of right upper lung adenosquamous carcinoma resection following neoadjuvant targeted therapy. Ann Palliat Med 10: 4987-4993, 2021.
16. Brody R, Zhang Y, Ballas M, Siddiqui MK, Gupta P, Barker C, Midha A and Walker J: PD-L1 expression in advanced NSCLC: Insights into risk stratification and treatment selection from a systematic literature review. Lung Cancer 112: 200-215, 2017.
17. Kang J, Zhang C and Zhong WZ: Neoadjuvant immunotherapy for non-small cell lung cancer: State of the art. Cancer Commun (Lond) 41: 287-302, 2021.
18. Xie J, Wu X, Wu J, Huang F and Xu L: Meta-analysis of the efficacy and safety of sintilimab for treating advanced non-small cell lung cancer. Oncol Lett 24: 425, 2022.
19. Gao S, Li N, Gao S, Xue Q, Ying J, Wang S, Tao X, Zhao J, Mao Y, Wang B, *et al*: Neoadjuvant PD-1 inhibitor (Sintilimab) in NSCLC. J Thorac Oncol 15: 816-826, 2020.
20. Shao M, Yao J, Wang Y, Zhao L, Li B, Li L, Wu Z, Chen Z, Fan J and Qiu F: Two vs three cycles of neoadjuvant sintilimab plus chemotherapy for resectable non-small-cell lung cancer: NeoSCORE trial. Signal Transduct Target Ther 8: 146, 2023.
21. Gandhi L, Rodríguez-Abreu D, Gadgeel S, Esteban E, Felip E, De Angelis F, Domine M, Clingan P, Hochmair MJ, Powell SF, *et al*: Pembrolizumab plus Chemotherapy in Metastatic Non-Small-Cell Lung Cancer. N Engl J Med 378: 2078-2092, 2018.
22. Expert Committee on Quality Control of Lung Cancer, National Quality Control Center for Cancer: Expert consensus on the pathological evaluation of neoadjuvant therapy efficacy for non-small cell lung cancer. Zhonghua Bing Li Xue Za Zhi 50: 1002-1007, 2021 (In Chinese).
23. Song P, Zhang J, Shang C and Zhang L: Curative effect assessment of immunotherapy for non-small cell lung cancer: The 'blind area' of Immune Response Evaluation Criteria in Solid Tumors (iRECIST). Thorac Cancer 10: 587-592, 2019.
24. Fleming CA, McCarthy K, Ryan C, McCarthy A, O'Reilly S, O'Mahony D, Browne TJ, Redmond P and Corrigan MA: Evaluation of discordance in primary tumor and lymph node response after neoadjuvant therapy in breast cancer. Clin Breast Cancer 18: e255-e261, 2018.
25. Wei J, Xiang J, Hao Y, Si J, Gu X, Xu M and Song Z: Clinical outcomes of immune checkpoint inhibitor therapy for advanced lung adenosquamous carcinoma. J Thorac Dis 15: 260-269, 2023.
26. Li C and Lu H: Adenosquamous carcinoma of the lung. Onco Targets Ther 11: 4829-4835, 2018.
27. Liu Y, Gao Z, Zhang C, Liu X, Liu Z, Lin X, Qian B, Jin F, Shao G and Yang Z: Asynchrony of primary tumor and mediastinal lymph nodes response after neoadjuvant immunotherapy plus chemotherapy in a patient with stage IIIA non-small-cell lung cancer: A case report. Anticancer Drugs 33: e784-e788, 2022.