SPANDIDOS PUBLICATIONS

ONCOLOGY LETTERS 28: 417, 2024

# Ectopic Cushing syndrome in metastatic castration-resistant prostate cancer: A case report and review of literature

ANGELIKI ANDRIKOPOULOU[1*], KRISTIANA GOGA[1*], KATERINA STEFANAKI[2], STAVROULA A. PASCHOU[2], STAVROS ATHANASOPOULOS[2], FLORA ZAGOURI[1] and MELETIOS-ATHANASIOS DIMOPOULOS[1]

[1]Department of Clinical Therapeutics, Alexandra Hospital, National and Kapodistrian University of Athens, 11528 Athens, Greece; [2]Department of Clinical Therapeutics, Endocrine Unit and Diabetes Centre, Alexandra Hospital, School of Medicine, National and Kapodistrian University of Athens, 11528 Athens, Greece

Received February 19, 2024; Accepted April 3, 2024

DOI: 10.3892/ol.2024.14550

**Abstract.** Cushing's syndrome (CS), as a result of ectopic adrenocorticotropic hormone (ACTH) production, constitutes a common paraneoplastic manifestation of various malignancies, with the most common being small cell lung carcinoma. In the literature, fewer than fifty cases associating ectopic CS with prostate cancer have been documented. In the present study, the case of a 76-year old man suffering from castration-resistant prostate adenocarcinoma that had been treated with enzalutamide and luteinizing hormone-releasing hormone (LHRH) analogue for the last four years is presented. The patient presented to the emergency department with lower extremity muscle weakness, bradypsychia and hypokalemia. Following a thorough diagnostic evaluation, hypercortisolemia was identified. No suppression after low- and high-dose dexamethasone challenge, increased cortisol 24 h excretion and normal pituitary magnetic resonance imaging led to the diagnosis of ectopic CS. Immediate targeted therapy was initiated with adrenal steroidogenesis inhibitors, including metyrapone and ketoconazole along with chemotherapy with docetaxel and prednisolone. There was a remarkable decrease in cortisol levels within days and hospitalization was no longer required. The patient managed to complete three cycles of chemotherapy; unfortunately, he succumbed within three months of the diagnosis of ectopic CS. In the present study, all existing cases of paraneoplastic CS related to prostate cancer are reviewed. The aim of the current study was to highlight the need of early diagnosis and treatment of this entity as it may present with atypical clinical findings and potentially evolve to a life-threatening condition.

*Correspondence to:* Dr Angeliki Andrikopoulou, Department of Clinical Therapeutics, Alexandra Hospital, National and Kapodistrian University of Athens, Vasilissis Sofias 80, 11528 Athens, Greece
E-mail: aggelikiandrikop@gmail.com

[*]Contributed equally

*Key words:* Cushing syndrome, ectopic adrenocorticotropic hormone, prostate cancer, paraneoplastic syndrome, neuroendocrine dedifferentiation

## Introduction

Prostate cancer is the second most common cancer in males accounting for more than 900,000 cases per year (1). Adenocarcinoma is by far the most common subtype and affects more than 95% of the patients (2). Androgen deprivation therapy (ADT) remains the cornerstone of treatment for metastatic prostatic adenocarcinoma. Despite the initial response to androgen blockade, castration resistance often occurs via multiple mechanisms through androgen receptor (AR) pathway or others. Neuroendocrine dedifferentiation is one of the AR-independent castration resistance mechanisms that lead to an aggressive phenotype (3,4). While neuroendocrine differentiation in prostate cancer (NEPC) is a rare phenomenon in primary prostate cancer (<2%), it is detected in up to 10-17% of metastatic castrate-resistant prostate cancer (3). In addition, NEPC is often observed among males who have been previously treated with ADT or radiotherapy for prostate cancer (4,5). These types of tumors express typical neuroendocrine markers such chromogranin, synaptophysin (SYP) and specific neuronal enolase (NSE) but lack the expression of AR and AR-mediated genes (3,5). These tumors may originate *de novo* from a small population of neuroendocrine cells present in the prostate but usually occur from a population of luminal-derived castration-resistant cells through a neuroendocrine differentiation (NED) or trans-differentiation process. This phenotypic change can lead to a more aggressive clinical presentation with atypical manifestations and fewer effective treatment options. Bioactive substances produced by these cells can lead to paraneoplastic syndromes, including ectopic adrenocorticotropic hormone (ACTH) secretion. In the present study, a case of paraneoplastic Cushing syndrome (CS) in a patient with metastatic prostate cancer is presented. A review of the literature on this rare clinical entity is also presented to improve characterization of the clinical features and prognosis.

## Case report

A 76-year old patient with a four-year history of metastatic prostate adenocarcinoma presented to the emergency department due to rapid-onset lower extremity weakness. The patient was first diagnosed with de novo metastatic prostate cancer in 2019 and was under ADT with enzalutamide and luteinizing hormone-releasing hormone analogue for the last four years. Biopsy of the prostate was performed in 2019 and revealed an adenocarcinoma Gleason 8 (5+3) of the prostate. Prostate-specific antigen (PSA) at initial diagnosis was 12.5 ng/ml and declined progressively to 0.007 ng/ml in 2022 after the initiation of enzalutamide. The patient now presented with lumbar pain and thus a magnetic resonance imaging (MRI) of the lumbar spine was performed which revealed the presence of an intraspinal metastasis in front of the fourth lumbar vertebra causing spinal cord compression. CT scans of the chest and abdomen showed an additional soft tissue metastasis on the left iliac bone and regional lymph node metastases. The patient started palliative radiotherapy at the metastatic foci of the O4 lumbar vertebrae and left iliac bone and was about to initiate chemotherapy with docetaxel. Of note, baseline PSA at disease progression was 0.48 ng/ml before the administration of chemotherapy.

The patient presented at the Emergency Department on the 13th of June 2023 with lower extremity muscle weakness and hypokalemia (2 mEq/l). He was hemodynamically stable and on inspection he appeared pale. Neurologically, he was oriented but exhibited emotional lability with bradypsychia. There were no focal neurological deficits in the lower extremities. Laboratory findings showed marked hypokalemia with serum potassium level of 2 mEq/l (3,5-5,1 mEq/l), metabolic alkalosis (HCO3: 48,5 mEq/l) and an elevated lactate dehydrogenase level of 461 U/l (135-225 U/l). Electrocardiogram revealed a prolonged QT interval with a corrected QT interval of 473 ms. The patient received intravenous and oral potassium supplements to prevent life-threatening arrhythmias and further investigation of hypokalemic alkalosis was initiated. The laboratory findings of the initial assessment are demonstrated in Table I.

No episodes of diarrhea or vomiting were reported from recent medical history, thus potassium loss from the gastrointestinal tract was excluded. Additionally, urine electrolytes were within normal limits, hence renal potassium loss was also excluded. Therefore, endocrinological causes of hypokalemia were investigated. An adrenal protocol CT scan was performed which revealed no pathologic findings. Based on the aforementioned findings, evaluation of renin, aldosterone, ACTH and cortisol levels was requested. The aforementioned tests revealed normal renin and aldosterone levels but elevated plasma cortisol levels >1,380 nmol/l (138-690 nmol/l) along with elevated plasma ACTH levels 194 pg/ml (<46 pg/ml). Measurement of 24 h urinary free cortisol revealed a value of 20,600.00 $\mu$g/gCr (1.00-119.00 $\mu$g/gCr). There was no suppression after both low-dose and high-dose dexamethasone challenge. Pituitary MRI was performed but revealed no pathologic findings (Fig. 1). Consequently, the patient was diagnosed with CS and ectopic ACTH production was considered the most likely diagnosis associated with paraneoplastic syndrome in the context of metastatic prostate adenocarcinoma.

Clinical deterioration was acute and thus both symptomatic treatment and chemotherapy were initiated. Symptomatic treatment included oral potassium supplements, potassium-sparing diuretics, along with mineralocorticoid blockade (spironolactone). Treatment with ketoconazole 200 mg and metyrapone 500 mg three times per day, which block the steroid biosynthetic pathway, was initiated. Additionally, anticoagulant therapy was administered due to increased risk of thromboembolism. The patient remained under close monitoring throughout the course of his treatment and did not experience any treatment-related adverse events, including hepatotoxicity, which is most commonly reported. On the 10th day of treatment with ketoconazole and metyrapone, lab tests revealed a decrease in serum cortisol levels (425 nmol/l) and ACTH levels (129 pg/ml) along with the stabilization of potassium levels (Fig. 2A and B). Following the clinical and laboratory stabilization of the patient, chemotherapy with docetaxel 75 mg/m$^2$ and prednisolone 5 mg bid was initiated. The patient was discharged from hospital after one month of hospitalization and continued chemotherapy. PSA declined from 0.48 to 0.22 ng/ml after three cycles of docetaxel administration. However, the patient died three months after initial presentation despite his initial response to treatment.

## Discussion

Ectopic CS constitutes a rare paraneoplastic entity in prostate cancer. Ectopic CS as a paraneoplastic syndrome accounts for only 10-15% of CS cases and is mostly related to small cell lung cancer, pancreatic, thymus or thyroid carcinoma (6). This case highlights the urgency of diagnosing this entity and the importance of initiating treatment promptly. A case of ectopic ACTH production in a patient with castration-resistant metastatic prostate cancer who had previously received enzalutamide plus ADT is presented in the current study. Despite prompt diagnosis of ectopic Cushing disease and immediate initiation of treatment with ketoconazole and metyrapone, the patient deteriorated and eventually succumbed at three months after initial presentation with CS.

The existing literature for cases of CS related to prostate cancer was reviewed. The search strategy consisted of the following keywords: 'cushing syndrome' AND 'prostate cancer' that was applied to PUBMED bibliographical database (https://pubmed.ncbi.nlm.nih.gov/). Overall, a total of 102 papers were retrieved from the search algorithm. After the removal of two review articles (7,8) as well as two non-English papers (9,10), a total of 26 articles were considered eligible for this review (11-36). An additional search of the literature cited in the aforementioned papers revealed 12 more eligible papers (37-48). Finally, a google research was performed that revealed three additional papers (49-52). The search algorithm is illustrated in Fig. 3 and all the cases identified are summarized in Table II. Papers reporting neuroendocrine differentiation of the prostate with positive ACTH staining without clinical manifestations of ACTH serum production were excluded (53-58).

The first case reports of ectopic ACTH production in patients with prostatic carcinoma date back to the 1960s written by Webster *et al* (38) and Jarett *et al* (56). However, either tissue staining for ACTH was not available (38) or the

Table I. Laboratory results at initial assessment.

| Analyte | Result | Reference interval |
|---|---|---|
| Serum potassium | 2 mEq/l | 3,5-5,1mEq/l |
| Glucose | 199 mg/dl | 75-115 mg/dl |
| Lactate dehydrogenase | 461 U/l | 135-225 U/l |
| HbA1c | 6.1% | 4.5-6% |
| Serum cortisol (08:00) | >1,380 nmol/l | 138-690 nmol/l |
| Serum bicarbonate | 48,5 mEq/l | 22-29 mEq/l |
| Arterial pH | 7,66 | 7,35-7,45 |
| Initial endocrine evaluation | | |
| Midnight cortisol | >1,380 nmol/l | 138-690 nmol/l |
| 1 mg overnight dexamethasone suppression test | >1,380 nmol/l | 138-690 nmol/l |
| 8 mg overnight dexamethasone suppression test | >1,380 nmol/l | 138-690 nmol/l |
| 24 h urinary free cortisol | 20,600.00 $\mu$g/gCr | 1.00-119.00 $\mu$g/gCr |
| Plasma ACTH | 194 pg/ml | <46 pg/ml |

ACTH, adrenocorticotropic hormone.

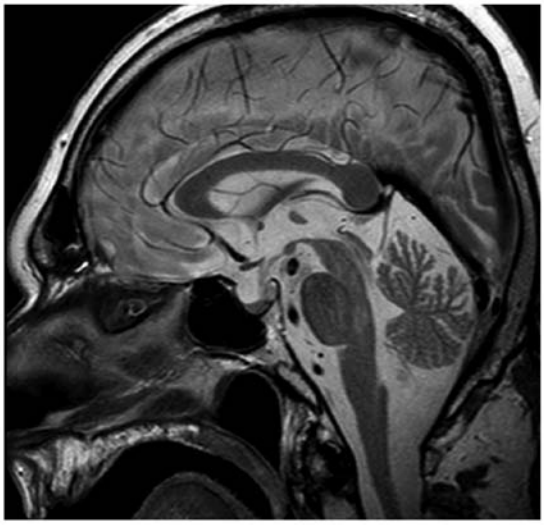

Figure 1. Pituitary magnetic resonance imaging T2 with no pathological findings.

primary tumor displayed no staining with the fluorescent anti-ACTH (56). The first well-documented case report of a patient with prostatic adenocarcinoma producing ACTH was presented by Newmark *et al* (37). Since then, several other cases of ectopic CS related to prostate cancer have been reported and are summarized in Table II. CS is a result of the ectopic production of ACTH in all of the cases except for two cases where corticotropin-releasing hormone (CRH) produced by the prostatic tumor is the driving cause (13,14). Indeed, CRH production from prostate cancer implicates 14% of the cases and is considered as an extremely rare source of ectopic ACTH (1-3%) (59). Histologically, CS emerged from small cell carcinoma of the prostate in 18 cases (11,13-15,20-22,24,25,27, 29-31,33,34,47,50,51), neuroendocrine carcinoma of the prostate in five cases (17,21,26,28,32), prostate adenocarcinoma usually poorly differentiated/undifferentiated in 16 cases (16,18,19,23,35-39,41,42,44-46,49,52), anaplastic carcinoma in two cases (12,19) and carcinoid tumor of the prostate in another two cases (40,43). In the vast majority of the cases disease was metastatic with distant visceral metastases except for 11 cases (11,18,19,22,30,33,40,41,47,49,51) where disease was either locally advanced or metastatic only to lymph nodes.

Interestingly, the typical clinical manifestations of CS with centripetal obesity, moon facies, purple striae, buffalo hump and skin hyperpigmentation are rarely present (12,17,23,31,36,47). In most cases, muscle weakness, mental changes mild hypertension and edema are the presenting symptoms along with hypokalemic alkalosis and elevated glucose levels from laboratory tests (11,13-16,18-22,24-30,32-35,37-41,43-46,49-52). In the present case, the main clinical feature was limb muscle weakness combined with severe hypokalemic alkalosis. This comes in agreement with the existing literature which identifies hypokalemic alkalosis as often the only initial manifestation of the syndrome. This clinical picture reflects the rapid onset and aggressiveness of the syndrome. Most patients die early because of the underlying malignancy before the development of typical Cushing's symptoms. Indeed, typical Cushing's signs and symptoms develop under the condition of long-term hypercortisolism, so ectopic CS tends to present with less dramatic features, but higher blood pressure and more profound electrolyte abnormalities. Laboratory findings typically include hypokalemic alkalosis, elevated plasma glucose along with elevated plasma cortisol and ACTH levels and increased glucocorticoid excretion in urine as in the present case.

Initiation of supportive medication with oral or intravenous potassium supplements may be required. Treatment of CS is based on adrenal steroidogenesis inhibitors, including ketoconazole, metyrapone, mitotane or mifepristone (14, 16-23,25-28,31-35,37,43-45,47,49-52) in over half of the cases (28/43; 65%) and more rarely etomidate (17,33) (2/43; 5%), as well as the newest therapeutic agent osilodrostat. Hypercortisolism may be controlled by blocking one or

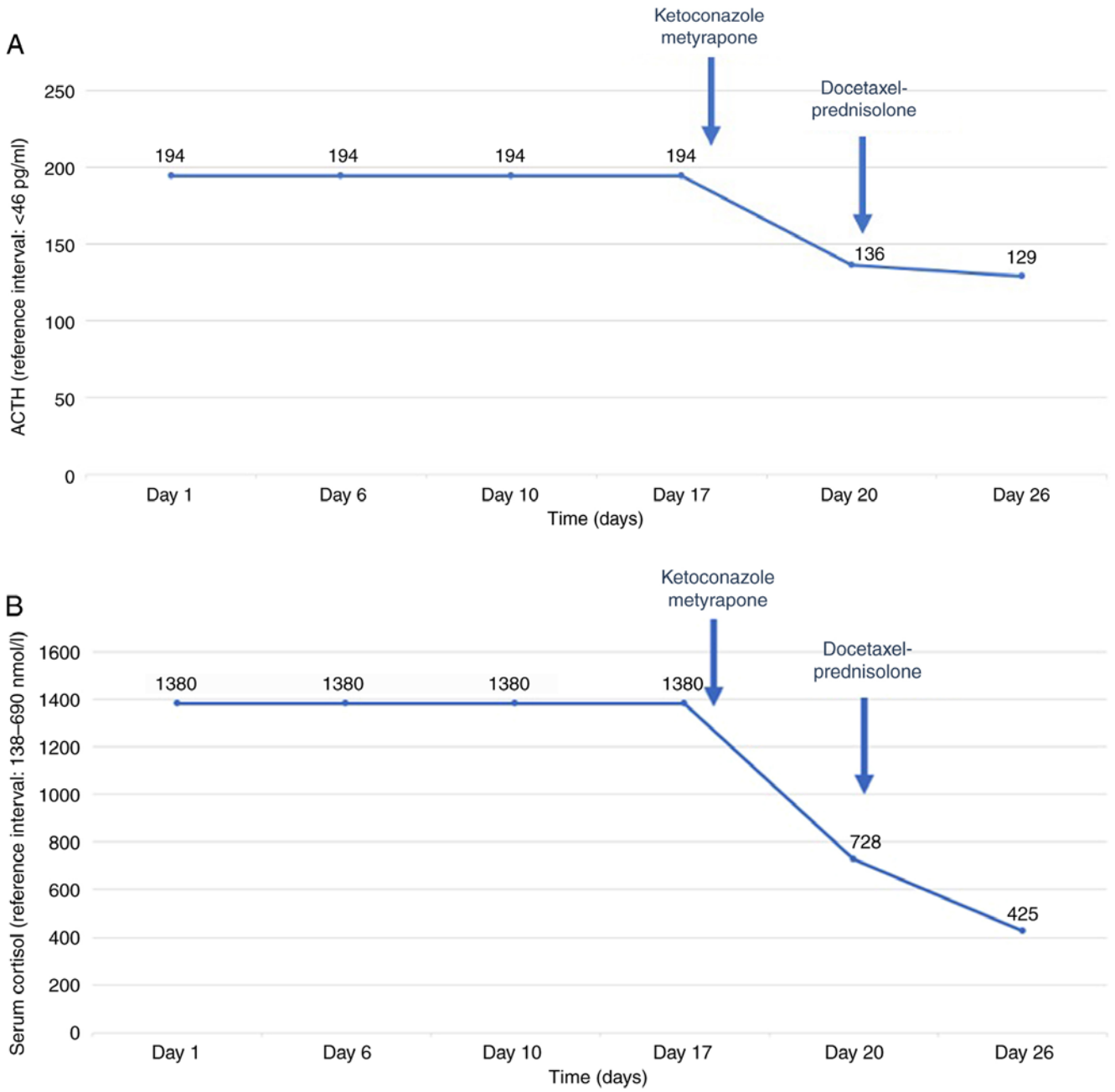


Figure 2. (A) Response of ACTH levels with adrenal blockage therapy. ACTH reference interval: <46 pg/ml (B) Response of serum cortisol levels within 10 days of therapy with ketoconazole and metyrapone. Serum cortisol reference interval: 138-690 nmol/l. ACTH, adrenocorticotropic hormone.

more adrenal enzymes, such as mitotane and metyrapone that inhibit 11β-hydroxylase or ketoconazole that inhibits both 17α-hydroxylase and 17,20-lyase. Interestingly, the somatostatin receptor ligand pasireotide is approved for patients with CS who have persistent or recurrent hypercortisolism and the dopamine agonist cabergoline facilitates initial normalization of urinary free cortisol levels and also improves the signs and symptoms of hypercortisolism. The cornerstone of treatment however remains the surgical removal of the tumor when is feasible. However, most of the ectopic ACTH-producing tumors are not resectable while patients may not be clinically fit enough for surgery. In these cases, supportive medication with antiglucocorticoid drugs is the preferred treatment option along with chemotherapy for the primary tumor. Chemotherapy was administered in one third of the cases (14/43) (13,17,19,21,22,24-27,31,35,47,52) and was mainly based on platinum-etoposide combinations. Whatever the treatment, prognosis is abysmal and median survival is as reported (Table II).

Neuroendocrine cells that lack androgen receptors are normally part of the normal prostate tissue and play a regulatory role in proliferation and secretion of the prostate epithelium (6,60). Neuroendocrine cells constitute only <1% of total epithelial cells found in prostate tissue and serve a paracrine or local regulatory role by secreting serotonin, calcitonin and other peptides (60). The inappropriate production of ACTH is attributed to these neuroendocrine cells that are part of the amine precursor uptake and decarboxylation

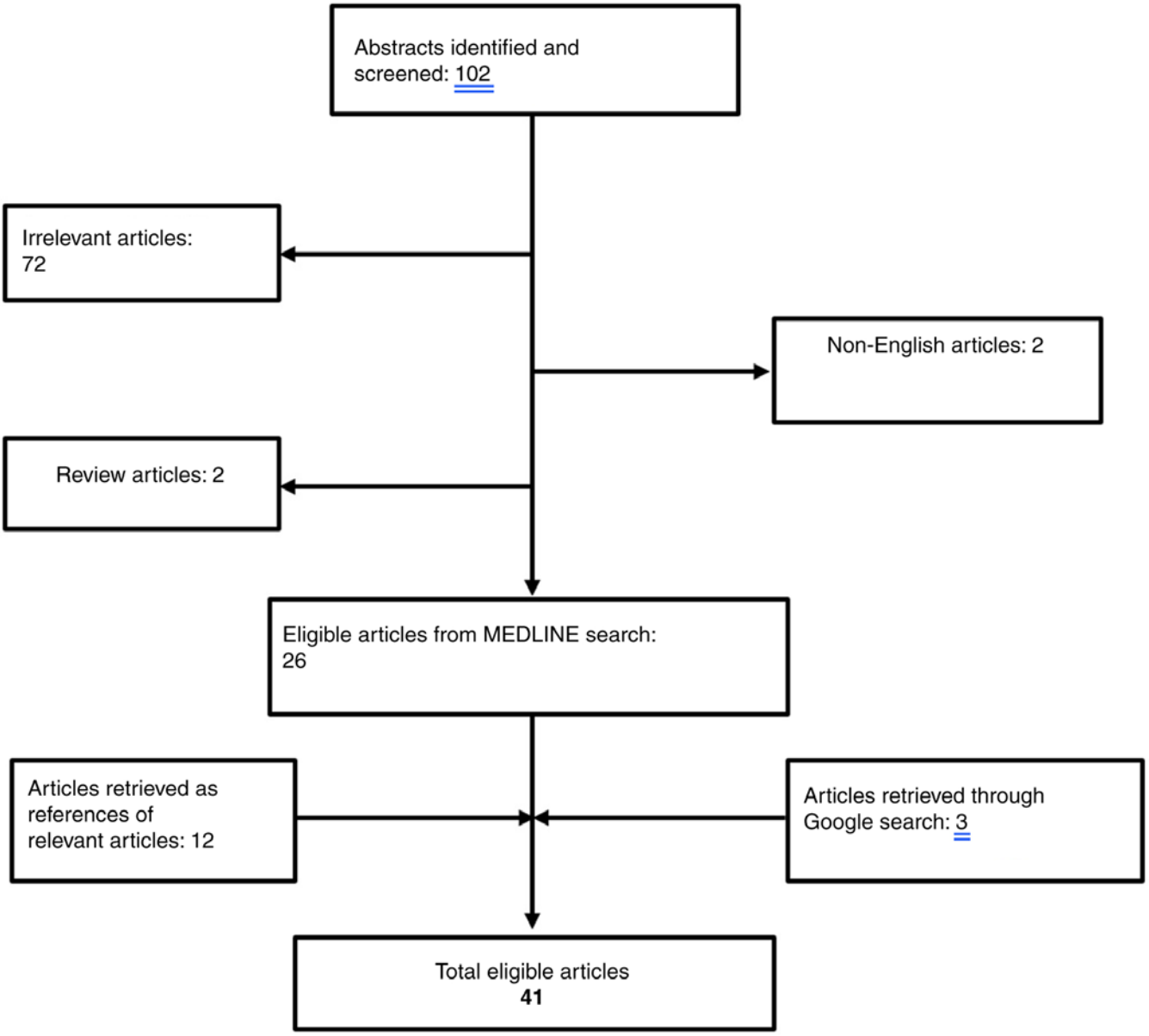


Figure 3. Flowchart presenting the successive steps during the selection of studies.

(APUD) regulatory system (60). Neuroendocrine APUD cells are dispersed in numerous organs and systems in small concentrations such as gastrointestinal tract, lung and prostate and serve as one of the most important mechanisms of homeostasis. These cells have common biochemical and cytological properties as well as the ability to secrete polypeptides that include ACTH, neuron-specific enolase (NSE) and chromogranin A (CGA) (60). *In vitro* experiments have revealed that during androgen deprivation treatment (ADT), prostate adenocarcinoma cells have the capacity to transdifferentiate to a neuroendocrine (NE) phenotype, a process called neuroendocrine trans-differentiation. *De novo* prostate neuroendocrine carcinoma (small cell or large cell) is a rare entity (<2%), however treatment-emergent neuroendocrine neoplasms account for 10-17% of patients with metastatic CRPC (3). Indeed, a substantial population of pre-treated end-stage prostate cancer patients show salient features of de novo neuroendocrine small cell carcinomas, mostly with an aggressive behavior and often with visceral metastases. Radiotherapy and androgen deprivation therapy activate the process of neuroendocrine dedifferentiation through the following mechanisms: Either they induce malignant transformation of neuroendocrine cells within adenocarcinoma cells or they facilitate the growth of pre-existing neuroendocrine cells. In this manner, cancer cells lack androgen receptors and transform into castration-resistant prostate cancer cells resulting in disease progression. Although most patients are not routinely biopsied in end-stage disease, it has been estimated that at least 25% of the patients with advanced prostate cancer will develop neuroendocrine prostate cancer under androgen deprivation pressure (4). Neuroendocrine prostate carcinoma differs from the conventional adenocarcinoma of the prostate histologically by expressing neuroendocrine markers such as chromogranin A, SYP, CD56, and NSE instead of prostate adenocarcinoma markers like AR, P501S, PSMA, PSAP and PSA (61). Of note, the introduction of next generation antiandrogen agents

Table II. Case reports of patients with ectopic Cushing disease associated with prostate cancer.

| Year | Authors | Histology of prostate cancer | Disease extent | Clinical manifestations | Laboratory findings | Diagnostic criteria | Treatment | Clinical outcome | (Refs.) |
|---|---|---|---|---|---|---|---|---|---|
| 1959 | Webster *et al* | Poorly differentiated adenocarcinoma | Lung, spleen, liver, left kidney, adrenals, pituitary and lumbar vertebrae metastases | Confusion, lethargy, anorexia, muscular weakness mild hypertension | Elevated glucose levels (305 mg/dl), hypokalemic alkalosis (1.8 mEq/l), glycosuria, elevated glucocorticoid excretion in urine | Elevated glucocorticoid excretion in urine, Hyperglycemia, glycosuria, adrenal hyperplasia at autopsy, normal pituitary, elevated urine potassium excretion | Estrogen, orchiectomy, insulin, intravenous potassium chloride | Death <1 week from Cushing's diagnosis | (38) |
| 1965 | Wise Jr. *et al* | Prostatic adenocarcinoma | Metastatic | Not available | Not available | Not available | Bilateral adrenalectomy | Not available | (42) |
| 1968 | Hall | Prostatic adenocarcinoma | Liver metastases | Mental changes (hypomania, disorientation), diabetes mellitus, peripheral edema, hepatomegaly, weight loss, muscle weakness, no Cushing's features | Hypokalemic alkalosis (2 mEq/l), elevated fasting plasma glucose levels (214 mg/dl), glycosuria, diffuse slowing on EEG | Elevated glucocorticoid excretion in urine | Orchiectomy and oral diethylstilbestrol daily, oral potassium supplements | Death at 2 months after Cushing's onset | (46) |
| 1973 | Newmark *et al* | Undifferentiated carcinoma | Bone, liver, lung metastases | Acute psychosis (mental changes), bilateral pitting edema | Elevated glucose levels (605 mg/dl), hypokalemic alkalosis (2.6 mEq/l), hypernatremia (156 mEq/l) | Elevated plasma ACTH (1,590 pg/ml), high ACTH tumor concentration, no suppression after high-dose DMZ challenge | Orchiectomy, mitotane, metyrapone, spironolactone, dexamethasone | Death on the 12th hospital day | (37) |
| 1975 | Lovern *et al* | Prostatic adenocarcinoma | Bone, liver, omentum, spleen, gallbladder metastases, abdominal lymph nodes metastases | Bilateral lower extremity pitting edema, muscle weakness | Elevated glucose levels (576 mg/dl), hypertension, glycosuria | Elevated plasma cortisol (3,972 nmol/l), elevated plasma ACTH (1,188 pg/ml), no suppression after low and high-dose DMZ challenge, elevated corticosteroid excretion in urine, adrenal hyperplasia | Bilateral adrenalectomy, insulin, intravenous antibiotics | Death at 3 months | (39) |

Table II. Continued.

| Year | Authors | Histology of prostate cancer | Disease extent | Clinical manifestations | Laboratory findings | Diagnostic criteria | Treatment | Clinical outcome | (Refs.) |
|---|---|---|---|---|---|---|---|---|---|
| 1977 | Wenk *et al* | Poorly differentiated, small cell ('oat-cell') carcinoma | Pelvic lymph nodes, urinary bladder | Generalized weakness, Dysuria, mild hypertension, pedal edema, confusion | Hypokalemic alkalosis (2.9 mEq/l), hypernatremia (162 mEq/l), diabetes mellitus, hyperosmolality (345 mOm/kg), elevated plasma ACTH and cortisol | Elevated plasma ACTH (133 pg/ml) and cortisol (1,434 nmol/l), high ACTH tumor concentration (4,010 pg/g tissue), no suppression after high-dose DMZ challenge | Insulin, furosemide, antibiotics for UTI | Death on the 23rd day | (11) |
| 1978 | Molland | Poorly differentiated adenocarcinoma of the prostate | No metastases | Mental changes (hypomania), bilateral lower extremity edema, no Cushing's features | Elevated glucose levels (260 mg/dl), glycosuria, hypokalemic alkalosis (2.4 mEq/l) | Elevated plasma cortisol levels (2,759 nmol/l), adrenal hyperplasia, Crooke's hyaline changes of the pituitary | No treatment | Death at 4 weeks | (41) |
| 1981 | Statham *et al* | Poorly differentiated adenocarcinoma of the prostate | Liver, lung, bone metastases | Mental changes ('euphoric behavior'), polydipsia, ankle edema | Hypokalemic alkalosis (1.7 mEq/l), hypernatremia (157 mEq/l), elevated plasma glucose levels | Elevated plasma cortisol levels (>1,377 nmol/l), elevated plasma ACTH (1,589 pg/ml), bilateral adrenal hyperplasia | Metyrapone 750 mg four times per day Prednisolone 15 mg/day, orchidectomy | Death at 2 months after Cushing's onset | (45) |
| 1981 | Vuitch and Mendelsohn | Anaplastic carcinoma of the prostate | Liver, bone, retroperitoneal lymph node metastases | Moon facies, central obesity | Elevated plasma cortisol (>1,65x$10^6$ nmol/l) | Elevated plasma cortisol (>1,65x$10^6$ nmol/l), bilateral adrenal hyperplasia, no suppression after high-dose DMZ challenge, high ACTH tumor staining (10 ng/mg tissue), Crooke's hyaline changes of the pituitary | Estrogen, orchidectomy, radiation | Death at 2 months of Cushing's onset | (12) |

Table II. Continued.

| Year | Authors | Histology of prostate cancer | Disease extent | Clinical manifestations | Laboratory findings | Diagnostic criteria | Treatment | Clinical outcome | (Refs.) |
|---|---|---|---|---|---|---|---|---|---|
| 1984 | Carey *et al* | Small cell carcinoma of the prostate | Liver, lung, mediastinal lymph node, bone, stomach, dura metastases, bone marrow invasion | Polyuria, polydipsia, cachexia | Diabetes insipidus, deficiency of growth hormone and thyroid-stimulating hormone excretion, low levels of LH, FSH, testosterone (hypogonadotropic hypogonadism) | Elevated plasma cortisol levels, elevated urine cortisol excretion, No suppression after low and high-dose DMZ challenge, elevated plasma ACTH levels, positive tumor staining for CRH, hyperplasia of corticotrophs in anterior pituitary | Chemotherapy | Death on the 22nd hospital day | (13) |
| 1984 | Ghali and Garcia | Well-differentiated adenocarcinoma and carcinoid of the prostate | Lung, liver, spleen, pelvic lymph node, bone marrow, adrenal metastases | Fainting episodes, mental changes (confusion, loss of consciousness), Hypertension, bilateral ankle edema, purpuric areas on both hands, no Cushing's signs | Hypokalemic alkalosis (1.9 mEq/l), glycosuria, hypernatremia, diabetes mellitus | Elevated plasma cortisol levels (1,511 nmol/l), elevated plasma ACTH (180 pg/ml), increased urine corticosteroid excretion, no suppression after high-dose DMZ challenge, bilateral adrenal hyperplasia, Crooke's hyaline changes of the pituitary, ACTH staining of primary tumor and metastases | Mitotane | Death at 6 weeks | (43) |
| 1985 | Slater | Primary carcinoid tumor of the prostate | Locally advanced | Oliguria, hematuria, nocturia, no clinical Cushing's signs | Hypokalemic alkalosis (2.2 mEq/l) | Elevated plasma cortisol levels ($1.2 \times 10^9$ nmol/l). elevated plasma ACTH levels (340 pg/ml), increased urine corticosteroid excretion, no suppression after high-dose DMZ challenge, bilateral adrenal hyperplasia, elevated tumor ACTH concentration (20 $\mu$g/g) | Potassium supplements, subcutaneous insulin, antibiotics | Death at 1 week | (40) |

Table II. Continued.

| Year | Authors | Histology of prostate cancer | Disease extent | Clinical manifestations | Laboratory findings | Diagnostic criteria | Treatment | Clinical outcome | (Refs.) |
|---|---|---|---|---|---|---|---|---|---|
| 1988 | Fjellestad-Paulsen *et al* | Small-cell carcinoma of the prostate | Multiple metastases | Muscle weakness, abdominal pain, weight loss, hypertension, diabetes mellitus | Hypokalemia | Elevated plasma cortisol levels (1,131 nmol/l), elevated plasma ACTH levels (354 pg/ml), hyperplasia of pituitary corticotropic cells, adrenal hyperplasia, tumor staining for CRH, TSH, calcitonin and somatostatin | Ketoconazole | Death at 6 days | (14) |
| 1999 | Haukaas *et al* | Small cell carcinoma and moderately differentiated prostate adenocarcinoma | Bone, lung, liver, adrenal metastases | Weight gain, leg edema | Elevated plasma glucose (468 mg/dl), hypokalemia (1.9 mEq/l) | Elevated plasma ACTH levels (25 pg/ml), elevated plasma cortisol levels (>1,500 nmol/l), increased urine cortisole excretion (573 nmol/24 h), elevated ACTH and deoxycortisole levels after suppression with metopiron | High-dose estrogen treatment, insulin, aldosterone antagonist, diuretics, potassium | Death at 2 months after treatment initiation | (15) |
| 2001 | Rickman *et al* | Prostatic adenocarcinoma | Liver, bone metastases | Mental changes (confusion), lower-extremity edema, hypertension, weight loss, no Cushing's signs | Hypokalemic alkalosis (2.2 mEq/l), diabetes mellitus | Elevated plasma cortisol levels (3,724 nmol/l), elevated plasma ACTH levels (13,87 pg/ml), elevated serum CRH levels (69 pg/dl), increased urine cortisol excretion (16,276 $\mu$g/24 h), bilateral adrenal hyperplasia, no suppression after high-dose DMZ challenge | Ketoconazole 1,200 mg/d, Intravenous potassium replacement, spironolactone | Discharged on 15th hospital day-death 13 days after discharge | (16) |

Table II. Continued.

| Year | Authors | Histology of prostate cancer | Disease extent | Clinical manifestations | Laboratory findings | Diagnostic criteria | Treatment | Clinical outcome | (Refs.) |
|---|---|---|---|---|---|---|---|---|---|
| 2002 | Hussein *et al* | Poorly differentiated adenocarcinoma of the prostate | Bone, liver, lymph node metastases | Left thigh pain, generalized fatigue, bilateral lower extremity edema, pigmentation without ecchymoses, mild hypertension | Hypokalemic alkalosis (2.5 mEq/l), elevated plasma glucose levels (188 mg/dl) | Elevated cortisol levels (2,041 nmol/l), elevated ACTH levels (610 pg/ml), no suppression after high-dose DMZ challenge, increased urine cortisol excretion (9,715 $\mu$g/day), bilateral adrenal hyperplasia, positive ACTH staining of metastasis | Oral ketoconazole therapy (400 mg tid), bilateral orchiectomy, intravenous potassium supplementation, insulin, nifedipine | Death at 2.5 months after Cushing onset | (44) |
| 2007 | Johnson and Canada | Neuroendocrine carcinoma of the prostate | Bone, liver metastases | Muscle weakness, moon facies, lower extremity edema, hypertension, hyperglycemia | Hypokalemia, hypocalcemia, hypophosphatemia, hypertension, and hepatic dysfunction | Elevated plasma cortisol levels (1,594 nmol/l), elevated plasma ACTH levels (249 pg/ml), increased urine cortisol excretion (2,400 $\mu$g/day) | Oral metyrapone 750 mg every 6 h initially, intravenous etomidate (0.06 mg/kg/h), intravenous potassium, magnesium, calcium and phosphate replacement, chemotherapy with cisplatin 30 mg/m2 and etoposide 100 mg/m$^2$ | Death five days after ICU admission | (17) |
| 2007 | Kataoka *et al* | Moderately differentiated prostatic adenocarcinoma with neuroendocrine differentiation | Locally advanced-no metastases | Leg edema, mild hypertension | Hyperglycemia, Hypokalemia (1.9 mEq/l) | Elevated serum ACTH levels (181 pg/ml), elevated serum cortisol levels (184,300 nmol/l), increased urine cortisol excretion (9,890 $\mu$g/day) and corticosteroids, no suppression after low- and high-dose DMZ challenge, no response to CRH testing, bilateral adrenal hyperplasia | Oral metyrapone (3 g/day), potassium supplements | Death after two weeks | (18) |

Table II. Continued.

| Year | Authors | Histology of prostate cancer | Disease extent | Clinical manifestations | Laboratory findings | Diagnostic criteria | Treatment | Clinical outcome | (Refs.) |
|---|---|---|---|---|---|---|---|---|---|
| 2007 | Nimalasena *et al* | Patient 1: Small cell carcinoma of the prostate (from de-differentiated prostatic adenocarcinoma) | Locally advanced | Fatigue, leg and arm oedema | Hypokalemia (2.7 mEq/l) | Elevated serum ACTH levels (241 pg/ml), elevated serum cortisol levels (2,370 nmol/l) | Ketoconazole, Metyrapone | Death at 3.5 months after Cushing's diagnosis | (19) |
| 2007 | Nimalasena *et al* | Patient 2: Anaplastic small cell carcinoma | Bone, liver metastases | Muscle weakness, bilateral leg and arm edema | Hypokalemia (1.7 mEq/l) | Elevated serum ACTH levels (1,064 pg/ml), elevated serum cortisol levels (2,392 nmol/l) | Ketoconazole, octreotide, flutamide, chemotherapy with epirubicin, carboplatin, 5-fluorouracil | Death at 1 month after Cushing's diagnosis | (19) |
| 2009 | Alwani *et al* | Small cell carcinoma of the prostate | Lung, liver, kidney, spleen, bone, peritoneal metastases | Weight gain, generalized edema, hyperpigmentation of the skin, no other Cushing's signs, mild hypertensions | Hypokalemic alkalosis (2.7 mmol/l), elevated lactate dehydrogenase (798 U/l) | No suppression after DMZ testing, elevated serum ACTH levels (39 pg/ml), increased urinary free cortisol excretion, positive ACTH immunohistochemical staining at primary and metastatic tumors | Mifepristone (800 mg/day), bilateral adrenalectomy | Death at 3 weeks after adrenalectomy | (20) |
| 2008 | Rajec *et al* | Small cell carcinoma of the prostate | Bone marrow infiltration, bone, liver, retroperitoneal lymph node metastases | Mental changes, weakness of legs, fatigue, mild hypertension | Hypernatremia, hypokalemic alkalosis, hyperglycemia | Elevated plasma cortisol level, no suppression after low and high-dose DMZ | Ketoconazole, chemotherapy with cisplatin/etoposide | Death after surgery for bowel perforation | (21) |
| 2008 | Rajec *et al* | Poorly differentiated neuroendocrine carcinoma | Bone, liver metastases, urinary bladder infiltration | Progressive fatigue, dyspnea, hematuria, peripheral edemas, mental changes | Hypernatremia, hypokalemic alkalosis, hyperglycemia | Elevated plasma cortisol levels (1,340 nmol/l) | Chemotherapy with carboplatin/etoposide | Death within two weeks after Cushing's diagnosis | (21) |
| 2010 | Alshaikh *et al* | Small cell carcinoma of the prostate | Bladder and rectum invasion, retroperitoneal lymph nodes | Edema of the lower limbs, shortness of breath/orthopnea, generalized weakness/proximal muscle weakness, abdominal obesity, hypertension, congestive heart failure | Hypokalemic alkalosis (1.7 mEq/l) | Elevated urine cortisol excretion (6,214.5 $\mu$g/dl), elevated serum ACTH level (3,160 pg/ml), positive tumor staining for ACTH, no suppression after high-dose DMZ | Ketoconazole 400 mg bid, metyrapone 750 mg tid, chemotherapy with cisplatin/etoposide | Death at 6 months after prostate cancer diagnosis | (22) |

Table II. Continued.

| Year | Authors | Histology of prostate cancer | Disease extent | Clinical manifestations | Laboratory findings | Diagnostic criteria | Treatment | Clinical outcome | (Refs.) |
|---|---|---|---|---|---|---|---|---|---|
| 2010 | Lemoinne *et al* | Prostatic adenocarcinoma | No metastasis | Depression, severe hypertension and diabetes mellitus | Hypokalemia | Elevated plasma cortisol levels (1,564 nmol/l), increased urine cortisol excretion (20,200 nmol/day), elevated serum ACTH level (145 pg/ml), no suppression after low-dose DMZ, normal pituitary MRI, bilateral adrenal hyperplasia | Mifepristone | Death at 11 days) after ICU admission (within 1 month after diagnosis | (49) |
| 2011 | Ramon *et al* | Poorly differentiated adenocarcinoma of the prostate with neuroendocrine component | Bone metastases, para-aortic and para-iliac lymph nodes | Bone pain, muscle weakness, uncontrolled hypertension, moon facies, red-purple striae, multiple ecchymoses, truncal obesity, proximal muscle atrophy, hypertension | Hypokalemic alkalosis (2.7 mEq/l), elevated plasma glucose, hypocalcemia, hypophosphatemia, reduced calcitriol level | Elevated plasma ACTH level (11.9 pg/ml), increased urine free cortisol excretion (30,534 nmol/day), no suppression after high-dose DMZ, positive tumor ACTH staining | Octreotide 500 mg tid, ketoconazole 200 mg tid, bilateral adrenalectomy | Clinical improvement after adrenalectomy-resolution of Cushing's signs and symptoms | (23) |
| 2016 | Rueda-Camino *et al* | Small cell carcinoma of the prostate | Liver, bone, pelvic lymph node metastases | Mental changes (loss of consciousness), pitting pedal edema, hypertension | Hypokalemic alkalosis (2.2 mEq/l), hyperglycemia, hypercortisolemia | Elevated plasma cortisol levels (1,489 nmol/l), elevated plasma ACTH levels (250 pg/ml), increased urine free cortisol excretion (9,360 $\mu$g/day), no suppression after low and high-dose DMZ, positive tumor ACTH staining | Chemotherapy with cisplatin/etoposide | Death at 12 months after the diagnosis of prostate cancer | (24) |

Table II. Continued.

| Year | Authors | Histology of prostate cancer | Disease extent | Clinical manifestations | Laboratory findings | Diagnostic criteria | Treatment | Clinical outcome | (Refs.) |
|---|---|---|---|---|---|---|---|---|---|
| 2016 | Shrosbree *et al* | Neuroendocrine (small cell) carcinoma of the prostate | Bone, pelvic lymph node, liver, adrenal metastases | Weight loss, mental changes (delirium), peripheral edema, symmetrical proximal myopathy, multiple ecchymoses, hypertension | Diabetes, hypokalaemic alkalosis, liver dysfunction, secondary hypogonadism, secondary hypothyroidism | Adrenal hyperplasia, elevated plasma cortisol levels (2,050 nmol/l), Increased urine cortisol excretion (300,441 nmol/day), increased plasma ACTH levels (14 pg/ml), no suppression after low and high-dose DMZ, positive tumor ACTH staining, weakly positive tumor staining for ACTH | Metyrapone, chemotherapy with carboplatin/etoposide | Clinical improvement after metyrapone initiation-radiologic response to chemotherapy | (25) |
| 2016 | Ramalingam *et al* | Neuroendocrine prostate carcinoma | Bone, lung, spleen, chest wall, liver, pelvic lymph node metastases | Skin hyperpigmentation, hypertension, profound weakness/fatigue | Hypokalaemic alkalosis (1.9 mEq/l), hyperglycemia (227 mg/dl) | Elevated plasma cortisol levels (1,544 nmol/l), elevated plasma ACTH levels (206 pg/ml), increased urine cortisol excretion (11,786 $\mu$g/day) Bilateral adrenal hyperplasia | Spironolactone, ketoconazole, chemotherapy with cisplatin/etoposide | Death at 12 months after diagnosis | (26) |
| 2016 | Balestrieri *et al* | Small cell carcinoma of the prostate | Locally advanced | Mental confusion, muscle weakness, hypertension, diabetes, moon facies, thin arms and legs | Hypokalemia (2.3 mEq/l) | Elevated plasma cortisol levels (1,098 nmol/l), elevated plasma ACTH levels (155.4 pg/ml), no suppression after high-dose DMZ, normal pituitary MRI, positive tumor staining for ACTH, bilateral adrenal hyperplasia | Ketoconazole 400 mg bid, SC Octreotide 0.1 mg tid, intravenous potassium, spironolactone, chemotherapy with epirubicin and carboplatin | Death at 3 months | (47) |

Table II. Continued.

| Year | Authors | Histology of prostate cancer | Disease extent | Clinical manifestations | Laboratory findings | Diagnostic criteria | Treatment | Clinical outcome | (Refs.) |
|---|---|---|---|---|---|---|---|---|---|
| 2017 | Elston *et al* | Mixed small-cell neuroendocrine carcinoma and adenocarcinoma of the prostate | Bone, lung, lymph node metastases | Generalised edema, hypertension, weight gain, proximal muscle weakness, labile mood, insomnia, multiple petechiae on the chest, thin skin, no other Cushing's signs | Hypokalaemic alkalosis (2.3 mEq/l), hyperglycemia | Elevated plasma cortisol levels (>1,655 nmol/l), elevated plasma ACTH levels (19.6 pg/ml), increased urine cortisol excretion (36,315 nmol/day), no suppression after low and high-dose DMZ, normal pituitary MRI, Weak positive tumor staining for ACTH | Ketoconazole 1.2 g daily, metyrapone 6 g daily, spironolactone, potassium supplements, chemotherapy with carboplatin and etoposide | Death at 9 months after diagnosis | (27) |
| 2018 | Kleinig *et al* | Small cell neuroendocrine carcinoma of the prostate | Lung, liver, adrenal metastases | Fatigue/proximal muscle weakness, depression, back pain, anorexia, weight loss, hypertension | Hypokalemic alkalosis, hyperglycemia | Elevated plasma cortisol levels (7,220 nmol/l) No suppression after low-dose DMZ, increased urine cortisol excretion (14,088 nmol/day), elevated plasma ACTH levels (23.7 pg/ml) | Not reported | Death at 9 weeks from sepsis | (29) |
| 2019 | Murphy *et al* | Neuroendocrine prostate carcinoma | Bone, retroperitoneal, inguinal and pelvic lymph node metastases | Polydipsia, polyuria, lower extremity edema | Hyperglycemia (508 mg/dl), hypokaliemia (3.1 mEq/l) | Elevated plasma cortisol levels (2,541 nmol/l), elevated plasma ACTH levels (1,250 pg/ml), increased urine cortisol excretion (3,002 $\mu$g/day), normal pituitary MRI, no suppression after low and high-dose DMZ | Ketoconazole | Death at 1 month after diagnosis | (28) |
| 2019 | Klomjit *et al* | Small cell neuroendocrine carcinoma of the prostate | Pelvic lymph node metastases | Resistant hypertension, lower extremity edema, easy bruising, generalized weakness, no Cushing's features | Hypokalemic alkalosis (2.8 mEq/l) | Elevated plasma ACTH levels (147 pg/ml), increased urine cortisol excretion, no suppression after low-dose DMZ, normal pituitary MRI | Bilateral adrenalectomy | Death at 1 month after diagnosis | (30) |

Table II. Continued.

| Year | Authors | Histology of prostate cancer | Disease extent | Clinical manifestations | Laboratory findings | Diagnostic criteria | Treatment | Clinical outcome | (Refs.) |
|---|---|---|---|---|---|---|---|---|---|
| 2019 | Soundarrajan *et al* | Small cell carcinoma of the prostate | Liver and bone metastases | Lower extremity weakness, Cushing's signs (diffuse ecchymoses, central obesity with pale abdominal stretch marks) | Hypokalemic alkalosis (2.9 mEq/l), hyperglycemia | Elevated plasma ACTH levels (241 pg/ml), increased urine cortisol excretion (5,760 $\mu$g/day), normal pituitary MRI, positive tumor staining for ACTH, low serum calcitonin level, Elevated carcinoembryonic antigen level | Ketoconazole 200 mg twice daily, metyrapone 300 mg daily, mifepristone, 300 mg daily and spironolactone 300 mg, chemotherapy with carboplatin and etoposide | Admitted to hospice facility | (31) |
| 2019 | Takeuchi *et al* | Small cell carcinoma of the prostate with component of prostatic adenocarcinoma | Liver, bone and lymph node metastases | Weight/appetite loss, lower extremity edema, hyperpigmentation, thinning of the skin, limb muscle weakness | Hypokalemia (K 1.8 mEq/l), hyperglycemia, leukocytosis (16,300/$\mu$l). | Elevated plasma ACTH levels (225.5 pg/ml), elevated plasma cortisol levels (1,509 nmol/l), increased urine cortisol excretion (544.4 $\mu$g/day), no suppression after low-dose and high-dose DMZ, negative tumor staining for ACTH | Metyrapone, potassium supplements | Death at four days after transfer to palliative hospital | (50) |
| 2020 | Schepers *et al* | Large cell neuroendocrine carcinoma of the prostate | Paraortic lymph nodes and bone metastases | Peripheral edema, hypertension, muscle weakness, emotional lability | Hypokalemic alkalosis (2.7 mEq/l) | Elevated cortisol in saliva (340 nmol/l), increased urine cortisol excretion (16,000 nmol/day), elevated plasma ACTH levels (11 pg/ml), elevated plasma cortisol levels (1.750 nmol/l), no suppression after low-dose DMZ, normal pituitary MRI, bilateral adrenal hyperplasia, negative tumor staining for ACTH | Spironolactone, Ketoconazole 400 mg bid | Death within weeks after diagnosis | (32) |

Table II. Continued.

| Year | Authors | Histology of prostate cancer | Disease extent | Clinical manifestations | Laboratory findings | Diagnostic criteria | Treatment | Clinical outcome | (Refs.) |
|---|---|---|---|---|---|---|---|---|---|
| 2020 | Atmaca *et al* | Small cell carcinoma of the prostate | No metastasis | Hypokalemia, heart failure | Hypokalemia (2.37 mEq/l) | Elevated plasma cortisol levels (1,650 nmol/l), increased urine cortisol excretion (3,218.5 $\mu$g/dl), elevated plasma ACTH levels (416 pg/ml), no suppression after high-dose DMZ, normal pituitary MRI, positive tumor staining for ACTH | Ketoconazole 600 mg/day | Death at 1 month after diagnosis | (51) |
| 2021 | Fernandes *et al* | Small cell neuroendocrine carcinoma of the prostate | Liver, bone, lymph node metastases | Pelvic pain, rectal tenesmus, fatigue, uncontrolled hypertension, no Cushing's signs | Hypokalemic alkalosis (2.1 mEq/l) | Elevated plasma cortisol levels (160 nmol/l), increased urine cortisol excretion (12,333 $\mu$g/day), elevated plasma ACTH levels (253 pg/ml), no suppression after high-dose DMZ, normal pituitary MRI | Metyrapone 250 mg daily, potassium supplements | Death within few days | (34) |
| 2021 | Riaza Montes *et al* | Small cell carcinoma of the prostate | Pelvic lymph node metastases | Urinary retention, arterial hypertension, lower extremity edema | Hypokalemic alkalosis (2.4 mEq/l) | Elevated plasma cortisol levels (7,945 nmol/l), elevated plasma ACTH levels (479 pg/ml) | Ketoconazole, intravenous etomidate | Death at 21 days after admission (~1 month after diagnosis) | (33) |
| 2021 | Bloomer *et al* | Not reported (possibly prostate adenocarcinoma) | Metastatic | Muscle weakness, hypertension | Hypokalemia (~2.5 mEq/l) | Elevated plasma ACTH levels (>1,000 pg/ml), increased urine cortisol excretion (10,000 $\mu$g/day) | Metyrapone, chemotherapy with cisplatin/irinotecan | Not reported | (52) |

Table II. Continued.

| Year | Authors | Histology of prostate cancer | Disease extent | Clinical manifestations | Laboratory findings | Diagnostic criteria | Treatment | Clinical outcome | (Refs.) |
|---|---|---|---|---|---|---|---|---|---|
| 2022 | Zeng Khoo | Prostate adenocarcinoma | Liver, lymph node and bone metastases | Lower extremity edema, proximal muscle weakness, no Cushing's signs | Hypokalemic alkalosis (2.5 mEq/l) | Elevated plasma cortisol levels (1,229nmol/l), normal plasma ACTH levels (57.4pg/ml), increased urine cortisol excretion (20,475 nmol/day), no suppression after low and high-dose DMZ, normal pituitary MRI, positive tumor staining for ACTH, suppressed plasma renin/aldosterone activity, central hypothyroidism | Ketoconazole 400 mg bid, intravenous octreotide 100 mcg tid, Spironolactone 25 mg once daily, chemotherapy with platinum and etoposide | Death at 3 months after diagnosis | (35) |
| 2022 | Hassan *et al* | Prostate adenocarcinoma with neuroendocrine differentiation | Liver and bone metastases | Cushingoid features | Not available | Not available | Not available | Not available | (36) |

EEG, electroencephalogram; ACTH, adrenocorticotropic hormone; DMZ, dexamethasone; UTI, urinary tract infection; CRH, corticotropin-releasing hormone; TSH, thyroid stimulating hormone; ICU, intensive care unit.

like enzalutamide or abiraterone resulted in an increase of neuroendocrine prostate carcinomas from 6.3 to 13.3% after 2012 (3). Paraneoplastic syndromes associated with prostate cancer are rare. However, when they occur, they constitute the initial clinical manifestation of prostate cancer in up to 70% of cases and a sign of progression to castration-resistance in 20% of cases (62). Paraneoplastic syndromes often related to prostate cancer include endocrine syndromes (inappropriate antidiuretic hormone secretion, CS, hypercalcemia) as well as hematological disorders and neurological syndromes (62).

Pure carcinoids of the prostate are rare, while mixed carcinomas of prostate adenocarcinoma and carcinoid are more frequent. Small cell prostate carcinoma accounts for ~0.5-2% of prostate carcinoma cases (63). It is thought that small cell carcinoma of the prostate has a common origin with prostate adenocarcinoma as ~40-50% of men with small cell carcinoma of the prostate have a prior or concurrent history of prostatic adenocarcinoma (63). Based on the aforementioned information, ectopic ACTH production mainly emerges from the neuroendocrine transformation of the preexisting prostate adenocarcinoma. This raises the question of performing re-biopsy to histologically confirm the diagnosis. However, the imminent need to initiate treatment early may postpone the performance of a confirmatory re-biopsy. As known, the state of extreme hypercortisolism creates a fertile environment for infections. Therefore, the prompt initiation of targeted treatment with metyrapone or ketoconazole and potassium supplements to target hypercortisolism in combination with chemotherapy for the underlying malignancy may be deemed more urgent. This case was thoroughly discussed in multidisciplinary medical meetings focusing on the best therapeutic approach. In accordance with the present case, re-biopsy was not performed in most of the cases identified in the existing literature mainly due to the fast deterioration of the patient and the subsequent lack of time. Indeed, most patients die from sepsis secondary to uncontrolled CS. This is the reason that suppression of the hypercortisolism is urgent and should not be delayed to identify the source of CS.

In conclusion, the ectopic CS can be a clinical manifestation of prostate cancer. It requires timely diagnosis and aggressive treatment to avoid life-threatening complications of hypercortisolemia. The present case highlighted the necessity of multiple laboratory and imaging examinations required for the definitive diagnosis of CS, with the ultimate goal of initiating targeted therapy promptly.

**Acknowledgements**

Not applicable.

**Funding**

No funding was received.

**Availability of data and materials**

The data generated in the present study may be found in the PUBMED database at the following URL: https://pubmed.ncbi.nlm.nih.gov.

**Authors' contributions**

FZ, MAD and SAP conceptualized the study. AA, KG and KS conducted the investigation. FZ, MAD and SAP supervised the study. AA, KG, SA and KS were involved in drafting the original manuscript and revised it critically for important intellectual content. SA also made a substantial contribution to the analysis and interpretation of the data, gave final approval for the manuscript to be published and agreed to be accountable for all aspects of the work. All authors read and approved the final manuscript. KG and AA confirm the authenticity of all the raw data.

**Ethics approval and consent to participate**

Not applicable.

**Patient consent for publication**

The patient provided written informed consent for this case study to be published.

**Competing interests**

MAD has received honoraria from participation in advisory boards from Amgen, Bristol-Myers-Squibb, Celgene, Janssen, Takeda. FZ has received honoraria for lectures and has served in an advisory role for Astra-Zeneca, Daiichi, Eli-Lilly, Merck, Novartis, Pfizer, and Roche. The remaining authors declare no competing interests.

**References**

1. Bray F, Ferlay J, Soerjomataram I, Siegel RL, Torre LA and Jemal A: Global cancer statistics 2018: GLOBOCAN estimates of incidence and mortality worldwide for 36 cancers in 185 countries. CA Cancer J Clin 68: 394-424, 2018.
2. Bergengren O, Pekala KR, Matsoukas K, Fainberg J, Mungovan SF, Bratt O, Bray F, Brawley O, Luckenbaugh AN, Mucci L, *et al*: 2022 update on prostate cancer epidemiology and risk Factors-A systematic review. Eur Urol 84: 191-206, 2023.
3. Merkens L, Sailer V, Lessel D, Janzen E, Greimeier S, Kirfel J, Perner S, Pantel K, Werner S and von Amsberg G: Aggressive variants of prostate cancer: Underlying mechanisms of neuroendocrine transdifferentiation. J Exp Clin Cancer Res 41: 46, 2022.
4. Gupta K and Gupta S: Neuroendocrine differentiation in prostate cancer: Key epigenetic players. Transl Cancer Res 6 (Suppl 1): S104-S108, 2017.
5. Hu CD, Choo R and Huang J: Neuroendocrine differentiation in prostate cancer: A mechanism of radioresistance and treatment failure. Front Oncol 5: 90, 2015.
6. Ejaz S, Vassilopoulou-Sellin R, Busaidy NL, Hu MI, Waguespack SG, Jimenez C, Ying AK, Cabanillas M, Abbara M and Habra MA: Cushing's syndrome secondary to ectopic ACTH secretion: The University of Texas MD Anderson Cancer Center Experience. Cancer 117: 4381-4389, 2011.
7. Matzkin H and Braf Z: Paraneoplastic syndromes associated with prostatic carcinoma. J Urol 138: 1129-1133, 1987.
8. Dhom G: Unusual prostatic carcinomas. Pathol Res Pract 186: 28-36, 1990.
9. Yonaha M, Tanaka M, Kawano T, Sugiyama M, Nishikawa T and Sasano K: An autopsy case of ACTH producing prostate neoplasms with Cushing's syndrome. Nihon Naika Gakkai Zasshi 81: 2005-2006, 1992 (In Japanese).
10. Ciudin A, Huguet Perez J, Ribal Caparros MJ and Alcaraz Asensio A: Cushing syndrome and prostate cancer recurrence with undetectable prostate-specific antigen. Med Clin (Barc) 140: 430-431, 2013 (In Spanish).

11. Wenk RE, Bhagavan BS, Levy R, Miller D and Weisburger W: Ectopic ACTH, prostatic oat cell carcinoma, and marked hypernatremia. Cancer 40: 773-778, 1977.
12. Vuitch MF and Mendelsohn G: Relationship of ectopic ACTH production to tumor differentiation: A morphologic and immunohistochemical study of prostatic carcinoma with Cushing's syndrome. Cancer 47: 296-299, 1981.
13. Carey RM, Varma SK, Drake CR, Thorner MO, Kovacs K, Rivier J and Vale W: Ectopic secretion of corticotropin-releasing factor as a cause of Cushing's syndrome. A clinical, morphologic, and biochemical study. N Engl J Med 311: 13-20, 1984.
14. Fjellestad-Paulsen A, Abrahamsson PA, Bjartell A, Grino M, Grimelius L, Hedeland H and Falkmer S: Carcinoma of the prostate with Cushing's syndrome. A case report with histochemical and chemical demonstration of immunoreactive corticotropin-releasing hormone in plasma and tumoral tissue. Acta Endocrinol (Copenh) 119: 506-516, 1988.
15. Haukaas SA, Halvorsen OJ, Nygaard SJT and Paus E: Cushing's syndrome in prostate cancer. An aggressive course of prostatic malignancy. Urol Int 63: 126-129, 1999.
16. Rickman T, Garmany R, Doherty T, Benson D and Okusa MD: Hypokalemia, metabolic alkalosis, and hypertension: Cushing's syndrome in a patient with metastatic prostate adenocarcinoma. Am J Kidney Dis 37: 838-846, 2001.
17. Johnson TN and Canada TW: Etomidate use for Cushing's syndrome caused by an ectopic adrenocorticotropic hormone-producing tumor. Ann Pharmacother 41: 350-353, 2007.
18. Kataoka K, Akasaka Y, Nakajima K, Nagao K, Hara H, Miura K and Ishii N: Cushing syndrome associated with prostatic tumor adrenocorticotropic hormone (ACTH) expression after maximal androgen blockade therapy. Int J Urol 14: 436-439, 2007.
19. Nimalasena S, Freeman A and Harland S: Paraneoplastic Cushing's syndrome in prostate cancer: A difficult management problem. BJU Int 101: 424-427, 2008.
20. Alwani RA, Neggers SJ, van der Klift M, Baggen MG, van Leenders GJ, van Aken MO, van der Lely AJ, de Herder WW and Feelders RA: Cushing's syndrome due to ectopic ACTH production by (neuroendocrine) prostate carcinoma. Pituitary 12: 280-283, 2009.
21. Rajec J, Mego M, Sycova-Mila Z, Obertova J, Brozmanova K and Mardiak J: Paraneoplastic Cushing's syndrome as the first sign of progression of prostate cancer. Bratisl Lek Listy 109: 362-363, 2008.
22. Alshaikh OM, Al-Mahfouz AA, Al-Hindi H, Mahfouz AB and Alzahrani AS: Unusual cause of ectopic secretion of adrenocorticotropic hormone: Cushing syndrome attributable to small cell prostate cancer. Endocr Pract 16: 249-254, 2010.
23. Ramon I, Kleynen P, Valsamis J, Body JJ and Karmali R: Hypophosphatemia related to paraneoplastic Cushing syndrome in prostate cancer: Cure after bilateral adrenalectomy. Calcif Tissue Int 89: 442-445, 2011.
24. Rueda-Camino JA, Losada-Vila B, De Ancos-Aracil CL, Rodríguez-Lajusticia L, Tardío JC and Zapatero-Gaviria A: Small cell carcinoma of the prostate presenting with Cushing Syndrome. A narrative review of an uncommon condition. Ann Med 48: 293-299, 2016.
25. Shrosbree J, Pokorny A, Stone E, Epstein R, Mccormack A and Greenfield JR: Ectopic Cushing syndrome due to neuroendocrine prostatic cancer. Intern Med J 46: 630-632, 2016.
26. Ramalingam S, Eisenberg A, Foo WC, Freedman J, Armstrong AJ, Moss LG and Harrison MR: Treatment-related neuroendocrine prostate cancer resulting in Cushing's syndrome. Int J Urol 23: 1038-1041, 2016.
27. Elston MS, Crawford VB, Swarbrick M, Dray MS, Head M and Conaglen JV: Severe Cushing's syndrome due to small cell prostate carcinoma: A case and review of literature. Endocr Connect 6: R80-R86, 2017.
28. Murphy N, Shen J, Shih A, Liew A, Khalili H, Yaskiv O, Katona K, Lee A and Zhu XH: Paraneoplastic syndrome secondary to treatment emergent neuroendocrine tumor in metastatic Castration-resistant prostate cancer: A unique case. Clin Genitourin Cancer 17: e56-e60, 2019.
29. Kleinig P and Russell P: Lesson of the month 2: An unusual cause of depression in an older man: Cushing's syndrome resulting from metastatic small cell cancer of the prostate. Clin Med (Lond) 18: 432-434, 2018.
30. Klomjit N, Rowan DJ, Kattah AG, Bancos I and Taler SJ: New-Onset resistant hypertension in a newly diagnosed prostate cancer patient. Am J Hypertens 32: 1214-1217, 2019.
31. Soundarrajan M, Zelada H, Fischer JV and Kopp P: Ectopic adrenocorticotropic hormone syndrome due to metastatic prostate cancer with neuroendocrine differentiation. AACE Clin Case Reports 5: e192-e196, 2019.
32. Schepers LM, Kisters JMH, Wetzels C and Creemers GJ: Hypokalaemia and peripheral oedema in a Cushingoid patient with metastatic prostate cancer. Neth J Med 78: 401-403, 2020.
33. Riaza Montes M, Arredondo Calvo P and Gallego Sánch JA: Small cell metastatic prostate cancer with ectopic adrenocorticotropic hormone hypersecretion: A case report. Ann Palliat Med 10: 12911-12914, 2021.
34. Fernandes R, Dos Santos J, Reis F and Monteiro S: Cushing syndrome as a manifestation of neuroendocrine prostate cancer: A rare presentation within a rare tumor. Cureus 13: e18160, 2021.
35. Zeng W and Khoo J: Challenging case of ectopic ACTH secretion from prostate adenocarcinoma. Case Rep Endocrinol 2022: 3739957, 2022.
36. Hassan B, Yazbeck Y, Akiki V, Salti I and Tfayli A: ACTH-secreting metastatic prostate cancer with neuroendocrine differentiation. BMJ Case Rep 15: e247997, 2022.
37. Newmark SR, Dluhy RG and Bennett AH: Ectopic adrenocorticotropin syndrome with prostatic carcinoma. Urology 2: 666-668, 1973.
38. Webster GD Jr, Touchstone JC and Suzuki M: Adrenocortical hyperplasia occurring with metastatic carcinoma of the prostate: Report of a case exhibiting increased urinary aldosterone and glucocorticoid excretion. J Clin Endocrinol Metab 19: 967-979, 1959.
39. Lovern WJ, Fariss BL, Wettlaufer JN and Hane S: Ectopic ACTH production in disseminated prostatic adenocarcinoma. Urology 5: 817-820, 1975.
40. Slater D: Carcinoid tumour of the prostate associated with inappropriate ACTH secretion. Br J Urol 57: 591-592, 1985.
41. Molland EA: Prostatic adenocarcinoma with ectopic ACTH production. Br J Urol 50: 358-358, 1978.
42. Wise HM, Pohl AL, Gazzaniga A and Harrison JH: Hyperadrenocorticism associated with 'reactivated' prostatic carcinoma. Surgery 57: 655-664, 1965.
43. Ghali VS and Garcia RL: Prostatic adenocarcinoma with carcinoidal features producing adrenocorticotropic syndrome. Immunohistochemical study and review of the literature. Cancer 54: 1043-1048, 1984.
44. Hussein WI, Kowalyk S and Hoogwerf BJ: Ectopic adrenocorticotropic hormone syndrome caused by metastatic carcinoma of the prostate: Therapeutic response to ketoconazole. Endocr Pract 8: 381-384, 2002.
45. Statham BN, Pardoe TH and Mir MA: Response of ectopic prostatic ACTH production to metyrapone. Postgrad Med J 57: 467-468, 1981.
46. Hall TC: Symptomatic hypokalemic alkalosis in hyperadrenocorticism secondary to carcinoma of the prostate. Cancer 21: 190-192, 1968.
47. Balestrieri A, Magnani E and Nuzzo F: Unusual Cushing's syndrome and hypercalcitoninaemia due to a small cell prostate carcinoma. Case Rep Endocrinol 2016: 6308058, 2016.
48. Asa SL, Kovacs K, Vale W, Petrusz P and Vecsei P: Immunohistologic localization of corticotrophin-releasing hormone in human tumors. Am J Clin Pathol 87: 327-333, 1987.
49. Lemoinne S, Baudel JL, Galbois A, Offenstadt G and Maury E: Suddzith Cushing's Syndrome. Open Endocrinol J 4: 1-2, 2014.
50. Takeuchi M, Sato J, Manaka K, Tanaka M, Matsui H, Sato Y, Kume H, Fukayama M, Iiri T, Nangaku M and Makita N: Molecular analysis and literature-based hypothesis of an immunonegative prostate small cell carcinoma causing ectopic ACTH syndrome. Endocr J 66: 547-554, 2019.
51. Atmaca M, Temiz C, Sebile DH, Dökmetaş M and Kiliçli F: A rare cause of ectopic cushing syndrome: Prostate cancer. Endocr Abstr 70: EP348, 2020.
52. Bloomer Z, Teague J and Vietor N: Ectopic Cushing's From metastatic prostate cancer. J Endocr Soc 5: A757, 2021.
53. Nadal R, Schweizer M, Kryvenko ON, Epstein JI and Eisenberger MA: Small cell carcinoma of the prostate. Nat Rev Urol 1: 213-219, 2014.
54. Rojas-Corona RR, Chen L and Mahadevia PS: Prostatic carcinoma with endocrine features. A report of a neoplasm containing multiple immunoreactive hormonal substances. Am J Clin Pathol 88: 759-762, 1987.
55. Abrahamsson PA, Wadström LB, Alumets J, Falkmer S and Grimelius L: Peptide-hormone- and serotonin-immunoreactive tumour cells in carcinoma of the prostate. Pathol Res Pract 182: 298-307, 1987.

56. Jarett L, Lacy PE and Kipnis DM: Characterization by immunofluorescence of an Acth-like substance in nonpituitary tumors from patients with hyperadrenocorticism. J Clin Endocrinol Metab 24: 543-549, 1964.
57. Turbat-Herrera EA, Herrera GA, Gore I, Lott RL, Grizzle WE and Bonnin JM: Neuroendocrine differentiation in prostatic carcinomas. A retrospective autopsy study. Arch Pathol Lab Med 112: 1100-1105, 1988.
58. Capella C, Usellini L, Buffa R, Frigerio B and Solcia E: The endocrine component of prostatic carcinomas, mixed adenocarcinoma-carcinoid tumours and non-tumour prostate. Histochemical and ultrastructural identification of the endocrine cells. Histopathology 5: 175-192, 1981.
59. Shahani S, Nudelman RJ, Nalini R, Kim HS and Samson SL: Ectopic corticotropin-releasing hormone (CRH) syndrome from metastatic small cell carcinoma: A case report and review of the literature. Diagn Pathol 5: 56, 2010.
60. di Sant'Agnese PA: Neuroendocrine differentiation in carcinoma of the prostate diagnostic, prognostic, and therapeutic implications. Cancer 70 (1 Suppl): S254-S268, 1992.
61. Parimi V, Goyal R, Poropatich K and Yang XJ: Neuroendocrine differentiation of prostate cancer: A review. Am J Clin Exp Urol 2: 273-285, 2014.
62. Hong MK, Kong J, Namdarian B, Longano A, Grummet J, Hovens CM, Costello AJ and Corcoran NM: Paraneoplastic syndromes in prostate cancer. Nat Rev Urol 7: 681-692, 2010.
63. Nadal R, Schweizer M, Kryvenko ON, Epstein JI and Eisenberger MA: Small cell carcinoma of the prostate. Nat Rev Urol 11: 213-219, 2014.