SPANDIDOS PUBLICATIONS

ONCOLOGY LETTERS 28: 448, 2024

Renal cell carcinoma preceded by a rheumatoid-like paraneoplastic syndrome: A case report

YUSUKE YOSHIMURA[1], TATSUYA SUWABE[1], KATSUYUKI MIKI[1], TAKAYOSHI YOKOYAMA[1], KEI KONO[2], KEIICHI KINOWAKI[2], IKUMA KATO[3], YOJI NAGASHIMA[4], ASAMI NISHIKORI[5], YASUHARU SATO[5], SHIGEKAZU KURIHARA[1], YUKI OBA[1], HIROKI MIZUNO[1], AKINARI SEKINE[1], MASAYUKI YAMANOUCHI[1], MANABU KAMIYAMA[6], YASUO ISHII[1], YUKI NAKAMURA[1], YOSHIFUMI UBARA[1] and NAOKI SAWA[1]

[1]Nephrology Center, Toranomon Hospital Kajigaya, Kawasaki, Kanagawa 213-8587; [2]Department of Pathology, Toranomon Hospital, Tokyo 105-8470; [3]Department of Molecular Pathology, Yokohama City University Graduate School of Medicine, Yokohama, Kanagawa 236-0004; [4]Department of Surgical Pathology, Tokyo Women's Medical University, Tokyo 162-8666; [5]Department of Molecular Hematopathology, Okayama University Graduate School of Health Sciences, Okayama 700-8530; [6]Department of Urology, Toranomon Hospital Kajigaya, Kawasaki, Kanagawa 213-8587, Japan

Received February 1, 2024; Accepted July 2, 2024

DOI: 10.3892/ol.2024.14581

Abstract. A man with polycystic kidney disease and a history of renal transplantation at the age of 55 years developed seronegative rheumatoid arthritis (RA) at the age of 68 years. Treatment with a biological derivative led to remission; however, the patient relapsed 2 years later. After being switched to baricitinib, the patient again achieved remission. After 2 years, when the patient was aged 72 years, RA recurred, and the right native kidney became enlarged due to the presence of a large tumor. Surgical nephrectomy was performed, and the tumor was classified as renal cell carcinoma (RCC), not otherwise specified. The cancer tissue comprised sarcomatoid and rhabdoid cells with marked neutrophil infiltration, and the tumor cells were positive for interleukin-6. The patient, aged 73 years, experienced a resolution of joint pain following surgical intervention; however, they died because of systemic metastases ~10 weeks post-operation. Based on the clinical course, the RA-like lesions and subsequent RCC were considered to represent a paraneoplastic syndrome.

Introduction

Renal cell carcinoma (RCC) is occasionally accompanied by paraneoplastic syndromes, characterized by the presence of extrarenal lesions and symptoms that typically resolve following tumor resection. Common manifestations of these paraneoplastic syndromes include fever and elevated levels of C-reactive protein (CRP) (1). Arthritis associated with malignancy may manifest as paraneoplastic polyarthritis, remitting seronegative symmetrical synovitis with pitting edema, or polymyalgia rheumatica; all these conditions are characterized by a lack of efficacy of steroids and symptomatic improvement after successful treatment of the malignancy, but detailed information on these conditions is still needed (2).

Here, we report the case of a man who presented with seronegative but typical rheumatoid arthritis (RA; i.e., RA-like arthritis). The patient had been successfully treated with a biological derivative but gradually developed treatment resistance and was subsequently diagnosed with RCC. This case is of interest because, to our knowledge, only a few similar reports have been published (3). The aim of this study is to highlight the potential association between RCC-related paraneoplastic polyarthritis and IL-6 production by RCC.

Case report

Case description. We report the case of a 73-year-old man who died of systemic metastasis of RCC, not otherwise specified, with treatment-resistant fever and polyarthralgia. The patient was diagnosed with autosomal dominant polycystic kidney disease at 34 years of age after developing lateral abdominal pain due to a ureteral stone. At 47 years of age, he started continuous ambulatory peritoneal dialysis, which was changed to hemodialysis 3 times a week at 52 years of age. At 54 years of age, he underwent renal artery embolization according to a previously published method (4) to reduce the size of an enlarged kidney. At age 55 years, he received a kidney transplant in China (no donor information is available). Thereafter, the size of the left kidney decreased, but the right kidney did not decrease much in size and showed cyst-like dilatation of the renal pelvis due to the presence of a ureteral stone; however, the patient's symptoms improved after 3 drainage procedures, and no further treatment was needed. At the age of 68 years, the patient developed fever, polyarthritis in the joints

Correspondence to: Mr. Yusuke Yoshimura, Nephrology Center, Toranomon Hospital Kajigaya, 1-3-1 Kajigaya, Takatsu, Kawasaki, Kanagawa, 213-8587, Japan
E-mail: yoshimura@toranomon.gr.jp

Key words: renal cell carcinoma, paraneoplastic syndrome

of both hands and feet, and elevated CRP (2.4 mg/dl). Tests for rheumatoid factor and anti-cyclic citrullinated peptide antibody were negative, and he was diagnosed with seronegative RA and started on adalimumab. Adalimumab was effective, and the patient's arthralgia and fever subsided; therefore, the treatment was continued. At the age of 70 years, the arthralgia worsened again, and the patient was switched to baricitinib. At 72 years of age, the cyst-like lesions in the right kidney again increased in size, and drainage was performed (Figs. 1 and 2). Cytological analysis of the fluid content did not reveal any malignancy. Nevertheless, the patient was admitted for the resection of the enlarged right kidney.

Immediately after transplantation, treatment commenced with prednisolone (5 mg), tacrolimus (3 mg), and mycophenolate mofetil (1,500 mg). After 3 years, prednisolone was discontinued due to a favorable response to treatment, while the tacrolimus dose was increased to 4 mg, and the mycophenolate mofetil dose was reduced to 750 mg. This treatment regimen was then maintained. Over the 17 years following renal transplantation, the peripheral blood lymphocyte count remained within the range of 1,020-1,500/4,800-5,600/μl. However, three months prior to the current admission, there was a notable decrease in the lymphocyte count to 812-913/5,800-8,300/μl.

On admission, the patient was 168 cm tall and weighed 54 kg. His blood pressure was 117/74 mmHg (with no administration of antihypertensive medication), and his body temperature was 37.6˚C. No heart murmur was heard, and no edema was observed. The laboratory findings were as follows: Red blood cell count, 470x10^4/μl (reticulocyte, 1.22%); hemoglobin, 12.0 g/dl; white blood cell count, 8,300/μl (segment, 83%; lymphocyte, 10.3%); total protein, 6.3 g/dl; albumin, 2.8 g/dl; serum urea nitrogen, 14 mg/dl; serum creatinine, 0.86 mg/dl; HbA1c, 6.0%; erythrocyte sedimentation rate, 60 mm/h; CRP, 3.05 mg/dl; total complement activity (assessed as CH50), 44 U/ml (reference range, >30 U/ml); complement 3, 104 mg/dl (reference range, 86-160 mg/dl); complement 4, 32 mg/dl (reference range, 17-45 mg/dl); immunoglobulin (Ig) G, 1,189 mg/dl (reference range, 861-1,747 mg/dl); IgA, 308 mg/dl (reference range, 110-410 mg/dl); and IgM, 76 mg/dl (reference range, 52-270 mg/dl). Tests for rheumatoid factor and anti-cyclic citrullinated peptide antibody were negative, and immunological tests were negative for anti-nuclear antibody, anti-neutrophil cytoplasmic antibody (MPO/PR3), and other major autoantibodies. The erythropoietin level was 32.9 mIU/ml (normal; 4.2-23.7 mIU/ml).

Pathological findings in the resected kidney. The resected right native kidney measured 22.5x16.8x11.7 cm in size and weighed 2,300 g. Most of the renal parenchyma was occupied by an invasive tumor measuring 15.9x7.6 cm in diameter. The tumor extended into the renal vein to form a tumor embolus. The cut surface of the tumor was massively necrotic and dark brown in color (Fig. 3A).

Histologically, there was infiltrative proliferation of poorly connected, highly pleomorphic tumor cells with marked necrosis. The cell nuclei were large and irregular, ranging from dark-toned nuclei to nuclei with intranuclear pseudoinclusions. The tumor cells were large, with ubiquitous nuclei and abundant acidophilic cytoplasm. These findings corresponded to a rhabdoid change, a term used because the cells resemble

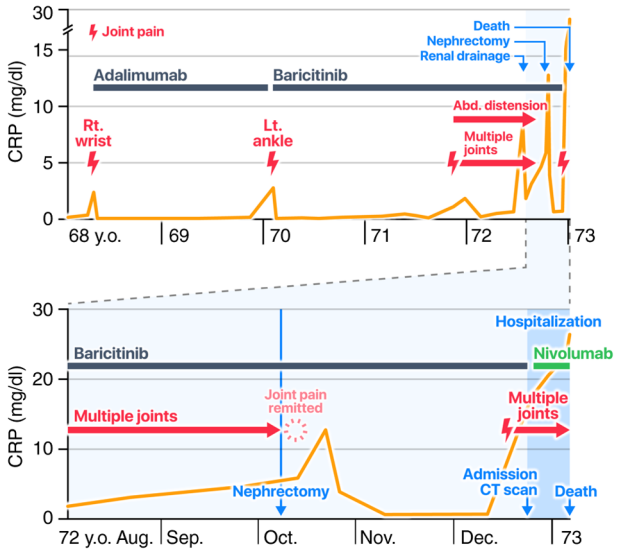

Figure 1. Clinical course. Abd., abdominal; Aug., August; CRP, C-reactive protein; CT, computed tomography; Dec., December; Lt., left; Nov., November; Oct., October; Rt., right; Sep., September; y.o., years old.

those found during rhabdogenesis. Neutrophils were observed inside the tumor cells, a finding referred to as emperipolesis (Fig. 3B). A neutrophilic infiltrate was observed around the tumor cells (Fig. 3C). No components were suggestive of an underlying histological type of RCC.

Immunohistochemically, the tumor cells were focally positive for cytokeratin 7, an α-methylacyl-CoA racemase; positive for cytokeratin AE1/AE3, cathepsin K, transcription factor E3 (TFE3), PAX8, and fumarate hydratase; and negative for carbonic anhydrase 9, anaplastic lymphoma kinase, and S-(2-succino)-cysteine. Furthermore, the tumor cells were weakly positive for IL-6 (Fig. 3D). Although TFE3-rearranged RCC was suspected, break-apart fluorescent *in situ* hybridization did not reveal a rearrangement of the *TFE3* gene. Based on these findings, the tumor was classified as RCC, not otherwise specified.

Clinical course. The patient's fever and arthralgia temporarily remitted after the operation. However, 2 months later, they returned, and systemic metastases of RCC developed, along with increasing pleural effusions. The CRP level was 6.17 mg/dl, the white blood cell count was 22,800/μl (segment, 86%), and the serum IL-6 level was 83.9 pg/ml (normal value, <7.0). Treatment with nivolumab was initiated but had little effect, and the patient died 2 weeks later (Fig. 1).

Discussion

We encountered a patient who developed seronegative RA 13 years after renal transplantation, followed by RCC, not otherwise specified, 5 years later. At the same time, as the RCC progressed, the CRP level increased, and the arthralgia worsened markedly. Furthermore, neutrophil infiltration and positive findings for IL-6 were also observed in the removed native RCC tissue, confirming the coexistence of IL-6-related rheumatoid-like symptoms and RCC. We therefore reviewed previous reports on renal carcinoma and associated paraneoplastic syndrome.

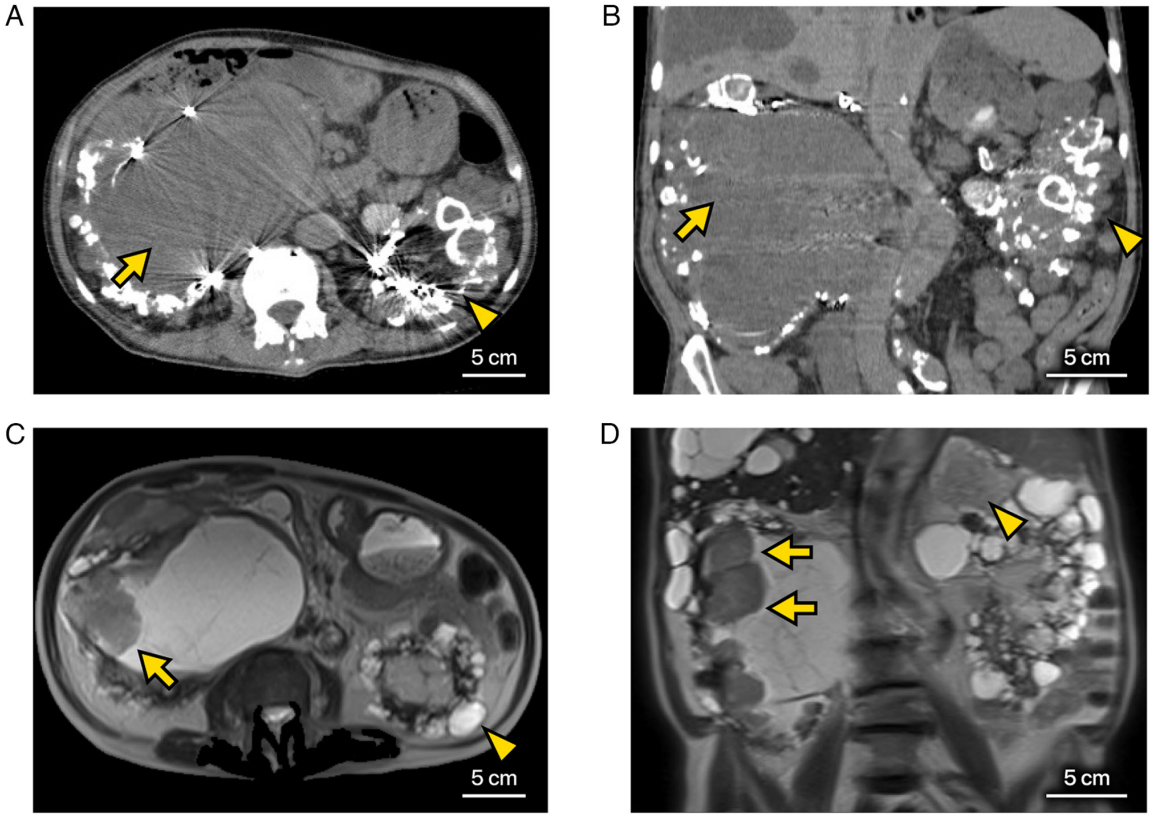

Figure 2. Imaging findings. (A) Transverse computed tomography image and (B) coronal computed tomography image of the right kidney (arrow) and left kidney (arrowhead). Swelling of the right kidney is seen (arrow). (C) Transverse magnetic resonance image and (D) coronalmagnetic resonance image (both T2-weighted) showing the tumor (arrow) and cyst (arrowhead).

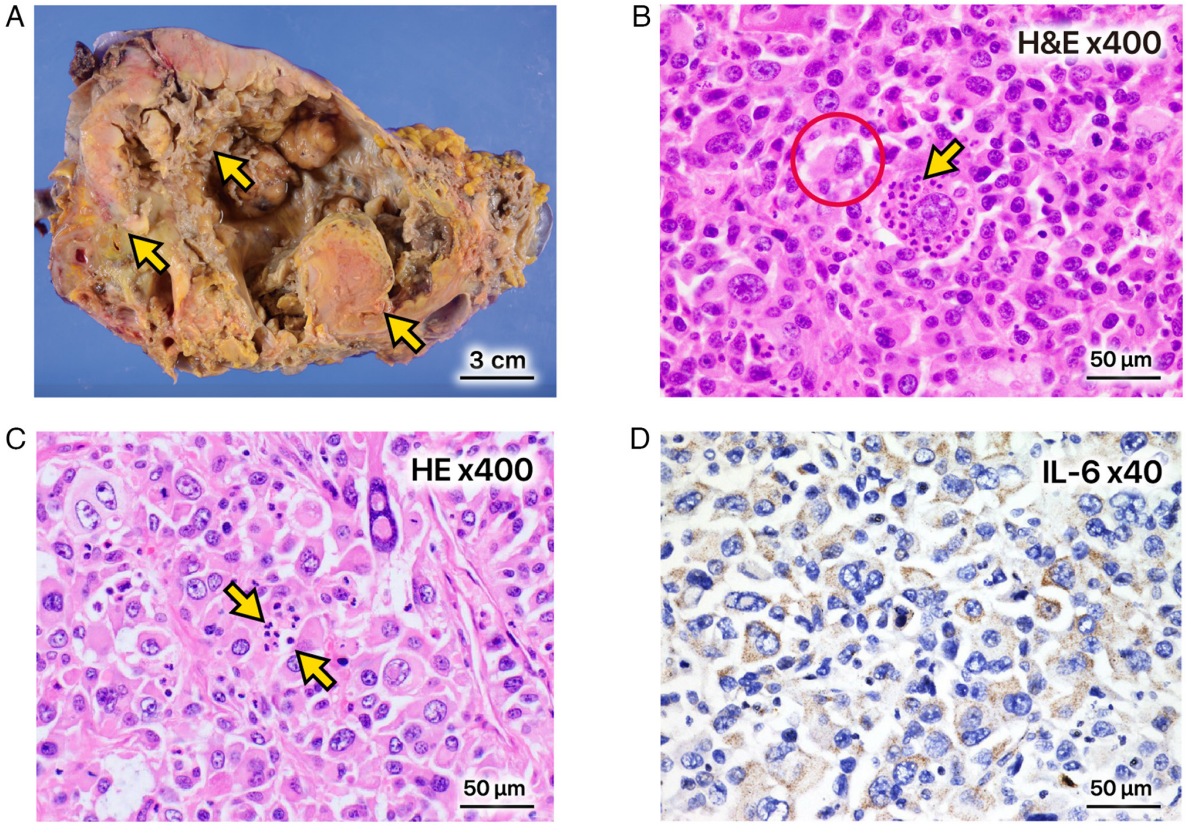

Figure 3. Pathological findings in the resected kidney. (A) Split section of the right kidney showing the tumor (arrow). (B) Large tumor cell (circle) with ubiquitous nuclei and abundant acidophilic cytoplasm and neutrophil-engaged tumor cells (arrow) (H&E stain; original magnification, x400). (C) Neutrophilic infiltration around the tumor cells (arrow). (D) Tumor cells are positive for IL-6 (original magnification, x40). H&E, hematoxylin and eosin; IL-6, interleukin-6.

The involvement of IL-6 in the paraneoplastic syndrome of RCC has been demonstrated by IL-6 staining in RCC tissue and elevated serum IL-6 (5,6). However, in a case report, IL-6 was not detected in RCC tissue, and a relationship between IL-6 and the paraneoplastic syndrome of RCC was not proven (7). The hypothesis that IL-6 is involved in the pathogenesis of RA is supported by the fact that IL-6 and tumor necrosis factor preparations suppress the progression of RA (8). In past reports, various histological types of renal carcinoma were suggested to be associated with paraneoplastic syndrome, and no association was demonstrated for a specific histological type (9,10); however, our case indicates that RCC, not otherwise specified, is one type of paraneoplastic syndrome.

The association of immunodeficiency and the appearance of tumors has been shown for other tumors, most often in HIV (11) For immunocompromised states and malignant tumors, the report by Grulich *et al* (12) is useful. They report that the most important risk factor for malignancy is an immunocompromised state, such as that seen in HIV (13).

Immunosuppressive drugs used in transplantation, including mycophenolate mofetil, have been shown to reduce T lymphocyte counts, resulting in immunosuppression and potentially contributing to tumor development (14). This finding suggests that the rapid progression of RCC may be linked to the excessive effect of immunosuppression induced by immunosuppressive drugs. In our patient, a rapid decrease in lymphocyte count was observed three months before the current hospitalization. It has been reported that, despite long-term treatment with standard immunomodulatory drugs in patients with autoimmune diseases such as systemic lupus erythematosus and RA, an inflammatory state may persist, as evidenced by elevated MCP-1 levels. This persistent inflammatory state could contribute to tumor development. Considering the onset and clinical course of lymphopenia, we believe that the decrease in lymphocyte count in this patient is associated with RCC, rather than being caused by lymphopenia as a hematologic disorder or immunodeficiency.

Numerous reports have documented the occurrence of renal carcinomas in the native kidneys of renal transplant recipients. Typically, these tumors manifest as low-stage, low-grade lesions with a favorable prognosis (15). However, there have also been reports of renal carcinomas with a poor prognosis (16,17). Furthermore, in addition to renal carcinoma, transplant lymphoproliferative disorders have been reported (18). Nevertheless, our case represents the first documented instance of renal carcinoma following renal transplantation accompanied by a related rheumatoid-like paraneoplastic syndrome.

This study has several limitations. A bone marrow examination was not conducted because the patient rapidly deteriorated to a fatal state within a few days of hospitalization. Furthermore, although the erythropoietin level on admission is shown above, it was not measured repeatedly since erythropoietin evaluation is not a routine method for assessing kidney damage in Japan.

In conclusion, we encountered a case of seronegative RA after renal transplantation, followed by later development of RCC. Positive staining for IL-6 and neutrophil infiltration were also observed in the RCC tissue, suggesting a paraneoplastic syndrome with RCC and RA-like symptoms.

Acknowledgements

Not applicable.

Funding

No funding was received.

Availability of data and materials

The data generated in the present study are included in the figures and/or tables of this article.

Authors' contributions

YY wrote the manuscript, submitted the manuscript, and conducted the background research. YY, TS, KM, TY, MK, YI, YuN and NS were the attending doctors of the patient, and contributed to the collection, analysis and interpretation of patient data. YY, TS, SK, YO, HM, AS, MY, YU and NS played essential roles in interpreting the pathogenesis of the current case and determining the treatment strategy. KKo, KKi, IK, YoN, AN, and YS interpreted the kidney biopsy specimens as specialists in pathology. YY, TS and YU confirm the authenticity of all the raw data. YU and NS supervised manuscript writing. All authors read and approved the final version of the manuscript.

Ethics approval and consent to participate

Not applicable.

Patient consent for publication

The patient provided written informed consent for the publication of this article.

Competing interests

The authors declare that they have no competing interests.

References

1. Palapattu GS, Kristo B and Rajfer J: Paraneoplastic syndromes in urologic malignancy: The many faces of renal cell carcinoma. Rev Urol 4: 163-170, 2002.
2. Azar L and Khasnis A: Paraneoplastic rheumatologic syndromes. Curr Opin Rheumatol 25: 44-49, 2013.
3. Sidhom OA, Basalaev M and Sigal LH: Renal cell carcinoma presenting as polymyalgia rheumatica. Resolution after nephrectomy. Arch Intern Med 153: 2043-2045, 1993.
4. Ubara Y: New Therapeutic option for autosomal dominant polycystic kidney disease patients with enlarged kidney and liver. Ther Apher Dial 10: 333-341, 2006.
5. Okada A, Higashihara T, Kusano T, Takemura K, Saigusa H, Maruno S, Matsumura M, Suzuki T, Shimizu A and Takano H: IL-6-producing renal cell carcinoma causing renal and endocrine paraneoplastic syndromes. Intern Med 58: 1953-1960, 2019.
6. Blay JY, Rossi JF, Wijdenes J, Menetrier-Caux C, Schemann S, Négrier S, Philip T and Favrot M: Role of interleukin-6 in the paraneoplastic inflammatory syndrome associated with renal-cell carcinoma. Int J Cancer 72: 424-430, 1997.
7. Yoshimura Y, Suwabe T, Ikuma D, Oba Y, Yamanouchi M, Sekine A, Mizuno H, Hasegawa E, Hoshino J, Kono K, *et al*: Renal cell carcinoma-associated diabetes mellitus due to paraneoplastic syndrome in maintenance hemodialysis: A case report. Kidney Med 4: 100477, 2022.

8. Ogata A, Kato Y, Higa S and Yoshizaki K: IL-6 inhibitor for the treatment of rheumatoid arthritis: A comprehensive review. Mod Rheumatol 29: 258-267, 2019.
9. Noda-Narita S, Kanzaki M, Uesaka Y, Suwabe T, Kinowaki K, Marui Y, Hoshino J, Sawa N and Ubara Y: Paraneoplastic polymyositis due to renal cell carcinoma in a patient with autosomal dominant polycystic kidney disease. Intern Med 60: 3577-3580, 2021.
10. Terakawa K, Sawa N, Mizuno H, Sekine A, Hayami N, Ikuma D, Kawada M, Hiramatsu R, Sumida K, Yamanouchi M, *et al*: Renal squamous cell carcinoma-related polymyositis in a patient with autosomal dominant polycystic kidney disease. Intern Med 60: 1237-1242, 2021.
11. Colović N, Jurišić V, Terzić T, Jevtovic D and Colović M: Alveolar granulocytic sarcoma of the mandible in a patient with HIV. Onkologie 34: 55-58, 2011.
12. Grulich AE, van Leeuwen MT, Falster MO and Vajdic CM: Incidence of cancers in people with HIV/AIDS compared with immunosuppressed transplant recipients: A meta-analysis. Lancet 370: 59-67, 2007.
13. Salavoura K, Kolialexi A, Tsangaris G and Mavrou A: Development of cancer in patients with primary immunodeficiencies. Anticancer Res 28 (2B): 1263-1269, 2008.
14. Bakrac M, Jurisic V, Kostic T, Popovic V, Pekic S, Kraguljac N and Colovic M: Pure red cell aplasia associated with type I autoimmune polyglandular syndrome-successful response to treatment with mycophenolate mofetil: Case report and review of literature. J Clin Pathol 60: 717-720, 2007.
15. Živković V, Cvetković T, Mitić B, Stamenković B, Stojanović S, Radovanović-Dinić B and Jurišić V: Monocyte chemoattractant protein-1 as a marker of systemic lupus erythematosus: An observational study. Rheumatol Int 38: 1003-1008, 2018.
16. Moris D, Kakavia K, Argyrou C, Garmpis N, Bokos J, Vernadakis S, Diles K, Sotirchos G, Boletis J and Zavos G: De Novo renal cell carcinoma of native kidneys in renal transplant recipients: A single-center experience. Anticancer Res 37: 773-779, 2017.
17. Kitajima T, Ubara Y and Marui Y: Sarcomatoid carcinoma in the native kidney of a renal transplant recipient. Ther Apher Dial 16: 376-378, 2012.
18. Yoshimura Y, Suwabe T, Fujiki A, Kaji D, Asano-Mori Y, Oba Y, Mizuno H, Yamanouchi M, Tanaka K, Hasegawa E, *et al*: Gastric Burkitt's monomorphic post-transplant lymphoproliferative disorder after kidney transplantation: A case report. Clin Nephrol 101: 250-256, 2024.