SPANDIDOS PUBLICATIONS

ONCOLOGY LETTERS 28: 451, 2024

# Newer combination treatments for breast cancer coexisting with acute myeloid leukemia in the novel regimens era: A case report and literature review

LINA XING, TIAN TIAN, YANG LI, JINGNAN ZHANG, XIAONAN GUO and SHUKAI QIAO

Department of Hematology, Hebei Key Laboratory of Hematology,
The Second Hospital of Hebei Medical University, Shijiazhuang, Hebei 050000, P.R. China

Received April 9, 2024; Accepted July 3, 2024

DOI: 10.3892/ol.2024.14584

**Abstract.** The occurrence of acute myeloid leukemia (AML) with a simultaneous diagnosis of breast cancer (BC) is rarely reported in the literature. The present study reports the case of a 50-year-old female patient diagnosed with AML coexisting with metastatic BC. Following one cycle of treatment with azacytidine in combination with oral venetoclax for AML, the patient achieved complete remission with incomplete hematological recovery. In addition, the mass in the left breast was smaller following adjuvant chemotherapy. However, due to a refusal from the patient to accept an allogeneic hematopoietic stem cell transplantation (allo-HSCT), the patient succumbed 3 months after diagnosis due to septic shock from neutropenia following the third cycle of chemotherapy. Altogether, the present case report highlighted the application of venetoclax, an oral selective B-cell lymphoma-2 inhibitor, both in hematologic malignancies and solid neoplasms, as an effective therapeutic regimen. Considering the fatality rate associated with AML, allo-HSCT is the only available strategy that can be used to achieve the long-term survival of patients with AML and BC.

## Introduction

The synchronous occurrence (within 6 months) of two neoplasms is rarely observed, particularly acute myeloid leukemia (AML) coexisting with breast cancer (BC) [with actual incidence rates of <1% (1)], which is also associated with a poor prognosis [the survival time varies from 1 month to 3 years] (2-8). The prognosis of patients with synchronous occurrence of AML and BC is closely related to the risk factors of AML, and in terms of the long-term survival of the patient, the solution in such a case is based primarily on the treatment of AML, while placing the management of BC on hold (9). B-cell lymphoma-2 (BCL-2) expression is high not only in leukemia stem cells in AML, but also in solid tumors, including BC (10,11). Venetoclax is an oral selective BCL-2 inhibitor widely used in the treatment of hematological malignancies (12). In such cases, venetoclax inhibits BCL-2 to promote tumor cell apoptosis (13,14), to simultaneously combat the coexistence of AML and BC. The present study describes a rare case of AML coexisting with metastatic BC (mBC), focusing on the treatment options with the use of venetoclax combined with other regimens to achieve an effective response in both AML and BC.

## Case report

In March 2021, a 50-year-old female patient presented to another hospital (The Affiliated Hospital of Hebei University, Baoding, China) with progressive fatigue that had persisted for 1 week. At 3 months prior to admission, the patient had noted a 20-mm mass in the left breast; however, the patient refused to be hospitalized. A complete blood count indicated a white blood cell count of $22x10^9$/l (normal range, 3.5-9.5x$10^9$/l), a hemoglobin concentration of 92 g/l (normal range, 115-150 g/l) and a platelet count of $42x10^9$/l (normal range, 125-300x$10^9$/l). A large number of monoblastic cells, which accounted for 66% of bone marrow nucleated cells, were observed in a bone marrow smear analysis (Fig. 1). Immunophenotyping revealed that the blast cells were $CD34^+$, $HLA\text{-}DR^+$, $CD123^+$, $CD38^+$, $CD117^+$, $CD7^+$, $CD11b^+$, $CD13^+$ and $CD33^+$, which appeared with myeloid blasts (Fig. 2). The patient harbored a complex karyotype (CK), as well as a monosomal karyotype (MK) {44,XX,t(4;16)(q11;p13),-15,-17,add(17)(p11),-19,-21,+mar1,+mar2[5]/44,idem del(5)(q31)[2]/46,XX[9]} (Fig. 3), without any molecular and next-generation sequencing abnormalities. Based on the World Health Organization 2016 criteria (15), the patient was diagnosed with AML (AML-not otherwise specified; poor-risk). There was a mass in the upper outer quadrant of the left breast of the patient and a palpable left axillary node was present. An ultrasound revealed a 39x32-mm mass (3 o'clock); however, the patient did not consent to a biopsy of the breast mass. These aforementioned results were provided by a relative of the patient.

*Correspondence to:* Dr Shukai Qiao, Department of Hematology, Hebei Key Laboratory of Hematology, The Second Hospital of Hebei Medical University, 215 West Heping Road, Shijiazhuang, Hebei 050000, P.R. China
E-mail: qiaoshukai@hebmu.edu.cn

*Key words:* acute myeloid leukemia, breast cancer, venetoclax, azacitidine, chemotherapy

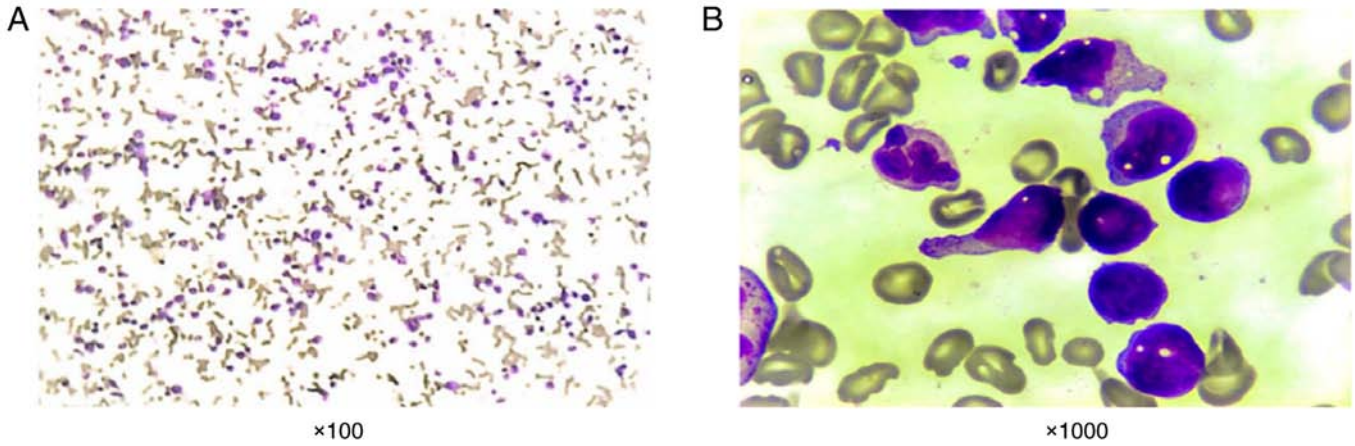


Figure 1. Morphology analysis of a bone marrow aspirate at the initial stage of diagnosis. Images collected at (A) x100 and (B) x1,000 magnification. Bone marrow smear (Giemsa staining) showed notably increasing myeloid blasts.

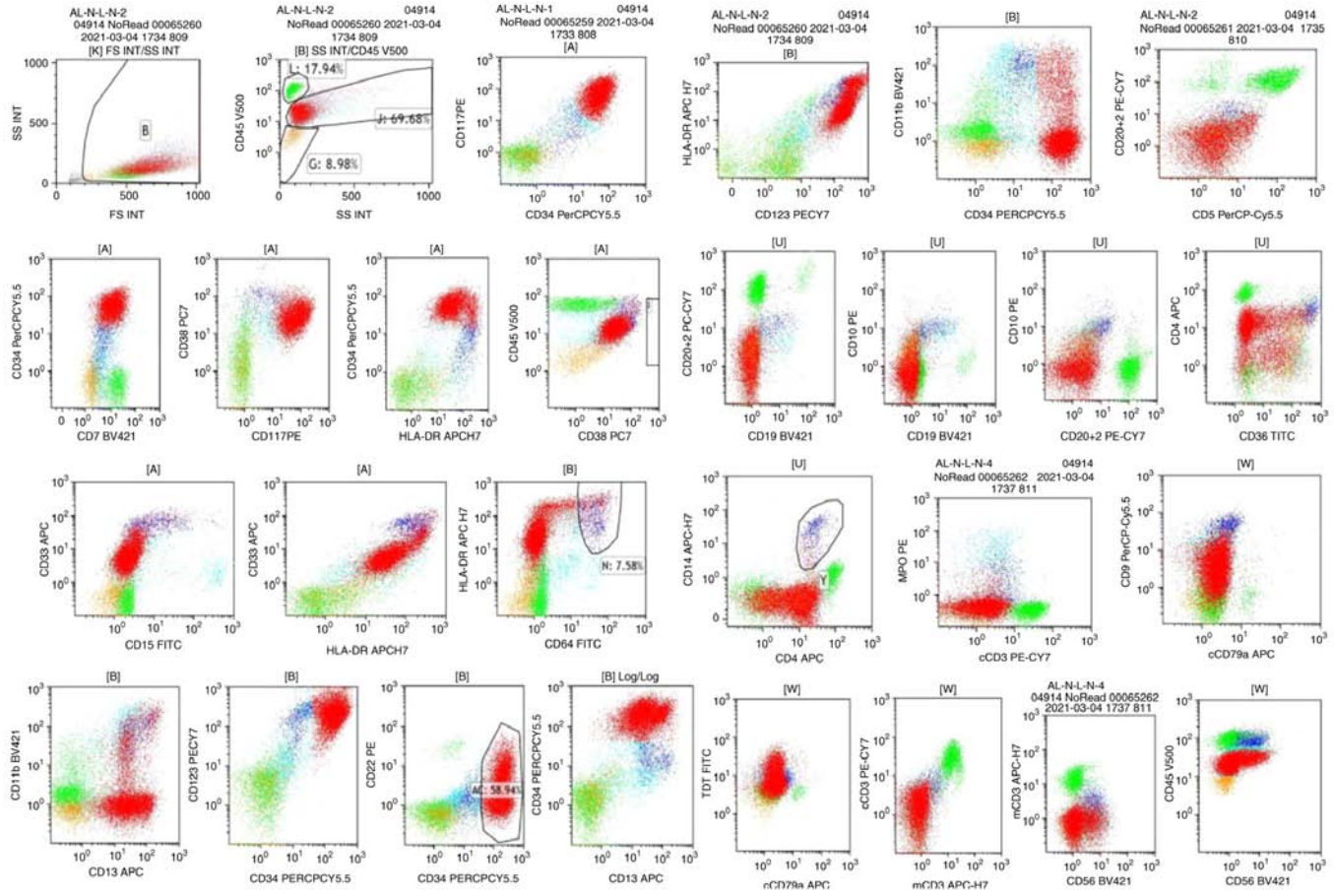

Figure 2. Flow cytometry analysis of a bone marrow aspirate. Bone marrow flow cytometry indicates an acute myeloid leukemia diagnosis: CD34$^+$, HLA-DR$^+$, CD123$^+$, CD 38$^+$, CD117$^+$, CD7$^+$, CD11b$^+$, CD13$^+$, CD33$^+$, CD5$^-$, CD3$^-$ and CD19$^-$.

An induction chemotherapeutic regimen consisting of azacitidine (AZA; 75 mg/m$^2$, days 1-7) + CAG [aclarubicin at 20 mg, days 4-7; cytarabine at 20 mg twice a day, days 4-14; granulocyte-colony stimulating factor (G-CSF) at 150 $\mu$g, days 4-14] was administered, and 21 days following the commencement of therapy, the patient did not achieve hypoplasia with 15% residual blasts. Moreover, the mass in the left breast exhibited rapid growth, which was confirmed by a subsequent ultrasound. The patient was then admitted to the Department of Hematology of The Second Hospital (Hebei Medical University, Shijiazhuang, China) for further diagnosis and therapy in April, 2021.

A subsequent peripheral blood cell count indicated a white blood cell count of 0.7x10$^9$/l, a hemoglobin concentration of 58 g/l and a platelet count of 53x10$^9$/l. To evaluate the effect of the previous cycle of combination chemotherapy, another bone marrow smear analysis was performed. For this, the

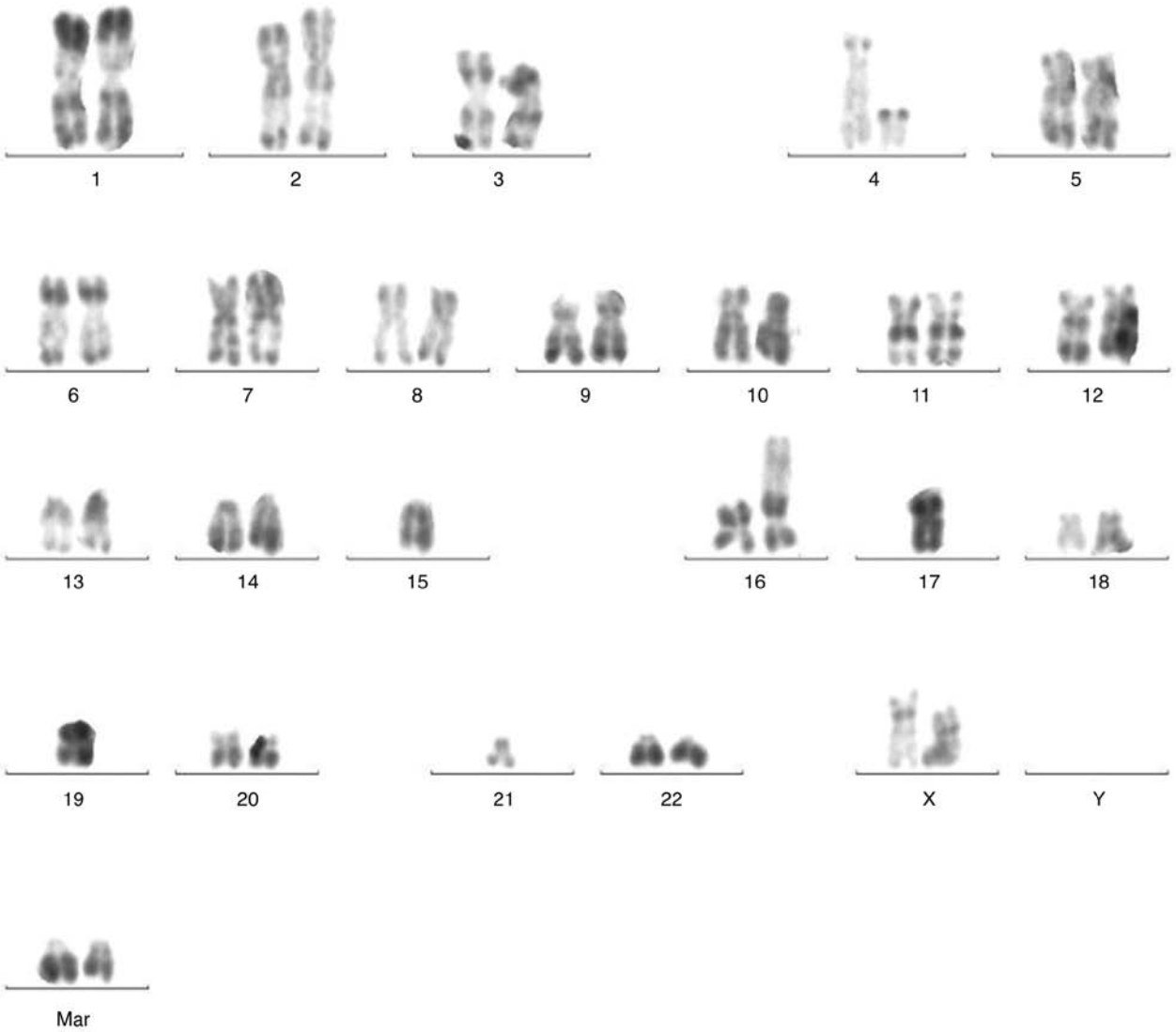


Figure 3. G-banded karyotype of bone marrow cells demonstrated a complex karyotype and a monosomal karyotype {44,XX,t(4:16)(q11;p13),-15,-17,add(17)(p11),-19,-21,+mar1,+mar2[5]/44,idem del(5)(q31)[2]/46,XX[9]}.

bone marrow smear was naturally dried, then 2-3 drops of Wright-Giemsa staining solution was added to the entire specimen smear at room temperature for 1-2 min. An equal amount of 0.01 mol/l sodium dihydrogen phosphate solution was added to the slide, the slide was gently shaken to thoroughly mix with the Wright-Giemsa staining solution and the sample was incubated at room temperature for 3-5 min. The smear was washed with double distilled water, blotted dry and examined under a light microscope. The bone marrow smear analysis revealed 58% monoblastic cells (Fig. 4A-D) on the 28th day following the commencement of chemotherapy. According to the response criteria definitions for AML, the patient had not achieved complete remission (CR) or partial remission (PR). An ultrasound revealed that the mass in the left breast was 62x43-mm (3 o'clock) with ipsilateral axillary lymphadenopathy, and evidence of bone destruction was confirmed by a subsequent bone scan. An ultrasound-guided core needle biopsy confirmed a diagnosis of invasive carcinoma. For this, the puncture tissues were immersed in formaldehyde solution (4%) and fixed overnight at 4˚C. The next day, the tissues were dehydrated and embedded in paraffin wax. The embedded material was then cut into 5-$\mu$m sections and the sections were dewaxed with xylene, rehydrated through an alcohol gradient (100, 95, 90, 80 and 70%; 5 min each), then washed with distilled water. H&E staining was performed at room temperature; slices were dyed with Harris hematoxylin for 3-8 min and washed with tap water, then incubated in eosin dye solution for 1-3 min and washed with tap water. The sections were successively immersed in 95% alcohol, anhydrous ethanol and xylene for 5 min each to dehydrate the sample. The sample was dried and sealed with neutral gum. Antigens were extracted at 100˚C before immunohistochemical staining. Endogenous peroxidase activity was then blocked with 3% hydrogen peroxide, after washing with phosphate buffered saline (PBS) twice for 5 min each. The sample was incubated with normal goat serum [5%; Yeason Biotechnology (Shanghai) Co., Ltd.] at 37˚C for 30 min to block non-specific background staining. Next, the sections were incubated with anti-estrogen receptor (ER; cat. no. ab16660; 0.5 $\mu$g/ml; Abcam), anti-progesterone receptor (cat. no. ab32085; 1 $\mu$g/ml; Abcam), anti-human epidermal growth factor receptor 2 (HER2; cat. no. ab16662;

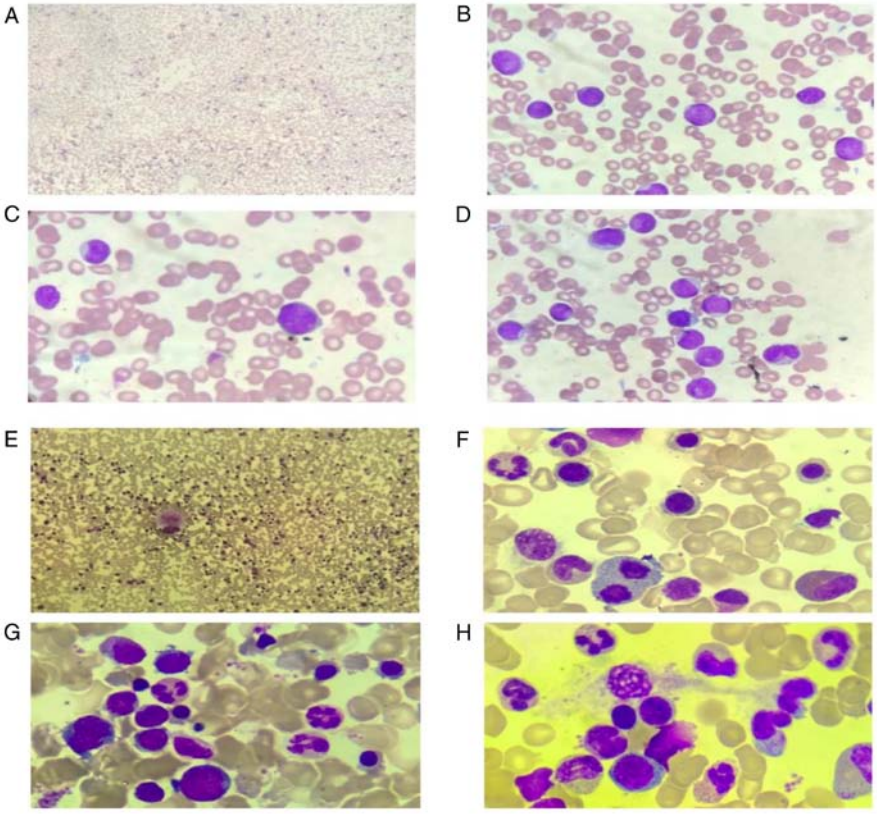


Figure 4. Morphology analysis of a bone marrow aspirate. Images collected before the second cycle of acute myeloid leukemia chemotherapy at (A) x100 and (B-D) x1,000 magnification. The bone marrow smear (Wright-Giemsa staining) showed notably increasing numbers of myeloid blasts. Images collected at (E) x100 and (F-H) x1,000 magnification on day 28 of the adjuvant chemotherapy treatment regimen. The bone marrow smear (Wright-Giemsa staining) showed the clearance of myeloid blasts (<5%).

1 $\mu$g/ml; Abcam) and anti-Ki-67 (cat. no. ab15580; 1 $\mu$g/ml; Abcam) at room temperature for 30 min. The slices were washed with PBS and incubated with secondary antibody (HRP marker; cat. no. ab6721; 1 $\mu$g/ml; Abcam) at room temperature for 20 min. DAB substrate staining was used. Representative images were collected using an optical microscope and analyzed with ImageJ (v.1.8.0; National Institutes of Health; https://imagej.net/software/imagej/) (16). Immunohistochemistry yielded positive results for the ER and progesterone receptor (80 and 10%, respectively), with a high Ki67 proliferation index (40%) and negative expression of HER2 (Fig. 5). Fluorescence *in situ* hybridization for the HER2 gene also yielded negative results using the PathVysion HER-2 DNA probe kit (Abbott) as previously described (17). These results indicated a luminal B-like ($HER2^-$) type BC [staging T3N1M1, according to the American Joint Committee on Cancer TNM staging system (18)] diagnosis.

After obtaining informed consent, the patient began an adjuvant chemotherapy treatment regimen with pegylated liposomal doxorubicin at 40 mg (day 1, per 21 days for two cycles) and albumin-bound paclitaxel at 200 mg (days 1 and 8, per 21 days for two cycles) to treat mBC. The patient was also treated with standard AZA at 75 mg/$m^2$ subcutaneously for 7 days, in combination with oral venetoclax for AML (based on a pharmacokinetic test, from a dose of 100-200 mg/day, the dosing of which must be adjusted in the setting of the concomitant administration of the CYP3A4 inhibitor, voriconazole (200 mg twice daily for 4 weeks). Tumor lysis syndrome was monitored during a 3-5-day dose ramp-up of venetoclax, and G-CSF was also administered (300 $\mu$g per day for 3 weeks) to reduce the risk of infections and other cytopenia-related adverse events with the venetoclax-based combinations. When the white blood cell and platelet counts of the patient were normal (white blood cell count, $5.6x10^9$/l; platelet count, $218x10^9$/l) a bone marrow aspiration was performed on day 28 (Fig. 4E-H). With the clearance of blasts (<5%), the response to AML treatment was defined as CR with incomplete hematological recovery (CRi). The treatment response to BC was defined as PR as the mass in the left breast was notably smaller (only 20x20 mm in size). Due to economic reasons, the patient refused an allogeneic hematopoietic stem cell transplantation (allo-HSCT); thus, the patient was then treated with another cycle of chemotherapy without dose modifications. However, the patient succumbed due to septic shock from neutropenia following the third cycle of chemotherapy.

## Discussion

Synchronous multiple cancer, defined as a cancer diagnosed simultaneously with another cancer or diagnosed within 6 months, is uncommon. The risk of a patient diagnosed with BC being diagnosed with a co-existing second cancer is 2-3% (1), and the synchronous occurrence of BC and AML is rare. The present study described the case of a female patient presenting with the co-existence of AML and BC. To date and to the best of our knowledge, only 11 cases of a synchronous occurrence of AML and BC have been described in the literature (Table I) (2-8). The simultaneous diagnosis of AML and BC is associated with

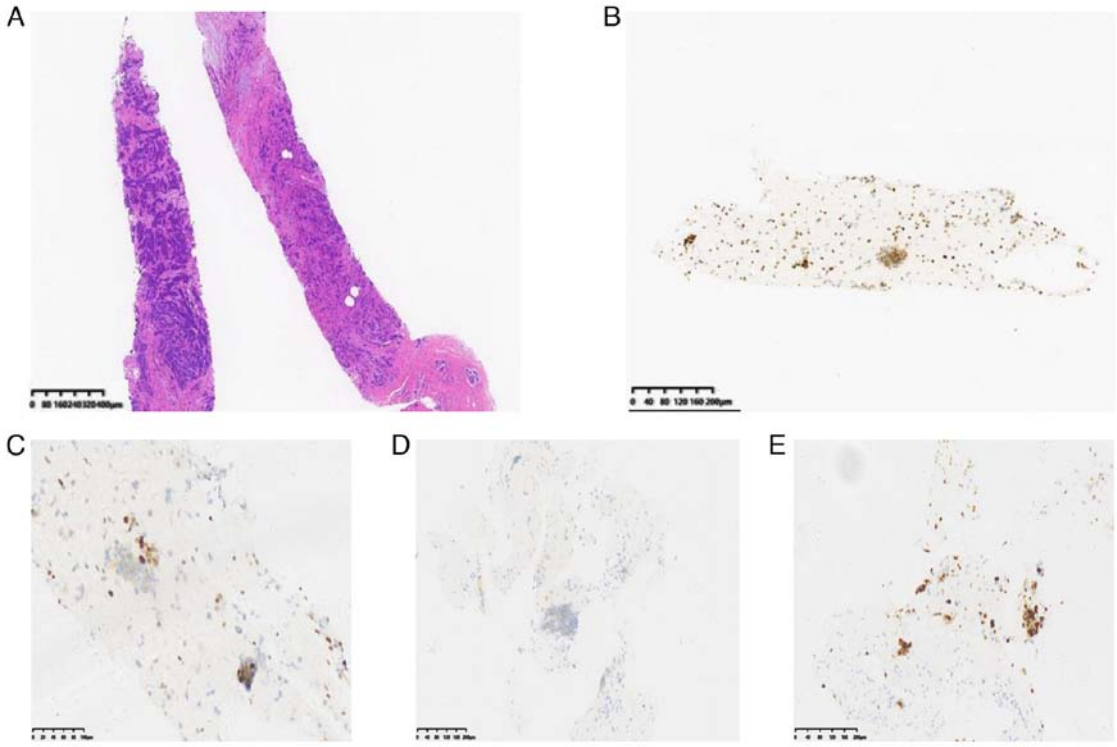


Figure 5. Pathology of the mass of the left breast. (A) Needle biopsy (H&E staining) showing tumor cells infiltrating the normal breast structure. Tumor cells were (B) partially bright positive for the estrogen receptor, (C) 10% positive for progesterone receptors, (D) human epidermal growth factor receptor 2 negative and (E) had a high Ki67 proliferation index (40%) by immunohistochemistry.

an extremely poor prognosis with standard therapies. Specifically, only 4 such cases have reached a CR for AML (4,6-8) and only 1 patient who achieved a CR for both diseases was able to undergo an allo-HSCT (8), which is currently regarded as the only recommended therapeutic approach aimed at achieving long-term disease-free survival for patients with AML (9). Of the 11 patients identified in the literature, 4 cases survived for as little as 1 week to 1.5 months, 2 patients survived for >3 years and 9 patients succumbed due to AML. To date, the median overall survival (OS) time of patients with mBC is only ~37 months (19), and clinicians typically treat AML first before BC due to the poor outcomes associated with AML. In the present study, the authors aimed to select the appropriate therapeutic strategy for the two malignancies simultaneously.

Patients with $ER^+$ mBC who are $HER2^-$ and who are not suitable to receive treatments such as quadrantectomy, local radiotherapy and HER2 inhibitors, are recommended classical endocrine therapy with or without molecular therapies (20-22). However, acquired resistance to hormonal therapies occurs in 30-50% of cases, which has been confirmed to occur via the PI3K-AKT-mTOR, cyclin D1-CDK4/6-retinoblastoma protein, BCL-2-p53-MDM2, ER1 and other cell-signaling pathways (23). Molecular-based therapies, including CDK4/6 inhibitors (such as palbociclib/ribociclib/abemaciclib) (24), an mTORC1 inhibitor (everolimus) (25), an α isoform-specific PI3K inhibitor (alpelisib) (26) and a BCL-2 inhibitor (venetoclax) (27) have been demonstrated to have potential efficacy as adjuvant therapies in patients with advanced-stage BC. Moreover, regardless of the molecular subtype, chemotherapy still represents a fundamental option for patients with mBC. In the present study, according to the pathological results, the patient accepted adjuvant chemotherapy, combining pegylated liposomal doxorubicin with albumin-bound paclitaxel. Furthermore, BCL-2 inhibitor molecular therapy was administered to the patient for BC and AML simultaneously.

BCL-2 expression is high in the leukemia stem cells of AML (28). Venetoclax, an oral selective BCL-2 inhibitor first approved for the treatment of chronic lymphocytic leukemia, can lead to the rapid initiation of AML cell apoptosis (13). Despite the modest efficacy of single-agent treatment with either venetoclax or hypomethylating agents (HMAs) (29), the rationale for combining venetoclax with HMAs was provided by the potential of BCL-2 inhibitors to sensitize AML cells to HMAs (30). In two pivotal clinical trials, the rates of CR plus CRi were 54 and 67% in patients treated with venetoclax plus low-dose cytarabine (LDAC) or HMAs, and the median OS time was 10.4 and 17.5 months, respectively (31,32). Due to these results, the U.S. Food and Drug Administration approved the use of venetoclax in combination with LDAC or HMAs for older or unfit patients newly diagnosed with AML and for patients who have relapsed/refractory AML.

The overall frequency of a CK in AML, the most unfavorable prognostic factor in AML with a well-known poor outcome, has been shown to occur in 10-14% of patients in prior studies and has been reported to occur in up to 23% of older patients with AML (33,34). Patients with AML with a CK are generally resistant to conventional induction and consolidation and only 10-40% achieve CR and tend to relapse in a median time of 6-8 months (35). The MK, another adverse cytogenetic aberration, appears to be a worse prognostic predictor of a poor outcome, with a 4-year OS rate of 4% compared with 21% in patients with CK (36). Patients with AML presenting with the co-existence of

Table I. Cases of synchronous occurrence of BC and AML in the literature.

| Author, year | Sex/Age, years | Interval | Diagnosis (type of BC) | Morphology of AML | Phenotype of AML | Genetics of AML | Karyotype of AML | Therapy for AML/BC | Response to AML/BC therapy | Outcome | (Refs.) |
|---|---|---|---|---|---|---|---|---|---|---|---|
| Softic, 1964 | F/84 | Simultaneous | NA | NA | NA | NA | NA | None | NA | Death | (2) |
| Carey *et al*, 1967 (case 1) | F/57 | 2 months | Ductal cell carcinoma | NA | NA | NA | NA | Cyclophosphamide of AML; radical mastectomy of BC | NR | Died during induction in 43 days. | (3) |
| Carey *et al*, 1967 (case 6) | F/55 | Simultaneous | NA | M3 | NA | NA | NA | None | NA | Death | (3) |
| Rosner *et al*, 1978 (case 18) | F/58 | 3 months | NA | NA | NA | NA | NA | 6-mercaptopu-rine, methotrexate, vincristine, and prednisone of AML radical mastectomy of BC | CR for AML lasting 1 year | Died for diabetic coma and gastrointestinal hemorrhage in CR of AML | (4) |
| Rosner *et al*, 1978 (case 23) | F/59 | 6 months | NA | NA | NA | NA | NA | Combination chemotherapy of AML; radical mastectomy of BC | HR for AML | Death after HR | (4) |
| Ershler *et al*, 1982 (case 6) | F/64 | 6 months | NA | NA | NA | NA | 45, banding not possible | Hydroxyurea for AML; cyclophosphamide for BC | PR for AML; NA for BC | Died after 3 months | (5) |
| Ershler *et al*, 1982 (case 8) | F/65 | Simultaneous | NA | M4 | NA | NA | NA | Cytarabine for AML; none for BC | NR for AML | Died during induction in 9 days | (5) |
| Mishra *et al*, 2004 | F/38 | 1 month | Infiltrating duct carcinoma | M1 | $CD13^+$, $CD33^+$, $HLA\text{-}DR^+$, $CD7^+$ | p53 mutation in both AML and BC | 46, XX | DA of AML; modified radical mastectomy of BC | CR for AML | Died following intracerebral hemorrhage | (6) |
| Hu *et al*, 2016 | F/57 | Simultaneous | Invasive | M4 ductal carcinoma | $CD117^+$, $CD34^+$, $CD33^+$, $CD11c^+$, $CD13^+$ | NPM1 and CEBPA mutations | 47, XX, +11 | DA/CAG for AML; tamoxifen/TEC/ MRM for BC | NR/CR for AML; progressed/stable for BC | Alive in CR; stable BC | (7) |
| Ballotta *et al*, 2020 | F/40 | 1 month | Invasive poorly differentiated ductal carcinoma | NA | $CD34^+$, $CD117^+$, $HLA\text{-}DR^+$, $CD4^+$, $CD7^+$, CD13, $TdT^+$, $CD33^{+/-}$ | Negative | 46, XX | ICE/G-CLAC/HSCT of AML; right quadrantectomy/DC/ tamoxifen of BC. | NR/CR of AML; CR of BC. | Alive in CR for AML and BC after allo-HSCT | (8) |

Table I. Continued.

| Author, year | Sex/Age, years | Interval | Diagnosis (type of BC) | Morphology of AML | Phenotype of AML | Genetics of AML | Karyotype of AML | Therapy for AML/BC | Response to AML/BC therapy | Outcome | (Refs.) |
|---|---|---|---|---|---|---|---|---|---|---|---|
| Ballotta *et al*, 2020 | NA | Simultaneous | NA | M2 | $CD34^{+/-}$, $CD117^{+}$, $CD7^{+}$, $HLA\text{-}DR^{+}$, $CD13^{+}$, $CD33^{+}$ | MLL self-fusion | 46, XX | NA | RD | Died of AML after 13 months | (8) |
| Present case | F/50 | 3 months | Invasive carcinoma | M5 | $CD34^{+}$, $HLA^{-}DR^{+}$, $CD123^{+}$, $CD38^{+}$, $CD117^{+}$, $CD7^{+}$, $CD11b^{+}$, $CD13^{+}$, $CD33^{+}$ | Negative | Complex karyotype | AZA + CAG/VA for AML | NR/CRi for AML; PR for BC | Died of septic shock | - |

BC, breast cancer; AML, acute myeloid leukemia; N, not available; CR, complete remission; NR, not remission; HR, hematological remission; PR, partial remission; CRi, complete remission with incomplete hematological recovery; RD, refractory disease; HSCT, hematopoietic stem cell transplantation; DA, daunorubicin and cytosine arabinoside; G-CSF, granulocyte-colony stimulating factor; CAG, arabinoside cytarabine 25 mg (days 1-14), aclarubicin 10 mg (days 1-8) and G-CSF 300 $\mu$g (days 1-14); ICE, idarubicin 10 mg/m$^2$ (days 1, 3 and 5), cytarabine 100 mg/m$^2$ (days 1-7) and etoposide 100 mg/m$^2$ (days 1-5); G-CLAC, clofarabine 30 mg/m$^2$ (days 1-5), cytarabine 2,000 mg/m$^2$ (days 1-5) and G-CSF until hemopoietic recovery; AZA, azacitidine; VA, azacitidine 75 mg/m$^2$ (days 1-7) and venetolax (100 mg days 1-7 and 200 mg days 8-28); DC, doxorubicin 60 mg/m$^2$/day and cyclophosphamide 600 mg/m$^2$/day; TEC, paclitaxel 77 mg/m$^2$, epirubicin 77 mg/m$^2$, cyclophosphamide 0.6 g/m$^2$, on day 1, every 3 weeks; MRM, modified radical mastectomy; MLL, myeloid/lymphoid leukemia.

MK and CK achieve an overall remission rate of 28% following treatment with intensive chemotherapy (37). A few studies to date have indicated that combination treatment of venetoclax with HMAs or mono-regimen CPX 351, a liposomal formulation of cytarabine and daunorubicin, is associated with an optimal trend for the OS of patients (38,39). The patient described in the present study diagnosed with adverse AML with CK and MK, first failed to achieve remission with one regimen of AZA + CAG; however, the patient achieved an effective response of CRi following the adjustment of a combination of venetoclax with AZA.

The increased expression of the anti-apoptotic protein, BCL-2, has been reported in a number of different solid tumor histotypes and is also linked to resistance to chemotherapies, including in renal, breast and thyroid carcinoma, but not in AML, mature B-cell malignancies and lymphoid malignancies; thus, studies mainly focus on BCL-2 inhibitor application in solid tumors (10,11). The expression of BCL-2 in BC is the second highest in a wide range of tumor histotypes, according to The Human Protein Atlas database (https://www.proteinatlas.org/). Due to the upregulation of BCL-2 in BC, particularly in 80% of primary $ER^+$ BC cases, the molecular mechanisms of venetoclax, including BC cell proliferation and growth inhibition via the promotion of apoptosis, cell cycle arrest and autophagy, have been confirmed via *in vitro* studies (14,40). Preclinical data on the combination of venetoclax with tamoxifen to increase the apoptosis of patient-derived xenograft models of $ER^+$ BC have led to a phase Ib dose-escalation and expansion study of venetoclax combined with endocrine therapy in mBC, which is both $ER^-$ and BCL-$2^+$ (27,41). In the first clinical study, 15 patients were treated orally with daily tamoxifen (20 mg) and venetoclax (200-800 mg) in the escalation phase, and in the expansion phase, 24 patients received 800 mg venetoclax as the recommended phase II dose (RP2D) for neither dose-limiting toxicities nor high-grade adverse events were observed. For treatment at the RP2D, all 24 patients had measurable disease with a clinical benefit rate of 75%; the objective response rate was 54% (1 CR and 12 PR), stable disease was 21% (5 patients) and the median progression-free survival was not reached at the time of data analysis (>51 weeks). According to the marked efficacy and acceptable safety of the combined use of venetoclax with endocrine therapy, a randomized phase II trial of venetoclax + fulvestrant versus fulvestrant in $ER^+$, $HER2^-$ locally advanced or mBC is ongoing in five countries, enrolling 100 patients (42). These findings support the use of venetoclax both as a single agent and in combination strategies for the further investigation of patients with BCL-$2^+$ tumors.

To the best of our knowledge, the case described in the present study is the only one characterized in the literature by a severe prognosis of AML with CK and MK that achieved CRi of AML and PR of BC. Venetolax was used as a therapeutic agent for AML; however, according to the criteria response of BC in the patient described in the present study and in the reported literature (27,41), it is conceivable that venetolax plays an effective role in the treatment of the two malignancies simultaneously.

In conclusion, it is essential to determine appropriate treatment measures for patients with co-existing AML and BC in the era of novel agents. Following the notable results with the application of venatoclax in AML and BC, respectively, this oral selective BCL-2 inhibitor may be used for the treatment of synchronous cancer (such as AML plus BC) to achieve efficacy and safety. However, further studies with a greater number of cases are required to clarify and optimize the therapeutic potential and use of treatment regimens containing venatoclax.

**Acknowledgements**

Not applicable.

**Funding**

No funding was received.

**Availability of data and materials**

The data generated in the present study may be requested from the corresponding author.

**Authors' contributions**

LX was responsible for clinical data collection, interpretation of the results, drafting the manuscript and providing final approval of the version to be published. SQ participated in the design of the study and analyzed patient data. TT and YL obtained medical images of the bone marrow smear, and JZ and XG gave advice on the treatment of the patient. JZ and XG confirm the authenticity of all the raw data. All authors have read and approved the final version of the manuscript.

**Ethics approval and consent to participate**

Not applicable.

**Patient consent for publication**

Written informed consent for publication of the case report, including the clinical details and images was provided by the patient's relative.

**Competing interests**

The authors declare that they have no competing interests.

**References**

1. Lee J, Park S, Kim SH, Kim J, Ryu J, Park HS, Kim SI and Park BW: Characteristics and survival of breast cancer patients with multiple synchronous or metachronous primary cancers. Yonsei Med J 56: 1213-1220, 2015.
2. Softic N: Acute myeloblastic leukemia in an 84-year-old woman, associated with a breast cancer and a mixed parotid tumor without metastasis. Nouv Rev Fr Hematol 4: 458-460, 1964 (In French).
3. Carey RW, Holland JF, Sheehe PR and Graham S: Association of cancer of the breast and acute myelocytic leukemia. Cancer 20: 1080-1088, 1967.
4. Rosner F, Carey RW and Zarrabi MH: Breast cancer and acute leukemia: Report of 24 cases and review of the literature. Am J Hematol 4: 151-172, 1978.
5. Ershler WB, Robins HI, Davis HL, Hafez GR, Meisner LF, Dahlberg S and Arndt C: Emergence of acute non-lymphocytic leukemia in breast cancer patients. Am J Med Sci 284: 23-31, 1982.
6. Mishra PP, Mahapatra M, Choudhry VP, Saxena R, Pati H, Dixit A, Anupama R, Bhattacharya J, Chatterjee T and Dutta P: Synchronous occurrence of breast carcinoma and acute myeloid leukemia: Case report and review of the literature. Ann Hematol 83: 541-543, 2004.

7. Hu G, Mallik DK, Yang W, Hou Y, Cheng Z, Chen P, Zhu W, Wang H, Shen L, Zhang H and Yang Z: Appropriate clinical strategies for breast cancer coexisting with acute myeloid leukemia in the genomic-molecular era: A case report. Breast Care (Basel) 11: 145-147, 2016.
8. Ballotta L, Trisolini SM, Iori AP, Rocca UL, Micozzi A, Gentile G, De Giacomo T, Guarini A, Foà R and Capria S: A rare case of coexisting breast cancer and refractory acute myeloid leukemia. Case Rep Hematol 2020: 8893185, 2020.
9. Litzow MR: The therapy of relapsed acute leukaemia in adults. Blood Rev 18: 39-63, 2004.
10. D'Aguanno S and Del Bufalo D: Inhibition of anti-apoptotic Bcl-2 proteins in preclinical and clinical studies: Current overview in cancer. Cells 9: 1287, 2020.
11. Maji S, Panda S, Samal SK, Shriwas O, Rath R, Pellecchia M, Emdad L, Das SK, Fisher PB and Dash R: Bcl-2 antiapoptotic family proteins and chemoresistance in cancer. Adv Cancer Res 137: 37-75, 2018.
12. Roberts AW, Wei AH and Huang DCS: BCL-2 and MCL-1 inhibitors for hematologic malignancies. Blood 138: 1120-1136, 2021.
13. Lagadinou ED, Sach A, Callahan K, Rossi RM, Neering SJ, Minhajuddin M, Ashton JM, Pei S, Grose V, O'Dwyer KM, *et al*: BCL-2 inhibition targets oxidative phosphorylation and selectively eradicates quiescent human leukemia stem cells. Cell Stem Cell 12: 329-341, 2013.
14. Alhoshani A, Alatawi FO, Al-Anaz FE, Attafi IM, Zeidan A, Agouni A, El Gamal HM, Shamoon LS, Khalaf S and Korashy HM: BCL-2 inhibivtor venetoclax induces autophagy-associated cell death, cell cycle arrest, and apoptosis in human breast cancer cells. Onco Targets Ther 13: 13357-13370, 2020.
15. Arber DA, Orazi A, Hasserjian R, Thiele J, Borowitz MJ, Le Beau MM, Bloomfield CD, Cazzola M and Vardiman JW: The 2016 revision to the World Health Organization classification of myeloid neoplasms and acute leukemia. Blood 127: 2391-2405, 2016.
16. Caroline AS, Vaine SR and Kevin WE: NIH Image to ImageJ: 25 Years of image analysis. Nat Methods 9: 671-675, 2012.
17. Oberauner-Wappis L, Loibner M, Viertler C, Groelz D, Wyrich R and Zatlouka K: Protocol for HER2 FISH determination on PAXgene-fixed and paraffin-embedded tissue in breast cancer. Int J Exp Pathol 97: 202-206, 2016.
18. Giuliano AE, Connolly JL, Edge SB, Mittendorf EA, Rugo HS, Solin LJ, Weaver DL, Winchester DJ and Hortobagyi GN: Breast cancer-major changes in the American Joint Committee on Cancer eighth edition cancer staging manual. CA Cancer J Clin 67: 290-303, 2017.
19. Gobbini E, Ezzalfani M, Dieras V, Bachelot T, Brain E, Debled M, Jacot W, Mouret-Reynier MA, Goncalves A, Dalenc F, *et al*: Time trends of overall survival among metastatic breast cancer patients in the real-life ESME cohort. Eur J Cancer 96: 17-24, 2018.
20. Hortbagyi GN, Stemmer SM, Burris HA, Yap YS, Sonke GS, Paluch-Shimon S, Campone M, Petrakova K, Blackwell KL, Winer EP, *et al*: Updated results from MONALEESA-2, a phase III trial of first-line ribociclib plus letrozole versus placebo plus letrozole in hormone receptor-positive, HER2-negative advanced breast cancer. Ann Oncol 29: 1541-1547, 2018.
21. Di Leo A, Jerusalem G, Petruzelka L, Torres R, Bondarenko IN, Khasanov R, Verhoeven D, Pedrini JL, Smirnova I, Lichinitser MR, *et al*: Results of the CONFIRM phase III trial comparing fulvestrant 250 mg with fulvestrant 500 mg in postmenopausal women with estrogen receptor-positive advanced breast cancer. J Clin Oncol 28: 4594-4600, 2010.
22. Reinert T and Barrios CH: Optimal management of hormone receptor positive metastatic breast cancer in 2016. Ther Adv Med Oncol 7: 304-320, 2015.
23. Rozeboom B, Dey N and De P: ER+ metastatic breast cancer: Past, present, and a prescription for an apoptosis-targeted future. Am J Cancer Res 9: 2821-2831, 2019.
24. Piezzo M, Cocco S, Caputo R, Cianniello D, Gioia GD, Lauro VD, Fusco G, Martinelli C, Nuzzo F, Pensabene M and De Laurentiis M: Targeting cell cycle in breast cancer: CDK4/6 inhibitors. Int J Mol Sci 21: 6479, 2020.
25. Moreau-Bachelard C, Robert M, Gourmelon C, Bourbouloux E, Patsouris A, Frenel JS and Campone M: Evaluating everolimus for the treatment of breast cancer. Expert Opin Pharmacother 24: 1105-1111, 2023.
26. André F, Ciruelos EM, Juric D, Loibl S, Campone M, Mayer IA, Rubovszky G, Yamashita T, Kaufman B, Lu YS, *et al*: Alpelisib plus fulvestrant for PIK3CA-mutated, hormone receptor-positive, human epidermal growth factor receptor-2-negative advanced breast cancer: Final overall survival results from SOLAR 1. Ann Oncol 32: 208-217, 2021.
27. Lok SW, Whittle JR, Vaillant F, The CE, Lo LL, Policheni An, Bergin ART, Desai J, Ftouni S and Gandolfo LC: A phase Ib dose-escalation and expansion study of the BCL2 inhibitor venetoclax combined with tamoxifen in ER and BCL2-positive metastatic breast cancer. Cancer Discov 9: 354-369, 2019.
28. Tiribelli M, Michelutti A, Cavallin M, Di Giusto S, Simeone E, Fanin R and Damiani D: BCL-2 expression in AML patients over 65 years: Impact on outcomes across different therapeutic strategies. J Clin Med 10: 5096, 2021.
29. Konopleva M, Pollyea DA, Potluri J, Chyla B, Hogdal L, Busman T, Mckeegan E, Salem AH, Zhu M, Ricker JL, *et al*: Efficacy and biological correlates of response in a phase II study of venetoclax monotherapy in patients with acute myelogenous leukemia. Cancer Discov 6: 1106-1117, 2016.
30. Bogenberger JM, Kornblau SM, Pierceall WE, Lena R, Chow D, Shi CX, Mantei J, Ahmann G, Gonzales IM, Choudhary A, *et al*: BCL-2 family proteins as 5-Azacytidine-sensitizing targets and determinants of response in myeloid malignancies. Leukemia 28: 1657-1665, 2014.
31. Wei AH, Strickland SA Jr, Hou JZ, Fiedler W, Lin TL, Walter RB, Enjeti A, Tiong IS, Savona M, Lee S, *et al*: Venetoclax combined with low-dose cytarabine for previously untreated patients with acute myeloid leukemia: Results from a phase Ib/II study. J Clin Oncol 37: 1277-1284, 2019.
32. DiNardo CD, Pratz K, Pullarkat V, Jonas BA, Arellano M, Becker PS, Frankfurt O, Konopleva M, Wei AH, Kantarjian HM, *et al*: Venetoclax combined with decitabine or azacitidine in treatment-naive, elderly patients with acute myeloid leukemia. Blood 133: 7-17, 2019.
33. Röllig C, Bornhäuser M, Thiede C, Taube F, Kramer M, Mohr B, Aulitzky W, Bodenstein H, Tischler HJ, Stuhlmann R, *et al*: Long-term prognosis of acute myeloid leukemia according to the new genetic risk classification of the European LeukemiaNet recommendations: Evaluation of the proposed reporting system. J Clin Oncol 29: 2758-2765, 2011.
34. Döhner H, Estey EH, Amadori S, Appelbaum FR, Büchner T, Burnett AK, Dombret H, Fenaux P, Grimwade D, Larson RA, *et al*: Diagnosis and management of acute myeloid leukemia in adults: Recommendations from an international expert panel, on behalf of the European LeukemiaNet. Blood 115: 453-474, 2010.
35. Mrózek K: Cytogenetic, molecular genetic, and clinical characteristics of acute myeloid leukemia with a complex karyotype. Semin Oncol 35: 365-377, 2008.
36. Breems DA, Van Putten WLJ, De Greef GE, Van Zelderen-Bhola SL, Gerssen-schoorl KB, Mellink CH, Nieuwint A, Jotterand M, Hagemeijer A, Beverloo HB and Löwenberg B: Monosomal karyotype in acute myeloid leukemia: A better indicator of poor prognosis than a complex karyotype. J Clin Oncol 26: 4791-4797, 2008.
37. Wierzbowska A, Wawrzyniak E, Siemieniuk-Rys M, Kotkowska A, Pluta A, Golos A, Robak T, Szarawarska M, Jaskowiec A, Duszenko E, *et al*: Concomitance of monosomal karyotype with at least 5 chromosomal abnormalities is associated with dismal treatment outcome of AML patients with complex karyotype-retrospective analysis of Polish adult leukemia group (PALG). Leuk Lymphoma 58: 889-897, 2017.
38. Estey EH: Acute myeloid leukemia: 2019 Update on risk-stratification and management. Am J Hematol 93: 1267-1291, 2018.
39. Daneshbod Y, Kohan L, Taghadosi V, Weinberg OK and Arber DA: Prognostic significance of complex karyotypes in acute myeloid leukemia. Curr Treat Options Oncol 20: 15, 2019.
40. Alcon C, Gómez Tejeda Zañudo J, Albert R, Wagle N, Scaltriti M, Letai A, Samitier J and Montero J: ER+ breast cancer strongly depends on MCL-1 and BCL-xL anti-apoptotic proteins. Cells 10: 1659, 2021.
41. Vaillant F, Merino D, Lee L, Breslin K, Pal B, Ritchie ME, Smyth GK, Christie M, Phillipson LJ, Burns CJ, *et al*: Targeting BCL-2 with the BH3 mimetic ABT-199 in estrogen receptor-positive breast cancer. Cancer Cell 24: 120-129, 2013.
42. Lindeman GJ, Fernando TM, Bowen R, Jezak KJ, Song X, Decker T, Boyle F, McCune S, Armstrong A, Shannon C, *et al*: VERONICA: Randomized phase II study of fulvestrant and venetoclax in ER-positive metastatic breast cancer post-CDK4/6 inhibitors-efficacy, safety, and biomarker results. Clin Cancer Res 28: 3256-3267, 2022.