

Changes in bowel mucosal permeability and wound healing after neoadjuvant chemotherapy

MASAHIRO HADA¹, KENJI OMURA², YASUMITSU HIRANO¹ and GO WATANABE¹

¹General and Cardiothoracic Surgery, Kanazawa University, 13-1 Takaramachi, Kanazawa 920-8641;

²Division of Surgery, Kouseiren Takaoka Hospital, 5-10 Eiraku-cho, Takaoka 933-8555, Japan

Received June 11, 2009; Accepted June 29, 2009

DOI: 10.3892/ol_00000030

Abstract. Neoadjuvant chemotherapy (NAC) with 5-fluorouracil (5-FU) and cisplatin (CDDP) is a promising approach for locally advanced gastric cancer. We investigated the influence of NAC with 5-FU/CDDP on the permeability of intestinal mucosa and wound healing. Male Sprague Dawley rats were divided into four groups (n=6). Group 1 received saline (control group) and Groups 2-4 were administered preoperative 5-FU/CDDP (NAC groups). The NAC consisted of daily intraperitoneal administration of 5-FU from day 1 to 5 and from day 8 to 12 and intravenous administration of CDDP on days 2 and 9. The rats underwent gastrotomy (1.0 cm) with a laparotomy of 3 cm in length, under general anesthesia. Seven days after surgery, the rats were orally administered with phenolsulfonphthalein (PSP), and the 24-h urinary excretion of PSP was quantified. On postoperative day 8, the bursting pressure (BP) of the gastric suture line and the tensile strength of the abdominal wound were measured. The hydroxyproline (HP) content in the tissue of the abdominal suture line was then measured, and the number of fibroblast cells in the tissue of the gastric suture line was calculated by histopathological examination. The PSP urinary excretion rate was significantly higher in Group 2 in comparison with the other groups ($P<0.05$), while the BP of a selected gastrorrhaphy region was significantly lower in Group 2 ($P<0.05$). No significant differences were noted in the HP content. NAC with 5-FU/CDDP disturbs the healing of intestinal anastomoses when the interval between chemotherapy and surgery is insufficient. Neither HP content nor fibroblast counts were correlated with BP. Consequently, NAC appeared to affect the remodeling of collagen fiber. Thus, the integrity of the intestine may play a role in intestinal wound healing.

Introduction

Complete resection of the tumor is necessary for curing gastric cancer. Macroscopic residue of the tumor is indicative of a poor patient prognosis since chemotherapy is unable to eliminate large gastric cancer cell masses. Unfortunately, a considerable number of patients with gastric cancer present locally advanced disease at diagnosis. Consequently, preoperative adjuvant chemotherapy (neoadjuvant chemotherapy, NAC), which can decrease the extent of the invasion to adjacent organs and/or decrease the number of lymph nodes involved, is considered to be a promising approach in the treatment of advanced gastric cancer.

Combined chemotherapy with TS-1 plus cisplatin (CDDP) is one of the most powerful regimens for advanced or metastatic gastric cancer. In a Japanese phase III study (SPIRITS trial) (1), TS-1/CDDP showed a median overall survival of 13 months for metastatic gastric cancer patients, which was significantly longer than the survival rate of 11 months with TS-1 alone. TS-1 is a mixed compound of tegafur, gimeracil and oteracil potassium. Tegafur is a precursor of 5-fluorouracil (5-FU), while gimeracil and oteracil have no anti-cancer effect. Consequently, TS-1/CDDP is a modified 5-FU/CDDP therapy.

Safety, as well as efficacy, are extremely important in NAC. NAC is associated with complications such as pneumonia, enterocutaneous fistula and delay of wound healing (2-5). However, the timing of 5-FU therapy for gastric cancer in relation to the surgical wound healing process has yet to be investigated.

Measurement of the urinary excretion of phenolsulfonphthalein (PSP) following oral administration is a standard method used to estimate intestinal permeability, which is correlated with mucosal integrity. The migration of fibroblasts and hydroxyproline (HP) production is essential for wound healing. Utilizing the above techniques we investigated the effect of the interval between NAC and surgery on enteric anastomotic and skin wound healing, and intestinal permeability.

Materials and methods

Twenty-four male Sprague Dawley rats weighing between 315 and 336 g were included in this study. The rats were housed under barrier-sustained conditions in temperature-

Correspondence to: Dr Masahiro Hada, General and Cardiothoracic Surgery, Kanazawa University, 13-1 Takaramachi, Kanazawa 920-8641, Japan

E-mail: mhada-gi@umin.ac.jp

Key words: neoadjuvant chemotherapy, bursting pressure, wound healing, bowel mucosal permeability test

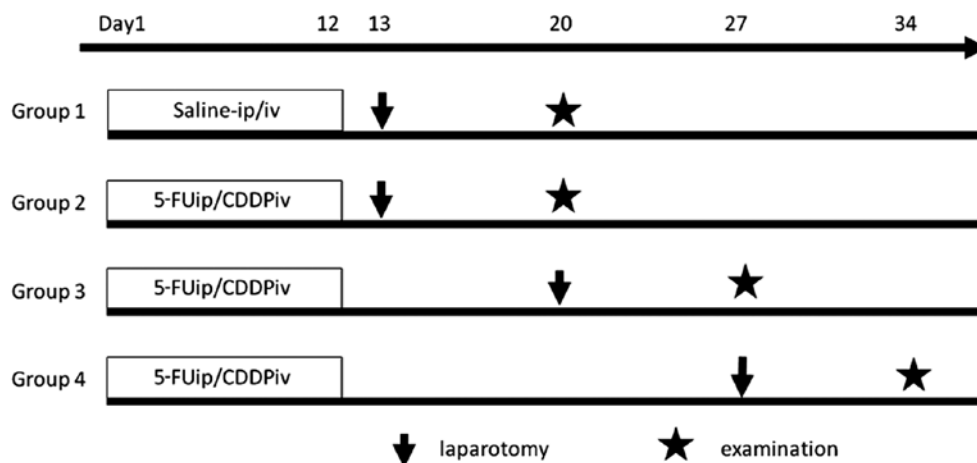


Figure 1. Schedule of chemotherapy, laparotomy and examination. ip, intraperitoneally; iv, intravenously.




Figure 2. Stomach resection and preparations for the examination. (A) The esophagus was cut at a length of 1 cm. (B) A catheter was inserted into the esophagus, and fixed in 2-0 floss. (C) The surgical suture of the gastrotomy section was removed. (D) The duodenum was ligated and separated.

controlled rooms under a light-dark cycle and fed standard rat food. Experimental protocols were approved by the National Research Council's Guide for the Care and Use of Laboratory Animals. The rats were divided into four groups, each containing 6 subjects (Fig. 1).

Group 1 (control). Animals were injected daily with 0.2 ml/kg of saline in the peritoneal cavity from day 1 to 5 and from day 8 to 12, and with 0.2 ml/kg of saline in the tail vein on days 2 and 9.

Groups 2, 3 and 4 (NAC groups). Animals were injected daily with 20 mg/kg of 5-FU (Kyowa Hakkoh, Tokyo, Japan) in the

peritoneal cavity from day 1 to 5 and from day 8 to 12, and with 2 mg/kg of cisplatin (CDDP; Nihon Chemical, Tokyo, Japan) in the tail vein on days 2 and 9.

Surgical procedure. The rats in Groups 1 and 2 underwent surgery on the day after drug administration was completed (day 13). Group 3 underwent surgery on day 20, and Group 4 on day 27.

The rats were fasted 24 h before surgery, and anesthetized with 40 mg/kg of pentobarbital sodium, intraperitoneally. Abdominal hair was shaved with electric clippers, and a laparotomic incision of 3 cm was made in the midline. A 1.0-cm incision was made on the gastric corpus, and an interrupted suture was performed using 5-0 Biocyn with 0.3-cm intervals in one layer. After closure of the gastrotomy, the small intestine was displaced from the abdominal cavity for 30 min and subsequently returned to the abdomen. The laparotomy was closed with an interrupted suture at a 0.6-cm interval in one layer using 4-0 Vicryl. The rats were placed in their cages and allowed food and drinking water from the day following the initial surgery.

Utilizing the same anesthesia technique as that mentioned above, the animals underwent a second surgical procedure on day 7, where the abdominal wall was removed (3 x 3 cm). Blood was drawn from the inferior vena cava for a serum assay, and the whole stomach was resected from the thorax-esophagus to the duodenum (Fig. 2).

Bursting pressure of the stomach. The bursting pressure (BP) of the resected stomach was measured using a blood sphygmomanometer. The end of the duodenum was tied with 2-0 silk, and a catheter was fixed to the esophagus, which was 1 cm proximal from the cardia portion. The catheter was connected to the manometer, and the segment was inflated with saline. BP was defined as the pressure level at which saline was able to spout from the resected stomach.

Tensile strength of the abdominal wound. The removed portion of the abdominal wall was fixed to one end so that the suture line was situated in the middle. A tensiometer was fixed to the other end, and was pulled. The number recorded when the

Table I. Tissue hydroxyproline levels, bursting pressure and Gut barrier function test.

	Group 1	Group 2	Group 3	Group 4
Bursting pressure (mmHg)	204.5±19	140.8±26 ^a	230.7±45	237.0±43
Tissue hydroxyproline levels (μmol/g)	43.7±5.2	41.0±6.5	42.4±4.8	41.1±4.9
Bowel mucosal permeability test (%)	15.7±2.8	24.5±6.6 ^a	13.0±4.6	14.5±3.8

Groups 1-4, n=6 each. Results are represented as the mean ± SD. ^ap<0.01, non-repeated measures ANOVA.

Table II. Fibroblast cell counts.

	Group 1	Group 2	Group 3	Group 4
Fibroblast cell number (x10 ³)	3.17±0.3	3.65±0.7	2.07±1.2	2.62±0.7

Groups 1-4, n=6 each. Results are represented as the mean ± SD. Non-repeated measures ANOVA.

tissue in the suture line began to separate was considered to be the tensile strength.

Measurement of tissue hydroxyproline levels. For the measurement of the tissue HP level, a sample (3 x 0.7 cm) was taken from the abdominal wall incision line and was preserved in deep freeze at -83°C. Tissue HP levels were measured using the method of direct dissolution with HCl (SRL Inc., Tokyo). The samples were weighed, hydrolyzed with 6 N HCl, and ion exchange water was added. The samples were then hydrolyzed at 100°C for 20 h. A 0.1-ml portion of the hydrolyzed sample was removed, added and mixed with 1.5 ml of 0.3 N LiOH. The sample was then analyzed by high performance liquid chromatography. The HP concentration in the tissue was calculated using the formula: HP (μmol/g) = [measured HP (μmo/l) x volume of HCl (ml)]/[weight of wet tissue (g) x 1000]

Bowel mucosal permeability test. The rats were fasted for 24 h prior to the initial surgery, after which 10 mg of phenolsulfonphthalein (PSP; Daiichi Sankyo, Tokyo, Japan) was orally administered to the animals. The 24-h urinary excretion of PSP was then quantified. The collected urine was alkalized in 0.2 ml of 1 N NaOH and brought to a volume of 200 ml with distilled water. The PSP concentration was then determined using a spectrophotometer at 562 nm.

Fibroblast cell counts. Four different sections were removed from the gastric suture line for each animal, and fibroblast cells were counted in a x40 magnification area. The total of these counts was recorded. Paraffin blocks of the tissue samples removed from the gastric suture line were prepared by staining with α-smooth muscle actin (α-SMA). Adobe Photoshop software was used to select SMA-positive cells. The quantitative parameters were assessed using WinROOF image-processing software (Mitani Corp., Tokyo, Japan).

Measurement of blood cell and serum biochemical parameters. Total leukocyte count (TCL), blood hemoglobin (Hb), blood

platelet (Plt), serum total protein (TP), serum albumin (Alb), serum basic-FGF and serum TGF-β were assayed for each rat. Basic-FGF and TGF-β were measured at SRL Inc., while any remaining measurements were carried out in the laboratory division of Kanazawa University.

Statistical analysis. Results were expressed as the mean ± SD. BP, HP and PSP were analyzed using non-repeated measures analysis of variance. P<0.05 was accepted as statistically significant.

Results

Bursting pressure of the gastric suture line. BP of the gastric suture line in Group 2 was 140.8±26 mmHg, which was significantly lower than that in the other groups (Table I; P<0.01). In Group 2, the stomach exploded at the suture line, while in the other groups, the stomach exploded at the gastric fundus upon compression.

Tensile strength of the abdominal wound. The tensile strength of the abdominal wound was above the upper limit of measurement in all of the groups.

Measurement of tissue hydroxyproline levels. No significant differences were noted in the HP of the abdominal wall in Groups 1-4 (Table I; P=0.34).

Bowel mucosal permeability test. The urinary excretion ratio of PSP in Group 2 was 24.5±6.6%, which was significantly higher than that in the other groups (Table I; P<0.01).

Fibroblast cell counts. No significant differences were noted in the fibroblast cell counts of the stomach wall in Groups 1-4 (Table II; P=1.75).

Measurement of blood cell and serum biochemical parameters. The serum levels of basic FGF were below the lower

Table III. Biochemical parameters of blood cells and serum.

	Group 1	Group 2	Group 3	Group 4
WBC ($\times 10^3/\text{mm}^3$)	7.21 \pm 2.1	6.26 \pm 2.8	6.06 \pm 0.9	6.95 \pm 1.7
RBC ($\times 10^2/\text{mm}^3$)	7.82 \pm 0.4	7.05 \pm 0.8	7.06 \pm 1.0	7.21 \pm 0.6
Hb (g/dl)	13.7 \pm 0.4	12.7 \pm 1.2	13.3 \pm 1.3	13.3 \pm 0.6
HCT (%)	43.1 \pm 1.2	41.2 \pm 2.6	42.9 \pm 2.6	42.7 \pm 2.0
Plt ($\times 10^4/\text{mm}^3$)	9.56 \pm 2.1	13.2 \pm 1.6 ^a	13.9 \pm 3.1 ^a	10.7 \pm 3.3
TP (g/dl)	6.03 \pm 0.2	5.91 \pm 0.4	6.06 \pm 0.3	5.9 \pm 0.1
Alb (g/dl)	0.75 \pm 0.1	0.73 \pm 0.1	0.77 \pm 0.1	0.68 \pm 0.1
TGF- β (ng/ml)	36.8 \pm 21	40.1 \pm 17	58.7 \pm 59	58.0 \pm 21
Basic FGF (pg/ml)	<10	<10	<10	<10

Groups 1-4, n=6 each. Results are presented as the mean \pm SD. ^ap<0.01, non-repeated measures ANOVA. WBC, white blood cells; RBC, red blood cells; Hb, blood hemoglobin; HCT, hematocrit; Plt, blood platelet; TP, serum total protein and Alb, serum albumin.

limit of measurement in all of the groups. No significant differences were found in TLC, Hb, TP, Alb and TGF- β in Groups 1-4. The Plt of Group 2 was $13.2 \pm 1.6 \times 10^4/\text{mm}^3$ and that of Group 3 was $13.9 \pm 3.1 \times 10^4/\text{mm}^3$, which was higher than Group 1 (Table III; P<0.01).

Discussion

NAC is a promising approach in the treatment of gastric cancer when R0 resection is difficult. NAC has various advantages compared to postoperative adjuvant chemotherapy. Drug delivery to the lesions is preferable since blood vessels are still preserved. When the tumor stage is reduced, the possibility of R0 resection increases. Furthermore, the sensitivity of the tumor to the regimen can be determined histopathologically using the resected specimens. However, besides the aforementioned benefits, disadvantages exist as well.

Gastrointestinal (GI) toxicities are common adverse effects of cancer chemotherapy. 5-FU, one of the most frequently used drugs in chemotherapy for gastric and colorectal cancer, sometimes shows severe GI toxicities (6). It is known that 5-FU causes a decrease in the height of intestinal villi on the one hand, but an increase in intestinal secretion and diarrhea on the other. The decrease in the height of villi indicates the derangement of numerous mucosal functions, including barrier function and regeneration.

In this study, BP of the stomach showed a significant decrease in Group 2 compared with the other three groups. Furthermore, in this study, no rupture occurred in the gastric suture lines of Groups 1, 3 and 4, while an interval of one week appears to be adequate for recovery of the wound healing ability of the gastric suture line.

Hananel *et al* (7) reported that the preoperative administration of 5-FU beginning 4 weeks prior to surgery had no effect on the healing of colonic anastomoses. Sahin *et al* (8) reported that in colorectal diseases wound healing was impaired in rats undergoing chemotherapy, but following the second week after chemotherapy, disrupted parameters returned to their normal levels.

In spite of the fragility of the gastric suture line, the fibroblast counts in this suture line did not differ in the four groups. Furthermore, the HP concentration in the abdominal wound in Group 2 was comparable to that of the other three groups. Since the HP concentration is a reliable indicator of collagen synthesis (6,9,10), the fragility of the gastric suture line in Group 2 did not result from impairment of fibroblast migration or collagen production. These findings suggest that the delay of wound healing following chemotherapy was due to the impairment of collagen remodeling.

Several animal studies have shown TGF- β to play a role in adhesion formation. TGF- β expression has been correlated with the pathogenesis of several fibrotic disorders such as skin scarring. It is secreted early in the immune cascade and stimulates the release of other pro-inflammatory mediators. However, the immunosuppressor often used after organ transplantation and reflected by a decrease in TGF- β levels, resulted in a decrease in postsurgical adhesion formation (11). Basic FGF is recognized as one of the most common angiogenic growth factors. Additionally, Kuhn *et al* (12) reported that the release of basic FGF was indicative of chemosensitivity in lung cancer patients. In this study, no significant difference was noted for serum TGF- β or basic FGF in the four groups. From these data, it appears that both TGF- β and basic FGF are not involved in the delay of wound healing following chemotherapy.

The urinary PSP excretion rate following oral administration is one of the indicators of intestinal mucosal permeability (13,14). We reported an increase in the urinary PSP excretion rate in rats that underwent surgery after total parenteral nutrition was administered. Such an increase in the urinary PSP excretion rate may be an indicator of decreased mucosal integrity. Moreover, an increase in the urinary PSP excretion rate was observed along with a simultaneous decrease in IgA-positive mucosal cell number and serum diamine oxidase activity (15). Nakamura *et al* (16) reported that the recovery rate of PSP correlated well with the extent of mucosal damage in the small intestine of the rat. In this study, the urinary PSP excretion rate showed a significant increase in Group 2 compared with the other three groups. These findings suggest that

the permeability of intestinal mucosa is an indicator of wound healing ability following chemotherapy.

The clinical effects of neoadjuvant chemotherapy for locally advanced gastric cancer are currently under investigation. As various powerful regimens against gastric cancer have been developed, NAC should improve the clinical outcome of patients with locally advanced gastric cancer. However, it is crucial to perform NAC without increased morbidity or mortality. Thus, our findings show that mucosal permeability may be a good indicator of wound healing ability following NAC. However, further studies are required to clarify the optimal interval between NAC and surgery for human patients.

Acknowledgements

The authors wish to thank Dr You Zen and the staff at the Pathology Department for the staining of the specimens.

References

1. Koizumi W, Narahara H, Hara T, Takagane A, Akiya T, Takagi M, Miyashita K, Nishizaki T, Kobayashi O, Takiyama W, Toh Y, Nagaie T, Takagi S, Yamamura Y, Yanaoka K, Orita H and Takeuchi M: S-1 plus cisplatin versus S-1 alone for first-line treatment of advanced gastric cancer (SPIRITS trial): a phase III trial. *Lancet Oncol* 9: 215-221, 2008.
2. Biert J, Seifert W, de Man B, Wobbes T, Hoogenhout J and Hendriks T: Combined preoperative irradiation and local hyperthermia delays early healing of experimental colonic anastomoses. *Arch Surg* 131: 1037-1042, 1996.
3. Graf W, Weiber S, Glimelius B, Jiborn H, Pahlman L and Zederfeldt B: Influence of 5-fluorouracil and folinic acid on colonic healing: an experimental study in the rat. *Br J Surg* 79: 825-828, 1992.
4. Morris T: Retardation of healing of large-bowel anastomoses by 5-fluorouracil. *Aust NZ J Surg* 49: 743-745, 1979.
5. Goldman LI, Lowe S and al-Saleem T: Effect of fluorouracil on intestinal anastomoses in the rat. *Arch Surg* 98: 303-304, 1969.
6. Weiber S, Graf W, Glimelius B, Jiborn H, Pahlman L and Zederfeldt B: Experimental colonic healing in relation to timing of 5-fluorouracil therapy. *Br J Surg* 81: 1677-1680, 1994.
7. Hananel N and Gordon PH: Effect of 5-fluorouracil and leucovorin on the integrity of colonic anastomoses in the rat. *Dis Colon Rectum* 38: 886-890, 1995.
8. Sahin M, Erikoglu M, Ozer S, Tekin A, Boz S, Golcuk M, Avunduk MC and Aköz M: Determination of operation time in colorectal diseases: preoperative chemotherapy application. *J Surg Res* 124: 209-215, 2005.
9. Jiborn H, Ahonen J and Zederfeldt B: Healing of experimental colonic anastomosis. III. Collagen metabolism in the colon after left colon resection. *Am J Surg* 139: 398-405, 1980.
10. Hendriks T and Mastboom WJB: Healing of experimental intestinal anastomoses. Parameters for repair. *Dis Colon Rectum* 33: 891-901, 1990.
11. Wasserberg N, Nunoo-Mensah JW, Ruiz P and Tzakis AG: The effect of immunosuppression on peritoneal adhesion formation after small bowel transplantation in rats. *J Surg Res* 141: 294-298, 2007.
12. Kuhn H, Weser L, Gessner C, Hammerschmidt S and Wirtz H: Release of bFGF following apoptosis and necrosis in NSCLC cells: Effects on chemosensitivity to cisplatin. *Oncol Rep* 14: 759-762, 2005.
13. Inutsuka S, Takesue F, Yasuda M, Honda M, Nagahama S, Kusumoto H, Nozoe T and Korenaga D: Assessment of the intestinal permeability following postoperative chemotherapy for human malignant disease. *Eur Surg Res* 35: 22-25, 2003.
14. Toh Y, Korenaga D, Maekawa S, Matsumata T, Muto Y, Ikeda T and Sugimachi K: Assessing the permeability of the gastrointestinal mucosa after oral administration of phenolsulfonphthalein. *Hepatogastroenterology* 44: 1147-1151, 1997.
15. Ohta K, Omura K, Hirano K, Kanehira E, Ishikawa N, Kato Y, Kawakami K and Watanabe G: The effects of an additive small amount of a low residual diet against total parenteral nutrition-induced gut mucosal barrier. *Am J Surg* 185: 79-85, 2003.
16. Nakamura J, Yoshizaki Y, Yasuhara M, Kimura T and Muranishi S: Mechanisms of the absorption of water-soluble dyes from the rat small intestine. *Chem Pharm Bull* 24: 683-690, 1976.