ONCOLOGY REPORTS 16: 25-31, 2006

SPANDIDOS PUBLICATIONS

Effect of hepatocyte growth factor on endogenous hepatocarcinogenesis in rats fed a choline-deficient L-amino acid-defined diet

CHIHIRO NAKANISHI[1], AKIHIRO MORIUCHI[2], AKIO IDO[2], MASATSUGU NUMATA[1,2], IL-DEOK KIM[2], KAZUNORI KUSUMOTO[1], SATORU HASUIKE[1], HIROO ABE[1], KENJI NAGATA[1], YUTAKA AKIYAMA[3], HIROFUMI UTO[1], HIROAKI KATAOKA[3] and HIROHITO TSUBOUCHI[1,2,4]

[1]Department of Internal Medicine II, Faculty of Medicine, University of Miyazaki, 5200 Kihara, Kiyotake, Miyazaki 880-1601; [2]Department of Experimental Therapeutics, Translational Research Center, Kyoto University Hospital, 54 Shogoin-Kawahara-cho, Sakyo-ku, Kyoto 606-8507; [3]Second Department of Pathology, Faculty of Medicine, University of Miyazaki, 5200 Kihara, Kiyotake, Miyazaki 880-1601; [4]Department of Digestive Disease and Life-style related Disease, Kagoshima University Graduate School of Medical and Dental Sciences, 8-35-1 Sakuragaoka, Kagoshima 890-8520, Japan

Received December 13, 2005; Accepted February 15, 2006

Abstract. Hepatocyte growth factor (HGF) is a promising agent for the treatment of intractable liver disease, due to its mitogenic, anti-apoptotic, and anti-fibrotic effects. We investigated the effect of recombinant human HGF (rh-HGF) on the development of both hepatocellular carcinoma (HCC) and preneoplastic nodules in rats fed a choline-deficient L-amino acid-defined (CDAA) diet, an animal model of hepatocarcinogenesis resembling human development of HCC with cirrhosis. From weeks 13 to 48 of the CDAA diet, rh-HGF (0.1 or 0.5 mg/kg/day) was administered intravenously to rats in four-week cycles, with treatment for five consecutive days of each week for two weeks, followed by a two-week washout period. Treatment with rh-HGF significantly inhibited the development of preneoplastic nodules in a dose-dependent manner at 24 weeks. Although the numbers and areas of the preneoplastic nodules in rats treated with rh-HGF were equivalent to those in mock-treated rats by 60 weeks, the incidence of HCC was reduced by HGF treatment. Although one rat treated with low-dose rh-HGF exhibited a massive HCC, which occupied almost the whole liver, and lung metastases, HGF treatment did not increase the overall frequency of HCC. Administration of high-dose rh-HGF, however, induced an increase in the urinary excretion of albumin, leading to decreased serum albumin at 60 weeks. These results indicate that long-term administration of rh-HGF does not accelerate hepatocarcinogenesis in rats fed a CDAA diet. However, these findings do not completely exclude the potential of HGF-induced hepatocarcinogenesis; this issue must be resolved before rh-HGF can be used for patients with intractable liver diseases, especially those with cirrhosis.

Correspondence to: Dr Akio Ido, Department of Experimental Therapeutics, Translational Research Center, Kyoto University Hospital, 54 Shogoin-Kawahara-cho, Sakyo-ku, Kyoto 606-8507, Japan
E-mail: akioido@kuhp.kyoto-u.ac.jp

Key words: hepatocyte growth factor, hepatocarcinogenesis, choline-deficient, L-amino acid

Introduction

Hepatocyte growth factor (HGF), originally isolated from the plasma of patients with fulminant hepatic failure, was identified as a potent mitogen for hepatocytes (1,2). HGF is a multifunctional growth factor that acts as a mitogen, motogen, and morphogen for a wide variety of cells, including epithelial and endothelial cells (3-6). In addition to promoting hepatocyte proliferation (7-9), this factor acts in concert with transforming growth factor (TGF)-α and heparin-binding epidermal growth factor during liver regeneration (10,11). HGF also ameliorates hepatic injury by stimulating anti-apoptotic effects in animal models of fulminant hepatic failure (12-18) and attenuating hepatic fibrosis in animals with liver cirrhosis (19-23). Consequently, HGF may induce liver regeneration, inhibit disease progression, and ameliorate hepatic fibrosis in patients suffering from intractable liver disease.

We have established an enzyme-linked immunosorbent assay to measure serum levels of human HGF. Using this assay, we identified increased serum HGF levels in patients with a variety of liver diseases (24). Serum HGF levels are a valuable prognostic tool in fulminant hepatic failure (25). We attempted to develop an innovative therapy using recombinant human HGF (rh-HGF) for the treatment of fatal liver diseases, including fulminant hepatic failure, small-for-size liver grafts in living donors, and liver cirrhosis. We recently demonstrated that bolus intravenous injection of rh-HGF led to increased serum levels of human HGF, which primarily distributed to the

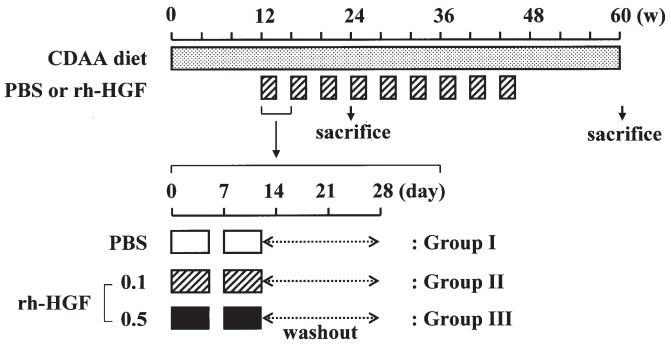

Figure 1. Experimental protocol. After a one-week acclimation period, rats were fed a CDAA diet for 60 weeks. After 12 weeks of diet administration, rh-HGF (0.1 or 0.5 mg/kg/day) or PBS was injected intravenously into rats for five consecutive days of the week for two weeks, followed by a two-week washout period. This four-week treatment was repeated from weeks 13 to 48 of CDAA diet administration. Rats were sacrificed at 24 and 60 weeks.

liver (26). Despite its short half-life, a single intravenous injection of rh-HGF induced the tyrosine phosphorylation of c-Met, the specific receptor for HGF, in liver tissues. It is necessary, however, to resolve whether repeated intravenous injection of rh-HGF accelerates hepatocarcinogenesis before clinical application of rh-HGF can proceed to the treatment of intractable liver diseases, especially cirrhosis, in which hepatocellular carcinoma (HCC) develops at a high incidence.

In rats fed a choline-deficient L-amino acid-defined (CDAA) diet, HCC develops without any exposure to exogenous carcinogens (27). This animal model of hepatocarcinogenesis is an appropriate experimental system, as HCC occurs in conjunction with fatty liver, hepatocyte death, and subsequent regeneration, fibrosis, and eventual cirrhosis (28), a similar progression to the histopathological sequence of human HCC development with cirrhosis.

In this study, we administered rh-HGF intravenously to rats fed a CDAA diet for an extended period (36 weeks). We then investigated the effect of HGF treatment on the development of preneoplastic nodules and HCC, which arises from neoplastic nodules, induced by long-term (60 weeks) administration of a CDAA diet.

Materials and methods

Animals. Six-week-old male Fischer 344 rats were obtained from Kyushu Experimental Animal Supply (Kumamoto, Japan). Animals were maintained at a constant room temperature (25˚C) and provided free access to water and the food indicated throughout the study. The protocols for these animal studies were approved by the ethics committee of the University of Miyazaki (Miyazaki, Japan).

Experimental protocol. After a one-week acclimation period on a standard diet, rats were switched to a CDAA diet (Dyets Inc., Bethlehem, PA). After a 12-week administration of the CDAA diet, rh-HGF (0.1 or 0.5 mg/kg/day) (Mitsubishi Pharma Co., Tokyo, Japan) or phosphate-buffered saline (PBS) was injected intravenously into rats on five consecutive days of a week for two weeks, followed by a two-week washout from rh-HGF or PBS treatment (Fig. 1). This four-week treatment was repeated from weeks 13 to 48 of the CDAA diet administration. The rats were sacrificed at weeks 24 and 60. Blood was obtained from the bifurcation of the abdominal aorta, from which we determined platelet counts, and the serum levels of alanine aminotransferase (ALT), albumin, total cholesterol (T-Chol), hyaluronic acid, and creatinine. We also measured the urinary excretion of albumin. The liver, spleen, and bilateral kidneys were immediately excised after sacrifice; the wet weight of these organs was then determined. Samples were subjected to histological analysis or frozen in liquid nitrogen and stored at -80˚C until analysis. After 60 weeks of CDAA diet administration, rats were maintained in metabolic cages, allowing quantitative urine collection for three consecutive days that was used for the measurement of albumin excretion.

Table I. Effect of rh-HGF administration on the weights of the total body, liver, and kidneys in rats fed a CDAA diet for 60 weeks.

Group	n	Body (g)	Liver (g/100 g body wt.)	Kidneys (g/100 g body wt.)
I	14	368±62	4.43±0.45	0.69±0.07
II	16	369±46	4.57±0.72	0.72±0.09
III	13	300±51[a]	5.56±1.82[b]	0.93±0.15[c]

The data are mean ± SD. [a]p=0.0053 or 0.0038 vs. I or II, respectively; [b]p=0.0403 vs. I; [c]p<0.0001 vs. I and II.

Histopathological and immunohistochemical analysis. To evaluate the development of hepatocellular carcinoma (HCC), 5-mm thick slices of whole liver were fixed in 10% formalin and embedded in paraffin. A 2-μm section, prepared from each fixed liver slice, was then stained with hematoxylin and eosin (H&E). Histological examinations were performed independently by two investigators blinded to the protocol. HCC was diagnosed according to well-established criteria (29).

We examined the development of precancerous lesions, which are positive for the placental form of rat liver glutathione S-transferase (GST-P), in three 5-mm thick slices obtained from the three major liver lobes (left lateral and the left and right median lobes). A 4-μm section prepared from each fixed liver slice was subjected to immunohistochemical analysis as described (28). Briefly, after boiling in distilled water for 10 min, slides were incubated with a rabbit polyclonal antibody against GST-P (Medical and Biological Laboratories, Nagoya, Japan). After application of goat anti-rabbit IgG (Nichirei Co., Tokyo, Japan), slides were treated with avidin-biotin-peroxidase complex and chromatin 3',3'-diaminobenzidine. The number of GST-P positive nodules was counted; the area of each nodule was measured using Image-Pro Plus software (version 4.5.1.28; Media Cybernetics Inc, MD, USA).

RNA isolation and quantitative reverse transcription (RT)-PCR. We utilized quantitative PCR to examine the expression of albumin mRNA. Total RNA was extracted from rat liver tissues using Isogen reagent (Nippon Gene Co., Toyama,

Effect of rh-HGF on biochemical markers in rats fed a CDAA diet for 60 weeks.

Group	n	ALT (IU/L)	s-Alb (g/dl)	T-Chol (mg/dl)	Plt (10^4/mm^3)	HA (ng/ml)	Cre (mg/dl)	u-Alb (mg/day)
I	14	99±31	4.4±0.3	68±15	58.1±10.1	47±7	0.28±0.08	33.3±11.6
II	15	126±83	4.0±0.4	87±35	59.0±10.0	56±18	0.29±0.10	40.9±20.5
III	13	65±22[a]	3.2±0.6[b]	135±30[c]	70.0±14.8[d]	66±37	0.21±0.15	127.3±18.3[b]

The data are mean ± SD. ALT, alanine aminotransferase; s-Alb, serum albumin; T-Chol, total cholesterol; Plt, platelet count; Cre, serum creatinine; u-Alb, urinary excretion of albumin. [a]p=0.0188 vs. II; [b]p<0.0001 vs. I and II; [c]p<0.0001 or =0.0003 vs. I or II, respectively; [d]p=0.0425 vs. I.

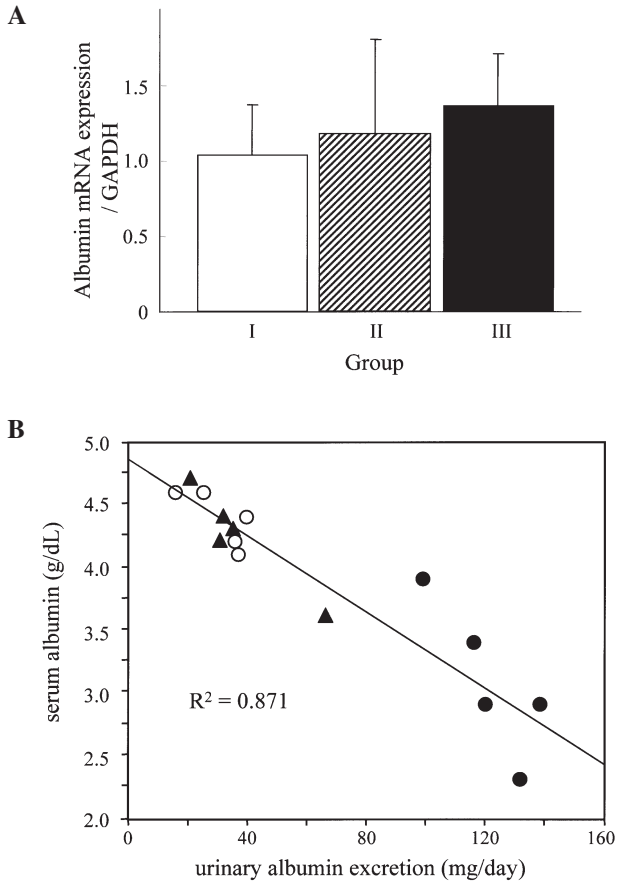

Figure 2. Hepatic expression of albumin mRNA in rats fed a CDAA diet, and the relationship between serum levels and urinary excretion of albumin. (A) Expression of albumin mRNA in liver tissues was examined by real-time RT-PCR. In comparison to mock-treated rats [group I (n=5); open column], albumin expression was unaffected by HGF administration [group II (n=5) and III (n=5); hatched and closed columns, respectively]. (B) Serum levels of albumin inversely correlated with urinary excretion of albumin. Group I, open circles; group II, triangles; group III, closed circles.

Japan). Total RNA (0.5 μg) was reverse transcribed using random hexamer priming in the presence of MMLV reverse transcriptase. PCR reactions combined TaqMan Universal PCR master mix, containing PCR primers and fluorogenic probes specific for rat albumin (Applied Biosystem, Foster City, CA), and 2.5 μl cDNA in a total volume of 25 μl. PCR amplification was performed in triplicate using the following temperature and cycling profile: after an initial incubation at 50˚C for 2 min and then at 95˚C for 10 min, we performed 40 cycles of 95˚C for 15 sec and 60˚C for 60 sec. Albumin transcripts, quantitated using an ABI PRISM 7700 Sequence detection system (Applied Biosystem), were normalized to the levels of amplified glyceraldehyde-3-phosphate dehydrogenase (GAPDH) mRNA.

Statistical analysis. Statistical analysis was performed using Statview J-4.5 software (Abacus Concepts, Inc., Berkeley, CA). Data are expressed as means ± SD. Normally distributed variables in different groups were compared by analysis of variance, while comparisons were performed using Fisher's PLSD or the Scheffè F test. The inter-group difference was considered to be statistically significant when the p-value was <0.05.

Results

Effect of rh-HGF on the weights of the body, liver, and kidneys in rats fed a CDAA diet. The weights of the total body, the liver, and the bilateral kidneys were measured after CDAA administration for 60 weeks (Table I). Repeated injections of rh-HGF at a low dose (0.1 mg/kg/day) (group II) did not affect these values in comparison to the mock-treated rats (group I). Rats treated with a high dose (0.5 mg/kg/day) of rh-HGF (group III); however, exhibited a significant decrease in body weight and a significant increase in the weights of the liver and kidneys.

Effect of rh-HGF on biochemical markers in rats given a CDAA diet. We also examined biochemical markers, platelet counts, and urinary excretion of albumin in rats fed the CDAA diet for 60 weeks (Table II). When compared to the mock-treated group (group I), administration of rh-HGF at a low dose (group II) did not significantly impact the expression of biochemical marker, platelet counts, or urinary excretion of albumin. In group III, however, administration of rh-HGF at a high dose decreased serum ALT levels and increased T-Chol and platelet counts. The serum levels of hyaluronic acid and creatinine were not affected. Decreases in serum albumin and increases in urinary excretion of albumin were also induced by this treatment. This result prompted us to examine hepatic expression of albumin and the relationship between serum levels and urinary excretion of albumin (Fig. 2). Although treatment with rh-HGF did not affect albumin expression in the liver (Fig. 2A), we observed an inverse correlation between

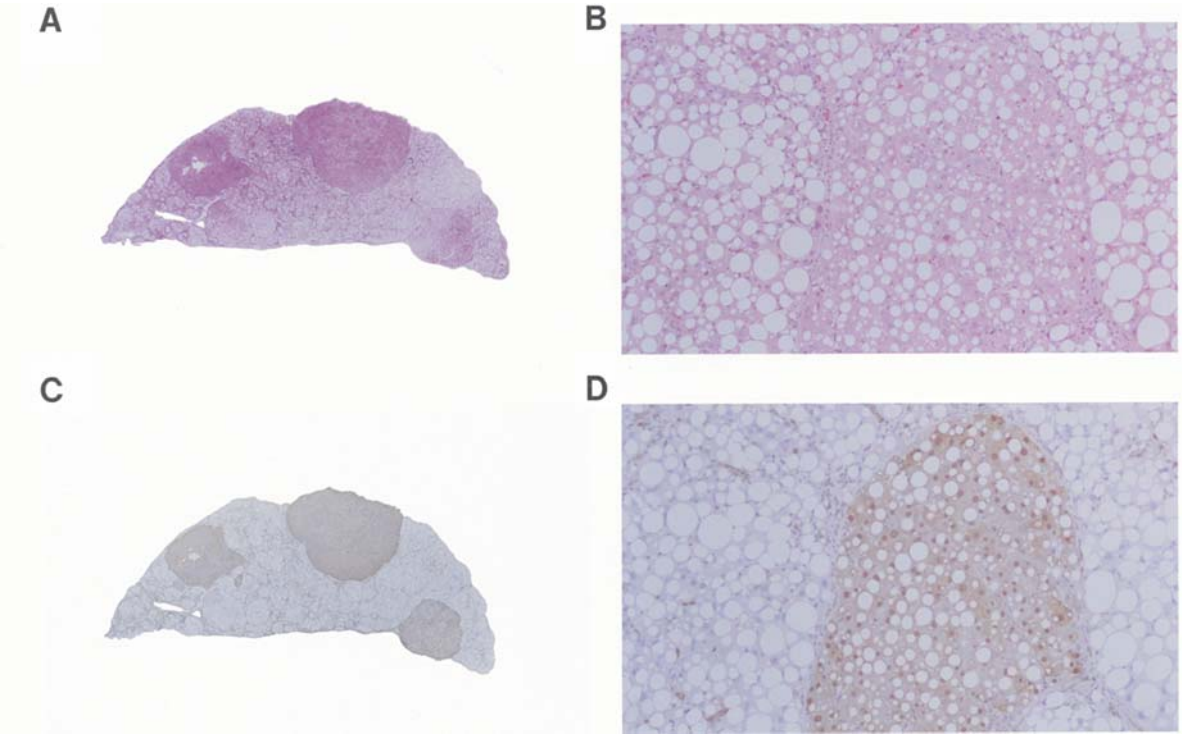

Figure 3. Representative photographs of liver derived from a rat fed a CDAA diet for 24 weeks. A section of liver tissue was stained with both H&E (A and B) and an anti-GST-P antibody (C and D). The development of liver cirrhosis and GST-P-positive preneoplastic nodules were observed in rats fed a CDAA diet for 24 weeks (group I) [original magnifications x100 (B and D)].

serum levels and urinary excretion of albumin (Fig. 2B). These results indicate that the observed decrease in serum albumin results primarily from the urinary loss of albumin, which is induced by repeated administration with high-dose rh-HGF.

Administration of rh-HGF suppressed the early development of preneoplastic lesions in rats fed a CDAA diet. In rats given a CDAA diet, collagen fibers began to extend at four weeks, which was shortly followed by the development of cirrhosis.

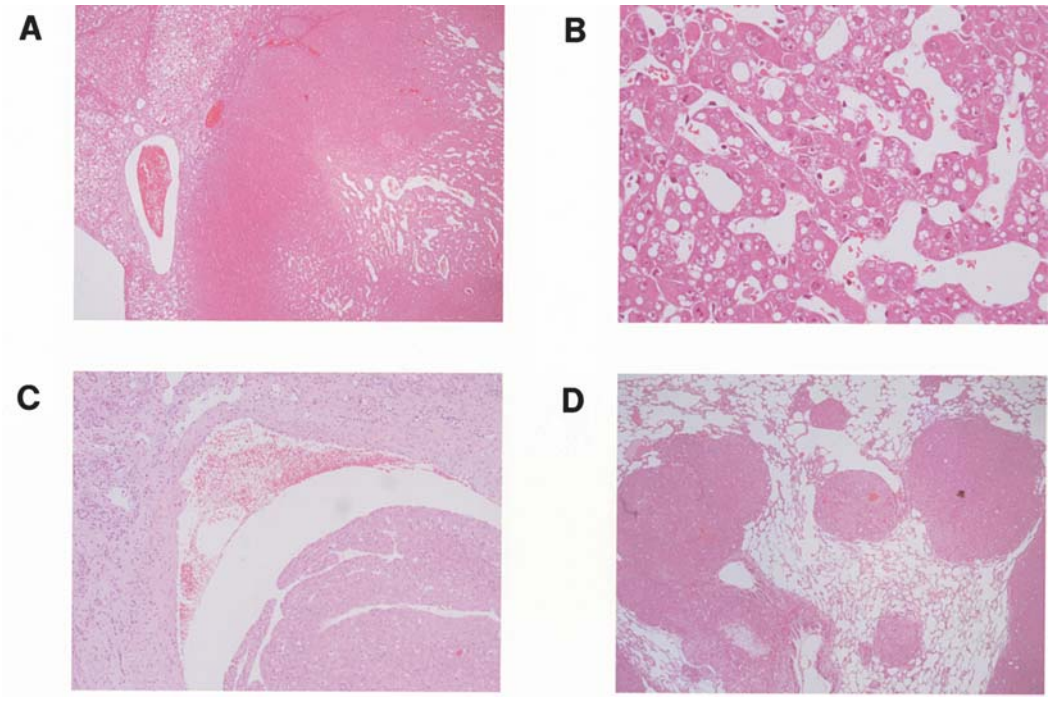

Figure 4. Representative microphotographs of the HCCs and metastatic lung tumors developing in rats treated with rh-HGF. (A and B) HCC lesions developed in rats fed a CDAA diet, who were treated with high-dose rh-HGF (group III) [magnifications x40 (A) and x400 (B)]. Cellular atypia, irregular shapes, and trabecular patterns were observed. Necrosis was also present within the HCC lesion. One of the seven animals treated with low-dose rh-HGF exhibited a large HCC lesion, which occupied the majority of the liver and invaded into the large hepatic vein (C), as well as lung metastases (D) [magnifications x40 (C and D)].

Effect of rh-HGF administration on the development of GST-P-positive preneoplastic nodules in rats fed a CDAA diet.

	24 weeks				60 weeks			
Group	n	Number/body	Area (%)	p-value (vs. I)	n	Number/body	Area (%)	p-value (vs. I)
I	4	17.5±4.7	20.2±8.0	-	14	44.2±8.7	20.3±9.3	-
II	4	15.3±3.3	7.4±4.2	0.033	16	40.6±16.8	21.7±12.0	0.917
III	4	18.0±2.9	8.0±3.7	0.040	13	34.2±13.5	16.6±5.6	0.606

The data are mean ± SD.

Table IV. Effect of rh-HGF on HCC development in rats fed a CDAA diet for 60 weeks.

		Incidence			
Group	n	n (%)	p-value (vs. I)	Number/ body	HCC area (%)
I	14	8 (57.1)		1.8±0.9	1.5±1.8
II	16	7 (43.8)	0.464	2.1±1.9	7.9±14.4
III	13	3 (23.1)	0.071	1.3±0.6	0.6±0.4

The data are mean ± SD.

Preneoplastic nodules positive for GST-P were observed in a small number of rats fed the CDAA diet for four weeks (28). In this study, all rats exhibited liver cirrhosis and GST-P-positive nodules by 24 weeks (Fig. 3). To determine the effects of rh-HGF administration on the development of GST-P-positive nodules, we examined the numbers and areas of preneoplastic nodules positive for GST-P in rats given a CDAA diet at 24 and 60 weeks (Table III). Although treatment with rh-HGF did not affect the number of GST-P positive nodules at 24 weeks, the average areas of these nodules were reduced following both low- and high-dose rh-HGF administration. At 60 weeks of CDAA diet administration, treatment with low-dose rh-HGF (group II) did not affect the number or area of GST-P positive nodules from the values observed in group I. High-dose rh-HGF administration, however, appeared to inhibit the development of GST-P-positive nodules, although there was no statistical significance of this inhibition in comparison to either group I or II.

Treatment with rh-HGF does not accelerate development of HCCs in rats given a CDAA diet for 60 weeks. Multiple GST-P-positive nodules develop into HCCs during a long-term administration of a CDAA diet. These developing HCCs, which exhibit cellular atypia, irregular shapes, and trabecular patterns (Fig. 4A and B), were observed in a proportion of the rats at 60 weeks. To clarify the effect of rh-HGF administration on HCC development, we examined the incidence, number, and area of HCC lesions in rats fed a CDAA diet for 60 weeks (Table IV). Although these values were not statistically significant, the incidence of HCCs was reduced in a dose-dependent manner following HGF treatment. The number of HCC lesions per animal was not affected by rh-HGF administration, regardless of the dose. In comparison to rats in group I with HCCs, treatment with high-dose rh-HGF did not affect the average area of HCC lesions in tumor-bearing rats. In group II, one of the seven rats exhibited massive HCCs, which occupied the majority of the liver and invaded into the large hepatic vein, in addition to a number of lung metastases (Fig. 4C and D). This animal increased the average HCC area of this group significantly (Table IV).

Discussion

Increased rates of benign and malignant tumor formation occur in the livers and mammary glands of HGF transgenic mouse strains (30-33). In addition, both diethylnitrosamine-induced hepatocarcinogenesis and ultraviolet radiation-induced skin carcinogenesis are accelerated in these mice (33-35), suggesting that prolonged and continuous exposure to HGF may accelerate neoplastic development in multiple organs. Transgenic mice specifically overexpressing HGF in the liver, however, do not develop HCC; the development of hepatic neoplasms induced by either TGF-α or c-myc overexpression was inhibited in these mice (36,37). Several investigators have examined the effect of a recombinant form of HGF lacking five amino acids (dHGF) (38) on the development of preneoplastic nodules or HCC in rat models of carcinogen-induced hepatocarcinogenesis. Although administration of recombinant dHGF stimulated DNA synthesis in preneoplastic nodules, this treatment inhibited cell proliferation of HCCs in a rat model of hepatocarcinogenesis induced by either diethylnitrosamine (DEN) or 3'-methyl-4-dimethylaminoazobenzene (39,40). Yaono *et al* reported that recombinant dHGF enhanced the development of preneoplastic hepatic foci in rats treated with the combination of DEN and N-ethyl-N-hydroxyethylnitrosamine (41). In this study, we administered rh-HGF to a rat model of hepatocarcinogenesis induced by the CDAA diet. Treatment with rh-HGF inhibited the development of preneoplastic nodules at 24 weeks of diet administration. As not all neoplastic nodules develop into HCC, we evaluated the effect of HGF administration on the development of HCC at 60 weeks. Despite the fact that these values were not statistically significant, HGF treatment reduced the overall incidence of HCC development. Although HGF treatment did not affect the development of preneoplastic nodules at 60 weeks, the inhibition of preneoplastic nodule development at 24 weeks

may contribute to the reduced incidence of HCC in rh-HGF rats at CDAA-60 weeks. HGF is known to function as both a mitogenic and anti-apoptotic agent, but also appears to induce apoptosis in a subset of malignant cells, such as sarcomas (42,43). Oxidative stress is likely involved in mechanism by which HGF suppresses the growth of tumor cells (44). Therefore, HGF may act as an apoptotic agent *in vivo* for HCC cells developing within the livers of rats fed a CDAA diet. The precise mechanism governing these reciprocal functions, mitogenesis and the induction of apoptosis in non-malignant and malignant cells, respectively, remains poorly understood.

One of seven rats bearing HCCs in group II exhibited a number of massive HCCs, which occupied the majority of the liver, in the presence of lung metastases. The incidence of HCC tended to be reduced following HGF treatment in comparison to mock-treated rats (group I). In addition, the number and areas of the observed HCC lesions were not increased by treatment with high-dose HGF. Therefore, administration of low-dose rh-HGF was not associated with the massive enlargement of HCC lesion, which was observed in only a single rat of group II. As HGF is known to act as a scattering factor, intravenous administration of rh-HGF may have influenced the development of metastatic lung neoplasia.

HGF reduces hepatic fibrosis in animal models of liver cirrhosis (19-23). This study is the first in which rh-HGF was administered to rats fed a CDAA diet. Administration of rh-HGF did not facilitate the hepatic fibrosis induced by the CDAA diet (data not shown). Although both liver weight and platelet counts were increased and serum ALT levels were reduced following treatment with high-dose rh-HGF (group III; 0.5 mg/kg/day), rh-HGF treatment may not be sufficient to attenuate the hepatic fibrosis induced by a CDAA diet. In contrast, long-term administration of high-dose rh-HGF (group III) induced a marked increase in the urinary excretion of albumin. Although serum creatinine levels were not affected by rh-HGF treatment, this albuminuria was irreversible, continuing for 12 weeks after the discontinuation of rh-HGF administration. Preliminary experiments revealed that repeated injections of rh-HGF for two weeks increased the urinary excretion of albumin; this albuminuria disappeared almost completely within one to two weeks after washout of rh-HGF (45). The histopathological findings seen in the kidneys after a two-week administration of rh-HGF were indicative of reversible changes. We therefore administered rh-HGF for five consecutive days of each week for two weeks followed by a two-week washout period to prevent rh-HGF-mediated nephrotoxicity (Fig. 1). In our studies, rats treated with low-dose rh-HGF (group II; 0.1 mg/kg/day) exhibited albuminuria equivalent to mock-treated rats (group I) by 60 weeks (12 weeks after washout of rh-HGF treatment). Conversely, as the serum levels of rh-HGF increase following intravenous administration in a bolus and the half-life of this molecule is prolonged in cirrhotic rats (26,45), rh-HGF nephrotoxicity may be augmented in rats fed a CDAA diet. Further experimentation is necessary to clarify the safe doses of rh-HGF that can be administered long-term or to patients with severe liver disease.

We are in the process of preparing a clinical study of rh-HGF administration to patients in fulminant hepatic failure, which is an intractable and fatal disease. The preliminary results of this clinical study indicate that short-term administration of rh-HGF is sufficient to rescue the patients, indicating a minimal possibility of HGF-induced hepatocarcinogenesis. HCCs, however, frequently develops in cirrhotic livers; long-term administration of rh-HGF is required to attenuate hepatic fibrosis in these patients. Therefore, it is important to resolve if long-term administration of rh-HGF accelerates the development of malignant tumors before we begin clinical trials for patients with liver cirrhosis. In this study, we administered rh-HGF for 36 weeks to rats fed a CDAA diet, an animal model of hepatocarcinogenesis resembling the development of human HCC. We then evaluated the effects of HGF treatment on the development of preneoplastic nodules and HCC lesions over a long experimental period. Although HGF treatment did not accelerate HCC development in this rat model of endogenous hepatocarcinogenesis, further *in vivo* investigations are required to clarify the risk of carcinogenesis induced by rh-HGF in both the liver and non-hepatic organs.

Acknowledgements

We thank Ms. Yuko Nakamura, Ms. Sayoko Ohara, and Ms. Kana Ohara for their technical assistance. This study was supported in part by Health and Labor Science Research Grants from the Ministry of Health, Labor, and Welfare of Japan for the Research of Intractable Diseases.

References

1. Gohda E, Tsubouchi H, Nakayama H, *et al*: Human hepatocyte growth factor in plasma from patients with fulminant hepatic failure. Exp Cell Res 166: 139-150, 1986.
2. Gohda E, Tsubouchi H, Nakayama H, *et al*: Purification and partial characterization of hepatocyte growth factor from plasma of a patient with fulminant hepatic failure. J Clin Invest 81: 414-419, 1988.
3. Michalopoulos GK: Liver regeneration: molecular mechanisms of growth control. FASEB J 4: 176-185, 1990.
4. Dignass AU, Lynch-Devaney K and Podolsky DK: Hepatocyte growth factor/scatter factor modulates intestinal epithelial cell proliferation and migration. Biochem Biophys Res Commun 202: 701-709, 1994.
5. Bussolino F, Di Renzo MF, Ziche M, *et al*: Hepatocyte growth factor is a potent angiogenic factor which stimulates endothelial cell motility and growth. J Cell Biol 119: 629-641, 1992.
6. Zarneger R and Michalopoulos GK: The many faces of hepatocyte growth factor: from hepatopoiesis to hematopoiesis. J Cell Biol 129: 1177-1180, 1995.
7. Fujiwara K, Nagoshi S, Ohno A, *et al*: Stimulation of liver growth by exogenous human hepatocyte growth factor in normal and partially hepatectomized rats. Hepatology 18: 1443-1449, 1993.
8. Ishiki Y, Ohnishi H, Muto Y, Matsumoto K and Nakamura T: Direct evidence that hepatocyte growth factor is a hepatotrophic factor for liver regeneration and has a potent antihepatitis effect *in vivo*. Hepatology 16: 1227-1235, 1992.
9. Ishii T, Sato M, Sudo K, *et al*: Hepatocyte growth factor stimulates liver regeneration and elevates blood protein level in normal and partially hepatectomized rats. J Biochem 117: 1105-1112, 1995.
10. Webber EM, FitzGerald MJ, Brown PI, Barlett MH and Fausto N: Transforming growth factor-α expression during liver regeneration after partial hepatectomy and toxic injury, and potential interactions between transforming growth factor-α and hepatocyte growth factor. Hepatology 18: 1422-1431, 1993.
11. Moriuchi A, Hirono S, Ido A, *et al*: Additive and inhibitory effects of simultaneous treatment with growth factors on DNA synthesis through MAPK pathway and G1 cyclins in rat hepatocytes. Biochem Biophys Res Commun 280: 368-273, 2001.

J, Shiota G and Kawasaki H: Protective action of cyte growth factor for acute liver injury caused by D-galacto-samine in transgenic mice. Hepatology 26: 1241-1249, 1997.
13. Kosai K, Matsumoto K, Nagata S, Tsujimoto Y and Nakamura T: Abrogation of Fas-induced fulminant hepatic failure in mice by hepatocyte growth factor. Biochem Biophys Res Commun 244: 683-690, 1998.
14. Masunaga H, Fujise N, Shiota A, *et al*: Preventive effects of the deleted form of hepatocyte growth factor against various liver injuries. Eur J Pharmacol 342: 267-279, 1998.
15. Kosai K, Matsumoto K, Funakoshi H and Nakamura T: Hepatocyte growth factor prevents endotoxin-induced lethal hepatic failure. Hepatology 30: 151-159, 1999.
16. Mori I, Tsuchida A, Taiji M and Noguchi H: Hepatocyte growth factor protects mice against anti-Fas antibody-induced death. Med Sci Res 27: 355-359, 1999.
17. Nomi T, Shiota G, Isono M, Sato K and Kawasaki H: Adenovirus-mediated hepatocyte growth factor gene transfer prevents lethal liver failure in rats. Biochem Biophys Res Commun 278: 338-343, 2000.
18. Xue F, Takahara T, Yata Y, *et al*: Attenuated acute liver injury in mice by naked hepatocyte growth factor gene transfer into skeletal muscle with electroporation. Gut 50: 558-562, 2002.
19. Yasuda H, Imai E, Shiota A, Fujise N, Morinaga T and Higashio K: Antifibrogenic effect of a deletion variant of hepatocyte growth factor on liver fibrosis in rats. Hepatology 24: 636-642, 1996.
20. Matsuda Y, Matsumoto K, Yamada A, *et al*: Prevention and therapeutic effects in rats of hepatocyte growth factor infusion on liver fibrosis/cirrhosis. Hepatology 26: 81-89, 1997.
21. Ueki T, Kaneda Y, Tsutsui H, *et al*: Hepatocyte growth factor gene therapy of liver cirrhosis in rats. Nat Med 5: 226-230, 1999.
22. Sato M, Kakubari M, Kawamura M, Sugimoto J, Matsumoto K and Ishii T: The decrease in total collagen fibers in the liver by hepatocyte growth factor after formation of cirrhosis induced thioacetamide. Biochem Pharmacol 59: 681-690, 2000.
23. Oe S, Fukunaka Y, Hirose T, Yamaoka Y and Tabata Y: A trial on regeneration therapy of rat liver cirrhosis by controlled release of hepatocyte growth factor. J Control Release 307: 146-151, 2003.
24. Tsubouchi H, Niitani Y, Hirono S, *et al*: Levels of the human hepatocyte growth factor in serum of patients with various liver diseases determined by an enzyme-linked immunosorbent assay. Hepatology 13: 1-5, 1991.
25. Tsubouchi H, Kawakami S, Hirono S, *et al*: Prediction of outcome in fulminant hepatic failure by serum human hepatocyte growth factor. Lancet 340: 307, 1992.
26. Ido A, Moriuchi A, Kim ID, *et al*: Pharmacokinetic study of recombinant human hepatocyte growth factor administered in a bolus intravenously or via portal vein. Hepatol Res 30: 175-181, 2004.
27. Nakae D, Yoshiji H, Mizumoto Y, *et al*: High incidence of hepatocellular carcinomas induced by a choline-deficient, L-amino acid-defined diet in rats. Cancer Res 52: 5042-5045, 1992.
28. Onaga M, Ido A, Hasuike S, *et al*: Enhanced expression of growth factors and imbalance between hepatocyte proliferation and apoptosis in the livers of rats fed a choline-deficient, L-amino acid-defined diet. Hepatol Res 28: 94-101, 2004.
29. Maronpot RR, Montgomery CA, Boorman GA and McConnell EE: National toxicology program nomenclature for hepatoproliferative lesions of rats. Toxicol Pathol 14: 263-273, 1986.
30. Sakata H, Takayama H, Sharp R, Rubin JS, Merlino G and LaRochelle WJ: Hepatocyte growth factor/scatter factor overexpression induces growth, abnormal development, and tumor formation in transgenic mouse livers. Cell Growth Differ 7: 1513-1523, 1996.
31. Takayama H, LaRochelle, Sharp R, *et al*: Diverse tumorigenesis associated with aberrant development in mice overexpressing hepatocyte growth factor/scatter factor. Proc Natl Acad Sci USA 94: 701-706, 1997.
32. Gallego MI, Bierie B and Hennighausen L: Targeted expression of HGF/SF in mouse mammary epithelium leads to metastatic adenosquamous carcinomas through the activation of multiple signal transduction pathways. Oncogene 22: 8498-8508, 2003.
33. Bell A, Chen Q, DeFrances MC, Michalopoulos GK and Zarnegar R: The five amino acid-deleted isoform of hepatocyte growth factor promotes carcinogenesis in transgenic mice. Oncogene 18: 887-895, 1999.
34. Horiguchi N, Takayama H, Toyoda M, *et al*: Hepatocyte growth factor promotes hepatocarcinogenesis through c-Met autocrine activation and enhanced angiogenesis in transgenic mice treated with diethylnitrosamine. Oncogene 21: 1791-1799, 2002.
35. Nooman FP, Otsuka T, Bang S, Anver MR and Merlino G: Accelerated ultraviolet radiation-induced carcinogenesis in hepatocyte growth factor/scatter factor transgenic mice. Cancer Res 60: 3738-3743, 2000.
36. Shiota G, Kawasaki H, Nakamura T and Schmidt EV: Characterization of double transgenic mice expressing hepatocyte growth factor and transforming growth factor α. Res Commun Mol Pathol Pharmacol 90: 17-24, 1995.
37. Santoni-Rugiu E, Preisegger KH, Kiss A, *et al*: Inhibition of neoplastic development in the liver by hepatocyte growth factor in a transgenic mouse model. Proc Natl Acad Sci USA 93: 9577-9582, 1996.
38. Shima N, Nagao M, Ogaki F, Tsuda E, Murakami A and Higashio K: Tumor cytotoxic factor/hepatocyte growth factor from human fibroblasts: cloning of its cDNA, purification and characterization of recombinant protein. Biochem Biophys Res Commun 180: 1151-1158, 1991.
39. Liu ML, Mars WM and Michalopoulos GK: Hepatocyte growth factor inhibits cell proliferation *in vivo* of rat hepatocellular carcinomas induced by diethylnitrosamine. Carcinogenesis 16: 841-843, 1995.
40. Ogasawara H, Hiramoto J, Takahashi M, *et al*: Hepatocyte growth factor stimulates DNA synthesis in rat preneoplastic hepatocytes but not in liver carcinoma cells. Gastroenterology 114: 775-781, 1998.
41. Yaono M, Hasegawa R, Mizoguchi Y, *et al*: Hepatocyte growth factor enhancement of preneoplastic hepatic foci development in rats treated with diethylnitrosamine and N-ethyl-N-hydroxyethylnitrosamine. Jpn J Cancer Res 86: 718-723, 1995.
42. Arakaki N, Kazi JA, Kazihara T, Ohnishi T and Daikuhara Y: Hepatocyte growth factor/scatter factor activates the apoptosis signaling pathway by increasing caspase-3 activity in sarcoma 180 cells. Biochem Biophys Res Commun 245: 211-215, 1998.
43. Gohda E, Okauchi H, Iwao M and Yamamoto I: Induction of apoptosis by hepatocyte growth factor/scatter factor and its augmentation by phorbol esters in Meth A cells. Biochem Biophys Res Commun 245: 278-283, 1998.
44. Arakaki N, Kajihara T, Akakaki R, *et al*: Involvement of oxidative stress in tumor cytotoxic activity of hepatocyte growth factor/scatter factor. J Biol Chem 274: 13541-13546, 1999.
45. Kusumoto K, Ido A, Moriuchi A, *et al*: Repeated intravenous injection of recombinant human hepatocyte growth factor ameliorates liver cirrhosis but causes albuminuria in rats. Int J Mol Med 17: 503-509, 2006.