ONCOLOGY REPORTS 20: 537-542, 2008

SPANDIDOS PUBLICATIONS

No relationship between ^{18}F-fluorodeoxyglucose positron emission tomography and expression of Glut-1 and -3 and hexokinase I and II in high-grade glioma

N. CHARNLEY[1], R. AIRLEY[2], D. DU PLESSIS[3], C. WEST[4], C. BROCK[5], C. BARNETT[6], J. MATTHEWS[1], K. SYMONDS[2], M. BOTTOMLY[1], R. SWINDELL[4] and P. PRICE[1]

[1]University of Manchester Wolfson Molecular Imaging Centre, Manchester; [2]Veterinary School, University of Bristol, Bristol; [3]Department of Neuropathology, Hope Hospital; [4]Academic Radiation Oncology, The University of Manchester, Christie Hospital, Manchester; [5]Department of Medical Oncology, Hammersmith and Charing Cross Hospital, London; [6]Siemens Medical Solutions, Bracknell, UK

Received March 6, 2008; Accepted April 4, 2008

DOI: 10.3892/or_00000039

Abstract. The purpose of this study was to compare glucose metabolism, measured using ^{18}F-fluorodeoxyglucose positron emission tomography ([^{18}F]FDG-PET), with the expression of Glut-1 and -3 and hexokinase I (Hex I) and II in high-grade glioma. The retrospective study involved 27 patients with WHO classification grade III and IV glioma, with either newly diagnosed or recurrent tumours. Patients underwent dynamic and static [^{18}F]FDG-PET to glucose metabolic rate (MRGlu) and standardised uptake value (SUV), respectively. Tumour biopsies were obtained and stained using immunohistochemistry for the expression of Glut-1, -3, Hex I and II. Relationships between variables were studied using Spearman's rank correlation test. Results showed that the expression of Glut-1, Glut-3, Hex I and Hex II varied between and within the tumour samples. The mean of MRGlu was 0.2 (range 0.09-0.25) μmol/min/ml and that of SUV was 4.2 (range 3.2-5.2). There were no significant relationships among the tumour expression of any of the proteins studied with either MRGlu or SUV ($p>0.21$ for all). In conclusion, the lack of relationship between the immunohistochemical expression of Glut-1, -3, Hex I or II and glucose metabolism measured using [^{18}F]FDG-PET in patients with high-grade glioma may be due to the tissue heterogeneity and presence of necrosis in high-grade tumours.

Correspondence to: Dr N. Charnley, University of Manchester Wolfson Molecular Imaging Centre, 27 Palatine Road, Withington, Manchester M20 3LJ, UK
E-mail: natalie.charnley@manchester.ac.uk

Key words: glucose transporter, hexokinase, positron emission tomography, high-grade glioma, [^{18}F]fluorodeoxyglucose

Introduction

Facilitated glucose transporter-1 (Glut-1) is a member of the solute carrier family 2 (SLC2) family of glucose transporters. These proteins carry a range of hexoses, and have tissue and cell-specific expression. Glut-1 is expressed in most tissue types, and is involved in the transport of glucose across the blood-brain barrier. Glut-1 expression is closely regulated, and may be increased under hypoxic conditions via hypoxia-inducible factor 1 (HIF-1) (1) and by conditions which demand a change in the metabolic rate, i.e. cell division and transformation (2). Glut-1 is overexpressed in several tumour types, where it is associated with a poor prognosis (3). The Glut-3 receptor has a high level of expression in the central nervous system (4), and is also involved in glucose transport across the blood-brain barrier. Hexokinase enzymes I (Hex I) and II (Hex II) are involved in glycolysis and irreversibly phosphorylate cellular glucose, trapping it within the cell. Their expression is regulated by intracellular glucose levels. Hex I is mostly localised to the brain (5). Gliomas express large quantities of Hex II, and the highest levels are in grade IV tumours (6). Pyruvate dehydrogenase and phosphofructokinase are involved in glycolysis and increased in tumours with high rates of glycolysis (7).

Warburg demonstrated many years ago that cancer cells had higher rates of glycolysis compared to normal cells, and this has been exploited by [^{18}F]fluorodeoxyglucose positron emission tomography ([^{18}F]FDG-PET) imaging. As Glut-1 and -3 are involved in glucose uptake in malignant cells, and hexokinases are involved in glucose metabolism, the expression of these proteins may be expected to correlate with the [^{18}F]FDG uptake and utilisation on a PET scan. The correlation between [^{18}F]FDG uptake measured as a standardised uptake value (SUV) and Glut-1 expression has been demonstrated in a variety of tumour types, including cervix (8), oesophageal (9), ovary (10) and non-small cell lung cancer (NSCLC) (11). The expression of glucose transporters and hexokinases in the context of FDG uptake has been poorly explored in brain tumours. Only one publication showing a positive relation-

ship between Glut-1 expression and SUV in glioma exists (11).

SUV is a semiquantitative parameter that is easily obtained within routine clinical practice. Although the collection of dynamic data is more complicated, the data can be analysed using mathematical models to obtain potentially more accurate quantitative data. The glucose metabolic rate (MRGlu) can be calculated from a dynamic [^{18}F]FDG-PET and is likely to be more accurate than SUV as a measure of glucose utilisation. No published study describes the relationship between MRGlu and the expression of glucose transporters and enzymes.

The purpose of this study was to compare the [^{18}F]FDG-PET measurements of glucose metabolism (MRGlu) and uptake (SUV) with the expression of Glut-1, -3, Hex I and II in high-grade glioma. Furthermore, this was a hypothesis generating incentive to investigate whether the potentially brain-specific expression of metabolic markers Hex I and Glut-3, alongside the ubiquitous tumour glucose transporter Glut-1 and glycolytic enzyme Hex II may affect an FDG-PET profile characteristic to HGG.

Materials and methods

Patients. The archival brain tumour tissue of patients recruited to [^{18}F]FDG-PET studies at the MRC cyclotron unit, Hammersmith Hospital between August 1993 and January 2000, were retrospectively reviewed. Twenty-seven patients with WHO classification grade III and IV glioma were studied. Patients had newly diagnosed or recurrent tumours. Eligibility criteria included a performance status ≤2 and stable dexamethasone doses for at least two weeks prior to treatment. Approval was obtained from the Hammersmith Hospital Research and Ethics Committee and the Administration of Radioactive Substances Advisory Committee of the UK.

Positron emission tomography. [^{18}F]FDG was synthesized at the MRC cyclotron unit as previously described (12). The patients fasted for 4-6 h prior to imaging and, in order to standardize cerebral activity, wore an eye mask and earplugs for the duration of the study. The input function was obtained by arterial or arterialized venous sampling. A hot pad was applied to the arm used for arterialized venous blood sampling as previously described (14). Scanning was performed on an ECAT-ART partial ring PET camera. An initial transmission scan was used to correct photon attenuation in tissue. A maximum dose of 185 MBq of [^{18}F]FDG was injected as a bolus with over 30 sec for the dynamic [^{18}F]FDG scan. Arterial blood was withdrawn continuously over a calibrated detector. An arterialized-venous blood sample was withdrawn at 20 min for normalization of the population-derived arterial input function.

PET data analysis. The PET data were attenuation-corrected and reconstructed using filter back projection as previously described (12). A region of interest (ROI) analysis was performed using the Sunview package 'Analyze' (Analyze, Mayo Clinic, Rochester, MN, USA). ROIs encompassing whole tumours were defined by a visual analysis of the pre-treatment PET scan, with reference to a CT scan or visually co-registered baseline MRI scan. Where possible, regions were drawn on >3 planes to ensure an axial length of at least 1 cm. MRGlu was calculated by compartmental modelling, using the tissue time activity curves from the PET scan, and either the arterial or a population-derived input function. An arterial input function was obtained using the 20-min arterialized venous ^{18}F concentration to normalize the population-derived input function. The population-based estimated arterial input function was generated using spectral analysis to produce a mean input function from 14 complete arterial input functions from a previously studied group of patients (12). MRGlu was calculated as previously described (12). SUVs were calculated from the static images during the last 15 min of the dynamic scan. These were normalized for patient weight and the injected activity of [^{18}F]FDG.

Immunohistochemical staining of biopsies. Immunohistochemical staining was carried out on archived tumour tissue from patients with high-grade glioma. The tumour samples were a mixture of resections and open biopsies. The length of time between the biopsy and subsequent PET scan varied, and was greatest for patients with recurrent tumours. A standard immunoperoxidase technique was used, which is described briefly. For all samples, sections were dewaxed in xylene and rehydrated through decreasing concentrations of ethanol to water. Glut-1 staining was performed using an Envision kit containing an anti-rabbit labelled polymer conjugate (Dako, UK). The primary antibody used was an affinity purified anti-rabbit Glut-1 (dilution: 1:100) (Alpha Diagnostic International, TX, USA). Glut-1 expression is prolific in erythrocytes. Therefore, the presence of these cells within tumour capillaries in the section provided an internal positive control. Glut-3 staining involved antigen retrieval by heating samples in citrate buffer, an affinity purified rabbit anti-Glut-3 (dilution: 1:100) antibody and a secondary anti-rabbit labelled polymer conjugate. For Hex II staining, the primary antibody used was an affinity purified anti-goat Hex II (dilution: 1:100). The secondary antibody used was polyclonal biotinylated rabbit anti-goat immunoglobulin (dilution: 1:400). Hex I staining included an additional antigen retrieval step after dewaxing and rehydration. The primary antibody was an affinity purified anti-goat Hex I (dilution 1:50) and the secondary antibody was as for Hex II. Two batch negative controls were included in each run.

Stained sections were viewed by an experienced brain tumour pathologist at an objective magnification of 10 and scored according to the extent of staining within the tumour cells: 0, no staining; 1, scant staining (<10%); 2, moderate staining (10-50%) and 3 extensive staining (>50%). Areas of necrosis were excluded from the scoring.

Statistical analysis. Correlation co-efficients were derived for the relationships between SUV or MRGlu, and expression of Glut-1, -3, Hex I and II. Spearman's test was applied to test for significance of the correlations.

Results

Biopsies were obtained from 6 patients with anaplastic astrocytoma, and 21 patients with glioblastoma multiforme. Table I lists the PET and protein expression data obtained. For some

xpression of Glut-1, -3, Hex I and II in high-grade glioma and the uptake of [^{18}F]FDG on PET scan (SUV and MRGlu).

Patient	Grade	SUV	MRGlu	Glut-1	Glut-3	Hex I	Hex II
1	IV		0.27	2	0	1	2
2	IV		0.26		2	2	1
3	IV		0.37	1	0	1	1
4	III		0.39	1	0	0	0
5	IV	3.8	0.16	1	0	2	0
6	III	3.6	0.13	2		1	1
7	III	5.0	0.20	1	0	0	0
8	III	6.2	0.23	1	0	0	0
9	III		0.23	2	0	3	0
10	III	3.9	0.15	1		2	2
11	IV		0.09	1	0	1	0
12	IV	4.2	0.17	3	2	2	2
13	IV	3.4	0.13	2	0	2	1
14	IV	3.8	0.22	3	1	3	
15	III	4.7	0.20	2	1	0	1
16	IV	5.3	0.23	2	1		2
17	IV	3.9	0.16	2	2	1	2
18	IV	5.2	0.21	2	1	3	2
19	IV	3.2	0.18	2	1	3	3
20	IV	4.6	0.25	2	1	1	2
21	IV	3.6	0.21		1	0	2
22	IV	4.3	0.21	3	1	3	2
23	IV	4.3	0.19	2		1	3
24	IV	4.3	0.18	2			2
25	IV	3.5	0.18	3	1	1	2
26	IV	3.5	0.16	3	1	2	2
27	IV		0.14	2	0	1	1

SUV, standardised uptake value; MRGlu, glucose metabolic rate (μmol/min/ml); Glut-1, glucose transporter-1; Glut-3, glucose transporter 3; Hex, I hexokinase I and Hex II hexokinase II. Patients 1-13 had recurrent tumours, while patients 14-27 had primary tumours.

patients, SUVs were not available, and as the PET data were historical, it was not possible to re-analyse this information. Some biopsies did not have the full profile of immunohistochemistry due to insufficient tumour material on certain sections. However, the tumour specimens were well preserved.

The mean of MRGlu was 0.2 (range 0.09-0.25) μmol/min/ml and that of SUV was 4.2 (range 3.2-5.2). There was a varied expression of Glut-1, -3, Hex I and II between and within the tumour samples. Median levels of the protein expression were 2 (Glut-1), 1 (Glut-3), 1 (Hex I) and 2 (Hex II). Fig. 1 illustrates expression of proteins by the tumours as shown by immunohistochemistry. Fig. 2 shows the relationship between MRGlu and the expression of the proteins studied. No relationship was found between MRGlu and the expression of Glut-1 (*rho* = -0.07, p=0.73), Glut-3 (*rho* = -0.04, p=0.84), Hex I (*rho* = -0.12, p=0.56) or Hex II (*rho* = -0.04, p=0.87). Similarly, no relationship was found between SUV and the expression of Glut-1 (*rho* = 0.64, p=0.15, for SUV), Glut-3 (*rho* = -0.08, p=0.76), Hex I (*rho* = -0.31, p=0.21) or Hex II (*rho* = -0.22, p=0.36).

The data were further analysed for patients who expressed Glut-1 and Hex I or II simultaneously. For patienst who expressed high (2 or 3) Glut-1 and Hex I, the mean of MRGlu was 0.19, and for patients who expressed high (2 or 3) Glut-1 and Hex II, the mean of MRGlu was 0.2. These values were similar to the mean of MRGlu of 0.2 for the group of patients as a whole. The time between the biopsy and PET scan was shorter for patients with primary as opposed to recurrent disease. Therefore, the data were analysed for the 14 patients with primary tumours only. In this group of patients, we found no significant relationships between MRGlu and Glut-1 (*rho* = -0.016, p=0.63), Glut-3 (*rho* = -0.27, p=0.39), Hex I (*rho* = -0.09, p=0.79) or Hex II (*rho* = 0.19, p=0.57).

Discussion

No significant relationship was found between the immunohistochemical expression of Glut-1, -3, Hex I or II and the FDG uptake/metabolism measured using PET in high-grade glioma. There are several published reports on the association

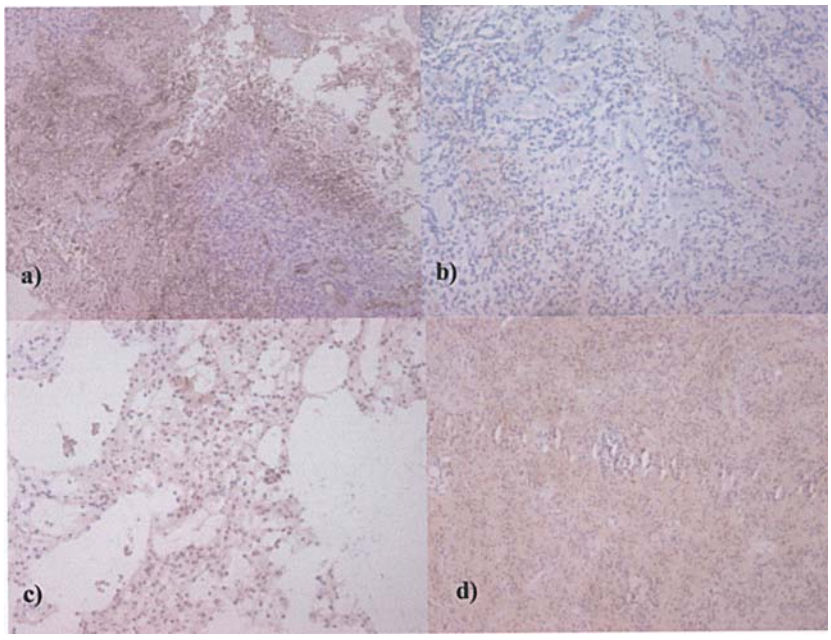

Figure 1. Expression of Glut-1 (a), Glut-3 (b), Hex I (c) and Hex II (d) in patients with high-grade glioma.

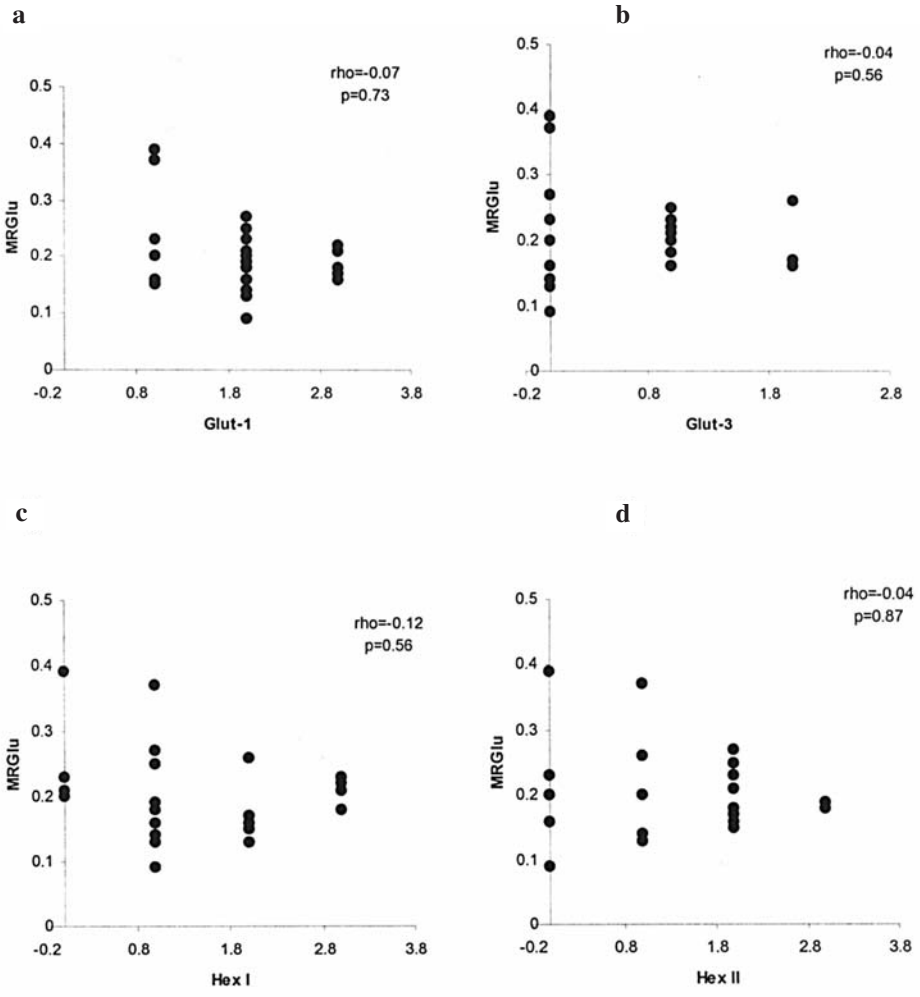

Figure 2. Relationship of Glut-1 (a), Glut-3 (b) Hex I (c) and Hex II (d) expression with MRGlu in patients with high-grade glioma.

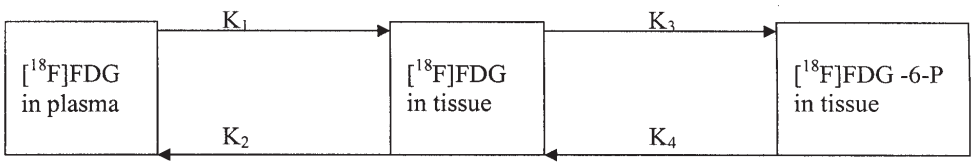

Figure 3. Metabolism of FDG in tissue. The rate constants K1, K2, K3 and K4 are determined by kinetic modelling and describe the transfer between compartments, i.e. delivery, washout, phosphorylation and dephosphorylation, respectively.

of Glut-1 with FDG-PET SUV in other tumours including cervix (8), breast (13), pancreas (14) and oesophageal (9) cancers. However, there are little data on the expression of this marker and the relationship with FDG uptake in glioma. The one publication which does show a positive relationship between Glut-1 expression and SUV in glioma (11) does not state whether the patients had low- or high-grade tumours.

Other groups have investigated the expression of hexokinases in the context of SUV, in other tumour types. There is one publication which relates Hex II to [18F]FDG uptake in patients with breast cancer, and this showed no correlation (13). In a mouse model, a good correlation was found between expression of Glut-1, Glut-3 and Hex II and [18F]FDG uptake in the central area of tumours, which corresponded with positive staining for HIF-1 (15).

In this study, immunohistochemistry was performed to assess the protein expression. Although not fully quantitative, it is intended to measure the relative, rather than the absolute expression of the markers. The merit of such semi-quantitative analysis is proven by previous studies (3,16).

The lack of correlation between Glut-1 expression and [18F]FDG uptake may be due to a number of factors: the study of only grade III and IV lesions; the heterogeneous composition of grade III/IV vs. lower grade gliomas in terms of morphology, necrosis, cell density and vascularity; and problems in comparing tissue sections with whole tumour scans. Tissue biopsies are less likely to be representative of whole tumours in higher compared with low-grade gliomas, particularly when image guided-biopsies are not obtained.

Grade IV gliomas often contain areas of necrosis. An area of necrosis will have a low glucose uptake on a PET scan due to poor access of [18F]FDG and poor metabolism, but there will be a lot of peri-necrotic Glut-1 staining. Although in general, an increased [18F]FDG uptake is seen in the malignant progression from low to high-grade glioma (17), a lower metabolism has been seen in grade IV gliomas compared to more homogeneous grade III tumours (18). In this group of patients, an increased expression of Glut-1 was seen in grade IV versus grade III tumours with mean expression levels of 2.1 and 1.4, respectively (p=0.03). In addition, the mean of MRGlu was not significantly different for grade III and IV tumours (mean MRGlu of 0.22 and 0.20, respectively, p=0.6).

For the relationship between expression of the markers and FDG uptake in patients with primary disease only, it is difficult to interpret the lack of correlation as the numbers were small.

Primary and recurrent tumours were included in this analysis as the aim was not to link the data with a clinical outcome. The aim of this study was to assess whether the glucose transporters and hexokinases were biologically linked, and whether this network of metabolic pathways may reflect FDG-PET data. However, the inclusion of primary and recurrent gliomas may have confounded the data as there is a tendency for [18F]FDG uptake to be higher in recurrent gliomas than primary tumours (19). This was not the case for the patients studied here. The mean of MRGlu for recurrent vs. primary tumours was 0.21 vs. 0.19, respectively, p=0.5).

Exposure to dexamethasone has been shown to affect the expression of glucose transporters (20). The majority of the patients in this study were taking dexamethasone. In addition, although the dexamethasone dose was stable for the 2 weeks preceding the PET scan, it is possible that the dose changed between the biopsy and the scan.

The kinetic modelling of PET data allows for the calculation of MRGlu (Fig. 3). MRGlu is quantitative and is expected to be a more accurate measure of glucose utilisation than SUV as the kinetic model allows for concentrations of blood glucose, blood [18F]FDG and unphosphorylated [18F]-FDG in tissues. The uptake and metabolism of [18F]FDG may not be the same as for glucose. The lumped constant is determined by the transport of glucose into cells, and the competition between [18F]FDG and glucose for Hex resulting in phosphorylated 18F-FDG and glucose, as per the equation:

$$\mathrm{MRGlu} = \frac{C_{pl}}{LC} \times \frac{K_1 K_3}{K_2 + K_3}$$

LC, lumped constant and C_{pl}, plasma glucose concentration

$$K_i = \frac{K_1 K_3}{K_2 + K_3}$$ K_i, extraction of FDG

This three-compartment model of glucose metabolism may not be optimal in this context, in view of the heterogeneity of brain tumours and due to the presence of the blood-brain barrier. In addition, the derived values of MRGlu may thus underestimate or overestimate the true value. It would be useful to investigate the relationship between Glut expression and Ki/K1. Ki/K1 depends on the ratio of the uptake between [18F]FDG and glucose, which in turn depends on the relative importance of the saturable processes governed by glucose transporters and hexokinases. In normal brain, a positive correlation has been demonstrated between Glut-1 or -3 expression and local cerebral glucose utilisation measured by autoradiography and 14C deoxyglucose, rather than [18F]FDG (21). In a future study, it would be interesting to compare the

uptake of ^{14}C-glucose with Glut-1 expression to investigate whether a more accurate correlation can be made.

In conclusion, in patients with high-grade glioma, there is no relationship between the expression of glucose transporters or enzymes and glucose utilisation (SUV, MRGlu) as measured by [^{18}F]FDG PET. This may be due to the tissue heterogeneity of high-grade tumours and the presence of necrosis.

Acknowledgements

This work was carried out at the University of Manchester Wolfson Molecular Imaging Centre and MRC Cyclotron Unit, Hammersmith Hospital, and was supported by Cancer Research UK and the National Translational Network of the UK.

References

1. Michiels C, Minet E, Michel G, Mottet D, Piret JP and Raes M: HIF-1 and AP-1 cooperate to increase gene expression in hypoxia: role of MAP kinases. IUBMB Life 52: 49-53, 2001.
2. Merrall NW, Plevin R and Gould GW: Growth factors, mitogens, oncogenes and the regulation of glucose transport. Cell Signal 5: 667-675, 1993.
3. Airley R, Loncaster J, Davidson S, *et al*: Glucose transporter glut-1 expression correlates with tumor hypoxia and predicts metastasis-free survival in advanced carcinoma of the cervix. Clin Cancer Res 7: 928-934, 2001.
4. Shepherd PR, Gould GW, Colville CA, McCoid SC, Gibbs EM and Kahn BB: Distribution of GLUT3 glucose transporter protein in human tissues. Biochem Biophys Res Commun 188: 149-154, 1992.
5. Schwab DA and Wilson JE: Complete amino acid sequence of rat brain hexokinase, deduced from the cloned cDNA, and proposed structure of a mammalian hexokinase. Proc Natl Acad Sci USA 86: 2563-2567, 1989.
6. Bennett MJ, Timperley WR, Taylor CB and Hill AS: Isoenzymes of hexokinase in the developing, normal and neoplastic human brain. Eur J Cancer 14: 189-193, 1978.
7. Weber G: Enzymology of cancer cells (second of two parts). N Engl J Med 296: 541-551, 1977.
8. Yen TC, See LC, Lai CH, *et al*: 18F-FDG uptake in squamous cell carcinoma of the cervix is correlated with glucose transporter 1 expression. J Nucl Med 45: 22-29, 2004.
9. Kato H, Takita J, Miyazaki T, *et al*: Correlation of 18-F-fluorodeoxyglucose (FDG) accumulation with glucose transporter (Glut-1) expression in esophageal squamous cell carcinoma. Anticancer Res 23: 3263-3272, 2003.
10. Kurokawa T, Yoshida Y, Kawahara K, *et al*: Expression of GLUT-1 glucose transfer, cellular proliferation activity and grade of tumor correlate with [F-18]-fluorodeoxyglucose uptake by positron emission tomography in epithelial tumors of the ovary. Int J Cancer 109: 926-932, 2004.
11. Chung JK, Lee YJ, Kim SK, Jeong JM, Lee DS and Lee MC: Comparison of [18F]fluorodeoxyglucose uptake with glucose transporter-1 expression and proliferation rate in human glioma and non-small-cell lung cancer. Nucl Med Commun 25: 11-17, 2004.
12. Brock CS, Young H, O'Reilly SM, *et al*: Early evaluation of tumour metabolic response using [18F]fluorodeoxy-glucose and positron emission tomography: a pilot study following the phase II chemotherapy schedule for temozolomide in recurrent high-grade gliomas. Br J Cancer 82: 608-615, 2000.
13. Brown RS, Goodman TM, Zasadny KR, Greenson JK and Wahl RL: Expression of hexokinase II and Glut-1 in untreated human breast cancer. Nucl Med Biol 29: 443-453, 2002.
14. Higashi T, Saga T, Nakamoto Y, *et al*: Relationship between retention index in dual-phase (18)F-FDG PET, and hexokinase-II and glucose transporter-1 expression in pancreatic cancer. J Nucl Med 43: 173-180, 2002.
15. Zhao S, Kuge Y, Mochizuki T, *et al*: Biologic correlates of intratumoral heterogeneity in 18F-FDG distribution with regional expression of glucose transporters and hexokinase-II in experimental tumor. J Nucl Med 46: 675-682, 2005.
16. Oliver RJ, Woodwards RT, Sloan P, Thakker NS, Stratford IJ and Airley RE: Prognostic value of facilitative glucose transporter Glut-1 in oral squamous cell carcinomas treated by surgical resection; results of EORTC Translational Research Fund studies. Eur J Cancer 40: 503-507, 2004.
17. Francavilla TL, Miletich RS, Di Chiro G, Patronas NJ, Rizzoli HV and Wright DC: Positron emission tomography in the detection of malignant degeneration of low-grade gliomas. Neurosurgery 24: 1-5, 1989.
18. Herholz K, Wienhard K and Heiss WD: Validity of PET studies in brain tumors. Cerebrovasc Brain Metab Rev 2: 240-265, 1990.
19. Herholz K, Ziffling P, Staffen W, Pawlik G, Wagner R, Wienhard K and Heiss WD: Uncoupling of hexose transport and phosphorylation in human gliomas demonstrated by PET. Eur J Cancer Clin Oncol 24: 1139-1150, 1988.
20. Langdown ML and Sugden MC: Enhanced placental GLUT1 and GLUT3 expression in dexamethasone-induced fetal growth retardation. Mol Cell Endocrinol 185: 109-117, 2001.
21. Duelli R and Kuschinsky W: Brain glucose transporters: relationship to local energy demand. News Physiol Sci 16: 71-76, 2001.