SPANDIDOS PUBLICATIONS

WORLD ACADEMY OF SCIENCES JOURNAL 5: 16, 2023

Management of ventilator-associated pneumonia due to *Stenotrophomonas maltophilia* infection: A case report and literature review

EDOARDO CAMPANELLA[1], ANDREA MARINO[2,3], STEFANO STRACQUADANIO[3], ROBERTA RESTIVO[2], CRISTINA MICALI[1], GIUSEPPE NUNNARI[2], BRUNO CACOPARDO[2] and MANUELA CECCARELLI[2]

[1]Department of Clinical and Experimental Medicine, Unit of Infectious Diseases, University of Messina, I-98124 Messina; [2]Department of Clinical and Experimental Medicine, Unit of Infectious Diseases, ARNAS Garibaldi Hospital, University of Catania; [3]Department of Biomedical and Biotechnological Sciences, University of Catania, I-95123 Catania, Italy

Received February 22, 2023; Accepted April 3, 2023

DOI: 10.3892/wasj.2023.193

Abstract. *Stenotrophomonas maltophilia* (*S. maltophilia*) is a difficult-to-treat bacteria. This glucose non-fermenting, multidrug-resistant Gram-negative bacillus is known to cause a range of infections, such as skin manifestations and bacteraemia, with respiratory tract infections being the most common. Patients in intensive care units are often exposed to a higher risk of acquiring an infection caused by this pathogen. Although distinguishing between *S. maltophilia* infections and colonization can be challenging, pneumonia caused by *S. maltophilia* infection is becoming increasingly prevalent. Furthermore, *S. maltophilia* infections are often coupled with *Pseudomonas aeruginosa* infections, reinforcing the need to consider this bacterium as a potential cause of ventilator-associated pneumonia (VAP). The present study describes the case of a 66-year-old male who was diagnosed with VAP due to *S. maltophilia* infection. This condition was effectively treated with trimethoprim/sulfamethoxazole. The case described herein underscores the importance of prompt recognition through heightened clinical suspicion, particularly in patients with VAP who are unresponsive to broad-spectrum β-lactam antibiotics. The early identification of *S. maltophilia* as the root cause of respiratory tract infections can make a significant difference to the outcomes of affected patients.

Correspondence to: Dr Andrea Marino, Department of Clinical and Experimental Medicine, Unit of Infectious Diseases, ARNAS Garibaldi Hospital, University of Catania, Via Palermo 636, I-95123 Catania, Italy
E-mail: andreamarino9103@gmail.com

Key words: *Stenotrophomonas maltophilia*, ventilator-associated pneumonia, multidrug-resistant bacteria, *Pseudomonas aeruginosa*, antimicrobial stewardship

Introduction

Stenotrophomonas maltophilia (*S. maltophilia*) is a glucose non-fermenting, aerobic, Gram-negative bacillus that is ubiquitously found in aquatic environments and soil (1). Although it is considered a low virulence pathogen, it is increasingly recognised as a main cause of nosocomial infections (2,3).

S. maltophilia, due to his high virulence determinants, including biofilm production, can cause various type of infections, such as skin manifestations and bacteraemia (1), mainly those involving the respiratory tract (4). Major concerns particularly involve vulnerable hosts, such as patients in intensive care units (ICUs) or patients with cystic fibrosis, haematological malignancies, and other significant underlying illnesses (5,6). Moreover, its intrinsic multidrug resistance to several classes of antibiotics poses a major clinical and therapeutic challenge (7).

Historically, trimethoprim/sulfamethoxazole (TMP-SMX) has represented the drug of choice used in the treatment of *S. maltophilia* infections, playing a key role in antibiotic management. However, the emergence of TMP-SMX resistance has already been reported. Other treatment options may include minocycline, tigecycline, levofloxacin, cefiderocol and ceftazidime/avibactam plus aztreonam (8).

The differentiation between *S. maltophilia* infections and colonisation remains challenging, particularly in patients with ventilator devices (1,9). Over the past years, researchers have assessed *S. maltophilia* infections in ICUs, including bloodstream infections, skin and soft tissues infections, urinary tract infections and ventilator-associated pneumonia (VAP), reporting high mortality rates (5,10). Despite its undeniable clinical impact, solid data on *S. maltophilia* are limited compared with other Gram-negative bacteria (11). Moreover, *S. maltophilia* infections are often combined with other bacteria, rendering the clinical picture even more complex (1,11).

The present study, describes the case of a patient with VAP caused by *S. maltophilia* infection, highlighting the challenges in the management of this condition and the importance of prompt recognition and aggressive treatment. Furthermore,

the present study highlights the need to consider alternative, effective antimicrobial agent in patients with VAP who are not responsive to broad-spectrum β-lactam antibiotics.

Case report

A 66-year-old male was admitted to the Emergency Department of ARNAS Garibaldi Hospital due to the onset of seizures along with a profoundly altered mental status and fever (maximum temperature, 38˚C). His medical history included type 2 diabetes mellitus, hypertension, benign prostatic hyperplasia, dyslipidaemia, and a history of smoking. The patient was taking ertugliflozin, ramipril, alfuzosin and atorvastatin.

Upon admission, the patient was transferred to the ICU and was intubated due to a severely impaired consciousness (Glasgow Coma Scale 8). A brain computed tomography (CT) scan did not reveal any abnormalities.

Lumbar puncture (LP) was performed and empirical antibiotic treatment with intravenous ceftriaxone, acyclovir, ampicillin, and dexamethasone was commenced. The examination of cerebrospinal fluid (CSF) revealed lymphocytic pleocytosis, normal glucose levels and a higher protein concentration. The analysis of CSF using the BIOFIRE® FILMARRAY® Meningitis/Encephalitis (ME) Panel (BioMérieux) yielded positive results for herpes simplex virus 1.

Therapy was continued only with acyclovir at 10 mg/kg three times. The CSF culture tested negative. His chest X-ray was negative (Fig. 1). The blood test results of the patient are presented in Table I.

Despite an initial improvement, 3 days following ICU admission and endotracheal intubation, the patient's clinical condition began to deteriorate, along with worsened respiratory parameters and blood test results (Table I). A chest-CT scan (SOMATOM Definition Flash, Siemens) revealed bilateral basal consolidative opacities, along with bilateral pleural effusion (Fig. 2A).

Due to the diagnosis of VAP, antibiotic therapy was empirically switched to intravenous meropenem at 1 g three times daily plus intravenous linezolid at 600 mg twice daily. *Legionella* and pneumococcal urinary antigens tested negative, as well as a nasopharyngeal swab for severe acute respiratory syndrome-coronavirus 2 (SARS-CoV-2). The analysis of bronchoalveolar lavage (BAL) using the BIOFIRE® FILMARRAY® Pneumonia Panel (PN) (BioFire Diagnostics) tested positive for *Pseudomonas aeruginosa* (*P. aeruginosa*).

At 2 days after switching the therapy, the BAL culture tested positive for *S. maltophilia* on a blood agar plate (Vacutest Kima S.R.L.) (Fig. 3) with a total bacterial count of 10^5 CFU/ml performed diluting the BAL sample at 1:100 in sterile saline and plating 100 μl on Muheller Hintong agar (Vacutest Kima S.R.L.). Species identification was assessed using the BD Phoenix system, selecting a colony from the blood agar, and the antibiotic susceptibility test performed using the MIC test strip (Liofilchem) revealed susceptibility to TMP-SMX at an increased exposure [MIC 2 mg/l; according to the European Committee on Antimicrobial Susceptibility Testing (EUCAST), breakpoints are expressed as the trimethoprim concentration]; hence intravenous TMP-SMX at 12 mg/kg (dosing was based on the TMP component) was commenced, while linezolid treatment was terminated.

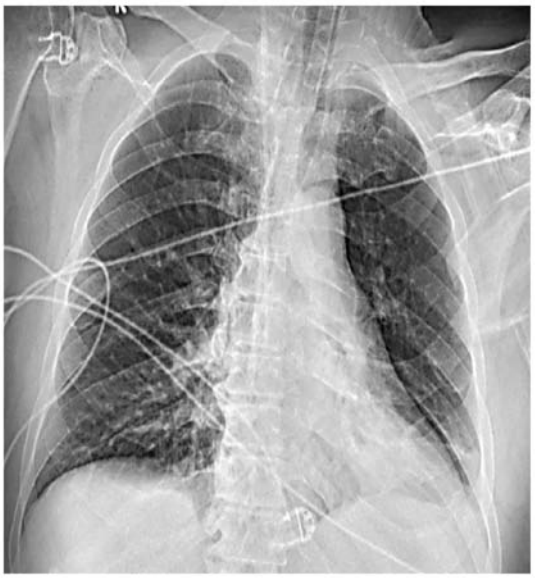

Figure 1. X-ray image of the patient upon admission.

At 4 days after the addition of TMP-SMX to the treatment schedule, the patient was extubated due to an amelioration in respiratory function and improved blood tests (Table I). The patient's mental status also improved, with no evidence of neurological deficits. The restored consciousness, along with a follow-up brain magnetic resonance imaging (Magneton, Siemens) not revealing any abnormalities, allowed for the discontinuation of acyclovir administration after 17 days of therapy. Furthermore, due to the resolution of consolidative opacities on a follow-up chest CT scan (Fig. 2B) along with a good general state, the antibiotic therapy with meropenem (14 days of therapy) and TMP-SMX (11 days of therapy) was terminated. Finally, the patient was discharged 7 days after the end of therapy, with no evidence of respiratory or neurological sequelae (Fig. 4).

Discussion

Gram-negative drug-resistant bacteria pose a major threat to physicians due to the increasing incidence of multi-drug resistant (MDR) infections worldwide (12-14), particularly among hospitalised patients (15,16). VAP is a type of pneumonia that occurs >48 h following intubation and is influenced by factors, such as immunosuppression, a long duration of hospitalisation, and prolonged ventilation (17,18).

The SARS-CoV-2 pandemic (19) may have contributed to an increase the number of cases with VAP, due to the large number of affected patients requiring ICU care and mechanical ventilation (20).

Gram-negative bacilli are the most commonly identified causative agents of VAP, with *P. aeruginosa*, *Enterobacter* spp. and *Klebsiella* spp. being the most prevalent (21,22). MDR Gram-negative infections result in poor outcomes of patients with hospital-acquired pneumonia/VAP and their increasing prevalence makes it crucial for management to consider the local ecology and patient risk factors (15,23). The identification

Table I. Laboratory findings at the time of admission, at the time of VAP diagnosis and following treatment.

Laboratory parameters (reference range)	At the time of admission	At the time of VAP diagnosis	Following treatment for VAP
WBC, cells/mmc (4,000-10,000)	10,330	15,100	7,200
Neutrophils, % (40-75)	73	85.6	57.3
Lymphocytes, % (25-50)	18.3	7.4	30.4
Monocytes, % (2-10)	8.8	6.3	9.8
Platelets, cells/mmc x10^3 (150-400)	150	123	309
Haemoglobin, g/dl (12-16)	13.1	12.6	12.4
AST, UI/l (15-35)	19	17	23
ALT, UI/l (15-35)	24	20	32
Creatinine, mg/dl (0.8-1.2)	0.59	0.44	0.47
Procalcitonin, ng/ml (<0.5)	0.04	0.04	0.01
CRP, mg/dl (0-0.5)	0.5	10.5	0.07

VAP, ventilator-associated pneumonia; WBC, white blood cell count; AST, aspartate aminotransferase; ALT, alanine aminotransferase; CRP, C-reactive protein.

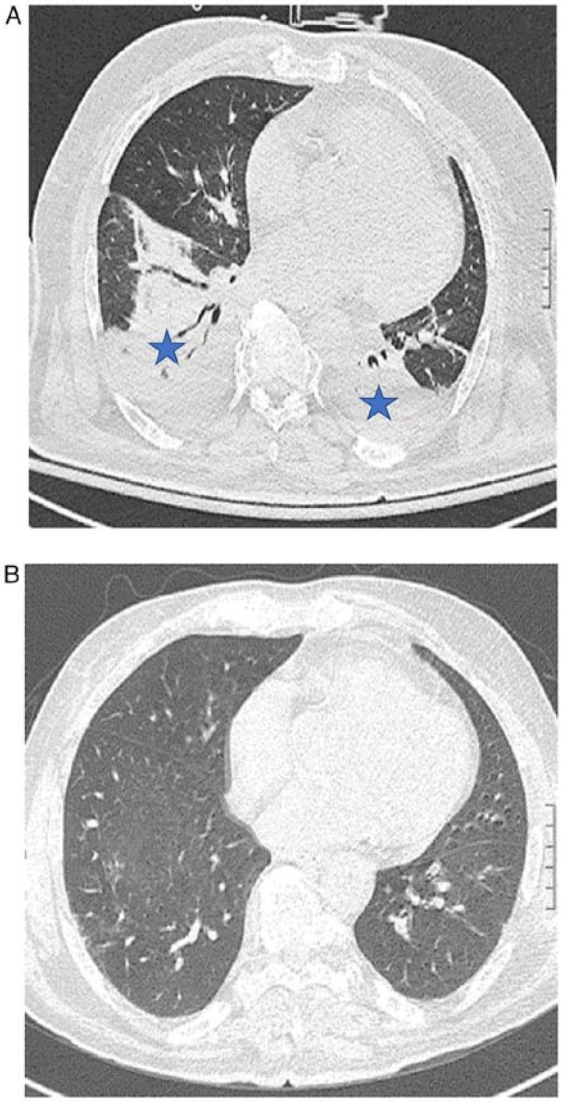

Figure 2. (A) Chest CT scan of the patient at the time of the diagnosis of ventilator-associated pneumonia. Blue stars indicate bilateral basal opacities with pleural effusion. (B) Chest CT scan following treatment with antibiotics. CT, computed tomography.

Figure 3. *Stenotrophomonas maltophilia* colonies on a blood agar plate.

of causative agents of VAP also needs to be a priority, due to the complexity of clinical and therapeutic management (17).

In the case described herein, the patient developed VAP due to *S. maltophilia* infection at 3 days after hospital admission. The categorisation of early- and late-onset VAP, of which late-onset VAP is more likely to be due to a MDR pathogen, is being challenged, as the timing of VAP development needs to be evaluated in the context of other risk factors (24,25).

Although often considered a colonizing pathogen, *S. maltophilia*, an ubiquitous, motile, free-living, aerobic, non-fermenting bacillus, multidrug-resistant Gram-negative bacterium (1), represents the causative agent of various infections, from skin manifestations to bacteraemia (26), particularly in patients with underlying illnesses (6). Recent research has reported that *S. maltophilia*-associated pneumonia

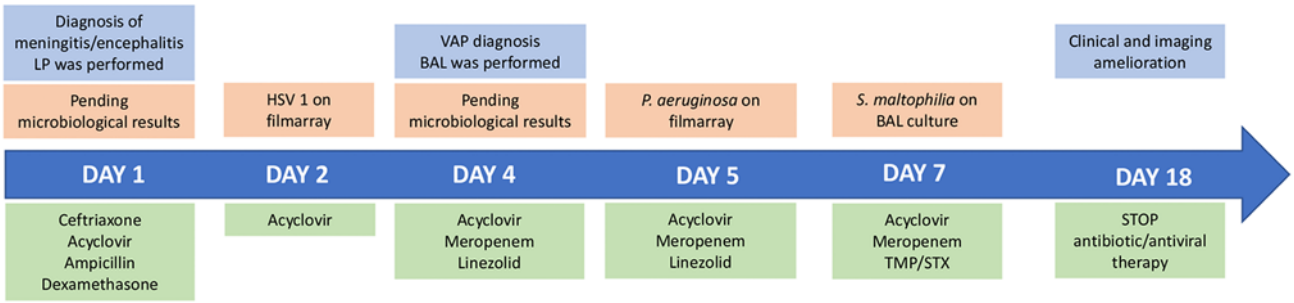

Figure 4. Clinical and therapeutic management timeline. Blue squares represent clinical assessment, pink squares represent microbiological results and green squares represent therapeutic management. LP, lumbar puncture; HSV, herpes simplex virus; VAP, ventilator-associated pneumonia; BAL, bronchoalveolar lavage; TMP, trimethoprim; STX, sulfamethoxazole.

is increasingly being isolated, describing this pathogen as one of the most common infectious agents in patients in ICUs, with a high morbidity and mortality rates. Risk factors for *S. maltophilia*-associated pulmonary diseases include ICU admission and mechanical ventilation, as well as prior broad-spectrum antibiotic therapy, prolonged hospitalization, and immunosuppression (27).

As patients with respiratory tract infections sustained by *S. maltophilia* are usually severely ill and hospitalised, and due to the drug-resistant profile of this bacteria, these conditions often lead to an increase in medical expenses, prolonged durations of hospitalisation and higher mortality rates. Therefore, identifying the right early targeted treatment is the key to reducing the mortality rates associated with *S. maltophilia* infection. A previously published meta-analysis demonstrated that previous carbapenem treatment was associated with lower respiratory tract infections by *S. maltophilia* with the highest odd ratio (OR, 3.69), followed by glycopeptide drugs (OR, 3.22), aminoglycoside drugs (OR, 2.57) and β-lactamase inhibitors (OR, 1.76) (28). That study suggested that when the clinical use of this type of drug is not effective, attention should be paid to the possibility of *S. maltophilia* infection; furthermore it was stated that more types of antibiotics, longer treatment durations and a greater number replacements can significantly increase the risk of respiratory tract infections caused by this bacterium (28).

These data may be explained by *S. maltophilia* features resulting in intrinsic or acquired resistance mechanisms to several antibiotics. Resistance to β-lactams is primarily mediated by L_1 and L_2, two chromosomal-mediated inducible β-lactamases. L_1 is a molecular class B Zn^{2+}-dependent metallo-β-lactamase, whilst L_2 is a molecular class A clavulanic acid-sensitive cephalosporinase. The *mrc*A gene (encodes penicillin-binding protein 1α) and regulatory proteins AmpR (transcriptional regulator) and AmpN-AmpG (permease system) influence basal β-lactamase activity. *mrc*A inactivation causes L_1/L_2 β-lactamase hyperproduction (29,30). *S. maltophilia* has demonstrated resistance to aminoglycosides as well, through efflux pumps and aminoglycoside modifying enzyme, such as 6'-N-aminoglycoside acetyltransferases. Fortunately, the new generation cephalosporin, cefiderocol, appears to be able to evade the chromosomally encoded L_1 and L_2 β-lactamases, as demonstrated by the 100% susceptibility of *S. maltophilia* to this molecule (29,30), as well as an *in vivo* model promising efficacy (31). The resistance of *S. maltophilia* to quinolones is mainly caused by mutations in the *gyr*A and *par*C genes at the target site (QRDRs) of the DNA gyrase enzyme, which is also related to the outer membrane barrier and high-efficiency efflux pump (32,33). Additionally, *S. maltophilia* can accumulate multidrug efflux pumps that reduce tetracycline and fluoroquinolone activity. Increased fluoroquinolone MICs are also observed in isolates that harbour the chromosomal Sm*qnr* gene, the determinants of which interfere through binding to gyrase and topoisomerase (1). Furthermore, *S. maltophilia* produces a wide variety of potential virulence factors, such as biofilm and extracellular enzymes, thus rendering treatment challenging (1,5,34).

Despite the lack of definitive evidence on the most effective available treatment, the current IDSA guidelines suggest TMP-SMX as the preferred treatment strategy for mild infections or in combination with another antibacterial agent for moderate to severe *S. maltophilia* infections. To date, combination therapy fails to exhibit evident superiority, with similar rates of clinical efficacy and resistance development compared with monotherapy (7,35), as reported by Shah *et al* (36) in a large retrospective cohort study.

As with other MDR Gram-negative bacteria, such as *Acinetobacter spp*., for which new antimicrobial agents are intensively being studied due to limited therapeutic options (37-39), *S. maltophilia* poses a major threat, particularly when resistant to TMP-SMX. When TMP-SMX is not a suitable treatment option, due to resistance or patients' intolerance, minocycline, tigecycline, other options include ticarcillin-clavulanate, cefiderocol, or ceftazidime/avibactam plus aztreonam (8).

While interpretive criteria for seven antibiotics have been established by the Clinical & Laboratory Standards Institute (CLSI), EUCAST has only provided breakpoints for TMP-SMX (40).

Of note, isolates resistant to this drug have already been reported (41,42). Previous studies have demonstrated that the *sul*1, *sul*2 and *drf*A genes may represent important determinants of TMP-SMX resistance in *S. maltophilia* isolates (1,43,44).

In the case described in the present study, the patient was diagnosed with VAP caused by a strain of *S. maltophilia* with a MIC for TMP-SMX equal to 2 mg/l, the same epidemiological cut-off value reported by the EUCAST. This value is close to the resistance breakpoint (>4 mg/l) and its treatment required an increased exposure to this antibiotic to assure the success of the therapy. This led to the addition of a higher

dose of TMP-SMX. After only 11 days, the patient's condition improved, and the pneumonia had resolved according to a follow-up chest CT scan.

It is worth mentioning that while the IDSA guidelines do not provide specific recommendations on therapy duration, they suggest considering factors, such as the patient's immune status, source control, and treatment response when deciding when to terminate antibiotics (8).

However, the nationwide study by Guerci *et al* (7) found no benefit in prolonged antimicrobial therapy beyond 7 days for patients admitted to ICUs. Nonetheless, the persistence of the infection caused a mistreatment could lead to the development of resistance phenotypes, particularly due to the commonly reported co-infection rate of *S. maltophilia* with other species, and its capability to obtain new resistance genes, such as *sul*1 and *sul*2, through horizontal gene transfer (45).

Furthermore, according to previous studies, *S. maltophilia* is often part of polymicrobial infections, with other non-fermenting Gram-negative bacteria, such as *P. aeruginosa*, *Acinetobacter* spp. and *Burkholderia cepacia* complex (2,11). Interactions between these bacteria may play a key role in clinical outcomes, with higher morbidity and mortality rates (46). For example, co-infection with *P. aeruginosa* and *S. maltophilia* has been linked to a higher mortality rate in patients with pneumonia. These two pathogens can form a polymicrobial biofilm in the lungs, interact through quorum-sensing signals and create a favourable environment for each other (47). McDaniel *et al* (48) found that the presence of *P. aeruginosa* facilitated *S. maltophilia* persistence in the lungs during polymicrobial infections.

In the case described herein, the FILMARRAY® test of BAL was positive for *P. aeruginosa*, even though it was not recovered on BAL culture. Given the higher risk of mortality associated with VAP caused by these two pathogens, it was decided to continue treatment with both meropenem and TMP-SMX.

In conclusion, the present study aimed to emphasize the importance of recognizing *S. maltophilia* as a potential pathogen in hospital settings where MDR bacteria are prevalent. The case described herein highlights the common co-occurrence of *S. maltophilia* and *P. aeruginosa* infections, reinforcing the need for considering this bacterium as a potential cause of VAP.

However, inadequate initial antimicrobial treatment is often the norm for *S. maltophilia* infections due to its resistance to commonly used antibiotics such as β-lactams. Thus, the consideration of alternative, effective treatment options for patients with VAP who are not responding to broad-spectrum β-lactam antibiotics is crucial, as well as in patients with *S. maltophilia* identified through bronchoalveolar lavage culture.

Notably however, more research is required in order to better understand the risk factors of VAP caused by *S. maltophilia* and to develop effective prevention strategies and early antimicrobial treatments, ultimately improving the outcomes of patients.

Acknowledgements

Not applicable.

Funding

No funding was received.

Availability of data and materials

Data sharing is not applicable to this article as no datasets were generated or analysed during the current study.

Authors' contributions

All authors (EC, AM, SS, RR, CM, GN, BC and MC) contributed to the conception and design of the study. EC and AM wrote the manuscript. SS, CM and MC revised the literature and references. RR provided clinical assistance to the patient. BC was responsible for the laboratory tests and pharmacological treatments. GN and BC revised the manuscript. All authors have read and approved the final manuscript. EC and AM confirm the authenticity of all the raw data.

Ethics approval and consent to participate

Written informed consent was obtained from the patient included in the present case report.

Patient consent for publication

Written informed consent was obtained from the patient for the publication of his data in the present case report.

Competing interests

The authors declare that they have no competing interests.

References

1. Brooke JS: Advances in the microbiology of *Stenotrophomonas Maltophilia*. Clin Microbiol Rev 34: e0003019, 2021.
2. Gajdács M and Urbán E: Epidemiological trends and resistance associated with *Stenotrophomonas maltophilia* Bacteremia: A 10-year retrospective cohort study in a tertiary-care hospital in Hungary. Diseases 7: 41, 2019.
3. Gröschel MI, Meehan CJ, Barilar I, Diricks M, Gonzaga A, Steglich M, Conchillo-Solé O, Scherer IC, Mamat U, Luz CF, *et al*: The phylogenetic landscape and nosocomial spread of the multidrug-resistant opportunist *Stenotrophomonas maltophilia*. Nat Commun 11: 2044, 2020.
4. Hafiz TA, Aldawood E, Albloshi A, Alghamdi SS, Mubaraki MA, Alyami AS and Aldriwesh MG: *Stenotrophomonas maltophilia* epidemiology, resistance characteristics, and clinical outcomes: Understanding of the recent three years's trends. Microorganisms 10: 2506, 2022.
5. Saied WI, Merceron S, Schwebel C, Monnier AL, Oziel J, Garrouste-Orgeas M, Marcotte G, Ruckly S, Souweine B, Darmon M, *et al*: Ventilator-associated pneumonia due to *Stenotrophomonas maltophilia*: Risk factors and outcome. J Infect 80: 279-285, 2020.
6. Chang YT, Lin CY, Chen YH and Hsueh PR: Update on infections caused by *Stenotrophomonas maltophilia* with particular attention to resistance mechanisms and therapeutic options. Front Microbiol 6: 893, 2015.
7. Guerci P, Bellut H, Mokhtari M, Gaudefroy J, Mongardon N, Charpentier C, Louis G, Tashk P, Dubost C, Ledochowski S, *et al*: Outcomes of *Stenotrophomonas maltophilia* hospital-acquired pneumonia in intensive care unit: A nationwide retrospective study. Crit Care 23: 371, 2019.

8. Tamma PD, Aitken SL, Bonomo RA, Mathers AJ, van Duin D and Clancy CJ: Infectious diseases society of America guidance on the treatment of AmpC β-Lactamase-producing Enterobacterales, Carbapenem-Resistant *Acinetobacter baumannii*, and *Stenotrophomonas maltophilia* Infections. Clin Infect Dis 74: 2089-2114, 2022.
9. Baidya A, Kodan P, Fazal F, Tsering S, Menon PR, Jorwal P and Chowdhury UK: *Stenotrophomonas maltophilia*: More than just a colonizer! Indian J Crit Care Med 23: 434-436, 2019.
10. Singhal L, Kaur P and Gautam V: *Stenotrophomonas maltophilia*: From trivial to grievous. Indian J Med Microbiol 35: 469-479, 2017.
11. Mojica MF, Humphries R, Lipuma JJ, Mathers AJ, Rao GG, Shelburne SA, Fouts DE, Van Duin D and Bonomo RA: Clinical challenges treating *Stenotrophomonas maltophilia* infections: An update. JAC Antimicrob Resist 4: dlac040, 2022.
12. Morris S and Cerceo E: Trends, epidemiology, and management of multi-drug resistant gram-negative bacterial infections in the hospitalized setting. Antibiotics (Basel) 9: 196, 2020.
13. Marino A, Campanella E, Stracquadanio S, Ceccarelli M, Zagami A, Nunnari G and Cacopardo B: *Corynebacterium striatum* bacteremia during SARS-CoV2 Infection: Case report, literature review, and clinical considerations. Infect Dis Rep 14: 383-390, 2022.
14. Marino A, Munafò A, Zagami A, Ceccarelli M, Campanella E, Cosentino F, Moscatt V, Cantarella G, Di Mauro R, Bernardini R, *et al*: Ampicillin plus ceftriaxone therapy against *Enterococcus faecalis* endocarditis: A case report, guidelines considerations, and literature review. IDCases 28: e01462, 2022.
15. Cillóniz C, Dominedò C and Torres A: An overview of guidelines for the management of hospital-acquired and ventilator-associated pneumonia caused by multidrug-resistant Gram-negative bacteria. Curr Opin Infect Dis 32: 656-662, 2019.
16. El-Sokkary R, Uysal S, Erdem H, Kullar R, Pekok AU, Amer F, Grgić S, Carevic B, El-Kholy A, Liskova A, *et al*: Profiles of multidrug-resistant organisms among patients with bacteremia in intensive care units: An international ID-IRI survey. Eur J Clin Microbiol Infect Dis 40: 2323-2334, 2021.
17. Kalil AC, Metersky ML, Klompas M, Muscedere J, Sweeney DA, Palmer LB, Napolitano LM, O'Grady NP, Bartlett JG, Carratalà J, *et al*: Management of adults with hospital-acquired and ventilator-associated pneumonia: 2016 clinical practice guidelines by the infectious diseases society of America and the American thoracic society. Clin Infect Dis 63: e61-e111, 2016.
18. Papazian L, Klompas M and Luyt CE: Ventilator-associated pneumonia in adults: A narrative review. Intensive Care Med 46: 888-906, 2020.
19. Marino A, Campanella E, Ceccarelli M, Larocca L, Bonomo C, Micali C, Munafò A, Celesia BM, Nunnari G and Cacopardo B: Sarilumab administration in patients with severe COVID-19: A report of four cases and a literature review. World Acad Sci J 4: 24, 2022.
20. Ippolito M, Misseri G, Catalisano G, Marino C, Ingoglia G, Alessi M, Consiglio E, Gregoretti C, Giarratano A and Cortegiani A: Ventilator-associated pneumonia in patients with covid-19: A systematic review and meta-analysis. Antibiotics (Basel) 10: 545, 2021.
21. Rouzé A, Martin-Loeches I, Povoa P, Makris D, Artigas A, Bouchereau M, Lambiotte F, Metzelard M, Cuchet P, Geronimi CB, *et al*: Relationship between SARS-CoV-2 infection and the incidence of ventilator-associated lower respiratory tract infections: A European multicenter cohort study. Intensive Care Med 47: 188-198, 2021.
22. Blonz G, Kouatchet A, Chudeau N, Pontis E, Lorber J, Lemeur A, Planche L, Lascarrou JB and Colin G: Epidemiology and microbiology of ventilator-associated pneumonia in COVID-19 patients: A multicenter retrospective study in 188 patients in an un-inundated French region. Crit Care 25: 72, 2021.
23. Patro S, Sarangi G, Das P, Mahapatra A, Mohapatra D, Paty B and Chayani N: Bacteriological profile of ventilator-associated pneumonia in a tertiary care hospital. Indian J Pathol Microbiol 61: 375-379, 2018.
24. Ferrer M, Liapikou A, Valencia M, Esperatti M, Theessen A, Martinez JA, Mensa J and Torres A: Validation of the American Thoracic Society-Infectious Diseases Society of America guidelines for hospital-acquired pneumonia in the intensive care unit. Clin Infect Dis 50: 945-952, 2010.
25. Restrepo MI, Peterson J, Fernandez JF, Qin Z, Fisher AC and Nicholson SC: Comparison of the bacterial etiology of early-onset and late-onset ventilator-associated pneumonia in subjects enrolled in 2 large clinical studies. Respir Care 58: 1220-1225, 2013.
26. Looney WJ, Narita M and Mühlemann K: *Stenotrophomonas maltophilia*: An emerging opportunist human pathogen. Lancet Infect Dis 9: 312-323, 2009.
27. Wang N, Tang C and Wang L: Risk factors for acquired *Stenotrophomonas maltophilia* pneumonia in intensive care unit: A systematic review and meta-analysis. Front Med (Lausanne) 8: 808391, 2021.
28. Wang Y, Wang Y, Rong H, Guo Z, Xu J and Huang X: Risk factors of lower respiratory tract infection caused by *Stenotrophomonas maltophilia*: Systematic review and meta-analysis. Front Public Health 10: 5410, 2023.
29. Nakamura R, Oota M, Matsumoto S, Sato T and Yamano Y: In vitro activity and in vivo efficacy of cefiderocol against *Stenotrophomonas maltophilia*. Antimicrob Agents Chemother 65: e01436-e01420, 2021.
30. Stracquadanio S, Torti E, Longshaw C, Henriksen AS and Stefani S: In vitro activity of cefiderocol and comparators against isolates of gram-negative pathogens from a range of infection sources: SIDERO-WT-2014-2018 studies in Italy. J Glob Antimicrob Resist 25: 390-398, 2021.
31. Petraitis V, Petraitiene R, Kavaliauskas P, Naing E, Garcia A, Georgiades BN, Echols R, Bonomo RA, Yamano Y, Satlin MJ and Walsh TJ: Efficacy of cefiderocol in experimental *Stenotrophomonas maltophilia* pneumonia in persistently neutropenic rabbits. Antimicrob Agents Chemother 66: e0061822, 2022.
32. Hotta G, Matsumura Y, Kato K, Nakano S, Yunoki T, Yamamoto M, Nagao M, Ito Y, Takakura S and Ichiyama S: Risk factors and outcomes of *Stenotrophomonas maltophilia* bacteraemia: A comparison with bacteraemia caused by pseudomonas aeruginosa and acinetobacter species. PLoS One 9: e112208, 2014.
33. Ba BB, Feghali H, Arpin C, Saux MC and Quentin C: Activities of ciprofloxacin and moxifloxacin against *Stenotrophomonas maltophilia* and emergence of resistant mutants in an in vitro pharmacokinetic-pharmacodynamic model. Antimicrob Agents Chemother 48: 946-953, 2004.
34. Gil-Gil T, Martínez JL and Blanco P: Mechanisms of antimicrobial resistance in *Stenotrophomonas maltophilia*: A review of current knowledge. Expert Rev Anti Infect Ther 18: 335-347, 2020.
35. Prawang A, Chanjamlong N, Rungwara W, Santimaleeworagun W, Paiboonvong T, Manapattanasatein T, Pitirattanaworranat P, Kitseree P and Kanchanasurakit S: Combination therapy versus monotherapy in the treatment of *Stenotrophomonas maltophilia* infections: A systematic review and meta-analysis. Antibiotics (Basel) 11: 1788, 2022.
36. Shah MD, Coe KE, El Boghdadly Z, Wardlow LC, Dela-Pena JC, Stevenson KB and Reed EE: Efficacy of combination therapy versus monotherapy in the treatment of *Stenotrophomonas maltophilia* pneumonia. J Antimicrob Chemother 74: 2055-2059, 2019.
37. Bivona DA, Mirabile A, Bonomo C, Bonacci PG, Stracquadanio S, Marino A, Campanile F, Bonaccorso C, Fortuna CG, Stefani S, *et al*: Heteroaryl-ethylenes as new effective agents for high priority gram-positive and gram-negative bacterial clinical isolates. Antibiotics 11: 767, 2022.
38. Stracquadanio S, Bonomo C, Marino A, Bongiorno D, Privitera GF, Bivona DA, Mirabile A, Bonacci PG and Stefani S: *Acinetobacter baumannii* and Cefiderocol, between Cidality and Adaptability. Microbiol Spectr 10: e0234722, 2022.
39. Marino A, Stracquadanio S, Campanella E, Munafò A, Gussio M, Ceccarelli M, Bernardini R, Nunnari G and Cacopardo B: Intravenous fosfomycin: A potential good partner for cefiderocol. Clinical experience and considerations. Antibiotics (Basel) 12: 49, 2022.
40. The European Committee on Antimicrobial Susceptibility Testing. Breakpoint tables for interpretation of MICs and zone diameters. Version 13.0, 2023. http://www.eucast.org.
41. Biagi M, Tan X, Wu T, Jurkovic M, Vialichka A, Meyer K, Mendes RE and Wenzler E: Activity of potential alternative treatment agents for *Stenotrophomonas maltophilia* isolates nonsusceptible to levofloxacin and/or Trimethoprim-sulfamethoxazole. J Clin Microbiol 58: e01603-e01619, 2020.
42. Wu RX, Yu CM, Hsu ST and Wang CH: Emergence of concurrent levofloxacin- and trimethoprim/sulfamethoxazole-resistant *Stenotrophomonas maltophilia*: Risk factors and antimicrobial sensitivity pattern analysis from a single medical center in Taiwan. J Microbiol Immunol Infection 55: 107-113, 2022.

43. Chung HS, Kim K, Hong SS, Hong SG, Lee K and Chong Y: The sul1 gene in *Stenotrophomonas maltophilia* with high-level resistance to trimethoprim/sulfamethoxazole. Ann Lab Med 35: 246-249, 2015.
44. Hu LF, Chen GS, Kong QX, Gao LP, Chen X, Ye Y and Li JB: Increase in the prevalence of resistance determinants to trimethoprim/sulfamethoxazole in clinical *Stenotrophomonas maltophilia* isolates in China. PLoS One 11: 157693, 2016.
45. Toleman MA, Bennett PM, Bennett DMC, Jones RN and Walsh TR: Global emergence of trimethoprim/sulfamethoxazole resistance in *Stenotrophomonas maltophilia* mediated by acquisition of sul Genes. Emerg Infect Dis 13: 559-565, 2007.
46. Yin C, Yang W, Meng J, Lv Y, Wang J and Huang B: Co-infection of Pseudomonas aeruginosa and *Stenotrophomonas maltophilia* in hospitalised pneumonia patients has a synergic and significant impact on clinical outcomes. Eur J Clin Microbiol Infect Dis 36: 2231-2235, 2017.
47. McDaniel MS, Schoeb T and Swords WE: Cooperativity between *Stenotrophomonas maltophilia* and *Pseudomonas aeruginosa* during polymicrobial airway infections. Infect Immun 88: e00855-e00819, 2020.
48. Mcdaniel MS, Lindgren NR, Billiot CE, Valladares KN, Sumpter NA and Swords WE: *Pseudomonas aeruginosa* promotes persistence of *Stenotrophomonas maltophilia* via increased adherence to depolarized respiratory epithelium. Microbiol Spectr 11: e0384622, 2022.