SPANDIDOS PUBLICATIONS

WORLD ACADEMY OF SCIENCES JOURNAL 6: 40, 2024

Nipple adenoma, a rare benign tumor in accessory breasts: A case report

RAWA M. ALI[1,2], ABDULWAHID M. SALIH[1,3], LANA R.A. PSHTIWAN[1], ABDULLAH A. QADIR[1], HIWA O. BABA[1], ARI M. ABDULLAH[1,4], HALKAWT OMER ALI[1], HARDI M. DHAHIR[1], REBAZ O. MOHAMMED[1] and FAHMI H. KAKAMAD[1,3,5]

[1]Department of Scientific Affairs, Smart Health Tower, Sulaymaniyah, Kurdistan 46001, Iraq; [2]Hospital for Treatment of Victims of Chemical Weapons, Halabja, Kurdistan 46018, Iraq; [3]College of Medicine, University of Sulaimani, Sulaymaniyah, Kurdistan 46001, Iraq; [4]Department of Pathology, Sulaymaniyah Teaching Hospital, Sulaymaniyah, Kurdistan 46001, Iraq; [5]Kscien Organization for Scientific Research, Sulaymaniyah, Kurdistan 46001, Iraq

Received April 22, 2024; Accepted June 7, 2024

DOI: 10.3892/wasj.2024.255

Abstract. Nipple adenoma, an uncommon benign tumor, typically appears between the fourth and fifth decades of life, occasionally manifesting in accessory breasts. The embryonic mammary ridges give rise to accessory breasts along the milk line, and the lack of involution results in supernumerary breasts, including accessory nipples. This study aims to report a case of adenoma originating from an accessory breast nipple. The present study describes the case of a 23-year-old female patient who presented with right axillary discomfort and swelling. A physical examination revealed a tender, non-inflamed lump. A breast ultrasonography revealed features compatible with an accessory nipple, confirmed by excisional biopsy revealing adenoma. Throughout the 4-month follow-up period, no signs of recurrence were observed. Although rare, accessory breast tissue can harbor neoplasms, with nipple adenoma posing a diagnostic challenge often confounded with Paget's disease. Histologically, nipple adenomas exhibit diverse patterns, emphasizing the importance of a precise diagnosis. Adenoma of the accessory nipples is a rare condition that necessitates proper clinical assessment. Surgical excision remains the standard, yielding favorable outcomes.

Introduction

Nipple adenoma is a rare, benign tumor of the breast that occurs between the fourth and fifth decades of life, predominantly affecting females, and very rarely encountered in accessory breasts (1). The breast (mammary gland) normally develops in the early embryonic period as two ectodermal thickenings known as mammary milk lines, which form along the sides of the embryo during the sixth week of development and extend from the axillary region to the groin. During normal development, the majority of the embryonic mammary ridges along the milk line undergo involution except for two segments in the pectoral area that eventually become breasts. When one of these ridges fails to involute, supernumerary breasts form. This condition, variably known as supernumerary breast, ectopic breast, or polymastia (2). In 2022, benign breast tumors were extensively studied with 839 publications. Common types include fibroadenoma, fat necrosis, papilloma, cyst, mastitis, hyperplasia, adenoma and granular cell tumors (3). Nipple adenoma, also termed nipple duct adenoma, papillary adenoma, erosive adenomatosis, florid papillomatosis, papillomatosis of the nipple and subareolar duct papillomatosis, represents a subtype of intraductal papilloma involving the terminal portion of the galactophorous ducts. Clinically, nipple adenoma can be mistaken for Paget's disease, while pathologically, it could be misclassified as a tubular carcinoma. Although axillary tumors have a variety of differential diagnoses ranging from benign to malignant, nipple neoplasms arising from axillary accessory breasts are rarely mentioned in the English literature (4).

The present study reports the case of a patient with adenoma arising from an accessory breast nipple, and also provides a brief literature review. The references have been inspected for reliability (5).

Case report

Patient information. A 23-year-old female patient presented to Smart Health Tower (Sulaymaniyah, Iraq) with a 4-year history of right axillary discomfort, pain and swelling. The patient, a non-smoker with no history of diabetes, had one child and breastfed for ~17 months, with the last lactation occurring ~2 years prior to the current presentation. An investigation into the surgical history of the patient revealed a cesarean section,

Correspondence to: Dr Fahmi H. Kakamad, College of Medicine, University of Sulaimani, HC8V+F66, Madam Mitterrand Street, Sulaymaniyah, Kurdistan 46001, Iraq
E-mail: fahmi.hussein@univsul.edu.iq

Key words: accessory breast, supernumerary nipple, mammary, adenoma, nipple

while an analysis of her family history did not reveal any notable findings.

Clinical finding. Upon a clinical examination, a tender, firm lump was detected in the right axillary region. The lump did not display signs of inflammation, such as redness and warmth.

Diagnostic approach. A breast ultrasound (data not shown) revealed a homogeneous background echotexture with a fibroglandular pattern. Bilateral accessory axillary breasts were observed, with the right side being larger, displaying normal morphology without any solid masses or distortions in either breast. Both primary and accessory nipples were normal. The breasts exhibited normal skin thickness and contours, and the axillary lymph nodes were unremarkable. Unfortunately, the ultrasound images were not captured due to limited resources in the present country, but the ultrasonography report was available. Additionally, the complete blood count results were within the normal range.

Therapeutic intervention. The mass was excised under local anesthesia, with hemostasis achieved without complications, and the wound was closed using absorbable sutures. Upon a gross examination, the skin excisional biopsy measured 1.2x0.8 cm with a thickness of 0.3 cm, revealing a 0.5-cm skin-covered, exophytic nodule, away from the peripheral and deep margins.

The histopathological examination was performed as follows: The specimen was fixed in 10% neutral-buffered formalin at room temperature for a period of 1 to 3 days. It was then processed using the DiaPath Donatello automated processor, progressing through the designated stages: Samples were held in 10% neutral-buffered formalin for an average duration of 20 min, then placed in deionized water for 10 min. Dehydration was conducted using alcohol, beginning with a concentration of 70% for 1 h, followed by 95% for 1 h, 99% for 1 h and 30 min, and another station of 99% for 1 h and 30 min. Clearing was performed through three stations of xylene, each lasting 1 h for a total of 3 h. Finally, infiltration with paraffin wax was carried out in three stations, each lasting 1 h for a total of 3 h. The blocks were subsequently embedded in paraffin wax using the Sakura Tissue-Tek embedding center (Sakura Finetek USA). The blocks were then trimmed and sectioned with the Sakura Accu-Cut SRM microtome (Sakura Finetek USA) to a thickness of 5 μm. The sections were floated in a Sakura 1451 water bath, maintained at 40-50˚C, and then mounted onto standard glass slides. These slides were then placed in an oven set at 60-70˚C and left overnight. The following day, the slides were stained with hematoxylin and eosin using the DiaPath Giotto autostainer, following these stages: First, the slides were immersed in xylene for three intervals of 7, 7 and 5 min. They were then treated with 100% alcohol in three stages lasting 7, 6 and 5 min, followed by 90% alcohol for 4 min, 70% alcohol for 3 min, and then rinsed with tap water for 2 min. They were then stained with Hematoxylin Gill II for 8 min, prepared from Sigma-Aldrich Hematoxylin Natural Black 1. This was followed by rinsing in tap water for 4 min, a brief dip in ammonia water for 1 min, another tap water rinse for 1 min, and then 70% alcohol for 2 min. Subsequently, the slides were stained with Eosin for 5 min, prepared from Sigma-Aldrich Eosin Y disodium salt, followed by a 1-min rinse in tap water. The dehydration process involved 70% alcohol for 15 sec, 90% alcohol for 2 min, and 100% alcohol in three stages of 3, 3 and 4 min. The slides were then cleared in xylene in three stages of 3, 5 and 4 min. After drying for 5 min, the slides were covered with SurgiPath Sub-X mounting medium and a coverslip. The microscope used for examination was an Olympus BX-51 microscope with a camera adaptor (Olympus U-TV0.5XC-3) (Olympus Corporation) for obtaining images.

The histopathological examination revealed a relatively ill-defined proliferation of variably sized ducts within the dermis. These ducts comprised a basal layer of flat to cuboidal myoepithelial cells with oval nuclei and fine chromatin, and a luminal epithelial layer of cuboidal to low columnar cells with oval nuclei exhibiting more open chromatin and conspicuous nucleoli, devoid of significant cytologic atypia and atypical mitotic figures. Some ducts displayed intraluminal micropapillary proliferation and bridging with streaming nuclei. The surrounding dermis exhibited fibrosis with patchy and mild mixed inflammatory cells but lacked a desmoplastic reaction. The overlying epidermis showed acanthosis, papillomatosis, and orthokeratosis. These findings were consistent with an adenoma arising within an accessory nipple (Fig. 1).

Follow-up and outcome. The patient was discharged in good health on the first post-operative day. A 4-month follow-up revealed no clinical signs of recurrence.

Discussion

Accessory breast tissue is a relatively uncommon occurrence ranging from 0.4 to 0.6%, typically originating alongside the embryogenic mammary ridge, extending from the axilla to the groin, and is commonly found in the axilla (2). Neoplasms in the axillary nipple can manifest as either benign or malignant lesions. Nipple adenoma, a rare benign tumor, develops within the superficial part of the nipple (6). Paget's disease of the nipple is the primary differential diagnosis (1). According to the study by Shinn *et al* (1), until 2015, only four published reports of nipple adenoma in an accessory nipple had been identified. A clinical examination often reveals a palpable lump and an eroded, ulcerated, or crusted nipple as typical findings (7). Previous case reports have documented varying clinical presentations of nipple adenoma in accessory breasts. For example, Shioi *et al* (4) described the case of an 82-year-old female patient with a painful right axillary tumor, whereas, Malagimani *et al* (6) reported the case of a 24-year-old female patient experiencing continuous pain and bleeding from her right accessory nipple, with examination revealed no neoplastic lesions or palpable axillary lymph nodes. In the case in the present study, the patient presented with a right-sided axillary swelling and a tender firm lump upon examination.

Nipple adenoma microscopically presents with the proliferation of a small tubular structures exhibiting a double-layered appearance, although it can display a wide range of histopathological features (4). Rosen and Caicco divided nipple adenomas into four morphological patterns: i) Sclerosing papillomatosis, which can resemble sclerosing papilloma; ii) papillomatosis, characterized by florid papillary hyperplasia of ductal epithelium; iii) adenosis, featuring

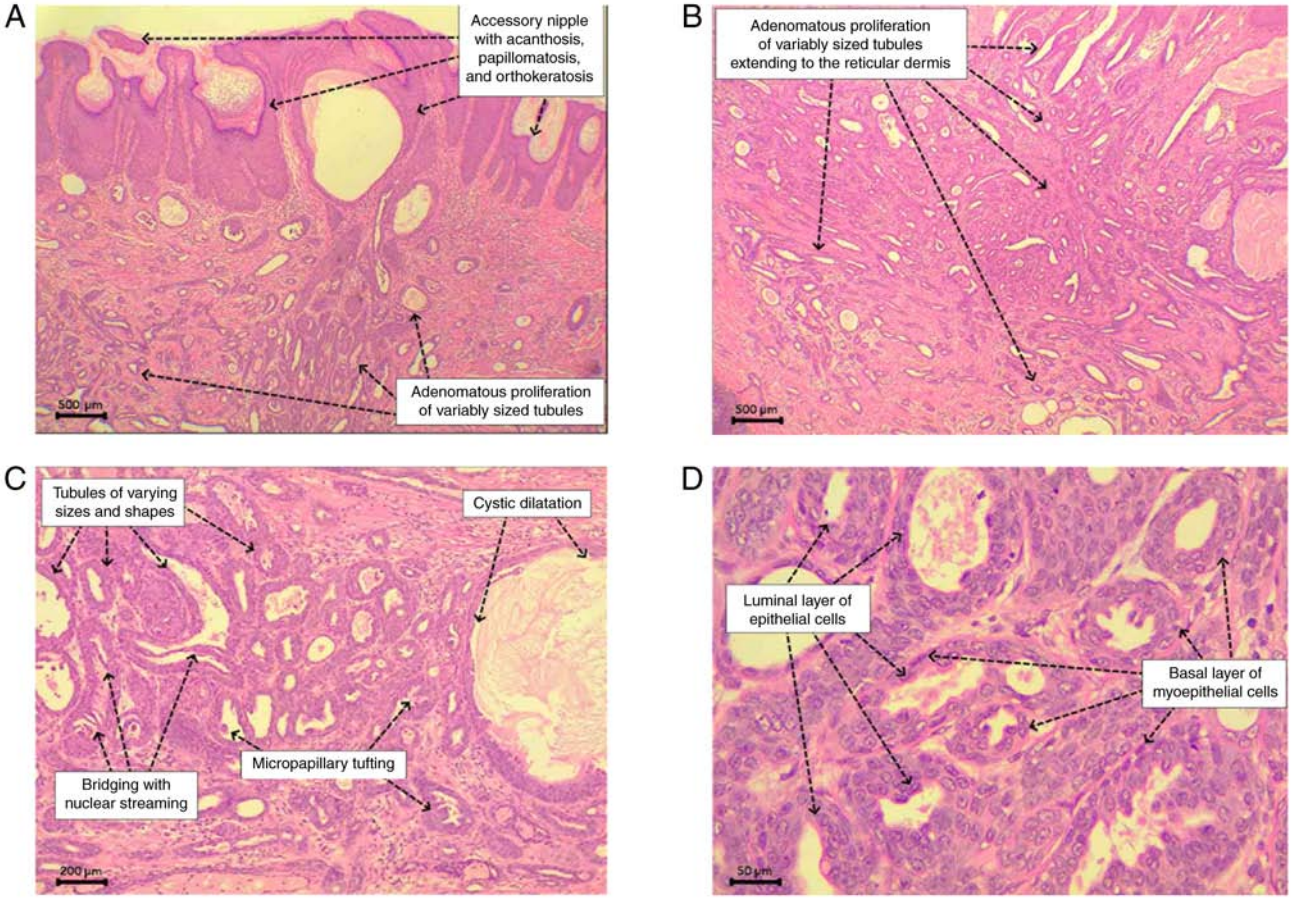

Figure 1. (A) The accessory nipple has an acanthotic epidermis with papillomatosis and orthokeratosis. Underneath, there is an irregular proliferation of variably sized ducts. (B) The irregular ductular proliferation extends down to the reticular dermis and is surrounded by fibrosis. (C) The ducts are of varying sizes and shapes, with some exhibiting cystic dilatation, micropapillary tufting, and bridging with streaming nuclei. The surrounding fibrotic dermis contains a mild mixed inflammatory infiltrate. (D) The ducts are lined by an outer flat to cuboidal layer of basal myoepithelial cells that have oval nuclei with fine chromatin, and an inner luminal layer of cuboidal to low columnar epithelial cells that have more open chromatin with conspicuous nucleoli. Hematoxylin and eosin staining was performed. (A and B) Magnification, x40; (C) magnification, x40; and (D) magnification, x400.

evident myoepithelial hyperplasia; and iv) a combination of these proliferative forms (8). However, there is no apparent indication of prognostic relevance associated with these patterns, and there is also a lack of evidence suggesting variance in their underlying pathogenesis (9). The case described herein exhibited a predominant pattern of adenosis admixed with focal micropapillary formations.

Radiographically, an ultrasound, mammography and magnetic resonance imaging (MRI) are commonly utilized modalities for identifying and characterizing nipple adenomas. Among these, an ultrasound is considered the most clinically useful, as it can delineate soft tissue nodularity, assess internal vascularity and facilitate image-guided fine-needle aspiration. The lesion typically appears well-defined and hypoechoic on the ultrasound scan, and may exhibit posterior echo enhancement. The MRI enhancement curve of nipple adenomas may mimic that of malignant lesions, displaying rapid uptake, peaking at 60-90 sec followed by washout, which can lead to diagnostic confusion. The results of mammography may vary, ranging from benign calcification to dense lesions with well-defined or irregular edges. It should be noted that no single imaging modality should be relied upon in isolation for diagnosing nipple adenoma (10). In the present study, a breast ultrasound unexpectedly revealed normal accessory breasts and nipples without evidence of a mass-forming lesion in either the accessory breasts or the normal breast tissue. In terms of management, the treatment of choice for an adenoma of the accessory nipple is the surgical excision of the tumor. This approach ensures complete removal of the tumor, thus alleviating any associated symptoms. The prognosis following surgical intervention is generally favorable, with a low risk of recurrence (10). While the link between breast adenomas and carcinomas remains incompletely understood, breast adenomas are generally considered benign tumors. Complete excision and a histopathological examination are crucial for an accurate diagnosis and for the prevention of the misdiagnosis of cancer, thereby avoiding unnecessary and costly surgery (4). In the case presented herein, the mass was successfully excised under local anesthesia with no complications, and the subsequent histopathological examination confirmed the benign nature of the tumor. It is worth highlighting that the efficient management of the case in the present study aligns with previous cases reported by in the studies by Shinn *et al* (1), Shioi *et al* (4) and Malagimani *et al* (6).

Nipple adenoma, despite its benign nature, has been found to be associated with breast cancer in clinical studies, with some cases revealing concurrent active breast cancer or clinically-occult invasive disease. Although establishing a direct

causal link remains challenging due to the rarity of malignant transformation, heightened suspicion for co-existing breast cancer is warranted in cases of nipple adenoma (8,11,12). Additionally, the expanding growth pattern and potential for local recurrence of nipple adenoma can significantly affect the quality of life of patients, particularly in women of child-bearing age reliant on intact nipple function for breastfeeding. Thus, a comprehensive clinical evaluation and screening for co-existing breast cancer are imperative in the management of nipple adenoma (13).

While specific risk factors for its occurrence in younger patients have not been extensively studied, several potential contributors have been suggested. Hormonal fluctuations due to puberty, menstrual cycles, or hormonal medications may stimulate breast tissue growth. Genetic predisposition, particularly with a family history of breast conditions, could elevate the risk. Reproductive factors, such as early menarche or nulliparity may also play a role, along with breast trauma or injury. Lifestyle factors such as diet and alcohol consumption may contribute as well. However, the exact association between these factors and nipple adenoma in younger patients requires further investigation due to the limited evidence available since a significant portion of the literature concerning nipple adenoma comprises only individual case reports and series of cases (14).

In conclusion, adenoma of accessory nipples is a rare condition that necessitates careful clinical evaluation and diagnostic workup to ensure proper management. Surgical excision remains the standard approach for addressing this benign tumor, with favorable long-term outcomes for affected individuals.

Acknowledgements

Not applicable.

Funding

No funding was received.

Availability of data and materials

The datasets used and/or analyzed during the current study are available from the corresponding author on reasonable request.

Authors' contributions

RMA and AMS were major contributors to the conception of the study, as well as in the literature search for related studies. AAQ and FHK were involved in the literature review, the design of the study and in the writing of the manuscript. AMA was the pathologist who performed the histopathological diagnosis. LRAP, HOB, HOA, HMD and ROM were involved in the literature review, the design of the study, in the critical revision of the manuscript, and in the processing of the figure. FHK and RMA confirm the authenticity of all the raw data. All authors have read and approved the final manuscript.

Ethics approval and consent to participate

In our locality, ethical approval is not required for case studies involving fewer than three cases. Written informed consent was obtained from the patient for her participation in the present study.

Patient consent for publication

Written informed consent was obtained from the patient for the publication of the present study and any accompanying images.

Competing interests

The authors declare that they have no competing interests.

References

1. Shinn L, Woodward C, Boddu S, Jha P, Fouroutan H and Péley G: Nipple adenoma arising in a supernumerary mammary gland: A case report. Tumori 97: 812-814, 2011.
2. Yefter ET and Shibiru YA: Fibroadenoma in axillary accessory breast tissue: A case report. J Med Case Rep 16: 1-6, 2022.
3. Salih A, Ahmed A, Mohammed S, Qadir A, Bapir N and Fatah G: Benign tumor publication in one year (2022): A cross-sectional study. Barw Med J 1: 20-25, 2023.
4. Shioi Y, Nakamura SI, Kawamura S and Kasami M: Nipple adenoma arising from axillary accessory breast: A case report. Diagn Pathol 7: 162, 2012.
5. Muhialdeen AS, Ahmed JO, Baba HO, Abdullah IY, Hassan HA, Najar KA, Mikael TM, Mustafa MQ, Mohammed DA, Omer DA, *et al*: Kscien's list; A new strategy to discourage predatory journals and publishers (Second Version). Barw Med J 1: 30-32, 2023.
6. Malagimani SC, Jashvanth CT, Kasasomasekhar K and Paga U: Case report: A rare case of accessory nipple (Polythelia) presenting as papillary adenoma. J Evolution Med Dent Sci 3: 2005-2008, 2014.
7. Healy CE, Dijkstra B, Walsh M, Hill AD and Murphy J: Nipple adenoma: A differential diagnosis for Paget's disease. Breast J 9: 325-326, 2003.
8. Rosen PP and Caicco JA: Florid papillomatosis of the nipple: A study of 51 patients, including nine with mammary carcinoma. Am J Surg Pathol 10: 87-101, 1986.
9. Mills SE, Carter D, Greenson JK, Reuter VE and Stoler MH (eds): Sternberg's diagnostic surgical pathology. 5th edition. Lippincott Williams & Wilkins, Philadelphia, PA, 2012.
10. Tatterton MR and Fiddes R: Nipple adenoma: A review of the literature. Ann Breast Surg 3: e8586, 2019.
11. Jones MW and Tavassoli FA: Coexistence of nipple duct adenoma and breast carcinoma: A clinicopathologic study of five cases and review of the literature. Mod Pathol 8: 633-636, 1995.
12. Gudjónsdóttir A, Hägerstrand I and OStberg G: Adenoma of the nipple with carcinomatous development. Acta Pathol Microbiol Scand A 79: 676-680, 1971.
13. Combi F, Palma E, Montorsi G, Gambini A, Segattini S, Papi S, Andreotti A and Tazzioli G: Management of nipple adenomas during pregnancy: A case report. Int Breastfeed J 18: 19, 2023.
14. Berger O, Gersh G and Talisman R: Nipple adenoma: Systematic review of literature. Plast Reconstr Surg Glob Open 12: e5827, 2024.