SPANDIDOS PUBLICATIONS

WORLD ACADEMY OF SCIENCES JOURNAL 6: 57, 2024

Effect of forceps biopsy on bronchial washing results in patients with endoscopically visible lung tumors

HAREM K. AHMED[1], KAMARAN AMIN QARADAKHY[2], KOSAR MOHAMED ALI[2], FAHMI H. KAKAMAD[1-3], BERUN A. ABDALLA[1,3] and DILAN S. HIWA[1]

[1]Department of Scientific Affairs, Smart Health Tower, Sulaymaniyah, Kurdistan 46001, Iraq; [2]College of Medicine, University of Sulaimani, Sulaymaniyah, Kurdistan 46001, Iraq; [3]Kscien Organization for Scientific Research, Sulaymaniyah, Kurdistan 46001, Iraq

Received April 22, 2024; Accepted July 9, 2024

DOI: 10.3892/wasj.2024.272

Abstract. Enhancing diagnostic bronchoscopy techniques is paramount for lung cancer detection; bronchial washing is one of those modalities. However, there is controversy regarding the optimum sequence of performing this procedure in relation to biopsy. The present study aimed to assess the most effective sequence of bronchial washing in relation to bronchial biopsy for diagnosing lung cancer. The present study was a single-center prospective study carried out over a period of 18 months. The study included patients >18 years of age with mass or suspected lesions on a chest computed tomography and an endoscopically visible mass. They were randomly assigned to a bronchial washing before the forceps biopsy group and a bronchial washing after the forceps biopsy group. Bronchial washing and forceps biopsy were performed under cytological and histopathological analysis, respectively. The present study included 50 patients with a mean age of 72 years. The males comprised 36 (72%) of the patients. The pre-biopsy bronchial wash (pre-BW) yielded positive results in 21 (42%) patients, and the post-biopsy bronchial wash (post-BW) yielded positive results in 23 (46%) patients. The biopsy results revealed that 22 (44%) of the cases were squamous cell carcinoma, 18 (36%) were adenocarcinoma, 8 (16%) were small cell lung carcinoma, 1 (2%) was acinar cell carcinoma, and 1 (2%) was not malignant. A comparison of pre-BW and post-BW revealed a statistically significant difference between them (P-value <0.001). Pre- and post-BW may affect the yield of diagnostic outcomes for endoscopically visible lung tumors. However, additional research, such as studies using larger sample sizes or meta-analyses, is required to determine the efficacy of this approach.

Correspondence to: Dr Fahmi H. Kakamad, College of Medicine, University of Sulaimani, HC8V+F66, Madam Mitterrand Street, Sulaymaniyah, Kurdistan 46001, Iraq
E-mail: fahmi.hussein@univsul.edu.iq

Key words: bronchoalveolar lavage, diagnosis, pulmonary carcinoma, pulmonary malignancy, bronchoscopy

Introduction

Over the past decade, notable changes have occurred in the epidemiology and prevention of lung cancer due to shifts in smoking habits, major progress in understanding the genetic basis of lung cancer, the crucial role of the immune system in controlling lung cancer, and the growing variety of treatment options available. The 5-year survival rate of patients with lung cancer has exhibited an increase from 15.6% in 2011 to 19.4% in 2019. However, despite these advancements, lung cancer remains a leading cause of cancer-related mortality. In 2018, ~2.09 million new cases, constituting 11.6% of the total cancer cases, and 1.76 million deaths, accounting for 18.4% of the total cancer-related deaths, were attributed to lung cancer. This confirms its status as the leading cause of cancer-related mortality among males. Furthermore, it is the third most common type of cancer and the second leading cause of cancer-related mortality among females (1,2). Low-dose computed tomography (CT) is standard practice for lung cancer screening. This specific screening method achieves a selectivity of 85% and a specificity of 99% compared to the absence of screening. However, the overall false-positive rate can be as high as 81%. This substantial rate necessitated supplementary imaging or diagnostic procedures to validate the findings (3).

Bronchial washing is a clinical procedure used to collect cellular samples from the airways that are linked to the lungs. It is frequently used to identify infections and detect potential cancerous or pre-cancerous cellular changes. This method involves using a bronchoscope, a flexible and narrow instrument equipped with a light and a lens for visual guidance, to maneuver through the nasal or oral cavity, and into the lungs. By contrast, forceps biopsy involves the use of a specialized instrument to extract a small tissue sample from the tumor for further investigation (4-6). There is empirical evidence to indicate that the application of both diagnostic techniques, in conjunction, can result in a diagnostic yield exceeding 90% in patients with observable lung cancers during endoscopy. Consequently, it has been demonstrated that the utilization of both techniques in combination outperforms the diagnostic accuracy of either technique used in isolation (7). Among the diagnostic procedures conducted through bronchoscopy, forceps biopsy stands

out for enhancing the diagnostic yield by almost 95%. By contrast, the diagnostic yield associated with bronchial washing for lung cancers featuring visibly observable tumors during endoscopy ranges widely from 45 to 85%. Generally, it falls below that achieved by forceps biopsy (8). The necessity of coupling bronchial washing with forceps biopsy has been a topic of debate. Specifically, certain investigations have reported a substantial increase in diagnostic yield by incorporating bronchial washing alongside forceps biopsy. Conversely, other studies have found no significant improvement in the overall diagnostic yield by employing bronchial washing in conjunction with forceps biopsy (9).

The majority of bronchoscopists collect washing samples in a seemingly arbitrary sequence by their personal preferences. In theory, it is conceivable that the diagnostic yield of bronchial washing could be elevated following forceps biopsy or brushing, as these techniques may prompt the shedding of additional malignant cells from the tumor into the washing samples. In addition to the ongoing debate surrounding the utility of bronchial washing, various other elements of this methodology, such as the ideal quantity of saline to be administered and the appropriate timing of the procedure in relation to biopsy or brushing, have yet to be definitively established (10). The present study aimed to compare the diagnostic yield of bronchial washing conducted before and after forceps biopsy in patients presenting with visible lung tumors during an endoscopy.

Patients and methods

Study design and setting. The present single-center prospective study was carried out over a period of 18 months, from June, 2022 to January, 2024 in an inpatient bronchoscopic unit at Shar Teaching Hospital in Sulaymaniyah, Iraq. The present study received approval from the Sulaimani University Ethics Committee (2024/no. 83). Written informed consent was obtained from the patients for their participation in the present study. The patients were assigned to a bronchial washing group before the forceps biopsy and a bronchial washing group after the forceps biopsy.

Inclusion and exclusion criteria. The patients were selected based on certain inclusion criteria, including adult patients >18 years of age, those with a mass or suspected lesions on chest CT scans, and those with an endoscopically visible mass within the bronchial tree. The exclusion criteria included patients <18 years of age, those previously diagnosed with bronchogenic carcinoma, and individuals with mucosal changes and external compression. All the studies included as references were checked for eligibility (11).

Procedure protocol. The bronchoscopies were performed by an experienced pulmonologist or by fellows specializing in pulmonology under the supervision of an experienced doctor. In addition, one or two well-trained nurses assisted the bronchoscopist with each procedure. The patients were required to fast for 6 h prior to the procedure and the procedure was performed under conscious sedation by administering pethidine hydrochloride (25-50 mg) (Gerot Lannach), with (1-3 mg) midazolam (HiGen Pharmaceutical) accordingly, a few minutes prior to the procedure. A 5.7-mm-diameter bronchoscope (Olympus Corporation) was used. Lidocaine was delivered to the upper airway and nares via spray, while to the lower airway via lidocaine injection (1%). All patients with endoscopically visible tumors underwent bronchial washing and forceps biopsy according to the assigned sequence. Between 10-20 ml of normal saline were instilled over the tumors before and after the biopsy. The latter usually became bloody; this action was repeated until a 20-ml returned aspirate was collected in a trap bottle. The aim of the forceps biopsy was to obtain at least four sections of tissue for histopathological and immunohistochemical analyses, if indicated [the histopathological and immunohistochemical analyses for the study were not conducted at the authors' center (Smart Health Tower), but at an external center].

Statistical analyses. The data collected from the medical profiles and the examination results of the patients were analyzed using the Statistical Package for Social Sciences (SPSS version 27.0; IBM Corp.). For this purpose, both descriptive and inferential statistical tests were utilized. A P-value <0.05 was considered to indicate a statistically significant difference. Fisher's exact test was used to compare the pre- and post-bronchial washing (pre-BW and post-BW, respectively) results. Additionally, this test was employed to compare the morphological and histopathological results with the pre-and post-BW outcomes.

Results

The present study included 50 patients with an average age of 72.1 years (±10.3) ranging from 52 to 93 years. The males comprised 36 (72%) of the patients. As regards the smoking status, 9 (18%) patients had 0-1 pack years, 4 (8%) patients had 1-20 pack years, 21 (42%) patients had 20-40 pack years, and 16 patients (32%) had >40 pack years. In terms of their occupation, 29 (58%) were retired. As regards their medical history, 10 (20%) of the patients had hypertension (HTN). The most frequent chief complaint was chronic cough in 28 (56%) patients (Table I).

The chest X-ray revealed abnormal findings in 38 (76%) patients. As regards the size of their masses, the CT scan results indicated that 14 (28%) were between 5 and 7 cm, and only 1 patient (2%) had a mass located in the right main bronchus. Morphological analysis of the lesions revealed that 40 (80%) were tumorous (Table II). The pre-biopsy bronchial wash (pre-BW) was positive in 21 patients (42%), while the post-biopsy bronchial wash (post-BW) was positive in 23 patients (46%). Of note, four pre-BW positive results turned negative post-BW, and six pre-BW negative results turned positive post-BW. This change was statistically significant (P-value <0.001; Table III). The biopsy results revealed that 22 (44%) of the cases were squamous cell carcinoma (Fig. 1), 18 (36%) were adenocarcinoma (Fig. 2), 8 (16%) were small cell lung carcinoma (Fig. 3), 1 (2%) was acinar cell carcinoma and 1 (2%) was non-malignant. However, the comparison of the morphological and histopathological findings of the endobronchial lesions with the corresponding pre-BW and post-BW results did not reveal any significant differences (P-value >0.05; Table IV).

Table I. Demographic and clinical characteristics of the patients.

Variables	Value
Age (mean ± SD)	72.10±10.30 years
Sex, n (%)	
Male	36 (72)
Female	14 (28)
Occupation, n (%)	
Retired	29 (58)
Housewife	9 (18)
Worker	11 (22)
Employee	1 (2)
Smoking habit PY, n (%)	
0-1 PY	9 (18)
1-20 PY	4 (8)
20-40 PY	21 (42)
>40 PY	16 (32)
Chief complaint, n (%)	
Chronic cough	28 (56)
Dyspnea	10 (20)
Hemoptysis	6 (12)
Cough	4 (8)
Productive cough	2 (4)
Previous medical history, n (%)	
None	20 (40)
HTN	10 (20)
IHD	7 (14)
DM	6 (12)
DM and HTN	2 (4)
COPD	1 (2)
IHD and COPD	1 (2)
CLD	1 (2)
RA	1 (2)
Negative	1 (2)

PY, pack-year; SD, standard deviation; HTN, hypertension; IHD, ischemic heart disease; DM, diabetes mellitus; COPD, chronic obstructive lung disease; CLD, chronic liver disease; RA, rheumatoid arthritis.

Table II. Summary of lesion characteristics with pre- and post-BW results.

Variables	Value
Mass size, n (%)	
<3 cm	5 (10)
3-5 cm	11 (22)
5-7 cm	14 (28)
>7 cm	12 (24)
None	4 (8)
Lung collapse	3 (6)
Suspected lung collapse	1 (2)
Location, n (%)	
Right upper lobe	10 (20)
Left lower lobe	10 (20)
Left upper lobe	11 (22)
Right lower lobe	13 (26)
Right middle lobe	5 (10)
Right main bronchus	1 (2)
Morphology of endobronchial lesion, n (%)	
Tumorous	40 (80)
Infiltrative	7 (17)
Tumorous and Necrosis	1 (2)
Submucosal	1 (2)
Fungating	1 (2)
Chest X-ray, n (%)	
Abnormal	38 (76)
Normal	12 (24)
Pre-BW, n (%)	
Positive	21 (42)
Negative	29 (58)
Post-BW, n (%)	
Positive	23 (46)
Negative	27 (54)

Pre-BW, pre-biopsy bronchial wash; post-BW, post-biopsy bronchial wash.

Discussion

The effectiveness of using bronchial washing as a diagnostic tool for visually detectable lung cancers during endoscopy is a subject of debate. Certain individuals argue against its use, citing cost and time constraints without notable improvements in diagnostic yield (12,13). On the other hand, others disagree, and present evidence of an improved diagnostic accuracy compared to relying solely on forceps biopsy, suggesting that it may even be cost-effective (14,15). Forceps biopsy, brushing and bronchial washing through flexible bronchoscopy are commonly used to make the cytological or histological diagnosis. Combining these procedures can achieve a diagnostic yield as high as 85 to 94% in patients with endoscopically visible lung cancers. The critics argue for further evidence to support its inclusion in diagnostic protocols, particularly when combined with other sampling methods (5,16,17).

Smoking represents a prominent risk factor in the development of lung cancer, with the duration and intensity of smoking contributing to an elevated likelihood of developing this condition. Carcinogenic substances found in cigarette smoke have the potential to harm the epithelial cells of the lungs, consequently fostering tumor growth. It is worth highlighting that lung cancer can also manifest in individuals who have never smoked or have been extensively exposed to secondhand smoke. Regrettably, there is a paucity of research pertaining to the impact of smoking on forceps biopsy and bronchial wash outcomes in patients presenting with visually detectable lung tumors (18). The findings of the present

Table III. Comparison between pre-BW and post-BW.

Parameter	Post-BW positive, n (%)	Post-BW negative, n (%)	Total, n (%)	P-value
Pre-BW positive, n (%)	17 (73.9)	4 (14.8)	21 (42.0)	<0.001
Pre-BW negative, n (%)	6 (26.1)	23 (85.2)	29 (58.0)	
Total, n (%)	23 (100.0)	27 (100.0)	50 (100.0)	

BW, bronchial wash.

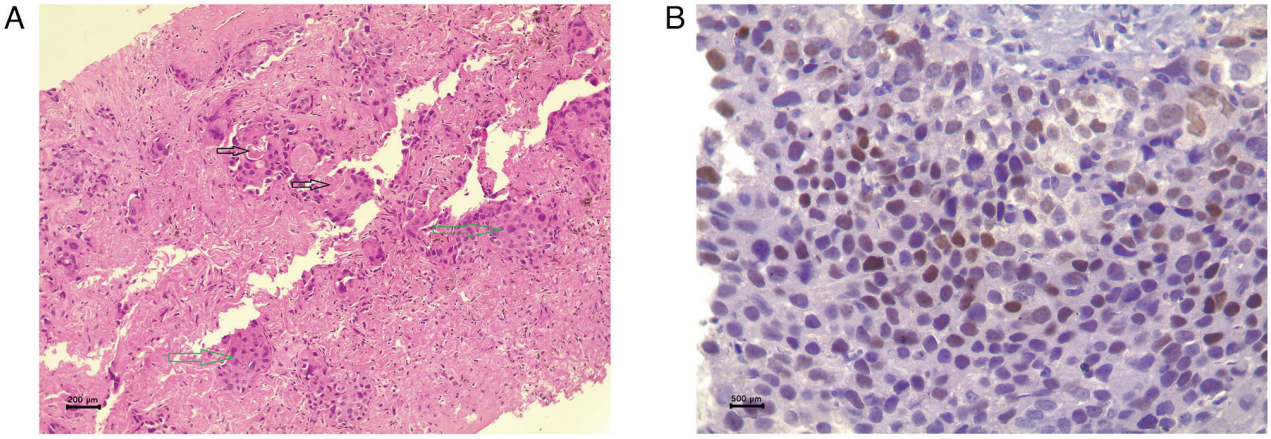

Figure 1. Histopathological and immunohistochemical images of a case with squamous cell carcinoma/ (A) Section displaying nests of malignant epithelioid cells (green arrows) with evidence of extracellular keratin formation (small dark arrows) indicating squamous cell carcinoma, stained with hematoxylin and eosin; magnification, x10. (B) Immunostaining image demonstrating a positive p63 nuclear staining pattern in the tumor cells of lung squamous cell carcinoma.

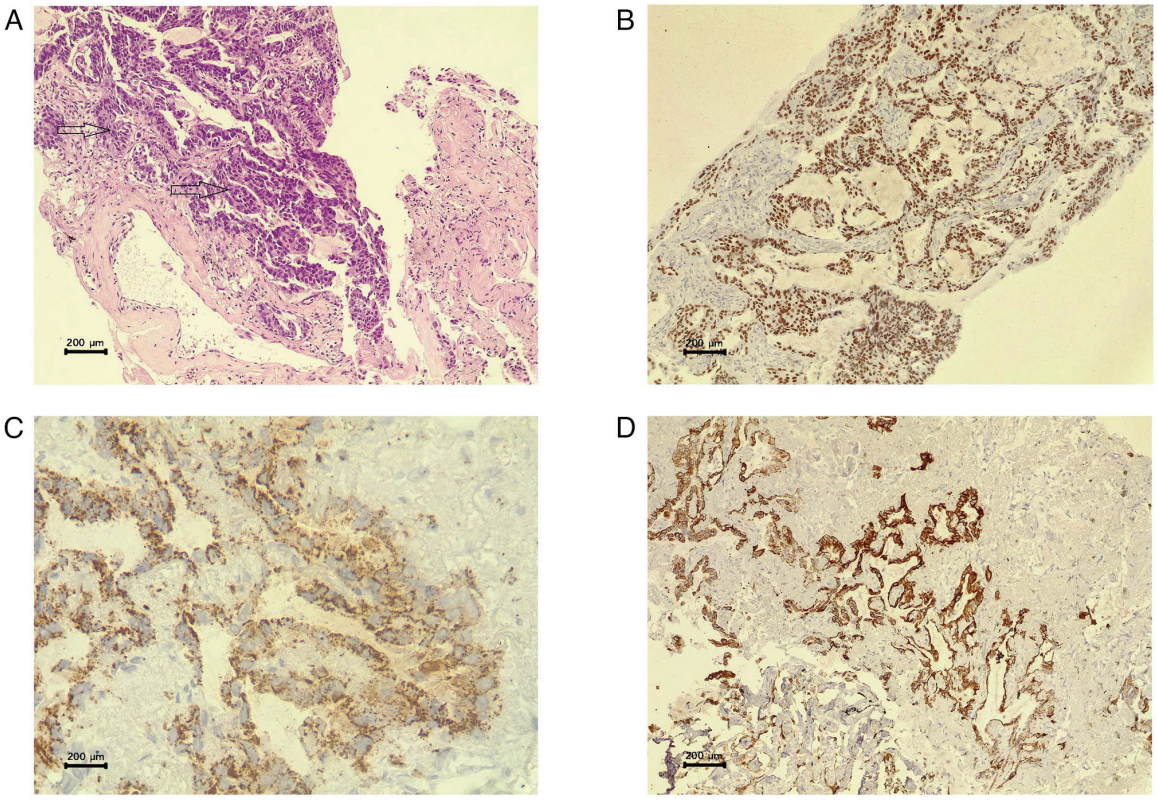

Figure 2. Histopathological and immunohistochemical images of a case with adenocarcinoma. (A) Section illustrating infiltrative malignant glands (dark arrows) with marked nuclear atypia and hyperchromasia, stained with hematoxylin and eosin; magnification, x10. (B) TTF1 immunostaining illustrating a nuclear staining pattern. (C) Napsin A positivity is characterized by a granular cytoplasmic staining pattern. (D) CK7 positivity in lung adenocarcinoma is indicated by a strong cytoplasmic staining pattern.

Table IV. The comparison of the morphological and histopathological findings of endobronchial lesions with the corresponding pre-BW and post-BW results.

	Pre-BW			Post-BW		
Morphology	Positive	Negative	P-value[a]	Positive	Negative	P-value[a]
Tumorous	19 (47.5%)	21 (52.5%)	0.75	21 (52.5%)	19 (47.5%)	0.88
Tumorous and Necrosis	0 (0.0%)	1 (100.0%)		1 (100.0%)	0 (0.0%)	
Infiltrative	2 (28.6%)	5 (71.40%)		1 (14.3%)	6 (85.7%)	
Submucosal	0 (0.0%)	1 (100.0%)		0 (0.0%)	1 (100.0%)	
Fungating	0 (0.0%)	1 (100.0%)		0 (0.0%)	1 (100.0%)	
Biopsy						
ADC	6 (33.3%)	12 (66.7%)	0.65	5 (27.8%)	13 (72.2%)	0.90
SCLC	4 (50.0%)	4 (50.0%)		4 (50.0%)	4 (50.0%)	
SCC	10 (45.5%)	12 (54.5%)		14 (63.6%)	8 (36.4%)	
Acinar	1 (100.0%)	0 (0.0%)		0 (0.00%)	1 (100.0%)	
None	0 (0.0%)	1 (100.0%)		0 (0.00%)	1 (100.0%)	

[a]Data were analyzed using Fisher's exact test. ADC, adenocarcinoma; SCLC, small cell lung carcinoma; SCC, squamous cell carcinoma; Acinar, acinar cell carcinoma; None, non-malignant.

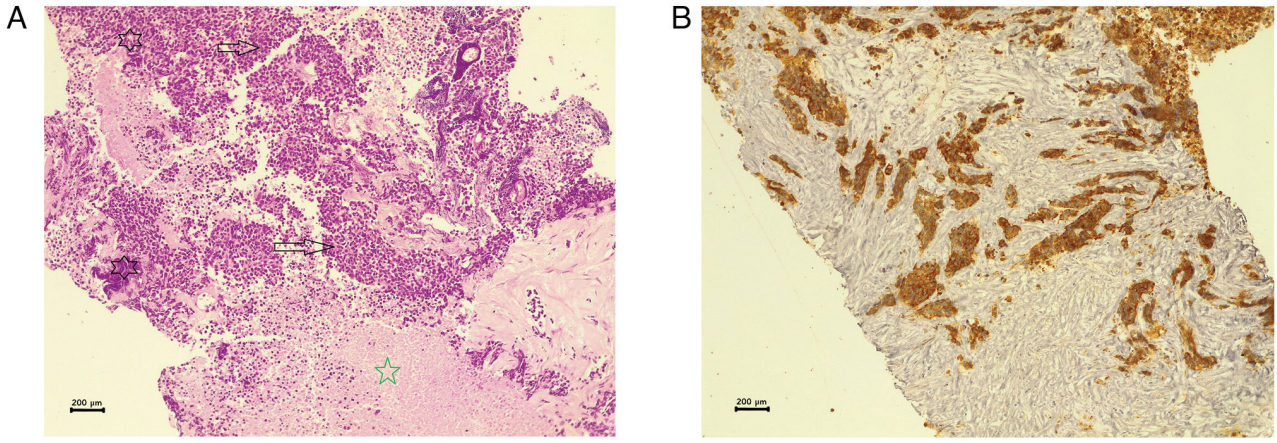

Figure 3. Histopathological and immunohistochemical images of a case with small cell lung carcinoma. (A) Sections display sheets of malignant small hyperchromatic cells (dark arrows) with signs of crushing artifact (dark stars) and areas of necrosis (green star), stained with hematoxylin and eosin; magnification, x10. (B) Chromogranin immunostaining illustrating a cytoplasmic staining pattern.

study indicated that the majority of patients were elderly males, revealing varying levels of smoking exposure within the group. Furthermore, the majority of the patients had other medical comorbidities and exhibited abnormal findings on a chest radiography, while CT scans revealed that almost half of the patients had masses >5 cm. These characteristic distributions offer valuable insight into factors influencing the surgical candidacy and post-operative outcomes of this population. A related study by Stanzel (19), performed in 2013, recommended selecting the area with the most prominent abnormality observed on chest radiographs or CT scans as the preferred site for bronchial washing in patients exhibiting substantial radiographic heterogeneity or localized lesions due to inflammatory infiltrates malignant growths, or other causes. Some researchers advocate performing bronchial washing at two or three different sites to enhance sample representation (19).

Several studies have investigated the impact of lung tumors located in the lower lobes on patient outcomes. The findings have indicated that lower lobe cancer is associated with higher overall mortality rates of patients with lung cancer, potentially due to lower rates of beneficial epidermal growth factor receptor mutations. The location of these tumors in the lower lungs may, therefore, contribute to poorer prognoses, particularly in cases of endobronchial lesions (20,21). The present study reported that the right side exhibited a slightly higher overall involvement, although it should be noted that almost half of the lesions were predominantly located in the lower lobes of the lungs, which, as aforementioned earlier, can be a negative prognostic factor for this patient group. Less frequent involvement was observed in the right middle lobe and right main bronchus. The histopathological examination further identified squamous cell carcinoma as the most prevalent subtype, which can be explained by the

higher rate of squamous cell carcinoma amongst smokers compared to non-smokers (22), which is in accordance with the current cohort of patients with the vast majority being smokers, followed by adenocarcinoma, and small cell lung carcinoma. Furthermore, the study by Biciuşcă *et al* (23) reported that the majority of endobronchial lesions exhibited infiltrative morphology. However, tumorous patterns, as well as less common characteristics, such as necrosis, submucosal involvement and fungating features, were also observed (23). In contrast to these findings, the present study demonstrated that the predominant morphology of endobronchial lesions was tumorous, accounting for 80% of the cases, followed by an infiltrative pattern. Uncommon morphologies, including tumorous necrosis, submucosal features and a fungating appearance, were also detected, suggesting a diverse range of growth presentations and heterogeneity in the morphological characteristics and providing valuable insights into the histological characteristics within the analyzed cohort. Considering this diversity, it is necessary to further examine the mechanisms through which specific growth presentations can affect diagnostic evaluations and treatment planning approaches to optimize patient outcomes.

A previous study reported a diagnostic yield of 52-77% for bronchial brushing in endoscopically visible tumors, which was not significantly superior to the yield achieved with biopsy alone. The efficacy of brushing may depend on the order in which it is performed relative to the biopsy, although this aspect has yet to be extensively studied (24). However, the study by Lim *et al* (10), examining the optimal washing sequence before or after the biopsy on 166 patients, found no significant difference in the diagnostic yield between the two sequences. The study by Rao *et al* (4) demonstrated that bronchial wash cytology had a low sensitivity in detecting pulmonary lesions. However, it can still provide value for patients with contraindications for biopsy. In situations where biopsy is not feasible, morphometry can be a useful adjunct to cytomorphology (4). Notably, Hou *et al* (24), in a study on 362 patients, revealed that pre-biopsy brushings outperformed post-biopsy brushings in diagnosing exophytic tumors; the enhanced diagnostic efficacy through pre-biopsy brushings is elucidated in the following manner: Prior to the biopsy procedure, exophytic tumors are readily visualized and amenable to sampling due to their distinctive nodular or focal mass appearance. Conversely, post-biopsy, the occurrence of bleeding introduces contamination to the already confined area designated for brushing, thereby complicating the identification and sampling of pertinent tissue (20). This is in contrast to the findings of the study by Chaudhary *et al* (25) on the sequencing of bronchial washing and biopsy. Chaudhary *et al* (25) suggested that post-biopsy washing yielded higher diagnostic rates. They clarified their findings by proposing that the biopsy procedure released tumor cells, thereby enabling a greater collection of these cells during the washing process (25). In the study by Lee *et al* (16) involving 207 patients with a definitive cytological or histological diagnosis of lung cancer, it was determined that the sequence of performing bronchial washing, whether before or after forceps biopsy, did not affect the diagnostic yield of bronchial washing. However, bronchial washing significantly increased the overall diagnostic yield of bronchoscopy in patients with lung cancer (16).

In their study on 75 patients, Fernández-Villar *et al* (26) found that bronchial washing fluid was positive in 40 patients (53.3%) when the washing was performed before brushing and forceps biopsy. When the washing was performed after these procedures, it was positive in 43 patients (57.3%) (P=0.6) (26). However, Raymond *et al* (27) found no significant differences in diagnostic yield for central tumors regardless of the timing of wash fluid collection. However, they observed differences for tumors not visible on endoscopy: Positive results were found in 25% of wash fluids collected before other sampling procedures compared to 45% for samples collected afterward (27).

In another study involving 54 patients, Yigla *et al* (28) found that washing was positive for malignancy in 33% of cases before brushing and biopsy, compared to 48% when performed afterward. However, this difference was not statistically significant (28). Additionally, van der Drift *et al* (29) reported a diagnostic yield of 72% from aspirated wash fluids collected before biopsy and brushing and 74% after these procedures in a series of 137 patients with endoscopically visible tumors (P=0.85).

Unlike these studies, the present study demonstrated a significant change in the results pre-BW and post-BW. Of note, four pre-BW positive results became negative post-BW, while six pre-BW negative results became positive post-BW (P-value <0.001; Table III). Despite this change, the overall positive results included 23 (46%) patients. In addition, the comparison of the morphological and histopathological findings of endobronchial lesions with the corresponding pre-BW and post-BW results did not reveal any significant differences.

The present study is limited by its small sample size, and it should be noted that the findings may only partially represent the broader population. Additionally, the present study was a single-center experience, which may limit the generalizability of the findings.

Further studies using larger sample sizes or meta-analyses, are required to evaluate the effectiveness of this strategy and optimize the diagnostic methods by exploring sample collection sequences or integrating multiple techniques. Understanding these findings may help tailor flexible bronchoscopy protocols to maximize diagnostic accuracy and improve clinical decision-making. Additionally, the specifics of bronchoscopic procedures could affect their diagnostic yield.

Of note, a limitation of the present study is that the details of the histopathological and immunohistochemical analyses could not be retrieved, as these analyses were conducted at an external center. In conclusion, bronchial washing pre- and post-BW may affect the yield of diagnostic outcomes for endoscopically visible lung tumors. However, additional research, such as studies using larger sample sizes or meta-analyses, are warranted to fully determine the efficacy of this approach.

Acknowledgements

Not applicable.

Funding

No funding was received.

Availability of data and materials

The datasets used and/or analyzed during the current study are available from the corresponding author upon reasonable request.

Authors' contributions

HKA was a major contributor to the conception of the study and the literature search for related studies. BAA, DSH and FHK were involved in the literature review and manuscript writing. KAQ, BAA, FHK and KMA were involved in the literature review, in the conception and design of the study, in the critical revision of the manuscript, and in the processing of the tables. DSH and BAA were involved in data collection and analysis. FHK and BAA confirm the authenticity of all the raw data. All authors have read and approved the final manuscript.

Ethics approval and consent to participate

The present study received ethical approval from the Sulaimani University Ethics Committee, Sulaymaniyah, Iraq (2024/no. 83). Written informed consent was obtained from the patients for their participation in the present study.

Patient consent for publication

Not applicable.

Competing interests

The authors declare that they have no competing interests.

References

1. Mingomataj E, Krasniqi M, Dedushi K, Sergeevich KA and Kust D, Qadir AA, Abdullah AS, Ahmed MK and Fatah GM: Cancer Publications in One Year (2023): A Cross-Sectional Study. Barw Med J 2: 3-11, 2024.
2. Bade BC and Cruz CS: Lung cancer 2020: Epidemiology, etiology, and prevention. Clin Chest Med 41: 1-24, 2020.
3. Nooreldeen R and Bach H: Current and future development in lung cancer diagnosis. Int J Mol Sci 22: 8661, 2021.
4. Rao S, Rao S, Lal A, Barathi G, Dhanasekar T and Duvuru P: Bronchial wash cytology: A study on morphology and morphometry. J Cytol 31: 63-67, 2014.
5. Roncarati R, Lupini L, Miotto E, Saccenti E, Mascetti S, Morandi L, Bassi C, Rasio D, Callegari E, Conti V, *et al*: Molecular testing on bronchial washings for the diagnosis and predictive assessment of lung cancer. Mol Oncol 14: 2163-2175, 2020.
6. Schramm D, Freitag N, Nicolai T, Wiemers A, Hinrichs B, Amrhein P, DiDio D, Eich C, Landsleitner B, Eber E, *et al*: Pediatric airway endoscopy: Recommendations of the society for pediatric pneumology. Respiration 100: 1128-1145, 2021.
7. Patil S, Toshniwal S and Acharya A: Role of fiberoptic bronchoscopy-guided needle aspiration cytology (EBNA) in diagnosing lung cancer in endobronchial lesions: A single-center experience. Int J Mol Immuno Oncol 8: 15-22, 2023.
8. Xia Y, Li Q, Zhong C, Wang K and Li S: Inheritance and innovation of the diagnosis of peripheral pulmonary lesions. Ther Adv Chronic Dis 14: 20406223221146723, 2023.
9. Wang J, Zhang T, Xu Y, Yang M, Huang Z, Lin J, Xie S and Sun H: Comparison between percutaneous transthoracic co-axial needle CT-guided biopsy and transbronchial lung biopsy for the diagnosis of persistent pulmonary consolidation. Insights Imaging 14: 80, 2023.
10. Lim JH, Kim MJ, Jeon SH, Park MH, Kim WY, Lee M, Kim JH, Kim JS, Kim YS, Kim L, *et al*: The optimal sequence of bronchial brushing and washing for diagnosing peripheral lung cancer using non-guided flexible bronchoscopy. Sci Rep 10: 1036, 2020.
11. Abdullah HO, Abdalla BA, Kakamad FH, Ahmed JO, Baba HO, Hassan MN, Bapir R, Rahim HM, Omar DA, Kakamad SH, *et al*: Predatory publishing lists: A review on the ongoing battle against fraudulent actions. Barw Med J 2: 26-30, 2024.
12. Karahalli E, Yilmaz A, Türker H and Özvaran K: Usefulness of various diagnostic techniques during fiberoptic bronchoscopy for endoscopically visible lung cancer: Should cytologic examinations be performed routinely?. Respiration 68: 611-614, 2001.
13. Kvale PA, Bode FR and Kini S: Diagnostic accuracy in lung cancer; comparison of techniques used in association with flexible fiberoptic bronchoscopy. Chest 69: 752-757, 1976.
14. Jones AM, Hanson IM, Armstrong GR and O'Driscoll BR: Value and accuracy of cytology in addition to histology in the diagnosis of lung cancer at flexible bronchoscopy. Respir Med 95: 374-378, 2001.
15. Govert JA, Dodd LG, Kussin PS and Samuelson WM: A prospective comparison of fiberoptic transbronchial needle aspiration and bronchial biopsy for bronchoscopically visible lung carcinoma. Cancer 87: 129-134, 1999.
16. Lee HS, Kwon SY, Kim DK, Yoon HI, Lee SM, Lee JH, Lee CT, Chung HS, Han SK, Shim YS and Yim JJ: Bronchial washing yield before and after forceps biopsy in patients with endoscopically visible lung cancers. Respirology 12: 277-282, 2007.
17. Carvalho AS, Cuco CM, Lavareda C, Miguel F, Ventura M, Almeida S, Pinto P, de Abreu TT, Rodrigues LV, Seixas S, *et al*: Bronchoalveolar lavage proteomics in patients with suspected lung cancer. Sci Rep 7: 42190, 2017.
18. Endalie D and Abebe WT: Analysis of lung cancer risk factors from medical records in Ethiopia using machine learning. PLoS Digital Health 2: e0000308, 2023.
19. Stanzel F: Bronchoalveolar Lavage. In: Principles and Practice of Interventional Pulmonology. Ernst A and Herth FJF (eds). Springer Nature, pp165-176, 2012.
20. Lee HW, Park YS, Park S and Lee CH: Poor prognosis of NSCLC located in lower lobe is partly mediated by lower frequency of EGFR mutations. Sci Rep 10: 14933, 2020.
21. Xie X, Li X, Tang W, Xie P and Tan X: Primary tumor location in lung cancer: The evaluation and administration. Chin Med J (Engl) 135: 127-136, 2021.
22. Drilon A, Rekhtman N, Ladanyi M and Paik P: Squamous-cell carcinomas of the lung: emerging biology, controversies, and the promise of targeted therapy. Lancet Oncol 13: e418-e426, 2012.
23. Biciuşcă V, Popescu IAS, Traşcă DM, Olteanu M, Stan IS, Durand P, Camen GC, Bălteanu MA, Cazacu IM, Demetrian AD, *et al*: Diagnosis of lung cancer by flexible fiberoptic bronchoscopy: A descriptive study. Rom J Morphol Embryol 63: 369-381, 2022.
24. Hou G, Miao Y, Hu XJ, Wang W, Wang QY, Wu GP, Wang EH and Kang J: The optimal sequence for bronchial brushing and forceps biopsy in lung cancer diagnosis: A random control study. J Thorac Dis 8: 520-526, 2016.
25. Chaudhary BA, Yoneda K and Burki NK: Fiberoptic bronchoscopy: Comparison of procedures used in the diagnosis of lung cancer. J Thorac Cardiovasc Surg 76: 33-37, 1978.
26. Fernández-Villar A, González A, Leiro V, Represas C, Botana MI, Blanco P, Mosteiro M and Piñeiro L: Effect of different bronchial washing sequences on diagnostic yield in endoscopically visible lung cancer. Arch Bronconeumol 42: 278-282, 2006 (In Spanish).
27. Raymond NJ, McLeod S and Thornley PE: Timing of bronchial washing at fibrebronchoscopy improves the diagnostic rate of primary bronchial carcinoma. Thorax 46 (Suppl): S289, 1991.
28. Yigla M, Nagiv D, Solomonov A, Malberger E, Ben-Izhak O, Rubin AH and Keren R: Timing of collecting bronchoscopic cytologic specimens in endobronchial malignant neoplasms. Journal of Bronchology & Interventional Pulmonology 9: 272-275, 2002.
29. van der Drift MA, van der Wilt GJ, Thunnissen FB and Janssen JP: A prospective study of the timing and cost-effectiveness of bronchial washing during bronchoscopy for pulmonary malignant tumors. Chest 128: 394-400, 2005.